


This article was downloaded by: [UNAM Ciudad Universitaria]

On: 21 December 2014, At: 11:41

Publisher: Routledge

Informa Ltd Registered in England and Wales Registered Number: 1072954 Registered office: Mortimer House, 37-41 Mortimer Street, London W1T 3JH, UK



Neurocase: The Neural Basis of Cognition

Publication details, including instructions for authors and subscription information:
<http://www.tandfonline.com/loi/nncs20>

Limb apraxia in acute ischemic stroke: A neglected clinical challenge?

Caroline Schell^a, Julia Suchan^b, Marc Himmelbach^b, Thomas Haarmeier^{ac} & Svenja Borchers^b

^a Department of Neurology and Epileptology, Hertie-Institute for Clinical Brain Research, Eberhard Karls University, Tübingen, Germany

^b Center for Neurology, Division of Neuropsychology, Hertie-Institute for Clinical Brain Research, Centre for Integrative Neuroscience, Eberhard Karls University, Tübingen, Germany

^c Department of Neurology, University Hospital RWTH Aachen, Aachen, Germany
Published online: 04 Jan 2013.



[Click for updates](#)

To cite this article: Caroline Schell, Julia Suchan, Marc Himmelbach, Thomas Haarmeier & Svenja Borchers (2014) Limb apraxia in acute ischemic stroke: A neglected clinical challenge?, *Neurocase: The Neural Basis of Cognition*, 20:2, 158-162, DOI: [10.1080/13554794.2012.741253](https://doi.org/10.1080/13554794.2012.741253)

To link to this article: <http://dx.doi.org/10.1080/13554794.2012.741253>

PLEASE SCROLL DOWN FOR ARTICLE

Taylor & Francis makes every effort to ensure the accuracy of all the information (the "Content") contained in the publications on our platform. However, Taylor & Francis, our agents, and our licensors make no representations or warranties whatsoever as to the accuracy, completeness, or suitability for any purpose of the Content. Any opinions and views expressed in this publication are the opinions and views of the authors, and are not the views of or endorsed by Taylor & Francis. The accuracy of the Content should not be relied upon and should be independently verified with primary sources of information. Taylor and Francis shall not be liable for any losses, actions, claims, proceedings, demands, costs, expenses, damages, and other liabilities whatsoever or howsoever caused arising directly or indirectly in connection with, in relation to or arising out of the use of the Content.

This article may be used for research, teaching, and private study purposes. Any substantial or systematic reproduction, redistribution, reselling, loan, sub-licensing, systematic supply, or distribution in any form to anyone is expressly forbidden. Terms & Conditions of access and use can be found at <http://www.tandfonline.com/page/terms-and-conditions>

Limb apraxia in acute ischemic stroke: A neglected clinical challenge?

Caroline Schell¹, Julia Suchan², Marc Himmelbach², Thomas Haarmeier^{1,3},
and Svenja Borchers²

¹Department of Neurology and Epileptology, Hertie-Institute for Clinical Brain Research, Eberhard Karls University, Tübingen, Germany

²Center for Neurology, Division of Neuropsychology, Hertie-Institute for Clinical Brain Research, Centre for Integrative Neuroscience, Eberhard Karls University, Tübingen, Germany

³Department of Neurology, University Hospital RWTH Aachen, Aachen, Germany

Symptoms of limb apraxia and executive dysfunctions are currently not explicitly considered by the National Institutes of Health Stroke Scale and, thus, not routinely tested by clinicians in the acute care of patients with suspected stroke. Neuropsychological testing, clinical examination, MRI, and functional magnetic resonance imaging (fMRI) were performed in a right-handed patient with acute onset of left-sided sensorimotor hemiparesis due to a right hemisphere ischemic stroke. Deficits in the execution of meaningless and meaningful gestures were not detected properly on initial clinical examination but were revealed later on through neuropsychological testing. Instead, the patient's inability to respond to specific instructions in the acute care setting was mistaken to reflect severe deficits in auditory comprehension. fMRI revealed right-hemispheric localization of language in the right-handed patient. We suggest including a bedside test for limb apraxia symptoms in acute clinical care of stroke patients. The distinction between deficits in limb praxis and impairments of language can be complicated owing to the common hemispheric co-localization of the two functions.

Keywords: Aphasia; Limb apraxia; Stroke fMRI; Bedside test.

In the care of patients with suspected stroke not only motor and sensory symptoms but also neuropsychological deficits should be examined early in the course of the disease in order to improve acute stroke treatment and neurorehabilitation care affecting long-term outcome. The National Institutes of Health Stroke Scale (NIHSS) is the most commonly used standardized neurologic examination tool for detecting and quantifying different neurological and neuropsychological

impairments in stroke patients (Odderson, 1999). In contrast to aphasia and visuo-spatial neglect, a routine screening test for symptoms of limb apraxia is currently not part of the NIHSS. Apraxia might therefore not be detected and could result in misinterpretations of other clinical aspects addressed by the NIHSS. Proper diagnosis of limb apraxia, however, is important because of its negative impacts on daily life activity (Hanna-Pladdy, Heilman, & Foundas, 2003).

Address correspondence to Thomas Haarmeier, MD, Department of Neurology, University Hospital RWTH Aachen, Pauwelsstraße 30, 52074. Aachen, Germany. (E-mail: thaarmeier@ukaachen.de).

We are indebted to our patient for his patience and motivation. We are grateful to the Division of Neuropsychology (Prof. Karnath) and the Department of Neuroradiology (Prof. Ernemann) of the University of Tuebingen for the support in data acquisition. This work was supported by the European Union (ERC StG 211078).

Conflict of Interest: None.

Limb apraxia comprises a rather diverse range of disorders of skilled movement which cannot be accounted for by an elementary motor or sensory impairment or cognitive deficit (Goldenberg, 2008, 2009; Pearce, 2009). Early theory-based classifications of limb apraxia seem to be ill-defined and not based on sufficient empirical evidence. Neither do they find a consistent use among researchers and clinicians (Goldenberg, 2008). Therefore, recent clinical and basic research on limb apraxia has focused on specific behavioral impairments that are consistently addressed as symptoms of limb apraxia (e.g., imitation of meaningless and meaningful gestures, gestures on command, tool use) instead of theoretical constructs like ideomotor versus ideational limb apraxia.

We here present the case of a right-handed patient who showed severe impairments in the imitation and instructed execution of meaningless and meaningful gestures with his upper limbs and also the use of everyday tools. For the sake of brevity we will refer to this combination of symptoms as limb apraxia in this report. The patient's consistent inability to respond adequately even to simple instructions in the acute clinical situation was initially misdiagnosed as sensory aphasia as a consequence of right hemisphere stroke.

CASE

A 53-year-old right-handed man presented to our stroke unit with suspected stroke. On examination,

he was alert showing a brachiofacial hemiplegia of the left side. Furthermore, he apparently presented sensory and motor impairments of language and was not able to follow verbal instructions or to respond verbally himself (NIHSS: 12). CT and CT perfusion scanning revealed delayed and decreased perfusion in the territory of the right middle cerebral artery (MCA). The CT angiogram showed an occlusion of the MCA on the M1 segment. Recanalization was achieved by endovascular thrombolysis starting 2.5 hours after onset of the first symptoms. Control MRI scans on day 4 revealed demarcation of the infarcted territory emphasizing large parts of insular and parietal cortex and basal ganglia of the right hemisphere (Figure 1A, C).

In the following days, the left-sided hemiplegia improved and spontaneous speech recovered fully. He did not show any relevant phonological or phonetic impairments of speech production that would indicate aphasia or apraxia of speech. However, auditory comprehension still seemed to be severely impaired. In conclusion, the patient was in all respects treated as a non-communicative patient. The unusually clear discrepancy between unimpaired spontaneous speech and dramatic deficits in auditory comprehension eventually raised doubts on the diagnosis of sensory aphasia. Sensory aphasia is usually associated with fluent, but severely disorganized speech production (Hillis, 2007). Indeed, detailed neuropsychological assessment showed a severe impairment in the imitation and pantomime of meaningless and

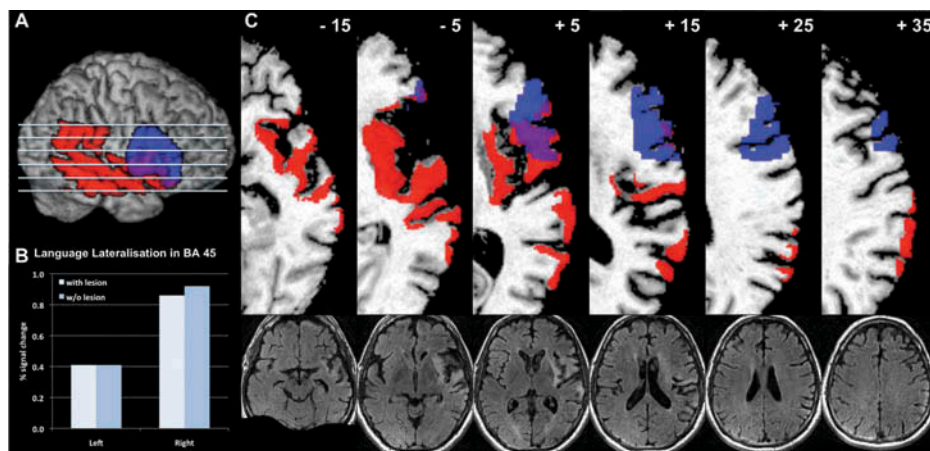


Figure 1. Anatomy of the lesion and fMRI ROI results. (A) Individual normalised rendered T1 scan with overlays of BA45 (blue) and the lesion (red). The slices that are shown in C are indicated. (B) The signal changes of the language lateralization task for left and right BA45 and BA45 without the lesion. (C) Six single horizontal slices are shown indicating the lesion (red) and BA45 (blue), i.e., the ROI for the fMRI analysis. The z -values are indicated at the top in MNI-coordinates and Talairach space. The bottom row shows the corresponding T2 fluid-attenuated inversion recovery (FLAIR) slices. [To view this figure in color, please visit the online version of this Journal.]

TABLE 1
Neuropsychological assessment 14 and 69 days post-stroke

	14 days post-stroke	69 days post-stroke
<i>Limb Apraxia Tests</i>		
1. Meaningless imitation (Goldenberg, 1996)		
• Right hand	12/20	20/20
• Left hand	12/20	18/20
• Right fingers	18/20	19/20
• Left fingers	13/20	19/20
2. Pantomiming (Goldenberg, Hermsdorfer, Glindemann, Rorden, & Karnath, 2007)	15/55	43/55
3. Pantomiming after visual presentation of objects ¹	–	11/15
4. Actual object usage ²	2/7	15/15
5. Complex object usage ³	–	4/4
<i>Aphasia Tests</i>		
1. Bedside Screening (Weniger, 2006)		
• Repetition of speech	6/10	10/10
• Reading aloud	6/6	6/6
• Naming	8/8	8/8
• Depicting	8/10	9/10
• Writing	6/6	5.5/6
• Auditory comprehension	8/8	6/8
• Visual comprehension	7/8	5/8
<i>Executive Tests</i>		
1. Wisconsin Card Sorting Test ⁴	Below average	Below average
• Total errors	58%	49%
• Perseverative errors	34%	35%
• Categories achieved	0/6	1/6
2. Trail Making Test-A/-B	–	(A) $z = 0.98$ (B) $z = -0.8$
3. Tower of London (TL-D)	–	12/20 (percentile rank: 6%)
<i>Neglect Tests (Rorden & Karnath, 2010)</i>		
1. Letter cancellation		
• Left	22	28
• Right	29	30
• CoC-value	0.094	0.034
2. Bells cancellation		
• Left	12	13
• Right	10	15
• Coc-value	-0.083	0.044
3. Copy task	1	0 (but spatially conspicuous)

¹Fifteen objects were visually presented on the table out of peripersonal space: comb, key, hammer, screwdriver, cup, wooden saw, pen, spoon, screw-wrench, toothbrush, paint-brush, scrubber, watering can, rubber, knife.

²In the first examination, seven objects were used: wooden saw, hammer, comb, pen, key, screwdriver, cup. In the second examination, the same fifteen objects were used as for pantomiming after visual presentation.

³Opening and closing a padlock with a key; drinking a glass of water where a crown cap had to be opened first; preparing a letter to be sent, preparing coffee with a standard filter coffee machine.

⁴The whole set contains 128 trials. In the first measurement 71 trials were performed, in the second measurement 115 trials due to reduced resilience. Therefore, the percentage of errors is calculated to compare them to group means of a normative sample (cutoff for total errors: 19%; cutoff for perseverative errors: 13%).

meaningful gestures as well as in the actual usage of objects and tools (Table 1). Additionally, the patient showed noticeable impairments in executive tasks producing perseverative responses and demonstrating inefficient conceptualization. These impairments of executive functions together with severe limb apraxia are indeed sufficient to explain

persistent problems to follow even simple verbal instructions with simultaneous full remission of spontaneous speech production.

During a follow-up neuropsychological assessment 9 weeks post stroke after rehabilitation training, the patient clearly demonstrated major improvements of limb apraxia and also in following

verbal instructions, although still presenting residual symptoms mainly during pantomiming (Table 1).

fMRI measurement

A functional magnetic resonance imaging (fMRI) study using a word generation task for detecting lateralization of language was conducted 69 days after stroke (see e.g., Chlebus et al., 2007). We used a block design with active tasks alternating with periods of rest, each block lasting 30 seconds. Twelve blocks of word generation were performed within two sessions. The patient silently generated as many words as possible, beginning with a letter that was visually presented. The task was practiced before scanning verifying that the patient understood the task and performed it accurately. During the rest periods, the patient simply relaxed. We conducted a region-of-interest (ROI) analysis for signal levels in Brodmann area (BA) 45. The definition of this region was derived from a combination of the patient's individual anatomy with a standardized histological definition (Amunts et al., 1999). This ROI analysis showed higher right-hemisphere signal changes during the active task in the patient (Figure 1B). Since part of BA45 overlaps with the lesion of this patient, the signal changes as well as the lateralization indices were calculated for both the original ROI covering the complete BA45 and a modified ROI where BA45 was masked with the lesion. The lateralization index (classical MRLI = $(L-R)/(L+R)*100$ (+100 = strong left hemisphere dominance; -100 = strong right hemisphere dominance; see Chlebus et al., 2007)) for an uncorrected threshold of $p = .001$ yielded an MRLI = -21 for the original ROI and an MRLI = -22 for the ROI without lesion. When corrected for multiple comparisons (FWE, $p = .05$), the functional analysis yielded an MRLI = -32 for both the original and the modified ROI, altogether suggesting an atypical language lateralization in this patient.

DISCUSSION

We present the case of a right-handed patient with left-sided sensorimotor hemiparesis and persisting symptoms of limb apraxia due to a right-hemisphere ischemic stroke. Critically, limb apraxia was not detected initially by standard clinical examinations, which are essentially based on

the widely used NIHSS. Therefore, any following examinations were biased by the assumption of a severe aphasia instead and the patient was addressed and treated as non-communicative. In emergency care this is rather unfortunate since immediate therapeutic decisions such as thrombolysis may not be discussed with the patient himself when an impaired auditory comprehension is misconceived. So the patient is not involved himself in the therapeutic decisions with all consequences. Furthermore, decisions in targeted rehabilitation would depend crucially on a distinction between limb apraxia, executive dysfunctions, and sensory aphasia early in the acute phase of stroke. Based on our experience, we presume that limb apraxia and executive dysfunctions mimicking aphasia in acute ischemic stroke is an underestimated problem. The reasons are 2-fold. First, since the NIHSS does not include tests assessing limb apraxia but attributes any noticeable problems of auditory (i.e., instruction) comprehension to aphasia, limb apraxia is often not diagnosed. Supplementary tests for limb apraxia fitting to the particular needs of emergency care settings have not been used consistently so far. Second, neural networks supporting praxis overlap with language circuits.

Recently, a new bedside test was established allowing reliable and valid assessment of limb apraxia within minutes based on the test for upper-limb apraxia (TULIA) (Vanbellinghen et al., 2011). The Birmingham Cognitive Screen, lasting around 1 hour, is not a test for the acute setting but provides a novel cognitive profile across a range of cognitive processes, amongst others also for praxis functions (Bickerton et al., 2012). In individuals with speech or language disorders, the Apraxia Battery for Adults (ABA-2) can be used for the diagnosis of limb apraxia when administered by experienced speech-language pathologists (Dabul, 2000). There are also standardized tools available to estimate the influence of apraxia on daily routine (Schwartz, Segal, Veramonti, Ferraro, & Buxbaum, 2002). We suggest that these tests should find a wider use in stroke assessment. Additionally, future versions of the NIHSS should explicitly incorporate the imitation of meaningful and meaningless gestures. Testing imitation only would obviously not cover the full range of limb apraxia symptoms. Yet, the nonverbal nature of these tests would allow for an evaluation of a patient's performance even in the presence of sensory aphasia.

In the majority of humans, language and praxis functions are both controlled dominantly by the left hemisphere (Bryden, Hecaen, & DeAgostini,

1983). In dextrals, the left hemisphere is assumed to be dominant for language in around 85% (Bryden et al., 1983). The lateralization for praxis is less clear due to the considerable variety of symptoms and test procedures associated with the concept of limb apraxia but is usually assumed to coincide with speech lateralization (for a detailed overview please see Goldenberg, 2008). Indeed, the laterality of parietal representations for gestures is predictive for the laterality of frontal representation for language (Kroliczak, Piper, & Frey, 2011). As shown with the fMRI language lateralization task, this phenomenon is exactly observed in our patient, although his initial aphasic symptoms were sparse and regressed rapidly. The case reported here is remarkable due to coincident right-hemispheric localization of both language and praxis in a right-handed patient. There are only few case studies presenting right-handed patients with apraxia and aphasia after right hemisphere stroke (e.g., Rapcsak, Gonzalez Rothi, & Heilman, 1987). This report is the first demonstrating lateralization of language in such a right-handed patient using fMRI.

In conclusion, we strongly suggest conducting a concise screening for limb apraxia symptoms even in the acute stage. Such a screening could be confined to a short test of the imitation of few meaningful and meaningless gestures. The atypical lateralization pattern in this patient reminds us to focus on overt behavioral impairments that seem to be unlikely to occur in a particular case.

Manuscript received 21 November 2011

Revised manuscript received 15 October 2012

First published online 3 January 2013

REFERENCES

- Amunts, K., Schleicher, A., Burgel, U., Mohlberg, H., Uylings, H. B., & Zilles, K. (1999). Broca's region revisited: Cytoarchitecture and intersubject variability. *The Journal of Comparative Neurology*, *412*, 319–341.
- Bickerton, W. L., Riddoch, M. J., Samson, D., Balani, A. B., Mistry, B., & Humphreys, G. W. (2012). Systematic assessment of apraxia and functional predictions from the Birmingham Cognitive Screen. *Journal of Neurology, Neurosurgery and Psychiatry*, *83*, 513–521.
- Bryden, M. P., Hecaen, H., & DeAgostini, M. (1983). Patterns of cerebral organization. *Brain and Language*, *20*, 249–262.
- Chlebus, P., Mikl, M., Brazdil, M., Pazourkova, M., Krupa, P., & Rektor, I. (2007). fMRI evaluation of hemispheric language dominance using various methods of laterality index calculation. *Experimental Brain Research*, *179*, 365–374.
- Dabul, B. (2000). *Apraxia battery for adults* (2nd ed.). Austin, TX: Pro-Ed.
- Goldenberg, G. (1996). Defective imitation of gestures in patients with damage in the left or right hemispheres. *Journal of Neurology, Neurosurgery and Psychiatry*, *61*, 176–180.
- Goldenberg, G. (2008). Apraxia. In G. Goldenberg & B. L. Miller (Eds.), *Handbook of clinical neurology. Vol. 88 Neuropsychology and behavioral* (pp. 323–338) *neurology*. Edinburgh: Elsevier B.V.
- Goldenberg, G. (2009). Apraxia and the parietal lobes. *Neuropsychologia*, *47*, 1449–1459.
- Goldenberg, G., Hermsdorfer, J., Glindemann, R., Rorden, C., & Karnath, H. O. (2007). Pantomime of tool use depends on integrity of left inferior frontal cortex. *Cerebral Cortex*, *17*, 2769–2776.
- Hanna-Pladdy, B., Heilman, K. M., & Foundas, A. L. (2003). Ecological implications of ideomotor apraxia: Evidence from physical activities of daily living. *Neurology*, *60*, 487–490.
- Hillis, A. E. (2007). Aphasia: Progress in the last quarter of a century. *Neurology*, *69*, 200–213.
- Kroliczak, G., Piper, B. J., & Frey, J. U. (2011). Atypical lateralization of language predicts cerebral asymmetries in parietal gesture representations. *Neuropsychologia*, *49*, 1698–1702.
- Odderson, I. R. (1999). The National Institutes of Health Stroke Scale and its importance in acute stroke management. *Physical Medicine and Rehabilitation Clinics of North America*, *10*, 787–800, vii.
- Pearce, J. M. (2009). Hugo Karl Liepmann and apraxia. *Clinical Medicine*, *9*, 466–470.
- Rapcsak, S. Z., Gonzalez Rothi, L. J., & Heilman, K. M. (1987). Apraxia in a patient with atypical cerebral dominance. *Brain and Cognition*, *6*, 450–463.
- Rorden, C., & Karnath, H. O. (2010). A simple measure of neglect severity. *Neuropsychologia*, *48*, 2758–2763.
- Schwartz, M. F., Segal, M., Veramonti, T., Ferraro, M., & Buxbaum, L. J. (2002). The Naturalistic Action Test: A standardised assessment for everyday action impairment. *Neuropsychological Rehabilitation*, *12*, 311–339.
- Vanbellinghen, T., Kersten, B., Van de Winckel, A., Bellion, M., Baronti, F., Müri, R., Bohlhalter, S. (2011). A new bedside test of gestures in stroke: The apraxia screen of TULIA (AST). *Journal of Neurology, Neurosurgery and Psychiatry*, *82*, 389–392.
- Weniger, D. (2006). Aphasia. In H. O. Karnath, W. Hartje, & W. Ziegler (Eds.), *Kognitive neurologie* (pp. 48–64). Stuttgart: Thieme.