

## Review

# Glioblastoma with the appearance of arteriovenous malformation: Pitfalls in diagnosis

Matthias Gmeiner<sup>a,\*</sup>, Michael Sonnberger<sup>b</sup>, Gabriele Wurm<sup>a</sup>, Serge Weis<sup>c</sup>

<sup>a</sup> Division of Neurosurgery, Landes-Nervenklinik Wagner-Jauregg, Linz, Austria

<sup>b</sup> Division of Neuroradiology, Landes-Nervenklinik Wagner-Jauregg, Linz, Austria

<sup>c</sup> Division of Neuropathology, Landes-Nervenklinik Wagner-Jauregg, Linz, Austria

## ARTICLE INFO

## Article history:

Received 29 August 2012

Received in revised form 3 December 2012

Accepted 9 December 2012

Available online 3 January 2013

## Keywords:

Glioblastoma

Vascular malformation

## ABSTRACT

**Objectives:** Very few cases of arteriovenous malformations (AVMs) associated with gliomas were reported so far in the literature.

**Methods:** Here, we report a rare case of a glioblastoma with an AVM-like lesion and review the existing literature.

**Results:** We report an unusual case of a 72-year old woman, who presented with a progressive history of aphasia, memory deficit, and headache. Initial MRI imaging was suggestive of a high-grade glioma for which a pterional craniotomy was performed. Intraoperatively, the lesion resembled a vascular malformation. Total extirpation of the lesion was verified by intraoperative MR imaging. Initial histopathological analysis revealed an AVM. Due to the discrepancy between the radiologic and histopathologic findings, the patient was monitored at close intervals. Two month later, multiple lesions were visible on MRI imaging, thus, supporting the diagnosis of malignant glioma. Therefore, after reinvestigating the histopathological sections and cutting the paraffin block in additional serial sections, in only 5% of the section a glioblastoma was discerned which was surrounded by an AVM-like lesion.

**Conclusion:** Gliomas are rarely found in association with AVMs and require accurate diagnostic evaluation and interpretation for adequate therapeutic interventions.

© 2012 Elsevier B.V. All rights reserved.

## Contents

1. Introduction.....	501
2. Materials and methods.....	501
3. Results.....	502
3.1. Case report.....	502
3.2. Review of the literature.....	503
4. Discussion.....	504
5. Conclusion.....	506
References.....	506

## 1. Introduction

Very few cases of arteriovenous malformations (AVMs) associated with gliomas were reported so far in the literature. Although several hypotheses have been generated, the pathogenesis of this lesion remains unclear [25]. Here, we report a rare case of a

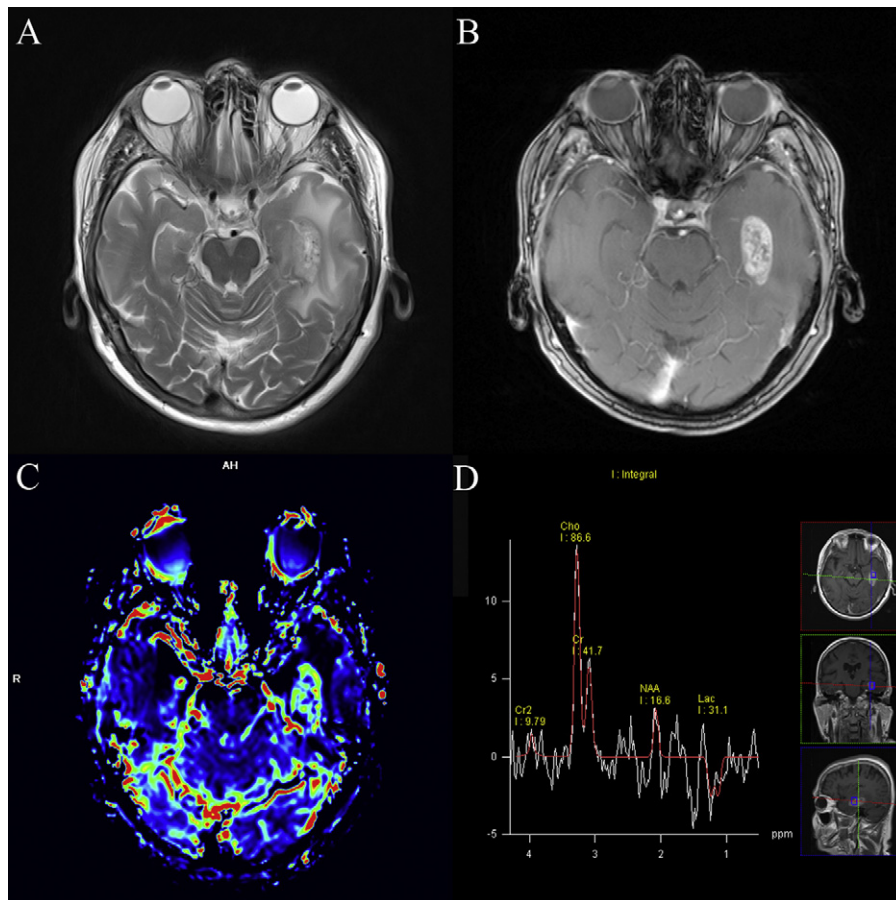
glioblastoma with an AVM-like lesion and review the existing literature. Such uncommon cases require adequate diagnostic evaluation and interpretation to avoid misdiagnosis. The combined appearance of a glioblastoma and an AVM in the same area has been published in three cases [1,3,19]. Therefore, the publication of such unusual cases in the medical literature is highly warranted.

## 2. Materials and methods

Publications for this review were identified by searching the PubMed using following keywords: “glioblastoma AND vascular

\* Corresponding author at: Division of Neurosurgery, Landes-Nervenklinik Wagner-Jauregg, Wagner-Jauregg-Weg 15A-4020, Linz, Austria.  
Tel.: +431 0505546228453; fax: +431 0505546225904.

E-mail address: [matthias.gmeiner@gespag.at](mailto:matthias.gmeiner@gespag.at) (M. Gmeiner).



**Fig. 1.** Preoperative MR imaging demonstrating a left temporal lesion with prominent vessels centrally in axial T2 (A) and contrast enhancement in axial T1 with contrast (B). Elevated cerebral blood flow is demonstrated in perfusion MR (C) with an increased choline peak and decreased NAA peak in MR-spectroscopy (D).

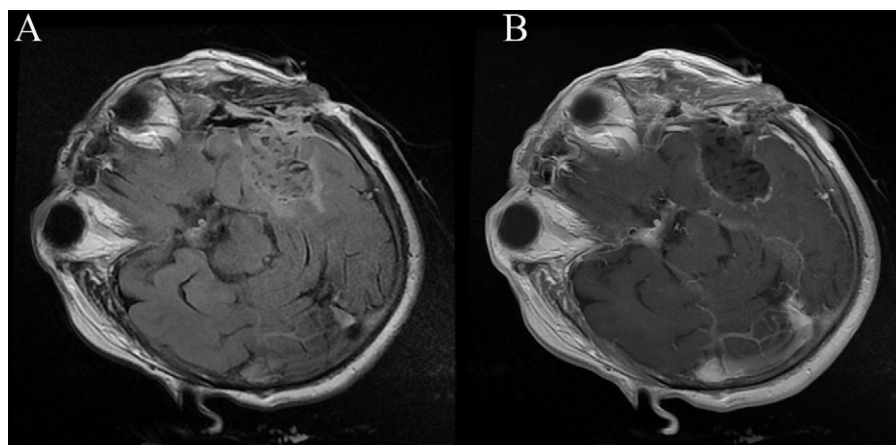
malformation”, “glioblastoma AND AVM”, “glioblastoma AND AVM-like malformation” or “angioglioma”. Searching period ranged from 1914 to April 2012. Further, we present a own case of a glioblastoma associated with an AVM-like lesion.

### 3. Results

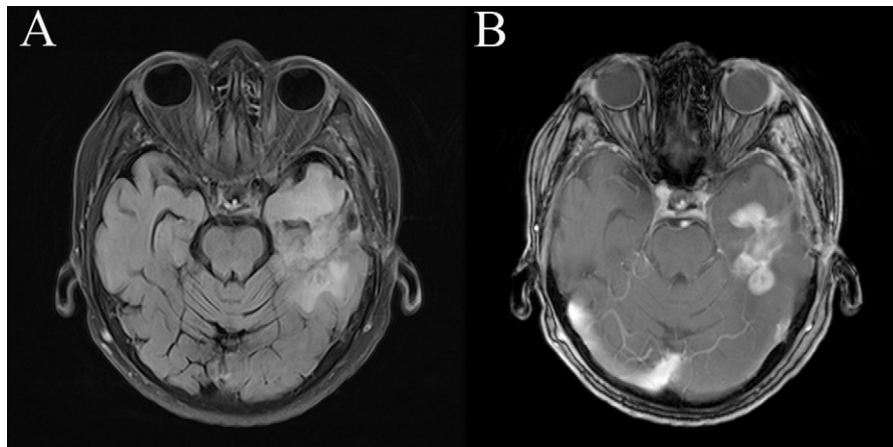
#### 3.1. Case report

A 72 years old female Caucasian presented in our hospital in October 2011 with an eight weeks history of progressive

aphasia, memory deficit, and headache. Initial CT-imaging revealed a left-sided temporal mass lesion with perifocal edema. Additional MRI imaging showed a left temporal lesion with prominent vessels located centrally within the lesion on axial T2 scans (Fig. 1A) and contrast enhancement in axial T1 (Fig. 1B). The contrast enhanced area showed elevated cerebral blood flow on perfusion MR scans (Fig. 1C). MR spectroscopy (Fig. 1D) indicated increased choline and decreased choline/N-acetyl aspartate (NAA) ratios, with an increased choline/NAA ratio above five consistent with a high-grade tumor. Thus, no preoperative angiography was performed. EEG analysis was normal. We decided to perform a left pterional



**Fig. 2.** Intraoperative MR imaging demonstrated complete resection of the contrast enhanced lesion, as seen in axial flair (A) and T1 with contrast (B).



**Fig. 3.** Postoperative MR imaging two month postoperatively. At the edges of the operation site recurrent tumor confirmed the diagnosis of glioblastoma multiforme in flair (A) and T1 with contrast (B).

craniotomy using neuronavigation and intraoperative MRI imaging. Intraoperatively, the lesion resembled a vascular malformation. Total resection of the lesion was verified by intraoperative MRI imaging (Fig. 2A and B). A representative specimen was sent for histological examination consisting of several pieces of brownish tissue measuring 2 cm × 1 cm × 0.7 cm in size. The histological section showed an accumulation of numerous vessels of various diameters displaying arterial and venous wall differentiation, some areas of old hemorrhage and reactive astrogliosis were also seen. Postoperatively, a CT angiography was performed showing no vascular malformation. Due to the discrepancy between the preoperative radiographic findings and the histological diagnosis we decided to monitor the patient at close intervals.

Two month later, MRI imaging was performed and at the edges of the operation site recurrent tumor was indicative of glioblastoma multiforme on FLAIR-scans (Fig. 3A) and contrast enhanced T1-scans (Fig. 3B). Therefore, histological sections were reinvestigated (Fig. 4) and the paraffin block was cut into additional serial sections (Fig. 5). One area of the section showed a tissue compatible with glioblastoma, *i.e.* accumulation of astrocytic tumor cells with pleomorphic nuclei and moderate to abundant cytoplasm. These cells stained immunohistochemically positive for GFAP. A moderate number of cells showed signs of proliferation (Ki-67-positive cells). Also a moderate number of cells were immunopositive for p53. The IDH1 R132H mutation could not be demonstrated by immunohistochemistry. However, this tumor area made up only

5% of the whole section. Concomitant radio-chemotherapy was initiated and this patient died in October 2012.

### 3.2. Review of the literature

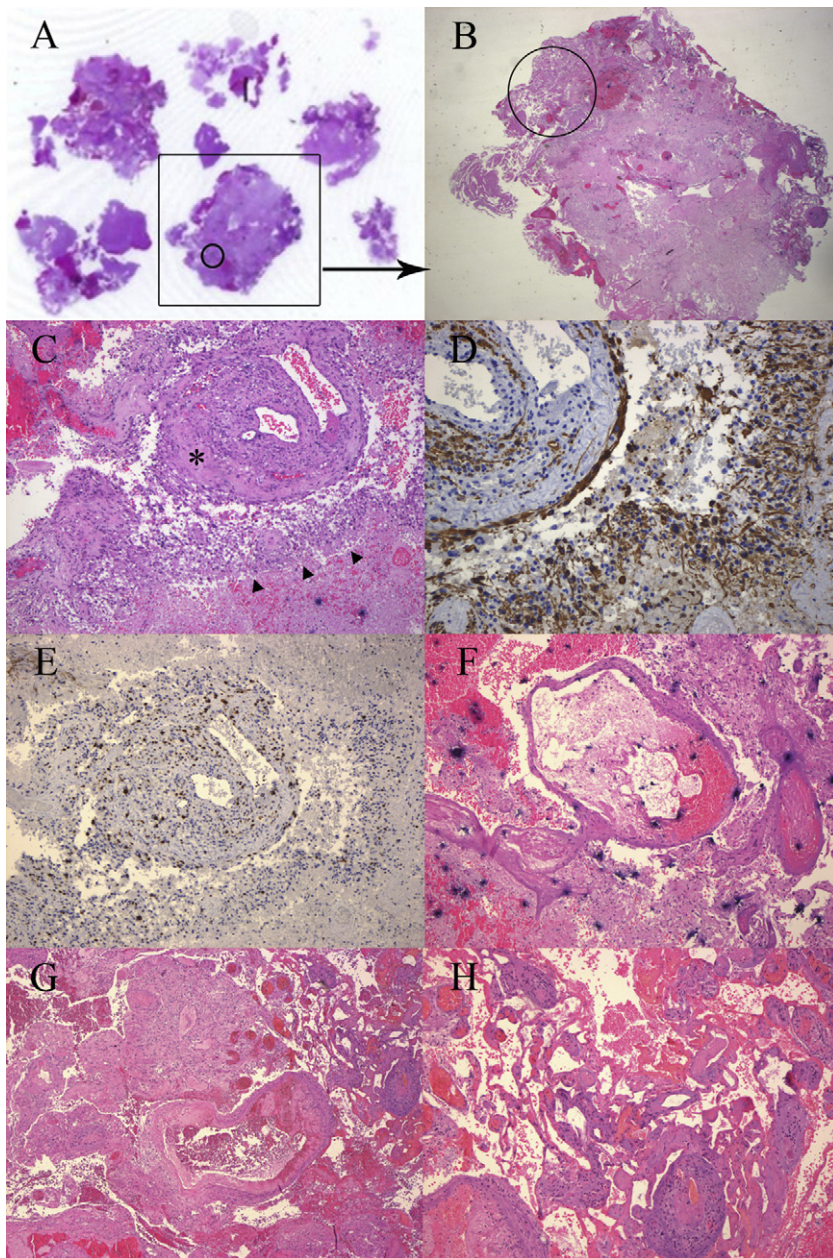
Vascular malformations associated with gliomas are very rare and include venous malformations, cavernous angioma or arteriovenous malformations. Some authors suggested a separate consideration for these highly vascularized tumors and named them “angiogliomas” [2,4,5,9,10,13,16,24]. Historically, the term angioglioma was first introduced by Councilman [5] who described a highly vascularized cerebellar tumor, that is now regarded as the cellular variant of hemangioblastoma [20]. Whereas Bonnin restricted this term for the combination of glioma and capillary hemangioblastoma [2], Lombardi used the designation for AVM-like vascularized low-grade gliomas. Thus, they reported that from 83 oligodendrogliomas and 155 cerebellar-type or supratentorial pilocytic astrocytomas 15 cases were diagnosed as angiogliomas. Interestingly, the clinical prognosis of these vascularized low-grade tumors did not differ from those unassociated with hypervascularity [20]. Other authors regard low-grade gliomas associated with any kind of vascular malformation as angiogliomas [10,16], including AVM-like lesions [20], cavernous angiomas [10], and capillary hemangioblastomas [2] (Table 1).

Coexistence of AVM and glioma remains a rare event documented only by a few case reports which are summarized in Table 2.

**Table 1**

List of reported “angiogliomas” in the literature. Vascular malformation and tumor within the same location.

Author	Cases	Vascular malformation	Tumor histology
Lombardi 1991 [20]	4	AVM-like	Oligodendroglioma
Lombardi 1991 [20]	5	AVM-like	Cerebellar-type pilocytic astrocytoma
Lombardi 1991 [20]	6	AVM-like	Supratentorial pilocytic astrocytoma
Hasegawa 1995 [13]	1	Cavernous angioma	Astrocytoma
Fischer 1982 [9]	1	Cavernous hemangioma	Oligodendroglioma
Fischer 1982 [9]	1	Cavernous hemangioma	Glial neoplasia
Chee 1985 [4]	1	Cavernous angioma	Oligodendroglioma
Gazzeri 2011 [10]	1	Cavernous angioma	Ganglioglioma
Gazzeri 2011 [10]	1	Cavernous angioma	Oligodendroglioma
Palma 1995 [29]	2	Cavernous angioma	Oligodendroglioma
Bonnin 1983 [2]	1	Hemangioblastoma	Anaplastic astrocytoma
Bonnin 1983 [2]	1	Hemangioblastoma	Mixed glioma-oligodendroglioma-astrocytoma-ependymoma
Bonnin 1983 [2]	1	Hemangioblastoma	Reactive peripheral astrocytoma
Matyja 2007 [24]	1	Hemangioblastoma-like	Pilocytic astrocytoma
Kasantikul 1996 [16]	6	Arteriovenous, capillaries, cavernous	Astrocytoma
Kasantikul 1996 [16]	3	Arteriovenous, capillaries	Mixed oligodendroglioma-astrocytoma
Kasantikul 1996 [16]	1	Cavernous, capillaries	Oligodendroglioma



**Fig. 4.** Histomicrographs of the lesion. Scan of the histological section (A). The encircled region shows the area with the suspicious tumor (A and B). (B) The area with the suspicious tumor (H&E stain, magnification 2.5 $\times$ ). (C) Prominent vessel (asterisk) with suspicious tumor area (arrow) (H&E stain, magnification 10 $\times$ ). (D) GFAP-positive cells (magnification 20 $\times$ ). (E) Low number of proliferating cells (immunohistochemistry for Ki67, magnification 10 $\times$ ). (F)–(H) Examples of vascular changes consistent with AVM-like lesion (H&E stain, magnification 10 $\times$ ).

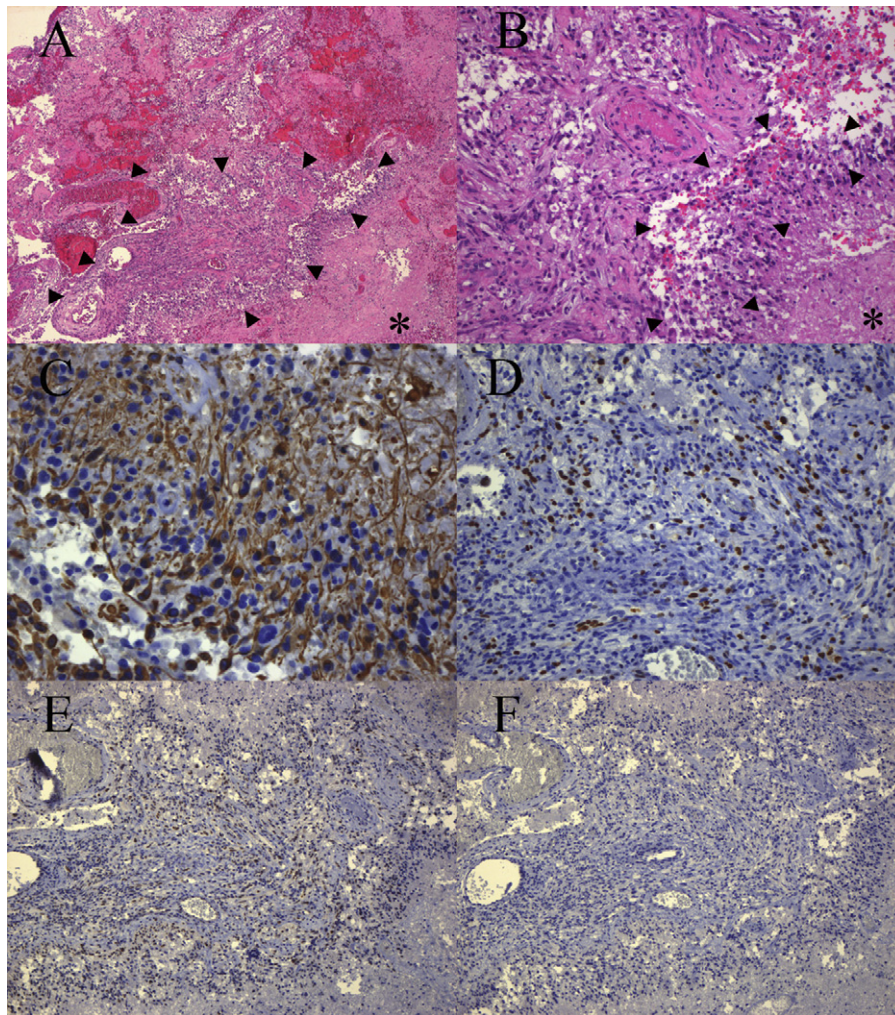
Thus, 18 cases were reported so far, where an AVM was associated with a glioma and included 7 astrocytomas, 4 oligodendrogliomas, 3 glioblastomas, 2 xanthoastrocytomas, 1 high-grade glioma and 1 gliosarcoma.

#### 4. Discussion

We report the case of a 72 year old woman with the histopathological diagnosis of a glioblastoma associated with an AVM-like lesion. Coexistence of AVM and glioma remains a rare event documented only by a few case reports which are summarized in Table 2. Based on the available literature, several hypotheses have been generated: fortuitous separate association [8,14,15,19,23,28,32], combined or sequential lesions [1,3,6,11,12,18,19,22,25,33,34], and a viral origin [9]. Some case reports have documented the

coexistence of separately located but not combined or intermixed lesions [8,14,19,23,28,32] that might represent a fortuitous association.

Furthermore, an AVM and a glioma might be combined presenting as one lesion [1,3,6,12,18,22,25,33,34]. In some cases, preoperative imaging only revealed one lesion whereas intraoperatively and histopathologically the other lesion could be detected [3,6,33]. In a patient with intracranial hemorrhage, an AVM malformation was diagnosed using cerebral angiography; histopathological analysis revealed a glioblastoma [3]. In two cases, preoperative imaging suggested a tumor mass whereas intraoperatively the associated AVM was observed [6,33]. Harris et al. report one case of development of an AVM, documented on serial angiograms, in the setting of a high-grade astrocytoma. The hyperangiogenic stimulus provided by the tumor might have initiated



**Fig. 5.** The tumor after cutting serial sections. (A) Area displaying the tumor (arrows) and necrosis (asterix) (H&E stain, magnification 5 $\times$ ). (B) Higher magnification of the region displayed in (A) displaying the tumor (arrows) and necrosis (asterix) (H&E stain, magnification 20 $\times$ ). (C) GFAP-positive tumor cells (magnification 20 $\times$ ). (D) Proliferating tumor cells (immunohistochemistry for Ki67, magnification 20 $\times$ ). (E) p53 immunopositive cells (magnification 10 $\times$ ). (F) The tumor does not show the IDH1 R132H mutation (magnification 10 $\times$ ).

the development of the AVM [12]. Similarly, McKinney et al. provide evidence about the *de novo* formation of an AVM within an anaplastic oligodendroglioma in a patient with initially negative brain MR and intracranial MR angiography. The subsequent occurrence of a

glioma after the diagnosis of an AVM has even been documented [11,18,19]. Goodkin reports a case, where initially an AVM using cerebral angiography was diagnosed. This lesion regressed and finally disappeared, while in the same period a hypovascular

**Table 2**

AVM and gliomas separate topographical coexistence (sep), AVM and glioma combined in the same location (comb), subsequent occurrence (sequ) of both lesions.

Case	Author	Age/sex	Type	Tumor histology	Radiographic study
1	Fine 1960 [8]	15/m	Sep	Oligodendroglioma	Ventriculogram angiogram
2	Welcker 1966 [32]	45/m	Sep	Astrocytoma	Angiogram
3	Heffner 1971 [14]	17/m	Sep	Astrocytoma	Brain scan, angiogram
4	Ho 1981 [15]	63/f	Sep	Astrocytoma	None
5	Licata 1986 [19]	60/f	Sep	Glioblastoma	CT, angiogram
6	Martinez-Lage 1986 [23]	43/m	Sep	Oligodendroglioma	CT, angiogram
7	Pallud 2009 [28]	35/m	Sep	Mal. pleomorphic xanthoastrocytoma	MRI, angiogram
8	Crowell 1975 [6]	17/m	Comb	Oligodendroglioma	Brain scan, angiogram, ventriculogram
9	Zuccarello 1979 [34]	50/m	Comb	Mal. astrocytoma	EEG, angiogram
10	Malcolm 1991 [22]	41/m	Comb	Astrocytoma	CT, angiogram
11	Harris 2000 [12]	57/m	Comb	Anaplastic astrocytoma	MRI, angiogram
12	Ziyal 2004 [33]	58/m	Comb	High-grade glioma	MRI, postop angiogram
13	McKinney 2008 [25]	55/f	Comb	Anaplastic oligoastrocytoma	MRI, angiogram
14	Cemil 2009 [3]	58/m	Comb	Glioblastoma	CT, angiogram
15	Aucourt 2012 [1]	65/m	Comb	Glioblastoma	MRI, angiogram
16	Licata 1986 [19]	44/m	Sequ	Gliosarcoma	CT, angiogram
17	Lee 1996 [18]	45/m	Sequ	Pleomorphic xanthoastrocytoma	MRI, CT, angiogram
18	Goodkin 1990 [11]	9/f	Sequ	Anaplastic astrocytoma	CT, angiogram

mass, histopathologically diagnosed as an anaplastic astrocytoma, developed at the same site. The authors conclude, that the tumor might have stimulated the AVM [11].

These reports provide evidence, that the vascular malformation might have been induced by the tumor. Enhanced angiogenesis, including vessels of increased diameter with high permeability, thickened basement membranes and highly proliferative endothelial cells mediated by proangiogenic factors overexpressed by the tumor is essential for the diagnosis of high-grade gliomas [27]. AVMs are traditionally considered as congenital lesions, although at least seven reports have documented a *de novo* development. These cases suggest, that inflammatory or ischemic conditions may trigger a *de novo* AVM [21]. Vascular malformations express a distinct pattern of proangiogenic growth factors [17,31], that are even involved in tumor angiogenesis and vascular homeostasis [27]. One of these, vascular endothelial growth factor, is expressed in both AVM and glioblastomas and other gliomas and therefore, proangiogenic growth factors may be the link between these two pathologies [27]. However, especially in the case of Goodkin, where initially an AVM was diagnosed, it could be speculated that the malformation induced the tumor growth [25]. Similarly, there is evidence in case reports, that an anaplastic oligo-astrocytoma [30] or ependymoma [7] occurs after the resection or at the site of a cerebral cavernous malformation. Nazek reports three cases of non-neoplastic oligodendroglial abnormality in AVMs [26]. Similarly, in 1034 AVMs, although no glioma could be diagnosed 8 cases were found in which oligodendroglial cells were increased [20]. Bonnin supports the hypothesis of reactive astrocytoma in the periphery of a capillary hemangioblastoma due to focal neoplastic transformation of the reactive glial cells [2].

## 5. Conclusion

In conclusion, we present an unexceptional case of a glioblastoma surrounded by an AVM-like lesion. Whether this is a combined lesion or represents two pathologies remains unclear. If the term angioglioma should be used as a diagnostic term (entity not listed in the WHO classification 2007), both the glioblastoma and the AVM-like lesion should be located in the same topographical region and appear at the same time. However, especially in cases where radiographic, macroscopic and histological findings are inconclusive, accurate histopathological evaluation is required to avoid misdiagnosis and to initiate appropriate treatment strategies.

## References

- [1] Aucourt J, Jissendi P, Kerdraon O, Baroncini M. Neuroimaging features and pathology of mixed glioblastoma-AVM complex: a case report. *Journal of Neuroradiology*.
- [2] Bonnin JM, Pena CE, Rubinstein LJ. Mixed capillary hemangioblastoma and glioma. A redefinition of the "angioglioma". *Journal of Neuropathology and Experimental Neurology* 1983;42:504–16.
- [3] Cemil B, Tun K, Polat O, Ozen O, Kaptanoglu E. Glioblastoma multiforme mimicking arteriovenous malformation. *Turkish Neurosurgery* 2009;19: 433–6.
- [4] Chee CP, Johnston R, Doyle D, Macpherson P. Oligodendrogloma and cerebral cavernous angioma. Case report. *Journal of Neurosurgery* 1985;62: 145–7.
- [5] Councilman W. The gliomatous tumors of the brain. *Long Island Medical Journal* 1914;8:401–9.
- [6] Crowell RM, DeGirolami U, Sweet WH. Arteriovenous malformation and oligodendrogloma. Case report. *Journal of Neurosurgery* 1975;43:108–11.
- [7] Ehtesham M, Kabos P, Yong WH, Schievink WI, Black KL, Yu JS. Development of an intracranial ependymoma at the site of a pre-existing cavernous malformation. *Surgical Neurology* 2003;60:80–2, discussion 83.
- [8] Fine RD, Paterson A, Gaylor JB. Recurrent attacks of subarachnoid haemorrhage in presence of a cerebral angioma and an intraventricular oligodendrogloma. *Scottish Medical Journal* 1960;5:342–5.
- [9] Fischer EG, Sotrel A, Welch K. Cerebral hemangioma with glial neoplasia (angioglioma?). Report of two cases. *Journal of Neurosurgery* 1982;56:430–4.
- [10] Gazzeri R, De Bonis C, Carotenuto V, Catapano D, d'Angelo V, Galarza M. Association between cavernous angioma and cerebral glioma. Report of two cases and literature review of so-called angiogliomas. *Neurocirugia (Asturias, Spain)* 22:562–566.
- [11] Goodkin R, Zaias B, Michelsen WJ. Arteriovenous malformation and glioma: coexistent or sequential? Case report. *Journal of Neurosurgery* 1990;72:798–805.
- [12] Harris OA, Chang SD, Harris BT, Adler JR. Acquired cerebral arteriovenous malformation induced by an anaplastic astrocytoma: an interesting case. *Neurological Research* 2000;22:473–7.
- [13] Hasegawa H, Bitoh S, Koshino K, Obashi J, Kobayashi Y, Kobayashi M, et al. Mixed cavernous angioma and glioma (angioglioma) in the hypothalamus – case report. *Neurologia Medico-Chirurgica* 1995;35:238–42.
- [14] Heffner Jr RR, Porro RS, Deck MD. Benign astrocytoma associated with arteriovenous malformation. Case report. *Journal of Neurosurgery* 1971;35:229–33.
- [15] Ho KL, Wolfe DE. Concurrence of multiple sclerosis and primary intracranial neoplasms. *Cancer* 1981;47:2913–9.
- [16] Kasantikul V, Shuangshoti S, Panichabongse V, Netsky MG. Combined angioma and glioma (angioglioma). *Journal of Surgical Oncology* 1996;62:15–21.
- [17] Kilic T, Pamir MN, Kullu S, Eren F, Ozek MM, Black PM. Expression of structural proteins and angiogenic factors in cerebrovascular anomalies. *Neurosurgery* 2000;46:1179–91, discussion 1191–1192.
- [18] Lee TT, Landy HJ, Bruce JH. Arteriovenous malformation associated with pleomorphic xanthoastrocytoma. *Acta Neurochirurgica* 1996;138:590–1.
- [19] Licata C, Pasqualin A, Freschini A, Barone G, Da Pian R. Management of associated primary cerebral neoplasms and vascular malformations. 2. Intracranial arterio-venous malformations. *Acta Neurochirurgica* 1986;83:38–46.
- [20] Lombardi D, Scheithauer BW, Piepgras D, Meyer FB, Forbes GS. "Angioglioma" and the arteriovenous malformation-glioma association. *Journal of Neurosurgery* 1991;75: 589–566.
- [21] Mahajan A, Manchandia TC, Gould G, Bulsara KR. De novo arteriovenous malformations: case report and review of the literature. *Neurosurgical Review* 33:115–119.
- [22] Malcolm GP, Symon L, Tan LC, Pires M. Astrocytoma and associated arteriovenous malformation. *Surgical Neurology* 1991;36:59–62.
- [23] Martinez-Lage JF, Poza M, Esteban JA, Sola J. Subarachnoid hemorrhage in the presence of a cerebral arteriovenous malformation and an intraventricular oligodendrogloma: case report. *Neurosurgery* 1986;19:125–8.
- [24] Matyja E, Grajkowska W, Taraszewska A, Marchel A, Bojarski P, Nauman P. Advanced reactive astrogliosis associated with hemangioblastoma versus astroglial-vascular neoplasm ("angioglioma"). *Folia Neuropathologica* 2007;45:120–5.
- [25] McKinney JS, Steineke T, Noehlin D, Brisman JL. De novo formation of large arteriovenous shunting and a vascular nidus mimicking an arteriovenous malformation within an anaplastic oligodendrogloma: treatment with embolization and resection. *Journal of Neurosurgery* 2008;109: 1098–102.
- [26] Nazek M, Mandybur TI, Kashiwagi S. Oligodendroglial proliferative abnormality associated with arteriovenous malformation: report of three cases with review of the literature. *Neurosurgery* 1988;23:781–5.
- [27] Onishi M, Ichikawa T, Kurozumi K, Date I. Angiogenesis and invasion in glioma. *Brain Tumor Pathology* 28:13–24.
- [28] Pallud J, Belaid H, Guillemin R, Vallee JN, Capelle L. Management of associated glioma and arteriovenous malformation – the priority is the glioma. *British Journal of Neurosurgery* 2009;23:197–8.
- [29] Palma L, Mastronardi L, Celli P, d'Addetta R. Cavernous angioma associated with oligo-astrocytoma-like proliferation. Report of two cases and review of the literature with a reappraisal of the term "angioglioma". *Acta Neurochirurgica* 1995;133:169–73.
- [30] Schreuder T, Te Lintelo M, Kubat B, Koehler P. Anaplastic oligo-astrocytoma occurring after resection of a cerebral cavernous malformation; malignant transformation? Case report and review on etiology. *Journal of Neurology* 257:349–353.
- [31] Uranishi R, Baev NI, Ng PY, Kim JH, Awad IA. Expression of endothelial cell angiogenesis receptors in human cerebrovascular malformations. *Neurosurgery* 2001;48:359–67, discussion 367–358.
- [32] Welcker ER, Seidel K. Combination of an arteriovenous aneurysmatic angioma with an astrocytoma. *Deutsche Zeitschrift für Nervenheilkunde* 1966;189:231–9.
- [33] Ziyal IM, Ece K, Bilginer B, Tezel GG, Ozcan OE. A glioma with an arteriovenous malformation: an association or a different entity? *Acta Neurochirurgica* 2004;146:83–6, discussion 86.
- [34] Zuccarello M, Giordano R, Scanarini M, Mingrino S. Malignant astrocytoma associated with arteriovenous malformation. Case report. *Acta Neurochirurgica* 1979;50:305–9.