

Transient amnesic syndromes

Thorsten Bartsch and Christopher Butler

Abstract | Transient amnesic syndromes are striking clinical phenomena that are commonly encountered by physicians in acute medical settings. Diagnosis of such syndromes can be challenging, and their causes have been debated for over 50 years. Critical clinical distinctions, such as between transient global amnesia (TGA) and transient epileptic amnesia (TEA), as well as important clues to the underlying pathophysiology, have recently been revealed. TGA is characterized by the sudden onset of a profound anterograde and retrograde amnesia that lasts for up to 24 h, with neuroimaging after an acute TGA event showing transient perturbation of specific hippocampal circuits that are involved in memory processing. Some cases of transient amnesia are attributable to focal seizure activity and are termed TEA, which has a clinical presentation similar to that of TGA, but can be distinguished from the latter by the brevity and frequency of amnesic attacks. Moreover, TEA carries a risk of persistent memory impairment that can be mistaken for dementia. Here, we summarize clinically relevant aspects of transient amnesic syndromes, giving practical recommendations for diagnosis and patient management. We describe results from imaging and epidemiological studies that have shed light on the functional anatomy and pathophysiological mechanisms underlying these conditions.

Bartsch, T. & Butler, C. *Nat. Rev. Neurol.* advance online publication 8 January 2013; doi:10.1038/nrneurol.2012.264

Introduction

Memory can be thought of as the ability to encode, store and retrieve information. Pathological impairment of memory is termed amnesia, and occurs in association with a variety of neurological conditions that disrupt the brain networks that underpin normal memory function—in particular, the hippocampus, the medial temporal lobe (MTL), the diencephalon, and the pathways that connect these structures. Syndromes of transient amnesia, in which the patient presents with acute onset of dense memory loss, are striking clinical phenomena that present a diagnostic challenge to the physician. The underlying mechanisms of these syndromes have long been a mystery. Recent research, however, has revealed important clinical distinctions as well as new insights into the pathophysiology of transient amnesia.

Human memory can be subdivided behaviourally and anatomically into a number of partially distinct memory systems that rely on local and large-scale brain networks. These networks can be differentially disrupted by a variety of neurological conditions (Figures 1 and 2). Lesions to the networks typically cause an anterograde amnesia, characterized by an inability to learn new consciously accessible—or explicit—information. This deficit is accompanied by retrograde amnesia; that is, difficulty in recalling events that occurred prior to the damage.^{1,2} Retrograde amnesia is often temporally graded, in that remote memories acquired well before the lesion seem to be better preserved than recent memories.

Implicit memory and short-term memory (or working memory) remain seemingly intact,³ as do non-memory cognitive domains such as perception, cognition, general intelligence and praxis.

In this Review, we highlight recent developments in the understanding of transient amnesic syndromes. Through the use of case examples, we emphasize clinical aspects, neuroimaging data and putative underlying mechanisms of these syndromes within a pathophysiological framework.

Neuroanatomy of human memory systems

The encoding, consolidation and retrieval of information in memory is crucially dependent on a large bidirectional network of brain areas that includes neocortical association regions, subcortical nuclei and the MTL, including the hippocampus and parahippocampal cortex (Figure 2).

The hippocampus

The hippocampus is a central node in the memory network, and is the site of pathology in many amnesic syndromes. It receives input from almost all neocortical association regions via the perirhinal and parahippocampal cortices, through the entorhinal cortex.⁴ The anatomy of the hippocampus is of particular importance in the mediation of episodic memory.¹

The hippocampal trisynaptic pathway is the principle feedforward sequential neural circuit involved in the processing of information through the hippocampus (Figure 2a). On a cellular network level, the dentate gyrus receives inputs from the entorhinal cortex via the perforant path. Mossy fibres from the dentate gyrus

Department of Neurology, Memory Disorders Group, University Hospital Schleswig-Holstein, University of Kiel, Schittenhelmstrasse 10, 24105 Kiel, Germany (T. Bartsch). Oxford Clinic for Cognitive Disorders, Nuffield Department of Clinical Neurosciences, University of Oxford, Level 6, West Wing, John Radcliffe Hospital, Oxford OX3 9DU, UK (C. Butler).

Correspondence to: T. Bartsch
t.bartsch@neurologie.uni-kiel.de

Competing interests

T. Bartsch declares associations with the following companies: GlaxoSmithKline, Thieme. See the article online for full details of the relationships. C. Butler declares no competing interests.

Key points

- In patients with transient amnesia, careful assessment of the amnesic deficit is mandatory to identify treatable conditions
- After an acute attack of transient global amnesia (TGA), hippocampal lesions can be detected on MRI, suggesting transient dysfunction of hippocampus-dependent memory circuits
- Transient epileptic amnesia (TEA) can often be distinguished from TGA by the brevity and frequency of the amnesic attacks
- In contrast to TGA, TEA carries a risk of developing persistent memory impairment, which can be mistaken for dementia
- Imaging and neuropsychological data indicate that focal hippocampal pathology occurs in both TGA and TEA
- Psychogenic amnesia typically involves profound retrograde amnesia, often with loss of personal identity, in the context of preserved new learning

project to pyramidal cells in the CA region 3 (CA3), which send Schaffer collaterals to CA1 pyramidal cells. Neurons in the CA1 and CA3 regions also receive direct entorhinal inputs from layers III and II, respectively. Recurrent collaterals in the dentate gyrus and CA3 form reciprocally connected networks. Postsynaptic outputs from the CA1 region project via the subiculum to deep layers of the entorhinal cortex and to various subcortical and cortical areas. Such outputs include monosynaptic projections to prefrontal areas.

Through the use of experimental animal models and, more recently, functional imaging in patients, researchers have sought to correlate components of the hippocampal circuit with distinct cognitive or mnemonic operations.⁵ For example, it has been shown that the dentate gyrus and the CA3 networks are involved in pattern separation—a function that is impaired in ageing and mild cognitive impairment—whereas the CA1 network is engaged in

input integration, novelty and mismatch detection.^{6,7} In accordance with cognitive-map theory, which suggests that allocentric (world-centred) spatial representations of locations are processed in the hippocampus, the CA1 subregion was shown to be involved in our ability to learn a map-like representation of an environment.^{8,9}

The CA1 region has attracted interest in the study of amnesic disorders as it shows a particular vulnerability to a variety of metabolic and excitotoxic insults (such as glutamate overload and calcium influx) caused by hypoxemia, amyloid- β -induced neurotoxicity and ischaemia, which are prominent in acute neurological conditions such as hypoxia–ischaemia, hypoglycaemia, encephalitis and epilepsy.¹⁰ Such vulnerability of the hippocampus explains why transient amnesic episodes often mirror the symptoms of a perturbed hippocampal–neocortical memory system. The basis of such regional susceptibility to insults is poorly understood, but could include genomically determined differences in tolerability to glutamate and distribution of glutamate receptors, as well as in excitatory synaptic transmission.

The clinical correlates of hippocampal dysfunction, and their temporal course and sequelae in humans, have only recently been studied *in vivo* with the use of MRI.^{10,11} A recently proposed hypothesis is that distinct clinical disorders differentially affect hippocampal subregions, which could account for the variety of cognitive deficits observed in amnesic disorders.¹² Experimental models of cellular pathophysiology suggest a descending grade of vulnerability from CA1 to CA3 to dentate gyrus cells.¹⁰ Processes of compensation and neuroplasticity might also determine region-specific susceptibility to metabolic and excitotoxic insults.

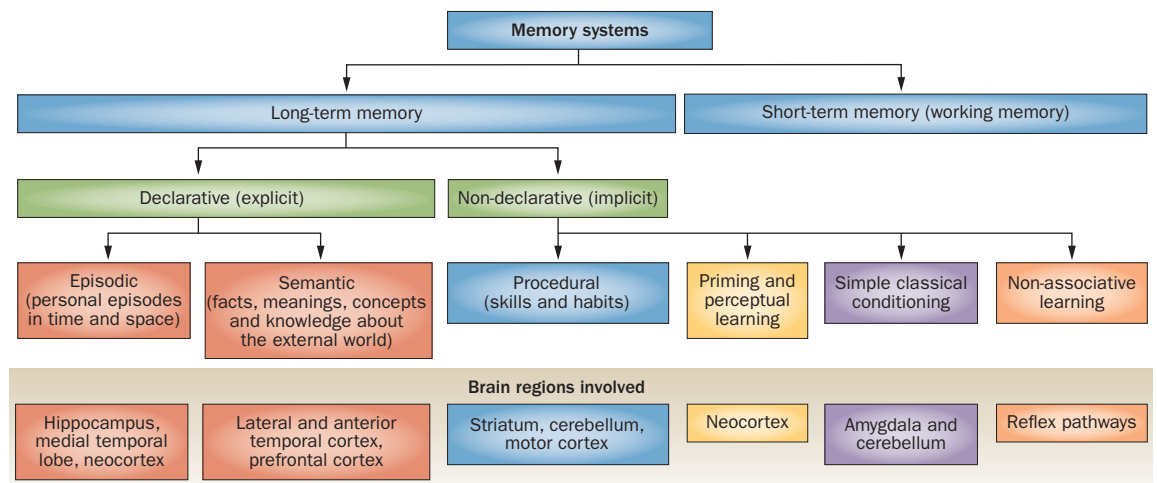
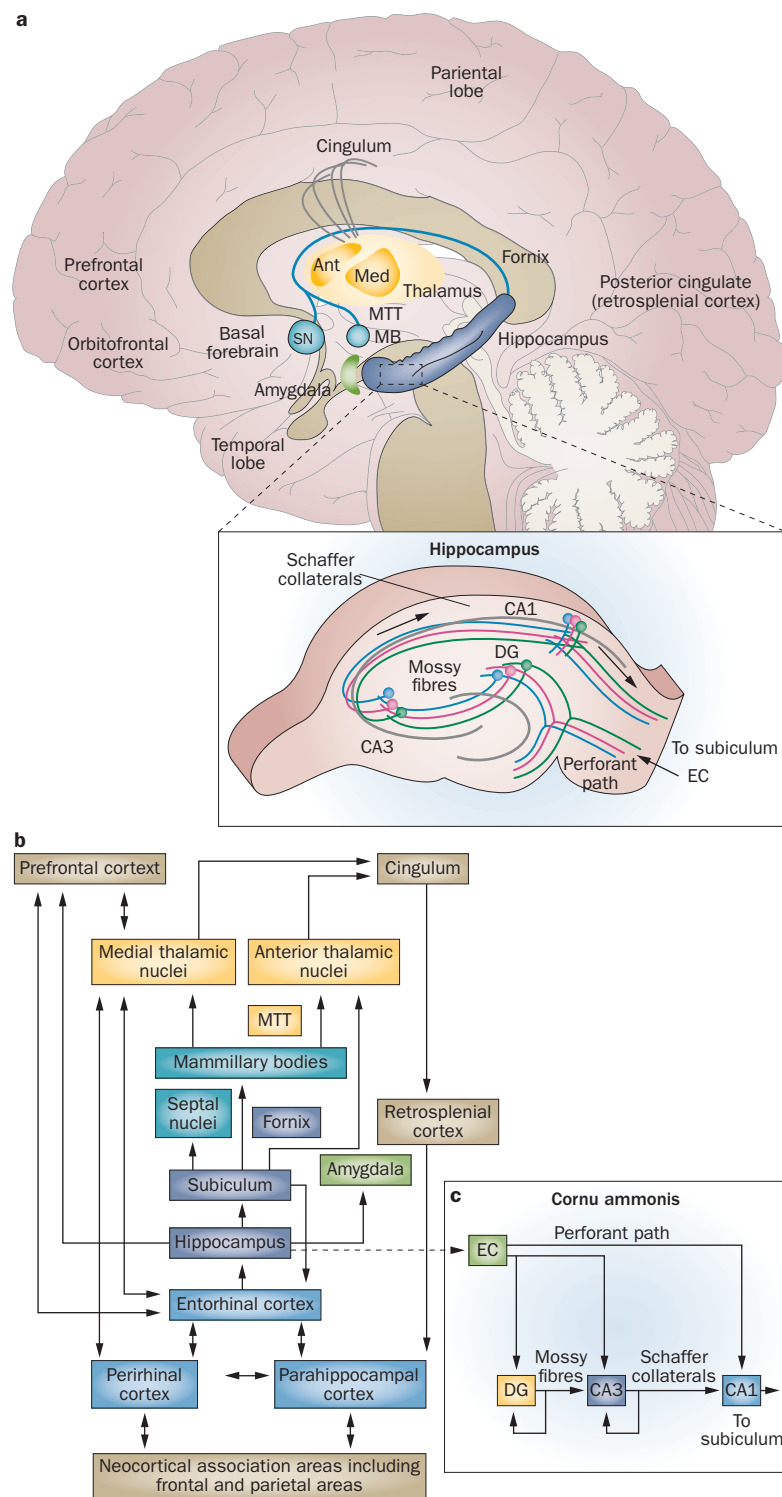


Figure 1 | Classification of memory systems in the human brain. The classic view of memory systems separates memory on a temporal scale (long-term versus working memory). The declarative theory further separates into conscious (explicit) and nonconscious (implicit) memory. Episodic memory represents memory of personal experiences and specific events in time and space that can be explicitly stated and, on a phenomenological basis, can be re-lived. Episodic autobiographical memory is usually regarded as part of episodic memory although it also comprises semantic memory, which includes facts, meanings, concepts and knowledge about the external world and refers to general factual knowledge. The different memory systems, however, are not isolated: they can interact and overlap with each other on a temporal scale (for example, episodic memory transfers into semantic memory over time) and content-wise (procedural learning can be modulated by declarative memory). Notably, alternative concepts of memory have been proposed, such as dual process theory (recollections versus familiarity), multiple trace theory, cognitive map theory and relational theory.

Figure 2 | Memory connectivity. **a** | Schematic drawing of the principal connections between brain regions that support episodic memory, highlighting the connections between the hippocampal system, diencephalic structures and neocortical regions. **b** | Diagrammatic representation of the unidirectional and bidirectional network connectivity of critical structures of the temporal lobe system, diencephalic nuclei and neocortical association areas involved in memory processing. Lesions to this network may differentially affect the functional connectivity and result in memory impairment. **c** | Inset shows the anatomy of the CA, depicting the trisynaptic pathway as the principal feedforward neural circuit involved in the processing of information through the hippocampus. Abbreviations: Ant, anterior thalamic nuclei; CA, cornu ammonis; DG, dentate gyrus; EC, entorhinal cortex; MB, mamillary bodies; Med, medial thalamic nuclei; MTT, mamillothalamic tract (bundle of Vicq d'Azyr); SN, septal nuclei. Parts a and b modified with permission from Macmillan Publishers Ltd © Bird, C.M. & Burgess, N. *Nat. Rev. Neurosci.* **9**, 182–194 (2008) and Moser, E. *Nat. Neurosci.* **14**, 407–408 (2011).



Subcortical circuits

Besides hippocampal–neocortical interactions, subcortical ‘limbic’ circuits are also considered critical for episodic memory and for interactions between different memory systems. Direct parallel projections connect the hippocampus to anterior thalamic nuclei via the mammillary bodies and the mamillothalamic tract and cingulate cortex.² Another pathway—the ventroamygdalofugal pathway—connects the perirhinal cortex, including the amygdala, to the mediodorsal nucleus of the thalamus. Lesions to these projections and this network can produce amnesic states that are similar to MTL amnesia.^{13–15} In particular, damage to the mamillothalamic tract predicts the presence of an amnesic syndrome.^{13,14,16} The exact role of thalamic nuclei in recognition processes in memory and amnesia remains unclear. It has been proposed that damage to the anterior nuclei of the mamillothalamic tract mainly affects recollection, whereas damage to the ventroamygdalofugal pathway and the mediodorsal nucleus particularly affects familiarity, but this distinction remains a matter of debate.²

Functional alterations

Besides structural disruption of brain circuits in neurological diseases, functional alteration in the connectivity dynamics of these interacting network components may also have a role in amnesia. The hippocampus is widely regarded as being at the centre of a brain network that supports communication for encoding, consolidation and retrieval of memory.¹⁷ Mnemonic information is believed to be represented by spatiotemporal patterns of firing in groups of neurons—also referred to as cell assemblies—which involve various fast oscillatory dynamics (such as theta waves, sharp waves, slow oscillations and γ oscillations) that are synchronized and temporally coordinated within and across cortical regions.^{18,19} Breakdown of local and remote network function and connectivity can be observed in Alzheimer

disease, in which cellular pathological changes in CA1 neurons occur early in the course of the disease, and is also seen in global hippocampal damage.^{20,21}

Summary

The results of the studies described above suggest that the basic principles and peculiarities of the memory circuitry—namely, its anatomical projections, vulnerability and temporal firing properties—have important

Box 1 | Diagnostic criteria for transient amnesic syndromes

Transient global amnesia

- Presence of an anterograde amnesia that is witnessed by an observer
- No clouding of consciousness or loss of personal identity
- Cognitive impairment limited to amnesia
- No focal neurological or epileptic signs
- No recent history of head trauma or seizures
- Resolution of symptoms within 24 h
- Mild vegetative symptoms (headache, nausea, dizziness) might be present during the acute phase

Although not included in current diagnostic criteria, temporally graded retrograde amnesia is usually present during an acute attack

Transient epileptic amnesia

- A history of recurrent, witnessed episodes of transient amnesia
- Cognitive functions other than memory judged, by a reliable witness, to be intact during typical episodes
- Evidence for a diagnosis of epilepsy based on one or more of the following: epileptiform abnormalities on EEG, concurrent onset of other clinical features of epilepsy (such as lip smacking or olfactory hallucinations), clear-cut response to anticonvulsant therapy

Box 2 | Differential diagnosis of acute amnesic syndromes

Strategic ischaemic insults in the posterior cerebral circulation

- Often presents with further cognitive signs or neurological deficits
- Somnolence

Intoxication, adverse drug effects

- Sleepy patient
- History of psychotropic medication (antidepressants, neuroleptics, anticholinergics, anxiolytics, sedative-hypnotics)
- Positive toxicology screening

Complex focal seizures, transient epileptic amnesia, postictal conditions

- History of epilepsy, EEG abnormalities

Functional amnesia, psychogenic fugue, dissociative conditions

- Frequently in young patients (<40 years of age) after a traumatic or stressful event
- Selective retrograde amnesia

Exacerbated episode of major depression

- History of depression or signs of depression

Posttraumatic amnesia, head injury

- Signs of head injury

Hypoglycaemia

- Often young patients with type 1 diabetes

Amnesic spell after cerebral angiography, particular in the vertebral arteries

- Peri-interventional evidence

Initial stage of limbic encephalitis

- Subacute onset
- Neurological, behavioural and cognitive signs
- Limbic involvement on MRI

Electroconvulsive therapy

- Recent electroconvulsive therapy
- History of major depression

roles in amnesic states. Although mechanisms of vulnerability have been widely investigated, mechanisms of compensation and reorganization in response to acute perturbation have only recently been begun to be studied.

Transient global amnesia

The classic example of an acute-onset transient amnesic syndrome is transient global amnesia (TGA), which is

characterized by a profound global (both anterograde and retrograde) amnesic episode lasting 2–24 h (Box 1).²² The systematic study of this syndrome was initiated in the middle of the 20th century by Bender, Guyotat and Courjon, and Fisher and Adams, who collected case series to describe the clinical phenotype of TGA, establish a classification system, and find aetiological factors involved in its pathophysiology.^{23–25}

Epidemiology

The yearly incidence of TGA is 3–8 cases per 100,000 people.^{26–29} TGA typically occurs between the ages of 50 and 70 years, and is rare in patients ≤ 40 or ≥ 80 years of age. Recurrence is unusual, but 6–10% of patients with TGA will experience a second or third episode.²⁸

Case example

A 65-year-old woman experienced an episode of amnesia after working hard in the garden for some hours. She began asking repeatedly “where am I?”, “what time is it?” and “why are all these branches lying around?” She appeared helpless, irritated and perplexed but otherwise normal. On examination in the emergency room she was found to be profoundly amnesic, with a retention span of 2–3 min and retrograde amnesia extending 20–30 years into the past. Neurological examination, EEG and cerebrovascular ultrasound were normal. The amnesia resolved over about 7 h, although the patient continued to feel irritable and anxious for some days. MRI of the head 3 days later revealed focal diffusion-weighted imaging (DWI) changes in the CA1 region of the hippocampus.

Clinical presentation

Diagnosis of TGA is based entirely on patient examination and clinical history (Boxes 1 and 2).^{30,31} The main cognitive deficits are in the acquisition of new memories and retrieval of memories for past events. TGA onset is usually heralded by repetitive questioning, often related to attempts at self-orientation such as “what day is it?” or “what am I doing here?” Although some information can be retained for a few seconds, it is rapidly lost when the patient is distracted. The deficit in retrograde memory is variable in its extent: patients are unable to report what they had been doing when the attack began, but may also have lost access to memories of events that occurred many years ago. In this sense, TGA is a classic example of hippocampal amnesia.

Besides amnesia, patients may show mild vegetative symptoms such as headache, nausea and/or dizziness. Subjective complaints of fatigue, irritability or anxiety can persist for some days after the episode. Typically, patients are not aware of the acute amnesia and have no explicit knowledge of their memory failure; thus, they exhibit a certain helplessness, perplexity and anxiety—they ‘feel’ something is wrong but cannot describe it. Such events may cause distress to the patient, and should be adequately dealt with by the physician.^{32,33} Furthermore, a depressed or anxious mood, or altered emotional state, may aggravate memory impairment.³³ After recovery from the acute episode, a dense amnesic

gap for events that occurred during the attack itself can persist.

TGA is often preceded by a period of intense emotional or bodily stress. Frequently reported triggers include sudden immersion in cold or hot water, physical exertion, the receipt of bad news, a heated argument, pain, medical procedures, sexual intercourse, and Valsalva-associated manoeuvres.^{29,34–37} These triggers seem to cluster in different patient groups: in men, the TGA episode occurs more frequently after physical exertion, whereas in women TGA is more typically preceded by emotional distress and is more associated with anxiety traits.²⁸ In patients ≤ 56 years of age, TGA is associated with a past history of migraine.²⁸

Neuropsychology

Formal neuropsychological testing during a TGA attack confirms the clinical impression.^{37–44} Tests of long-term anterograde memory, such as delayed recall of a word list, story or complex figure, reveal dramatically impaired performance. Outcome on tests of retrograde amnesia can be variable, but typically shows a Ribot gradient, with preservation of old memories relative to more-recent ones. The memory deficit in TGA is particularly pronounced with regard to autobiographical memory, and affects the subjective, qualitative experience of remembering that is known as auto-noetic consciousness.⁴⁵ Spatial memory is also severely impaired. In a recent study, patients with acute TGA who were tested in a virtual water maze (an established paradigm for testing hippocampus-dependent spatial and navigational memory) exhibited marked deficits in learning and retrieval of places.⁸ Furthermore, TGA impairs prospective memory; that is, the ability to remember to perform an intended action in the future.⁴⁶ Semantic and implicit memory are usually spared, whereas working memory can be impaired in a subgroup of patients.^{40,47–49}

This neuropsychological profile is typical of patients with impairment of hippocampal function. Additional evidence for involvement of the hippocampus in TGA came from a recent study that found impairment of hippocampus-mediated recollection in patients with TGA, whereas familiarity-based recognition memory, often thought to rely on extrahippocampal structures, was unaffected.⁴³

Cognitive outcome

Clinical recovery from TGA over the course of a few hours is generally favourable, but whether an episode of TGA results in long-lasting but subtle neuropsychological deficits is debated.^{37,40,44} Several early studies suggested that memory impairment could persist for several months after an acute episode of TGA.^{50–58} However, the spectrum and magnitude of these deficits varied considerably between studies. A high rate of mood disorders was reported in patients with TGA who were examined several months after the episode.⁵⁹ Such postictal anxiety or depressive symptoms might correlate with subjective memory complaints.⁵⁸ Other studies, however, found no evidence of persistent cognitive

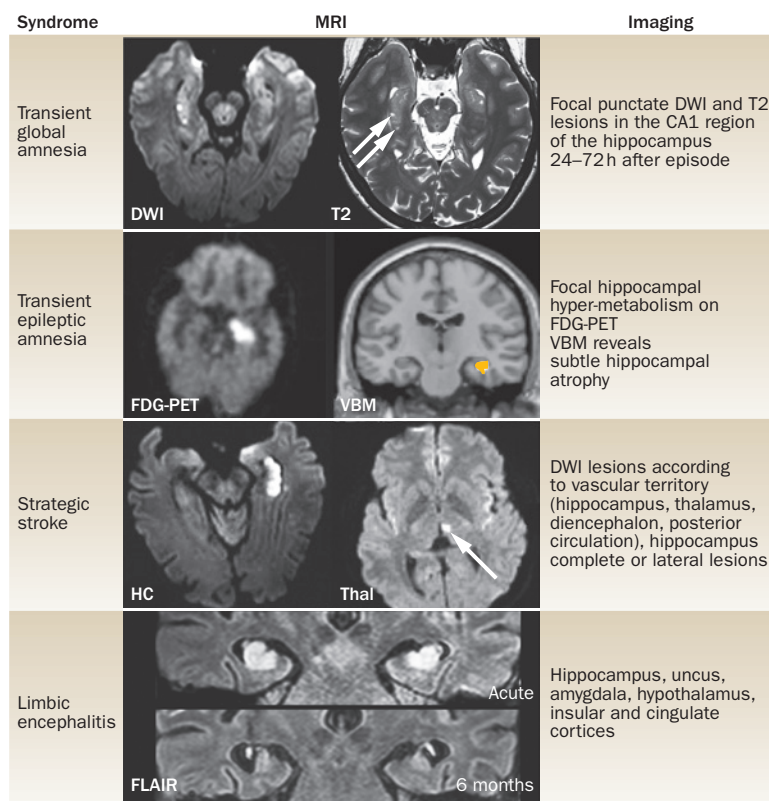


Figure 3 | Neuroimaging findings in amnesic syndromes. Abbreviations: DWI, diffusion-weighted imaging; FDG-PET, ¹⁸F-fluorodeoxyglucose PET; FLAIR, fluid-attenuated inversion recovery; HC, hippocampus; T2, T2 weighted MRI; Thal, thalamus; VBM, voxel based morphometry. Images courtesy of O. Jansen, Department of Neuroradiology, University Hospital Kiel, Germany.

impairment after TGA.⁶⁰ In a meta-analysis of 25 studies, no significant long-term performance differences were found between patients with TGA and healthy controls.⁴⁴ Another study, which compared patients with and without hippocampal CA1 lesions on MRI in the acute setting, also found no significant effect of TGA on long-term cognitive outcome.⁶¹

Neuroimaging

For many years, neuroimaging failed to reveal any structural abnormality in patients with TGA. Recent work, however, using high-resolution MRI, has consistently revealed that the acute stage is associated with highly focal lesions in the CA1 field of the hippocampus (Figure 3).^{62–65} These lesions, which are evident on both DWI and T2-weighted MRI sequences, are best detected 2–3 days after the episode^{66–69} and usually disappear within 14 days. Long-term follow-up MRI reveals no structural sequelae 4–6 months after the acute attack.^{22,66,70,71} Combined ¹⁸F-fluorodeoxyglucose PET (FDG-PET) and MRI in one case of acute TGA revealed left hippocampal hypometabolism in the acute stage, with a typical focal DWI lesion in CA1 visible 48 h later.⁷² Functional disruption of hippocampal CA1 neurons was confirmed by the presence of lactate, a marker of metabolic stress, which was detected in these lesions by means of magnetic resonance spectroscopy.⁷³

Hippocampal CA1 neurons are known to have a critical role in memory formation and consolidation. It has been proposed, therefore, that the lesions seen in TGA are directly related to the amnesic deficit and reflect a focal, transient perturbation of CA1-dependent hippocampal circuits.^{8,45} The highly selective nature of this damage is probably attributable to the vulnerability of CA1 neurons to metabolic and oxidative stress (as discussed above).⁷⁴ One could speculate that mood manifestations of TGA are a correlate of the various functional roles of the hippocampus, which go beyond cognitive processes. For example, a recent suggestion is that the dorsal hippocampus has a role in the cognitive processes of learning and memory, whereas the ventral hippocampus is involved in the regulation of emotional and motivational behaviour, and an intermediate zone integrates cognitive and spatial processing into behaviourally relevant actions.^{75,76} The precise pathophysiological pathways leading to TGA remain unknown, but several possibilities—including migraine-related mechanisms, hypoxic–ischaemic events, venous flow abnormalities, psychological factors and epileptic activity—have been suggested.^{22,35,66,77,78}

Transient epileptic amnesia

It has been known for over a century that episodes of isolated memory impairment may be the sole or main manifestation of epileptic seizures. In 1888, the British neurologist John Hughlings Jackson reported the case of Dr Z, a physician with focal epilepsy who, while at work, experienced the onset of his typical epileptic aura. The doctor subsequently examined, diagnosed and treated a child with pneumonia, yet afterwards had no recollection of the consultation. Some years later, the physician's brain came to autopsy, and a single, circumscribed lesion in the left uncus was discovered.⁷⁹ Over subsequent decades, a steady flow of case reports and short series of patients with epileptic amnesia have appeared in the literature,^{80–82} with many of these cases initially classified as TGA. Hodges and Warlow's diagnostic criteria for TGA strive to exclude cases of epilepsy (Box 1) but, nevertheless, even in these authors' own, carefully screened series of 114 TGA cases, a small proportion (7%) went on to develop clear-cut seizures.³¹ The term 'transient epileptic amnesia' was introduced in the early 1990s by Kapur, who highlighted that amnesic attacks caused by epilepsy can be similar to those occurring in TGA, but are usually distinguished by features including brevity and recurrence (Box 2).^{54,80,83} In 1998, Zeman and colleagues proposed diagnostic criteria for TEA that have become widely used (Box 1).^{84,85}

Epidemiology

The prevalence of TEA is unknown. Similar to TGA, amnesic attacks in TEA typically begin in late middle age, with a mean age of onset of 57 years. For reasons that are not clear, two-thirds of reported patients with TEA are male.⁸¹

Case example

A 55-year-old mathematics teacher vaguely recalled his six witnessed episodes of amnesia, three of which

occurred on waking and one while he was driving. His wife confirmed that on each occasion he would repeatedly ask "where am I? What day is it? Am I going to work today?" and try to piece his memory back together over about 30 min while continuing with other activities. MRI was normal. EEG revealed epileptiform abnormalities over the left hemisphere and the attacks ceased on treatment with lamotrigine. He described a dense but patchy loss of autobiographical memories from the past 25 years, including his first holiday abroad, his daughter's wedding, and his silver wedding anniversary. He had also developed pronounced difficulties with route-finding, even in familiar environments.

Clinical presentation

The clinical features of 94 published cases of TEA, including a series of 50 patients from the UK, have recently been reviewed⁸¹ to assess features of this disorder. Episodes of amnesia during TEA are generally briefer than those of TGA, lasting a median of 30–60 min. As with most forms of epilepsy, the frequency of attacks is highly variable but, on average, they occur about once per month—a pattern that is very different from TGA. A third clue to indicate a diagnosis of TEA is that episodes characteristically occur on waking, with around 70% of patients experiencing at least one attack in this context. During the amnesic episode, patients often have difficulty laying down new memories (anterograde amnesia) and retrieving memories for past events (retrograde amnesia). In contrast to TGA, the anterograde component is often partial: 44% of patients later say they can "remember not having been able to remember."⁸¹ Patients may repetitively ask questions during the attack, but this feature is less consistent in TEA than in TGA. Activities such as conversing, dressing, eating, or even driving, are often carried out without difficulty, indicating that cognitive domains other than memory are preserved.

Amnesia is the predominant feature of TEA attacks, but careful inquiry can, in some instances, reveal other signs that are suggestive of epilepsy. The most common of these signs is olfactory or gustatory hallucinosis, experienced by up to 50% of patients with TEA.⁸¹ Subtle oral automatisms (lip smacking or chewing) or brief periods of unresponsiveness can also accompany some attacks. A few patients develop clear-cut 'complex partial seizures', but generalized tonic–clonic convulsions are rare.⁸⁶ Routine interictal EEG recording reveals epileptiform abnormalities in about one-third of cases of TEA, although the sensitivity of EEG to detect abnormalities can be enhanced in patients following sleep deprivation (Figure 4a). Thus, although an EEG may be helpful in the evaluation of a patient with transient amnesia (especially when there have been multiple episodes), a 'normal' result does not rule out TEA.⁸⁷ When identified, epileptiform discharges typically localize to the temporal regions.⁸⁵

Neuropsychology

To date, no systematic study of the neuropsychological profile during TEA attacks has been performed. In contrast to TGA, however, TEA is associated with marked

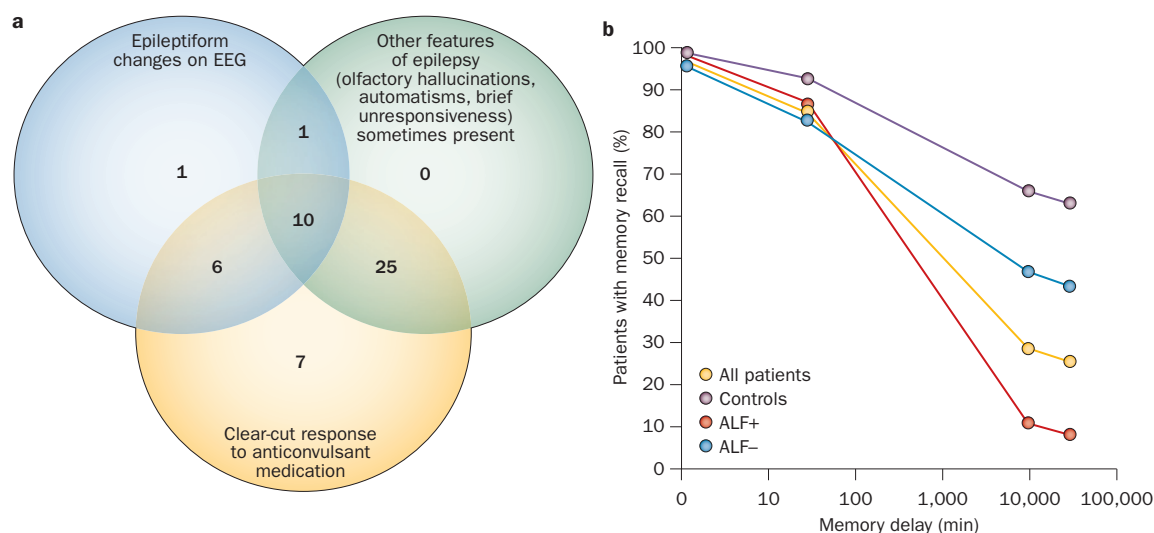


Figure 4 | Transient epileptic amnesia—diagnostic criteria and outcomes. **a** | Illustration of the different diagnostic criteria, including of the numeric distribution of patients fulfilling the diagnostic criteria for epilepsy, used in a large sample study. **b** | ALF in transient global amnesia: ALF+ indicates patients who complain of ALF; ALF– indicates patients who do not complain of ALF. Abbreviation: ALF, accelerated long-term forgetting. Reprinted with permission from John Wiley & Sons © Butler, C. R. *et al. Ann. Neurol.* **61**, 587–598 (2007).

persistent (interictal) cognitive impairment. Despite effective treatment of amnesic episodes, 81% of patients with TEA complain of substantial ongoing memory difficulties.⁸⁵ The problems described are unusual: 70% report loss of memories for salient, personally experienced events from the remote past (autobiographical amnesia); 44% describe the excessively rapid fading of newly acquired memories over a period of days to weeks (accelerated long-term forgetting [ALF]); and 36% report new difficulties with spatial navigation (topographical amnesia), even around previously familiar environments (Figure 4b).⁸⁸

Performance on standard neuropsychological instruments, which typically test retention of newly learned material after a delay of up to 30 min, is often normal in TEA. Experimental tests, however, have revealed that patients with TEA have marked deficits of autobiographical memory, particularly affecting the recollection of episodic detail.^{85,89} These deficits may affect memories for events that occurred many decades prior to the clinical onset of seizures, suggesting that TEA can disrupt well-established memory traces. Complaints of ALF have also been corroborated through the use of objective testing, which demonstrates that, although patients learn and initially retain information normally, they forget this information at an abnormally rapid rate over the following days (Figure 4b).^{85,90} This pattern suggests a specific and novel impairment of memory consolidation in TEA.⁹¹

Neither ALF nor autobiographical amnesia is exclusive to TEA as both have been described in association with other forms of epilepsy.^{92–95} Indeed, profound interictal memory deficits (rather than seizures) may, on occasion, be the principal symptom that leads the patient to seek medical help. This clinical presentation has been termed the ‘epileptic amnesic syndrome.’⁶³ The causes of ALF and autobiographical amnesia are unknown, but

possibilities include subtle structural damage to the brain or physiological disruption of memory circuits owing to seizure-related activity.

Neuroimaging

MRI of the brain in patients with TEA is usually clinically unremarkable. Volumetric MRI analysis has revealed subtle atrophy (8% volume reduction) bilaterally in the hippocampus of patients with TEA (Figure 3).⁹⁶ The degree of hippocampal volume atrophy correlates with performance on standard neuropsychological tests of memory in TEA patients, but does not explain the presence of ALF or autobiographical amnesia.⁹⁶

Pathophysiology

Several clinical features of TEA—namely, the mixed anterograde and retrograde amnesia, associated olfactory hallucinations, and the localization of epileptiform abnormalities on scalp EEG—point to the medial temporal lobes as the seizure source. In one reported case, peri-ictal scanning with FDG-PET revealed focal hypermetabolism in the left hippocampus, which resolved after successful treatment of the seizures (Figure 3).⁹⁵ Furthermore, in a series of 50 patients with TEA, a bilateral, localized, but subtle loss of volume was observed in the medial temporal lobes.⁹⁶ 10 published case reports of TEA have included EEG data gathered during an amnesic attack;⁸¹ six found amnesia to be an ictal phenomenon, whereas in four it was found to be postictal. Ictal epileptiform EEG changes were bilateral in eight of the 10 patients. Interictal epileptiform abnormalities, when present, tend to be bilateral: 56% are bilateral, 32% are left-sided, and 12% are right-sided.⁸¹

Treatment

Current evidence suggests that TEA attacks can be managed with anticonvulsant medication, and often resolve

completely following monotherapy.⁸⁵ However, treatment is often delayed owing to misdiagnosis of patients as having TGA, psychogenic attacks or dementia. Whether persistent memory impairments (including ALF, autobiographical amnesia or topographical amnesia) also respond to, or can be prevented with, antiepileptic drugs is unclear. One case report of TEA suggests that treatment is associated with some memory improvement.⁹⁷ Nevertheless, for some patients persistent memory problems remain even once the amnesic attacks have ceased.⁹⁸ In many countries, patients diagnosed with TEA are banned from driving until they have been free of attacks for 1 year.

Psychogenic amnesic states

Cases of transient amnesia straddle the border between psychiatry and neurology, and highlight how artificial and misleading the traditional distinction between these two disciplines can be. As discussed above, TGA—generally thought of as a neurological condition with hints of ‘organic pathology’ in the medial temporal lobes—can be triggered by psychological stressors, and may be more common among people with pathological personality traits or a history of anxiety or depressive disorder.²⁸ For other instances of transient amnesia in which no obvious neuropathological cause exists, the disorder may be explained in purely psychological terms. Such cases are variably termed ‘psychogenic amnesia’ (our preference), ‘functional amnesia’, ‘dissociative amnesia’ or ‘hysterical amnesia’.

According to Kopelman,⁹⁹ psychogenic amnesia can be divided into two main subtypes; namely, situation-specific psychogenic amnesia and global psychogenic amnesia. In the former, a temporally circumscribed amnesia is associated with a specific and usually emotionally charged event, such as a criminal offence. The degree of amnesia is proportional to the violence of the offence, and up to 30% of convicted homicide cases have amnesia claimed at trial.¹⁰⁰ Global psychogenic amnesia (or mnestic block syndrome¹⁰¹) is not restricted to a single event but involves memory loss for a large swathe of the past and even loss of the patient’s own identity. This type of amnesia looms large in the public imagination and is beloved by Hollywood screenwriters.

Epidemiology

The incidence of psychogenic amnesia is unknown, but it seems to be much less common than TGA or TEA.¹⁰² Psychogenic amnesias also tend to affect young people, being more commonly reported in the third and fourth decade of life.^{103–107}

Case example

A 53-year-old salesman was found wandering in a forest by police, having been reported missing by his family. On assessment in hospital, he was found to have “a complete loss of memory,” unable to recall any events from his past. He could not remember his own name and failed to recognize family members including his daughter, with whom he had a bitter row that morning. In stark

contrast, he had no difficulty in retaining new information such as the names of the medical staff attending him. Routine investigations, including MRI of the brain, were normal. It later emerged that, over the past few months, he had amassed extensive financial debt as a result of failed investments, and had been drinking heavily. Little improvement in his memory was observed over a 5-year follow-up period.

Clinical presentation

The onset of psychogenic amnesia typically follows a stressful experience, such as a marital or financial crisis, and there is often a background of depression or alcohol abuse.¹⁰⁶ Psychogenic amnesia is thought to be linked to a history of nonpsychogenic, or ‘organic’, transient amnesia.¹⁰⁸ Knowledge of personal identity is often impaired—a feature not observed in organic amnesia. A period of wandering or ‘psychogenic fugue’ may occur, lasting for a few hours to days. Patients have a profound inability to recall information acquired prior to the onset of amnesia, but anterograde memory is comparatively preserved so that they are able to ‘relearn’ about themselves. Such focal retrograde amnesia is often held as the hallmark of psychogenic amnesia, but this characteristic has also been reported in association with neurological conditions, including TEA (Figure 5).^{91,108–110} Some patients with psychogenic amnesia have neurobehavioural abnormalities such as functional limb weakness, loss of ability to read and write, or difficulty using common devices such as a telephone.¹⁰² There may be a suspicion of secondary gain in some patients;¹¹¹ however, to try and untangle conscious and nonconscious mechanisms underlying the amnesic event is usually fruitless, except in rare cases when the patient later confesses to having intentionally deceived.

Neuropsychology

The pattern of performance on neuropsychological testing varies considerably in patients with psychogenic amnesia. In general, anterograde memory is preserved, although some individuals may score lower on testing than would be expected by their ability to remember day-to-day events.^{106,111,112} By contrast, retrograde memory both for personal and public events, as well as factual knowledge (for example, of famous people or television programmes), is strikingly impaired, often across the lifespan. Despite this perceived loss of retrograde memory, patients might demonstrate implicit use of ‘forgotten’ information when tested indirectly.^{106,111} Beyond the memory domain, patients may also demonstrate impairment on tests of attention and executive function—a finding that has been attributed to ‘persistent stress’ by some researchers.¹¹¹

Neuroimaging

Psychogenic amnesia, by definition, is not associated with structural brain damage to which the memory impairment can be attributed. However, FDG-PET imaging in single cases and in one sample of 14 patients with psychogenic amnesia revealed a region of hypometabolism

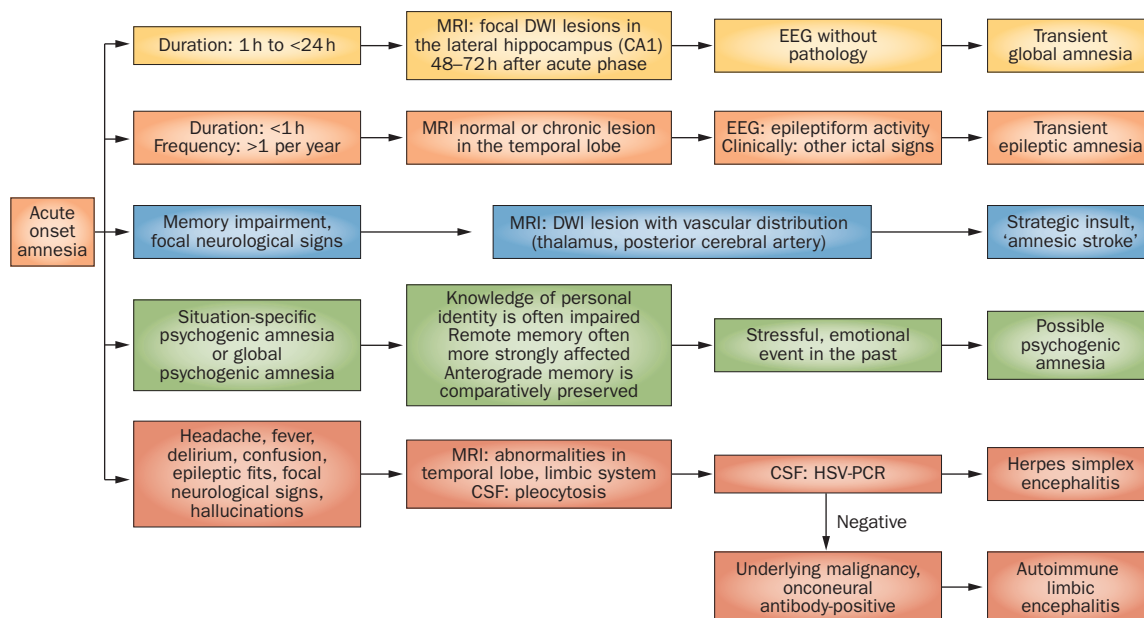


Figure 5 | Diagnostic pathways in patients with acute memory loss. Abbreviations: CSF, cerebrospinal fluid; DWI, diffusion-weighted imaging; HSV, herpes simplex virus.

in the right prefrontal cortex.¹¹³ Whether functional changes in this brain region are causally related to the amnesia has not yet been established. Notably, however, focal damage to the right prefrontal cortex has been reported to cause focal retrograde amnesia for autobiographical events.¹¹⁴

Treatment

Memory impairment in psychogenic amnesia has classically been regarded as reversible, with early studies reporting good recovery within a month from the onset of amnesia.^{103,115} More-recent studies that employed extensive neuropsychological testing, however, showed only protracted and incomplete recovery in many cases.^{106,116} No data exist on the efficacy or otherwise of behavioural or pharmaceutical interventions for psychogenic amnesia.

Other causes of transient amnesia

Hippocampal stroke

The hippocampal region is very sensitive to ischaemic damage. In the 1970s, Benson *et al.* coined the term 'amnesic stroke' to describe patients with memory impairment after experiencing a stroke.¹¹⁷ Several case series have since confirmed that posterior cerebral artery strokes, which involve the hippocampus, can lead to transient amnesia.^{117–122} Hippocampal stroke may mimic the amnesic deficit observed in TGA,¹²³ but the amnesia is often accompanied by other signs, such as hemianopia, owing to more-widespread infarction.¹²⁴ Szabo *et al.* identified four distinct anatomical patterns of hippocampal infarction that each correspond to distinct arterial territories: complete; lateral (selective CA1 damage); partial (either posterior or anterior regions of the hippocampus); and small focal lesions.^{121,122}

Diencephalic amnesia

Damage to the anterior and medial thalamic nuclei can cause memory impairment that is broadly similar to hippocampal amnesia in that episodic memory is most severely affected while working and implicit memory seems to be spared.^{2,15,125} However, amnesia caused by such damage is often accompanied by dysexecutive and behavioural symptoms such as reduced verbal fluency, apathy and dysphoria.¹²⁶ The two commonest causes of diencephalic amnesia are thalamic stroke and Korsakoff syndrome—a subacute neurological syndrome resulting from vitamin B₁ deficiency that leads to diencephalic lesions involving the medial thalamus, periventricular region of the third ventricle, periaqueductal area, mammillary bodies, midbrain tectum and fornix. The anterior and medial thalamic nuclei and the mamillothalamic tract are supplied by the anterior choroidal, tuberothalamic artery and paramedian arteries, respectively. Lacunar infarcts of these vascular territories, particularly if they are left-sided, can lead to acute impairments of anterograde and retrograde episodic memory (Figure 3). Damage to the basal forebrain (often with additional involvement of the orbitofrontal cortex) leads to basal forebrain amnesia as a result of rupture of an anterior communicating artery aneurysm, and can result in a profound anterograde memory impairment that is frequently accompanied by executive deficits and confabulations.¹²⁷

Limbic encephalitis

The limbic system, including the hippocampus, can be specifically targeted by infectious agents such as herpes simplex virus, or by inflammatory conditions (Figure 3). Recent interest has focused on autoimmune limbic encephalitis. Although not directly classified as a classic transient amnesic syndrome, patients with

these syndromes can present with subacute episodic memory disturbance and epileptic seizures, sometimes accompanied by various neuropsychiatric symptoms, such as disorientation, confusion, and behavioural abnormalities. Paraneoplastic limbic encephalitis is associated with the presence of classic onconeural antibodies, such as anti-Hu, anti-Ma2 (or anti-Ta), anti-CV2 (or anti-CRMP5) and anti-neuronal nuclear antibody type 3, and can be detected in some patients with cancers of the lung, thymus, breast or testes.¹²⁸ In nonparaneoplastic limbic encephalitis, autoantibodies can be found that attack neuronal surface antigens, such as proteins associated with the voltage-gated potassium channel complex (leucine-rich glioma inactivated 1 and contactin-associated protein 2), glutamic acid decarboxylase, and receptors for the neurotransmitters NMDA, AMPA and GABA_B.^{129,130} MRI may reveal signal abnormalities in limbic structures involved in memory processing (such as the hippocampus, amygdala, hypothalamus, and insular and cingulate cortices), with the hippocampus being the predominantly affected structure (Figure 3).^{131,132} A favourable treatment response and outcome is dependent on early and aggressive immunotherapy.^{130,133} In a number of patients, however, the acute phase is complicated by a relapsing disease course followed by permanent amnesia with atrophy due to neuronal loss in the hippocampus (Figure 3).^{131,132}

Conclusions

Human memory systems rely on a number of local and large-scale brain networks, the activity of which can be affected in various neurological conditions. In particular,

connections between the temporal lobe system, neocortical areas and medial diencephalic structures are crucial for the formation of episodic memory. Lesions to either region elicit a profound amnesic state. Recent neuroimaging findings suggest that a transient perturbation of hippocampal function is the correlate of transient global amnesia, as focal lesions in the CA1 region can be reliably detected on DWI. The maximum detectability of these lesions is at 24–72 h after onset of symptoms. If a patient has repetitive, brief amnesic episodes, the diagnosis of transient epileptic amnesia should be considered. Antiepileptic drugs are highly effective in treating the amnesic attacks, but unusual interictal memory deficits may persist. Both TGA and TEA need to be distinguished from psychogenic amnesia, in which retrograde memory loss usually occurs in the presence of normal anterograde memory. Further studies should focus on the mechanisms of regional susceptibility within memory networks to acute insults, neurodegeneration and age-related changes, and explore the potential role of hippocampal plasticity in the rehabilitation of patients with memory disorders.

Review criteria

Full-text papers and abstracts were selected for this Review using the PubMed database. Search terms were “amnesia” and “memory disorders”, either alone or in combination with one of the following terms: “epilepsy”, “hippocampus”, “global amnesia”, “memory impairments” and “transient”. Publications in all years were considered. Reference lists of identified papers were also searched for further relevant publications.

1. Bird, C. M. & Burgess, N. The hippocampus and memory: insights from spatial processing. *Nat. Rev. Neurosci.* **9**, 182–194 (2008).
2. Aggleton, J. P. *et al.* Hippocampal-anterior thalamic pathways for memory: uncovering a network of direct and indirect actions. *Eur. J. Neurosci.* **31**, 2292–2307 (2010).
3. Dickerson, B. C. & Eichenbaum, H. The episodic memory system: neurocircuitry and disorders. *Neuropsychopharmacology* **35**, 86–104 (2009).
4. van Strien, N. M., Cappaert, N. L. & Witter, M. P. The anatomy of memory: an interactive overview of the parahippocampal-hippocampal network. *Nat. Rev. Neurosci.* **10**, 272–282 (2009).
5. Lisman, J. E. Relating hippocampal circuitry to function: recall of memory sequences by reciprocal dentate–CA3 interactions. *Neuron* **22**, 233–242 (1999).
6. Brock Kirwan, C. *et al.* Pattern separation deficits following damage to the hippocampus. *Neuropsychologia* **50**, 2408–2414 (2012).
7. Duncan, K., Ketz, N., Inati, S. J. & Davachi, L. Evidence for area CA1 as a match/mismatch detector: a high-resolution fMRI study of the human hippocampus. *Hippocampus* **22**, 389–398 (2012).
8. Bartsch, T. *et al.* Focal lesions of human hippocampal CA1 neurons in transient global amnesia impair place memory. *Science* **328**, 1412–1415 (2010).
9. Suthana, N. A., Ekstrom, A. D., Moshirvaziri, S., Knowlton, B. & Bookheimer, S. Y. Human hippocampal CA1 involvement during allocentric encoding of spatial information. *J. Neurosci.* **29**, 10512–10519 (2009).
10. Michaelis, E. in *The Clinical Neurobiology of the Hippocampus* (ed. Bartsch, T.) 54–76 (Oxford University Press, Oxford, 2012).
11. Bartsch, T. in *The Clinical Neurobiology of the Hippocampus* (ed. Bartsch, T.) 200–222 (Oxford University Press, Oxford, 2012).
12. Small, S. A., Schobel, S. A., Buxton, R. B., Witter, M. P. & Barnes, C. A. A pathophysiological framework of hippocampal dysfunction in ageing and disease. *Nat. Rev. Neurosci.* **12**, 585–601 (2011).
13. Van der Werf, Y. D., Jolles, J., Witter, M. P. & Uylings, H. B. Contributions of thalamic nuclei to declarative memory functioning. *Cortex* **39**, 1047–1062 (2003).
14. Van der Werf, Y. D., Witter, M. P., Uylings, H. B. & Jolles, J. Neuropsychology of infarctions in the thalamus: a review. *Neuropsychologia* **38**, 613–627 (2000).
15. Carlesimo, G. A., Lombardi, M. G. & Caltagirone, C. Vascular thalamic amnesia: a reappraisal. *Neuropsychologia* **49**, 777–789 (2011).
16. Josseume, T. *et al.* Acute anterograde amnesia by infarction of the mamillothalamic tracts. *J. Neuroradiol* **34**, 59–62 (2007).
17. Battaglia, F. P., Benchenane, K., Sirota, A., Pennartz, C. M. & Wiener, S. I. The hippocampus: hub of brain network communication for memory. *Trends Cogn. Sci.* **15**, 310–318 (2011).
18. Sirota, A. *et al.* Entrainment of neocortical neurons and gamma oscillations by the hippocampal theta rhythm. *Neuron* **60**, 683–697 (2008).
19. Buzsaki, G. Neural syntax: cell assemblies, synapse ensembles, and readers. *Neuron* **68**, 362–385 (2010).
20. Dickerson, B. C. & Sperling, R. A. Large-scale functional brain network abnormalities in Alzheimer’s disease: insights from functional neuroimaging. *Behav. Neurol.* **21**, 63–75 (2009).
21. Campo, P. *et al.* Remote effects of hippocampal sclerosis on effective connectivity during working memory encoding: a case of connective diaschisis? *Cereb. Cortex* **22**, 1225–1236 (2012).
22. Bartsch, T. & Deuschl, G. Transient global amnesia: functional anatomy and clinical implications. *Lancet Neurol.* **9**, 205–214 (2010).
23. Bender, M. B. Syndrome of isolated episode of confusion with amnesia. *J. Hillside Hospital* **5**, 212–215 (1956).
24. Fisher, C. M. & Adams, R. D. Transient global amnesia. *Acta Neurol. Scand.* **40** (Suppl. 9), 1–83 (1964).
25. Guyotat, M. & Courjon, J. Les ictus amnésiques [French]. *J. Med. Lyon* **37**, 697–701 (1956).
26. Miller, J. W., Petersen, R. C., Metter, E. J., Millikan, C. H. & Yanagihara, T. Transient global amnesia: clinical characteristics and prognosis. *Neurology* **37**, 733–737 (1987).
27. Hodges, J. R. & Warlow, C. P. The aetiology of transient global amnesia. A case-control study of 114 cases with prospective follow-up. *Brain* **113**, 639–657 (1990).

28. Quinette, P. *et al.* What does transient global amnesia really mean? Review of the literature and thorough study of 142 cases. *Brain* **129**, 1640–1658 (2006).
29. Berli, R., Hutter, A., Waespe, W. & Bachli, E. B. Transient global amnesia—not so rare after all. *Swiss Med. Wkly* **139**, 288–292 (2009).
30. Caplan, L. in *Handbook of Clinical Neurology* (eds Vinken, P. J. *et al.*) 205–218 (Elsevier, Amsterdam, 1985).
31. Hodges, J. R. & Warlow, C. P. Syndromes of transient amnesia: towards a classification. A study of 153 cases. *J. Neurol. Neurosurg. Psychiatry* **53**, 834–843 (1990).
32. Hainselin, M. *et al.* Awareness of disease state without explicit knowledge of memory failure in transient global amnesia. *Cortex* **48**, 1079–1084 (2012).
33. Noel, A. *et al.* Psychopathological factors, memory disorders and transient global amnesia. *Br. J. Psychiatry* **193**, 145–151 (2008).
34. Inzitari, D. *et al.* Emotional arousal and phobia in transient global amnesia. *Arch. Neurol.* **54**, 866–873 (1997).
35. Lewis, S. L. Aetiology of transient global amnesia. *Lancet* **352**, 397–399 (1998).
36. Rösler, A., Mras, G. J., Frese, A., Albert, I. & Schnorpfel, F. Precipitating factors of transient global amnesia. *J. Neurol.* **246**, 53–54 (1999).
37. Bartsch, T. *et al.* Selective affection of hippocampal CA-1 neurons in patients with transient global amnesia without long-term sequelae. *Brain* **129**, 2874–2884 (2006).
38. Hodges, J. R. & Ward, C. D. Observations during transient global amnesia. A behavioural and neuropsychological study of five cases. *Brain* **112**, 595–620 (1989).
39. Eustache, F. *et al.* Episodic memory in transient global amnesia: encoding, storage, or retrieval deficit? *J. Neurol. Neurosurg. Psychiatry* **66**, 148–154 (1999).
40. Quinette, P. *et al.* Working memory and executive functions in transient global amnesia. *Brain* **126**, 1917–1934 (2003).
41. Guillery-Girard, B. *et al.* The dynamic time course of memory recovery in transient global amnesia. *J. Neurol. Neurosurg. Psychiatry* **75**, 1532–1540 (2004).
42. Zeman, A. Z. Episodic memory in transient global amnesia. *J. Neurol. Neurosurg. Psychiatry* **66**, 135 (1999).
43. Jager, T. *et al.* Selective disruption of hippocampus-mediated recognition memory processes after episodes of transient global amnesia. *Neuropsychologia* **47**, 70–76 (2009).
44. Jäger, T., Bätzner, H., Kliegel, M., Szabo, K. & Hennerici, M. G. The transience and nature of cognitive impairments in transient global amnesia: a meta-analysis. *J. Clin. Exp. Neuropsychol.* **31**, 8–19 (2009).
45. Bartsch, T., Döhring, J., Rohr, A., Jansen, O. & Deuschl, G. CA1 neurons in the human hippocampus are critical for autobiographical memory, mental time travel, and auto-noetic consciousness. *Proc. Natl Acad. Sci. USA* **108**, 17562–17567 (2011).
46. Hainselin, M. *et al.* Can we remember future actions yet forget the last two minutes? Study in transient global amnesia. *J. Cogn. Neurosci.* **23**, 4138–4149 (2011).
47. Hodges, J. R. Semantic memory and frontal executive function during transient global amnesia. *J. Neurol. Neurosurg. Psychiatry* **57**, 605–608 (1994).
48. Eustache, F. *et al.* Transient global amnesia: implicit/explicit memory dissociation and PET assessment of brain perfusion and oxygen metabolism in the acute stage. *J. Neurol. Neurosurg. Psychiatry* **63**, 357–367 (1997).
49. Guillery, B. *et al.* Semantic acquisition without memories: evidence from transient global amnesia. *Neuroreport* **12**, 3865–3869 (2001).
50. Mazzucchi, A., Moretti, G., Caffarra, P. & Parma, M. Neuropsychological functions in the follow-up of transient global amnesia. *Brain* **103**, 161–178 (1980).
51. Caffarra, P., Moretti, G., Mazzucchi, A. & Parma, M. Neuropsychological testing during a transient global amnesia episode and its follow-up. *Acta Neurol. Scand.* **63**, 44–50 (1981).
52. Cattaino, G., Querin, F., Pomes, A. & Piazza, P. Transient global amnesia. *Acta Neurol. Scand.* **70**, 385–390 (1984).
53. Hodges, J. R. & Oxbury, S. M. Persistent memory impairment following transient global amnesia. *J. Clin. Exp. Neuropsychol.* **12**, 904–920 (1990).
54. Gallassi, R. *et al.* Transient global amnesia: neuropsychological findings after single and multiple attacks. *Eur. Neurol.* **33**, 294–298 (1993).
55. Borroni, B. *et al.* Is transient global amnesia a risk factor for amnesic mild cognitive impairment? *J. Neurol.* **251**, 1125–1127 (2004).
56. Guillery-Girard, B. *et al.* Long-term memory following transient global amnesia: an investigation of episodic and semantic memory. *Acta Neurol. Scand.* **114**, 329–333 (2006).
57. Le Pira, F. *et al.* Cognitive findings after transient global amnesia: role of prefrontal cortex. *Appl. Neuropsychol.* **12**, 212–217 (2005).
58. Noel, A. *et al.* Influence of patients' emotional state on the recovery processes after a transient global amnesia. *Cortex* **47**, 981–991 (2011).
59. Neri, M. *et al.* Transient global amnesia: memory and metamemory. *Ageing (Milano)* **7**, 423–429 (1995).
60. Uttner, I. *et al.* Transient global amnesia—full recovery without persistent cognitive impairment. *Eur. Neurol.* **58**, 146–151 (2007).
61. Uttner, I. *et al.* Long-term outcome in transient global amnesia patients with and without focal hyperintensities in the CA1 region of the hippocampus. *Eur. Neurol.* **67**, 155–160 (2012).
62. Sedlaczek, O. *et al.* Detection of delayed focal MR changes in the lateral hippocampus in transient global amnesia. *Neurology* **62**, 2165–2170 (2004).
63. Lee, H. Y. *et al.* Diffusion-weighted imaging in transient global amnesia exposes the CA1 region of the hippocampus. *Neuroradiology* **49**, 481–487 (2007).
64. Yang, Y., Kim, S. & Kim, J. H. Ischemic evidence of transient global amnesia: location of the lesion in the hippocampus. *J. Clin. Neurol.* **4**, 59–66 (2008).
65. Weon, Y. C., Kim, J. H., Lee, J. S. & Kim, S. Y. Optimal diffusion-weighted imaging protocol for lesion detection in transient global amnesia. *AJNR Am. J. Neuroradiol.* **29**, 1324–1328 (2008).
66. Bartsch, T., Alfke, K., Deuschl, G. & Jansen, O. Evolution of hippocampal CA-1 diffusion lesions in transient global amnesia. *Ann. Neurol.* **62**, 475–480 (2007).
67. Ryoo, I. *et al.* Lesion detectability on diffusion-weighted imaging in transient global amnesia: the influence of imaging timing and magnetic field strength. *Neuroradiology* **54**, 329–334 (2012).
68. Choi, B. S., Kim, J. H., Jung, C. & Kim, S. Y. High-resolution diffusion-weighted imaging increases lesion detectability in patients with transient global amnesia. *AJNR Am. J. Neuroradiol.* **33**, 1771–1774 (2012).
69. Scheel, M., Malkowsky, C., Klingebiel, R., Schreiber, S. J. & Bohner, G. Magnetic resonance imaging in transient global amnesia: lessons learned from 198 Cases. *Clin. Neuroradiol.* <http://dx.doi.org/10.1007/s00062-012-0140-7>.
70. Cianfoni, A. *et al.* Hippocampal magnetic resonance imaging abnormalities in transient global amnesia. *Arch. Neurol.* **62**, 1468–1469 (2005).
71. Auyeung, M. *et al.* Association of diffusion weighted imaging abnormalities and recurrence in transient global amnesia. *J. Clin. Neurosci.* **18**, 531–534 (2011).
72. Gonzalez-Martinez, V., Comte, F., de Verbizier, D. & Carlander, B. Transient global amnesia: concordant hippocampal abnormalities on positron emission tomography and magnetic resonance imaging. *Arch. Neurol.* **67**, 510 (2010).
73. Bartsch, T. *et al.* Focal MR spectroscopy of hippocampal CA-1 lesions in transient global amnesia. *Neurology* **70**, 1030–1035 (2008).
74. Wang, X. *et al.* High intrinsic oxidative stress may underlie selective vulnerability of the hippocampal CA1 region. *Brain Res. Mol. Brain Res.* **140**, 120–126 (2005).
75. Segal, M., Richter-Levin, G. & Maggio, N. Stress-induced dynamic routing of hippocampal connectivity: a hypothesis. *Hippocampus* **20**, 1332–1338 (2010).
76. Fanselow, M. S. & Dong, H. W. Are the dorsal and ventral hippocampus functionally distinct structures? *Neuron* **65**, 7–19 (2010).
77. Sander, K. & Sander, D. New insights into transient global amnesia: recent imaging and clinical findings. *Lancet Neurol.* **4**, 437–444 (2005).
78. Enzinger, C. *et al.* Transient global amnesia: diffusion-weighted imaging lesions and cerebrovascular disease. *Stroke* **39**, 2219–2225 (2008).
79. Hughlings Jackson, J. & Colman, W. S. Case of epilepsy with tasting movements and “dreamy state”: very small patch off softening in the left uncinate gyrus. *Brain* **21**, 580–590 (1898).
80. Gallassi, R. Epileptic amnesic syndrome: an update and further considerations. *Epilepsia* **47** (Suppl. 2), 103–105 (2006).
81. Butler, C. R. & Zeman, A. Z. Recent insights into the impairment of memory in epilepsy: transient epileptic amnesia, accelerated long-term forgetting and remote memory impairment. *Brain* **131**, 2243–2263 (2008).
82. Cretin, B., Davature, C., Longato, N., Philippi, N. & Blanc, F. Syndrome of transient epileptic amnesia and epileptic amnesic syndrome: the same entity? [French]. *Rev. Neurol. (Paris)* <http://dx.doi.org/10.1016/j.neurol.2012.03.013>.
83. Kapur, N. Transient epileptic amnesia—a clinical update and a reformulation. *J. Neurol. Neurosurg. Psychiatry* **56**, 1184–1190 (1993).
84. Zeman, A. Z., Boniface, S. J. & Hodges, J. R. Transient epileptic amnesia: a description of the clinical and neuropsychological features in 10 cases and a review of the literature. *J. Neurol. Neurosurg. Psychiatry* **64**, 435–443 (1998).
85. Butler, C. R. *et al.* The syndrome of transient epileptic amnesia. *Ann. Neurol.* **61**, 587–598 (2007).
86. Butler, C. R. & Zeman, A. The causes and consequences of transient epileptic amnesia. *Behav. Neurol.* **24**, 299–305 (2011).
87. Biló, L., Meo, R., Ruosi, P., de Leva, M. F. & Striano, S. Transient epileptic amnesia: an emerging late-onset epileptic syndrome. *Epilepsia* **50** (Suppl. 5), 58–61 (2009).
88. Manes, F., Graham, K. S., Zeman, A., de Lujan Calcagno, M. & Hodges, J. R. Autobiographical amnesia and accelerated forgetting in transient epileptic amnesia. *J. Neurol. Neurosurg. Psychiatry* **76**, 1387–1391 (2005).

89. Milton, F. *et al.* Remote memory deficits in transient epileptic amnesia. *Brain* **133**, 1368–1379 (2010).
90. Muhler, N., Milton, F., Butler, C. R., Kapur, N. & Zeman, A. Z. Accelerated forgetting of real-life events in transient epileptic amnesia. *Neuropsychologia* **48**, 3235–3244 (2010).
91. Hornberger, M. *et al.* Focal retrograde amnesia: extending the clinical syndrome of transient epileptic amnesia. *J. Clin. Neurosci.* **17**, 1319–1321 (2010).
92. Bell, B. D. & Giovagnoli, A. R. Recent innovative studies of memory in temporal lobe epilepsy. *Neuropsychol. Rev.* **17**, 455–476 (2007).
93. Herfurth, K., Kasper, B., Schwarz, M., Stefan, H. & Pauli, E. Autobiographical memory in temporal lobe epilepsy: role of hippocampal and temporal lateral structures. *Epilepsy Behav.* **19**, 365–371 (2010).
94. Wilkinson, H. *et al.* Long-term accelerated forgetting of verbal and non-verbal information in temporal lobe epilepsy. *Cortex* **48**, 317–332 (2012).
95. Butler, C. R. & Zeman, A. A case of transient epileptic amnesia with radiological localization. *Nat. Clin. Pract. Neurol.* **4**, 516–521 (2008).
96. Butler, C. R. *et al.* Transient epileptic amnesia: regional brain atrophy and its relationship to memory deficits. *Brain* **132**, 357–368 (2009).
97. Midorikawa, A. & Kawamura, M. Recovery of long-term anterograde amnesia, but not retrograde amnesia, after initiation of an anti-epileptic drug in a case of transient epileptic amnesia. *Neurocase* **13**, 385–389 (2007).
98. Butler, C. R. *et al.* The syndrome of transient epileptic amnesia. *Ann. Neurol.* **61**, 587–598 (2007).
99. Kopelman, M. D. Disorders of memory. *Brain* **125**, 2152–2190 (2002).
100. Pyszora, N., Barker, A. & Kopelman, M. Amnesia for criminal offences: a study of life sentence prisoners. *J. Forens. Psychiatry Psychol.* **14**, 475–490 (2003).
101. Markowitsch, H. J. Functional retrograde amnesia—amnestic block syndrome. *Cortex* **38**, 651–654 (2002).
102. Kritchevsky, M., Zouzounis, J. & Squire, L. R. Transient global amnesia and functional retrograde amnesia: contrasting examples of episodic memory loss. *Philos. Trans. R. Soc. Lond. B Biol. Sci.* **352**, 1747–1754 (1997).
103. Kanzer, M. Amnesia: a statistical study. *Am. J. Psychiatry* **96**, 711–716 (1939).
104. Coons, P. M. & Milstein, V. Psychogenic amnesia: a clinical investigation of 25 cases. *Dissociation* **5**, 73–79 (1992).
105. Yehuda, R., Schmeidler, J., Siever, L. J., Binder-Brynes, K. & Elkin, A. Individual differences in posttraumatic stress disorder symptom profiles in Holocaust survivors in concentration camps or in hiding. *J. Trauma Stress* **10**, 453–463 (1997).
106. Kritchevsky, M., Chang, J. & Squire, L. R. Functional amnesia: clinical description and neuropsychological profile of 10 cases. *Learn. Mem.* **11**, 213–226 (2004).
107. Reinhold, N. & Markowitsch, H. J. Retrograde episodic memory and emotion: a perspective from patients with dissociative amnesia. *Neuropsychologia* **47**, 2197–2206 (2009).
108. Kopelman, M. D. Focal retrograde amnesia and the attribution of causality: an exceptionally critical view. *Cogn. Neuropsychol.* **17**, 585–621 (2000).
109. Kapur, N. Focal retrograde amnesia and the attribution of causality: an exceptionally benign commentary. *Cogn. Neuropsychol.* **17**, 623–637 (2000).
110. Manes, F., Hodges, J. R., Graham, K. S. & Zeman, A. Focal autobiographical amnesia in association with transient epileptic amnesia. *Brain* **124**, 499–509 (2001).
111. Fujiwara, E. *et al.* Functional retrograde amnesia: a multiple case study. *Cortex* **44**, 29–45 (2008).
112. Piolino, P. *et al.* Right ventral frontal hypometabolism and abnormal sense of self in a case of disproportionate retrograde amnesia. *Cogn. Neuropsychol.* **22**, 1005–1034 (2005).
113. Brand, M. *et al.* Functional brain imaging in 14 patients with dissociative amnesia reveals right inferolateral prefrontal hypometabolism. *Psychiatry Res.* **174**, 32–39 (2009).
114. Levine, B. *et al.* Episodic memory and the self in a case of isolated retrograde amnesia. *Brain* **121**, 1951–1973 (1998).
115. Loewenstein, R. J. in *Review of Psychiatry* Vol. 10 (eds Tasman, A. & Goldfinger, S. M.) 189–222 (APA Press, Washington DC, 1991).
116. Markowitsch, H. J., Thiel, A., Kessler, J., von Stockhausen, H.-M. & Heiss, W.-D. Ephorizing semi-conscious information via the right temporopolar cortex—a PET study. *Neurocase* **3**, 445–449 (1997).
117. Benson, D. F., Marsden, C. D. & Meadows, J. C. The amnesic syndrome of posterior cerebral artery occlusion. *Acta Neurol. Scand.* **50**, 133–145 (1974).
118. Takahashi, S. *et al.* Correlation of lesions in the hippocampal region noted on MR images with clinical features. *Eur. Radiol.* **7**, 281–286 (1997).
119. Victor, M., Angevine, J. B. Jr, Mancall, E. L. & Fisher, C. M. Memory loss with lesions of hippocampal formation. Report of a case with some remarks on the anatomical basis of memory [Italian]. *Arch. Neurol.* **5**, 244–263 (1961).
120. Ott, B. R. & Saver, J. L. Unilateral amnesic stroke. Six new cases and a review of the literature. *Stroke* **24**, 1033–1042 (1993).
121. Szabo, K. *et al.* Hippocampal lesion patterns in acute posterior cerebral artery stroke: clinical and MRI findings. *Stroke* **40**, 2042–2045 (2009).
122. Forster, A. *et al.* Diffusion-weighted imaging for the differential diagnosis of disorders affecting the hippocampus. *Cerebrovasc. Dis.* **33**, 104–115 (2012).
123. Carota, A., Lysandropoulos, A. P. & Calabrese, P. Pure left hippocampal stroke: a transient global amnesia-plus syndrome. *J. Neurol.* **259**, 989–992 (2012).
124. von Cramon, D. Y., Hebel, N. & Schuri, U. Verbal memory and learning in unilateral posterior cerebral infarction. A report on 30 cases. *Brain* **111**, 1061–1077 (1988).
125. Graff-Radford, N. R., Tranel, D., Van Hoesen, G. W. & Brandt, J. P. Diencephalic amnesia. *Brain* **113**, 1–25 (1990).
126. von Cramon, D. Y., Hebel, N. & Schuri, U. A contribution to the anatomical basis of thalamic amnesia. *Brain* **108**, 993–1008 (1985).
127. Papagno, C., Rizzo, S., Ligorì, L., Lima, J. & Riggio, A. Memory and executive functions in aneurysms of the anterior communicating artery. *J. Clin. Exp. Neuropsychol.* **25**, 24–35 (2003).
128. Tuzun, E. & Dalmau, J. Limbic encephalitis and variants: classification, diagnosis and treatment. *Neurologist* **13**, 261–271 (2007).
129. Dalmau, J. Recognizing paraneoplastic limbic encephalitis. *J. Clin. Oncol.* **27**, e230–e231 (2009).
130. Vincent, A., Bien, C. G., Irani, S. R. & Waters, P. Autoantibodies associated with diseases of the CNS: new developments and future challenges. *Lancet Neurol.* **10**, 759–772 (2011).
131. Urbach, H. *et al.* Serial MRI of limbic encephalitis. *Neuroradiology* **48**, 380–386 (2006).
132. Bien, C. G. *et al.* Limbic encephalitis as a precipitating event in adult-onset temporal lobe epilepsy. *Neurology* **69**, 1236–1244 (2007).
133. Dalmau, J., Lancaster, E., Martinez-Hernandez, E., Rosenfeld, M. R. & Balice-Gordon, R. Clinical experience and laboratory investigations in patients with anti-NMDAR encephalitis. *Lancet Neurol.* **10**, 63–74 (2011).
134. Squire, L. R. Memory systems of the brain: a brief history and current perspective. *Neurobiol. Learn. Mem.* **82**, 171–177 (2004).

Acknowledgements

We wish to thank G. Deuschl, J. Döhring, K. Witt, A. Zeman, and other colleagues for helpful input, support and for many inspiring discussions. This work has been supported by Deutsche Forschungsgemeinschaft SFB 654 (TP A14; awarded to T. Bartsch) and by the Faculty of Medicine, University of Kiel, Germany. C. Butler is funded by the National Institute for Health Research. All case examples included in this manuscript are fictional and provided for illustrative purposes only.

Author contributions

Both authors contributed equally to all aspects of this manuscript.