

Vascular Malformations and Pregnancy

Balaji Sadasivan, M.B.B.S., F.R.C.S., Ghaus M. Malik, M.D., Chang Lee, M.D., and James I. Ausman, M.D., Ph.D.

Henry Ford Neurosurgical Institute, Department of Neurological Surgery, Henry Ford Hospital Division, and Department of Gynecology & Obstetrics, Henry Ford Hospital, Detroit, Michigan

Sadasivan B, Malik GM, Lee C, Ausman JI. Vascular malformations and pregnancy. *Surg Neurol* 1990;33:305-13.

Between January 1975 and June 1989, 240 patients with cerebral vascular malformations were treated at Henry Ford Hospital. In 16 of the patients, the treatment was influenced by pregnancy. Eleven of the patients presented with hemorrhage, four with seizures, and one with hydrocephalus. There were no maternal or fetal deaths in the patients presenting with seizure or hydrocephalus. There were two maternal deaths and one fetal death among the cases presenting with hemorrhage. In the patients with seizure or hydrocephalus, the pregnancy was brought to term and obstetric indications used to determine the time and method of delivery. Hydrocephalus was treated by shunting, and seizures with medication. Antiepileptic drug levels fluctuate in pregnancy and hence were closely monitored to ensure therapeutic levels. Vascular malformations are the most common cause of subarachnoid hemorrhage in pregnancy. The risk of rebleed in the same pregnancy is about 27%. If an arteriovenous malformation ruptures during pregnancy and the patient's condition deteriorates, appropriate emergency surgery should be done. In stable patients, our policy has been to bring the pregnancy to term and then electively perform a craniotomy to excise the arteriovenous malformation.

KEY WORDS: Arteriovenous malformation; Hydrocephalus; Pregnancy; Seizures; Subarachnoid hemorrhage

Introduction

Spontaneous subarachnoid hemorrhage (SAH) due to ruptured aneurysm or arteriovenous malformation (AVM) accounts for about 4.4% of all maternal deaths [2]. It is the third most frequent nonobstetric cause for maternal death [2]. About half the patients who present with SAH during pregnancy have a ruptured AVM

[22,23]. The presence of an AVM, ruptured or unruptured, complicates the management of pregnancy. Pregnancy also affects the natural history of an AVM, making it more likely to hemorrhage. We present our experience in the management of 16 patients with vascular malformations complicated by pregnancy. We also discuss some of the problems in the management of vascular malformations during pregnancy.

Clinical Material and Methods

Between January 1975 and June 1989, 240 patients with cerebral vascular malformations were treated at Henry Ford Hospital. In 16 of the patients, the management was complicated by pregnancy. Eleven patients had a history of hemorrhage. The unruptured AVMs were diagnosed because of seizures in four patients and hydrocephalus in one patient.

Results

Ruptured Arteriovenous Malformation

The clinical findings, management, and outcome of each case are summarized in Table 1. One case of hemorrhage occurred in the first trimester, three cases in the second trimester, four cases in the third trimester, and three cases in the puerperium. There were four primigravida patients (average age 21.3 years) and seven multigravida patients (average age 30.9 years). In cases 2 and 9, the malformation was a venous angioma. Three patients presented in a comatose state with decerebrate posturing. Headache was a complaint for all noncomatose patients. Two patients had grand mal seizures at the time of hemorrhage.

In 10 patients, the vascular malformation was excised. Six patients had good results, and one had a fair result. There were two maternal deaths (cases 6 and 7), and one case with a poor result secondary to severe arterial narrowing (case 1). In case 8, the AVM was not operated on. There was one fetal death (case 3).

Address reprint requests to: Ghaus M. Malik, M.D., Henry Ford Neurosurgical Institute, Department of Neurological Surgery, Henry Ford Hospital, 2799 West Grand Boulevard, Detroit, Michigan 48202.

Received October 20, 1989; accepted December 19, 1989.

Table 1. Patients with Ruptured Arteriovenous Malformation

Case no.	Age (yr)	Parity	Site	Type of vascular malformation	Gestation at time of hemorrhage	Presenting complaint	Management	Outcome of mother	Outcome of infant
1	26	G3P0A2	L occipital	AVM	12 weeks	Headache, dysphasia, R hemiparesis	Craniotomy and exc 9 days after hemorrhage	Poor; bilateral infarcts from arterial narrowing	Spontaneous abortion just before hemorrhage CS at 36 weeks
2	19	G1P0A0	L parieto-temporal	Venous angioma	21 weeks	Headache, seizure	Exc of AVM 4 yrs after delivery	Good	Delivered stillborn by CS at 23 weeks
3	38	G4P3A0	R parietal	AVM	23 weeks	Headache, lethargy, L hemiplegia, fetal distress	Emergency CS followed by emergency evac of ICH. Exc AVM remnant 2 weeks later	Good	
4	25	G1P0A0	R lateral ventricle	AVM	23 weeks	Decerebrate	Emergency evac hematoma. Exc AVM 2 mo postdelivery	Good; left with residual hemiparesis	Membrane ruptured at 34 weeks; CS done to avoid labor, infant well
5	39	G2P1A0	Corpus callosum	AVM	27 weeks	Headache, L hemiparesis	Craniotomy and exc of AVM 3 mo post-delivery	Good	Infant well
6	27	G3P2A0	R basal ganglia	AVM	34 weeks	L hemiplegia then decerebrate	Craniotomy with evac ICH. Aggressive mgmt of ICP	Progressive neurologic deterioration; brain death	CS at 34 weeks immediately after craniotomy; infant well
7	37	G3P2A0	Corpus callosum	AVM	36 weeks	Headache, drowsiness	Rebled day 6 postpartum. Emergency craniotomy, evac of hematoma, and exc of AVM	Postop gram-negative ventriculitis; died 1 mo later	CS at 36 weeks for fetal distress; infant well

8	23	G4P3A0	L temporal	AVM	32 weeks	Headache	Conservative	Good; follow up 1 yr later. No rebleed	CS at 34 weeks		
9	18	G1P1A0	R parietal	Venous angioma	2 weeks postpartum	Headache, blurred vision, seizure	Craniotomy and exc venous angioma 2 mo postdelivery	Good	Infant well		
10	23	G1P1A0	L occipital	AVM	3 weeks postpartum	Headache, R homonymous inferioquadrant-anopia	Craniotomy and exc of AVM 2 mo post-delivery	Good	Infant well		
11	26	G2P2A0	R frontal	AVM	3 weeks postpartum	Headache, L hemiplegia then obtundation	Craniotomy, evac of hematoma, and excision of AVM	Fair	Infant well		

Abbreviations: AVM, Arteriovenous malformation; CS, cesarian section; evac, evacuation; exc, excision; ICH, intracerebral hematoma; CP, intracranial pressure; L, left; magt, management; R, right.

Maternal Mortality

Case 6 was a 27-year-old woman, gravida 3, para 2, who at 34 weeks of pregnancy had the sudden onset of left hemiplegia and progressed to decerebrate posturing. Computed tomography (CT) scan showed a right basal ganglia hemorrhage. An emergency craniotomy, evacuation of hematoma, and excision of AVM were performed. This was followed by a cesarean section in which a healthy baby was delivered. The patient remained comatose, and despite aggressive medical treatment with Mannitol (Astra Pharmaceutical Products, Inc., Westboro, Mass.) and Lasix (Hoechst-Roussel Pharmaceuticals, Inc., Sommerville, NJ), she progressed to brain death.

Case 7 was a 37-year-old woman, gravida 3, para 2, who presented with headache and drowsiness at 36 weeks of pregnancy. Computed tomography scan showed intraventricular hemorrhage. Cerebral angiography revealed a corpus callosum AVM. A cesarean section was performed at 36 weeks for fetal distress. The infant was healthy. On the sixth postpartum day, she rebleed and became comatose (Figure 1). An emergency craniotomy, evacuation of hematoma, and excision of AVM were performed. The postoperative period was complicated by gram-negative ventriculitis. She remained in a vegetative state for a month and then died.

Fetal Mortality

Case 3 was a 38-year-old woman, gravida 4, para 3, who at 23 weeks gestation developed headache, lethargy, and hemiplegia. She also had evidence of fetal distress. An emergency cesarean section was performed and a still-born fetus was delivered. This was followed by a craniotomy, evacuation of hematoma, and excision of right parietal AVM. Postoperative angiography showed residual AVM, which was excised 2 weeks later. The patient had a good outcome.

Morbidity from "Vasospasm"

Case 1 was a 26-year-old woman, gravida 3, para 0, who by history was 12 weeks pregnant when she was admitted with a left occipital hemorrhage. There was a history of vaginal bleeding the day before admission. Ultrasound of the pelvis could not detect a gestational sac. Serum human chorionic gonadotropin tested twice was 41 and 47 mIU/mL (normal nonpregnant, <10 mIU/mL; 12 weeks pregnant, 500-200,000 mIU/mL). We concluded that she had a spontaneous abortion before her admission. On the ninth day after admission, her condition worsened. The AVM was excised, and the hematoma

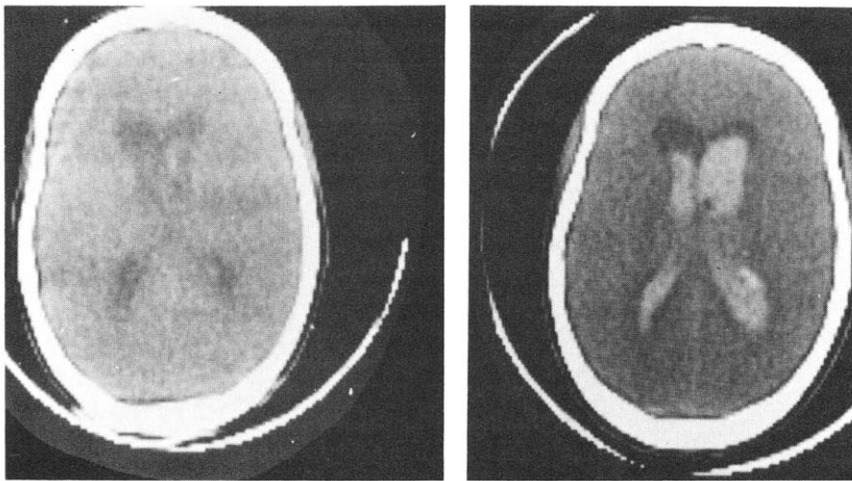


Figure 1. case 7. (Left) CT scan at time of admission (36 weeks gestation) shows a little blood along the margin of the left lateral ventricle. (Right) CT scan on sixth postpartum day shows rehemorrhage.

evacuated. Angiograms the next day revealed severe narrowing of bilateral carotid, anterior cerebral, and middle cerebral arteries (Figure 2). She sustained infarcts in both hemispheres and is in a vegetative state.

Unoperated Arteriovenous Malformation

Case 8 was a 23-year-old woman, gravida 4, para 3, who at 32 weeks of pregnancy presented with headache. Magnetic resonance imaging (MRI) revealed a small left medial temporal lobe AVM and hematoma. At 34 weeks, a cesarean section was performed and a healthy infant delivered. Cerebral angiography showed no evidence of the AVM that was present on MRI. We believe the AVM was probably thrombosed. We intend to repeat angiography and MRI 1 year later.

Unruptured Arteriovenous Malformations

The clinical findings, management, and outcome of the patients with unruptured AVMs are summarized in Table 2. The four patients who presented with seizure during pregnancy were primigravid. Three had their first episode of grand mal seizure during the pregnancy. One patient (case 1) had the first episode of grand mal seizure at age 12. She was seizure-free until her first pregnancy at age 21.

Case 16 was a 27-year-old woman, gravida 2, para 1, who complained of headache. A CT scan showed hydrocephalus and a third ventricular AVM. Cerebral angiography revealed the third ventricular AVM. She also had an AVM in the lung (Rendu-Osler-Weber syndrome) (Figure 3). She was treated with a ventriculoperitoneal shunt. The AVM was excised 3 years later.

In all five cases of unruptured AVM, the pregnancy

was successfully managed and healthy infants delivered at term based on obstetric indications. The patients had elective craniotomy and excision of AVM between 2 to 16 years after their pregnancy, with four good results and one fair result.

Discussion

Robinson et al [22,23] have shown an association between pregnancy and hemorrhage from an AVM. They compared women younger than 45 years old who were diagnosed as having an AVM and were pregnant within 2 years of the diagnosis with similar women who were not pregnant within 2 years of the diagnosis. There was a 10% incidence of SAH in the nonpregnant group and an 85% incidence of SAH in the pregnant group. If a pregnant woman presents with a diagnosis of SAH, the chance of an AVM being the cause of the SAH is 50%, as compared with 10% in nonpregnant women. The risk of rebleed after a ruptured AVM is about 6% in the first year [29]. The risk of rebleed within the same pregnancy after a hemorrhage is 27% [22].

We have added our cases to others reported in the literature to create a composite graph showing the period in gestation when rupture occurred (Figure 4) [1,2,4,6,11,18,23,26]. This graph shows that AVMs tend to rupture between 20 weeks gestation and 6 weeks postpartum. The tendency to rupture may be related to hemodynamic, hormonal, and coagulation changes that occur during this period.

Cardiac output rises during pregnancy by 30%–60%. The increase begins during the first trimester and reaches a maximum toward the end of the second trimester [13]. This high level is maintained

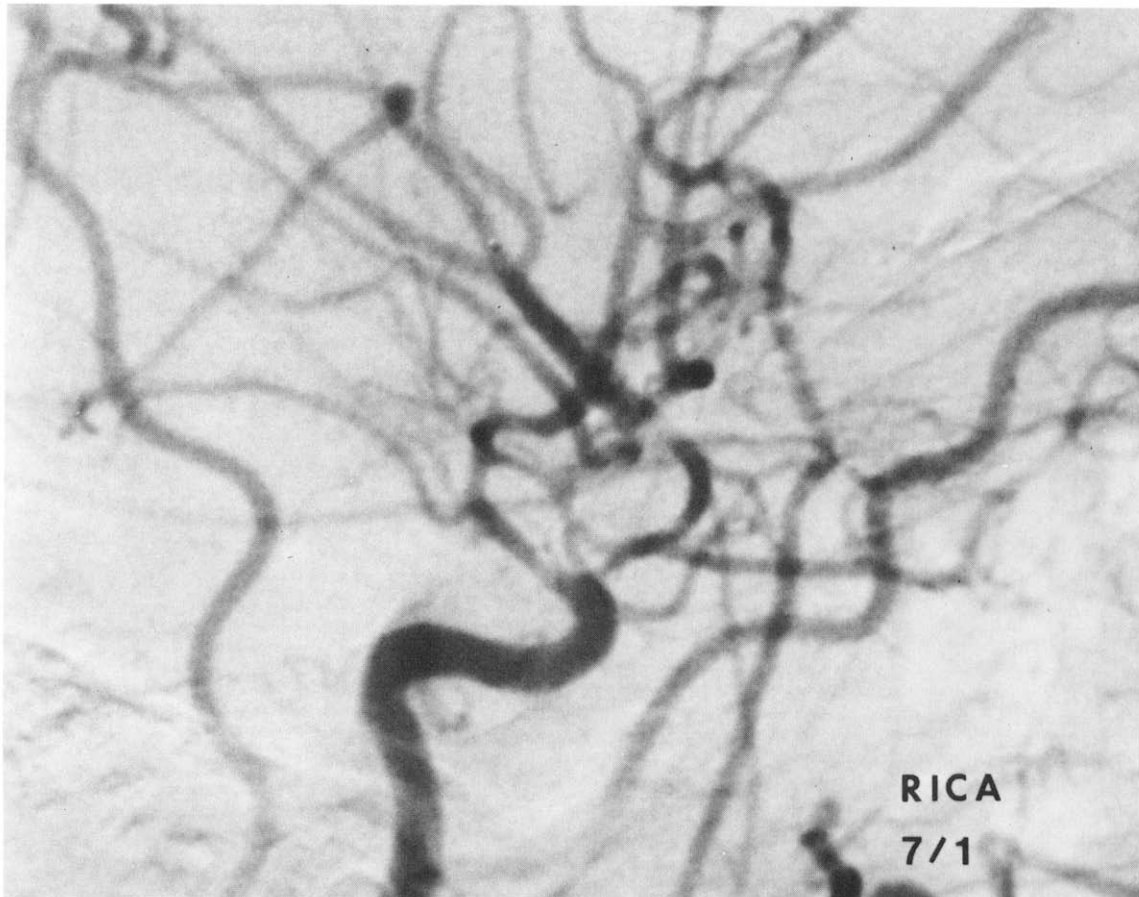


Figure 2. Case 1. Angiogram shows severe arterial narrowing of right internal carotid artery, middle cerebral artery, and anterior cerebral artery 10 days after hemorrhage.

until term. The levels return to the prepregnancy state several weeks after delivery. The period of increased risk of hemorrhage coincides with the period of raised cardiac output. The increase in cardiac output is greater than can be accounted for by the increase in uterine blood flow. This increase in cardiac output appears to be mediated by a decrease in systemic vascular resistance. The mechanism for this vasodilatation is not known, but it may be secondary to the rise in estrogens [27].

Fibrin formation may increase fivefold in pregnancy. This is accompanied by substantially increased fibrinolysis. Although fibrin formation should improve hemostasis, the increase in fibrinolysis makes the patient vulnerable to intravascular coagulation and its hemorrhagic complications [10].

The management of ruptured vascular malformations during pregnancy is difficult. When a pregnant patient is suspected of having SAH, a CT scan on the head with appropriate shielding of the abdomen should be done. Once the diagnosis is confirmed, the management is based on neurosurgical rather than obstetric criteria.

If the patient has an intracranial hematoma and clinical evidence of herniation, emergency evacuation of the hematoma is necessary. There have been several reports of successful excision of AVMs in pregnant women using hypothermia [5,8,9,18]. The risk of hypothermia to the fetus is unknown. During surgery of the pregnant patient, hypotension and osmotic diuretics should be avoided. Maternal hypotension causes fetal hypoxia. Osmotic diuretics such as Mannitol have been shown to cross the placenta and raise the osmolarity of fetal plasma [3,8]. This can result in fetal dehydration.

Two of the vascular malformations in our patients were venous angiomas (Figure 5). The risk of hemorrhage from venous angioma is real though not well established statistically. Malik et al [17] reported nine patients with hemorrhage in their series of 21 cases of venous angioma. Two of the nine patients with

Table 2. *Patients with Unruptured Arteriovenous Malformation During Pregnancy*

Case no.	Age (yr)	Parity	Presentation	Location of AVM	Management	Outcome
12	21	G1P0A0	GMS at age 12; seizure-free until first pregnancy	L frontoparietal AVM	Continued to have seizures about 2 episodes/yr for 6 yrs. Had 2nd child, craniotomy, and exc of AVM	Expressive dysphasia and dyscalculia; seizures
13	16	G1P0A0	First episode of GMS during pregnancy	L parietotemporal AVM	Psychomotor seizures for 16 yrs. Craniotomy and exc of AVM	No deficits; psychomotor seizures under control
14	30	G1P0A0	Episode L body numbness at ages 7, 13, 17; headache at 3 mo gestation; 1st episode of GMS at 6 mo gestation	R parietal AVM	Craniotomy and exc of AVM 2 yrs later	L homonymous hemianopsia, seizures
15	30	G1P0A0	Episode R body numbness at age 15; GMS during pregnancy	L frontoparietal AVM	Progressive increased seizures and spastic R hemiparesis 2 yrs. Craniotomy and exc of AVM	R hemiparesis, dysphasia, impaired memory
16	27	G2P1A0	L leg weakness and paresthesia; headache backache; CT scan: hydrocephalus and 3rd ventricular AVM	Corpus collosum AVM, 3rd ventricular AVM	Ventriculoperitoneal shunt, 3 yrs. post delivery craniotomy and exc of AVM	Transient diabetes insipidus. Discovered to have pulmonary AVM (Rendu-Osler-Weber syndrome)

Abbreviations: AVM, Arteriovenous malformation; exc, excision; GMS, grand mal seizure; L, left; R, right.

hemorrhage from venous angioma were pregnant at the time of hemorrhage. Pregnancy and/or the sex hormones may have a role in increasing the risk of hemorrhage from venous angioma.

Angiographic arterial narrowing (vasospasm) after hemorrhage from an AVM is rare. There are few reports of radiologic evidence of arterial narrowing after hemorrhage from an AVM, but the arterial narrowing was not associated with infarction [20,24,25,28]. The occurrence of arterial narrowing and subsequent infarcts in case 1 is unusual. Again, the role of pregnancy in contributing to the arterial narrowing remains speculative.

There are several considerations in the management of non-life-threatening, ruptured AVMs in pregnancy once the diagnosis is made:

1. The pregnant patient is at increased risk of re-bleed during the pregnancy and puerperium. This risk can be eliminated only by excision of the AVM.
2. Surgery during pregnancy poses risks to the fetus and the mother.
3. The technical difficulty and risks in excising the lesion need consideration. The size, location, arterial supply, and venous drainage, as well as the need for

preoperative embolization in selected cases, should be considered.

4. If the malformation is in an eloquent area, the patient may wish to postpone surgery to when it is easier for her and her family to deal with any disability, even a temporary one.

In general, if we are dealing with an AVM that can be easily excised with low risk, we wait until the fetus is mature enough to be safely delivered (usually 34 to 38 weeks). Cerebral angiography (if not performed previously) and excision of the AVM can then be performed.

It is difficult to determine the best time to perform the elective surgery to excise the AVM. Puerperium is a period of increased risk of hemorrhage, and delaying surgery until after puerperium exposes the patient to this risk. We have generally performed the elective surgery about 2 months after the delivery when the hemodynamic changes associated with pregnancy return to normal. We have presumed that this makes the surgery easier. However, a strong case can be made for surgery immediately after delivery. Case 7 in this report rebled on the sixth postdelivery day. Treatment in all cases should be individualized after discussion with the patient and her family.

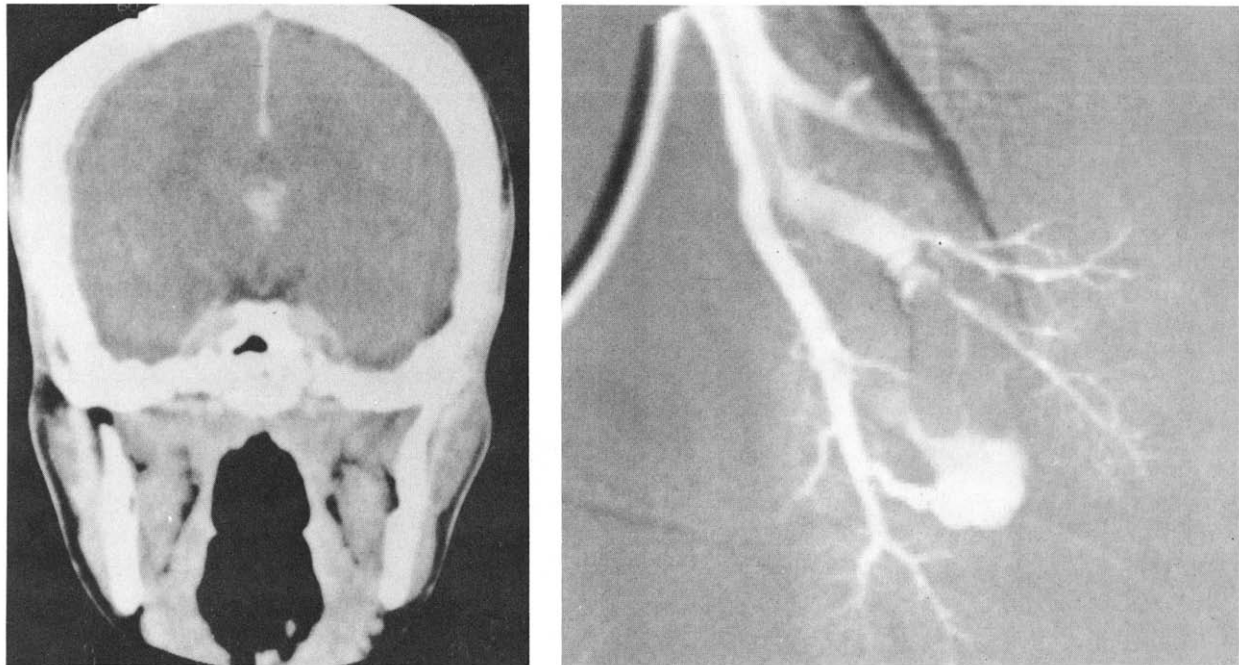


Figure 3. Case 16 (Rendu-Osler-Weber syndrome). (Left) CT scan with contrast enhancement shows the third ventricular AVM. (Right) Right pulmonary angiogram shows an AVM in the lung.

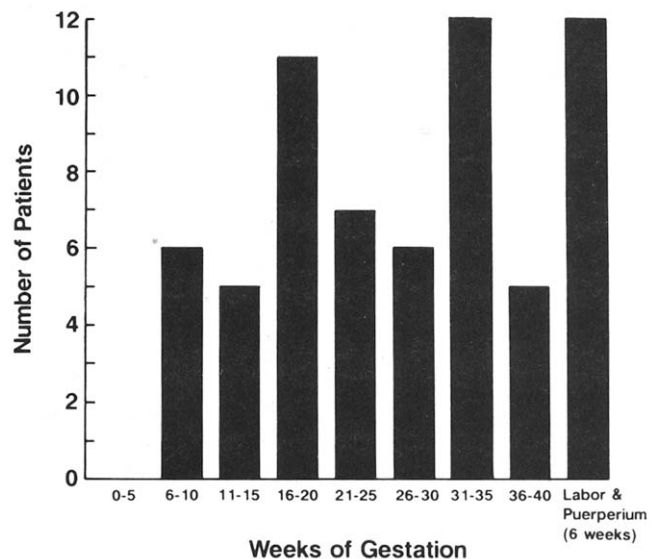
It is unclear whether labor increases the risk of hemorrhage. Biller and Adams [4] reported a case of hemorrhage from an AVM during labor. One third of pregnant women have markedly elevated cerebrospinal fluid pressure during labor [19]. The Valsalva effect during labor causes the venous pressure to rise and increases the stress on the abnormal veins in the AVM. We think it is probably safer to perform an elective cesarean section.

The management of patients with unruptured AVM during pregnancy is based on obstetric criteria. The AVM is treated after delivery based on the same principles as in nonpregnant women. The unruptured AVM in most cases is diagnosed because of seizures. In 13% of all epileptic women, seizures first begin during a pregnancy [14,15]. Estrogens and chorionic gonadotropin appear to lower the seizure threshold. In the presence of an epileptogenic focus such as an AVM, the lowered threshold causes a seizure.

No anticonvulsant is free of teratogenic risk. To minimize the teratogenic risk, it is probably safer to use monotherapy rather than multiple drug therapy. There are several good reviews in the management of

epilepsy in pregnancy [7,12,15,16,21]. Phenytoin or carbamazepine may be used. It is important to measure serum anticonvulsant levels throughout pregnancy. High or toxic levels should be avoided in the first trimester because this is the period of greatest teratogenic risk, and the risk may be dose dependent. In the latter part of pregnancy, anticonvulsant levels may drop because of decreased protein binding.

Figure 4. Composite graph showing the period in gestation when hemorrhage occurs.



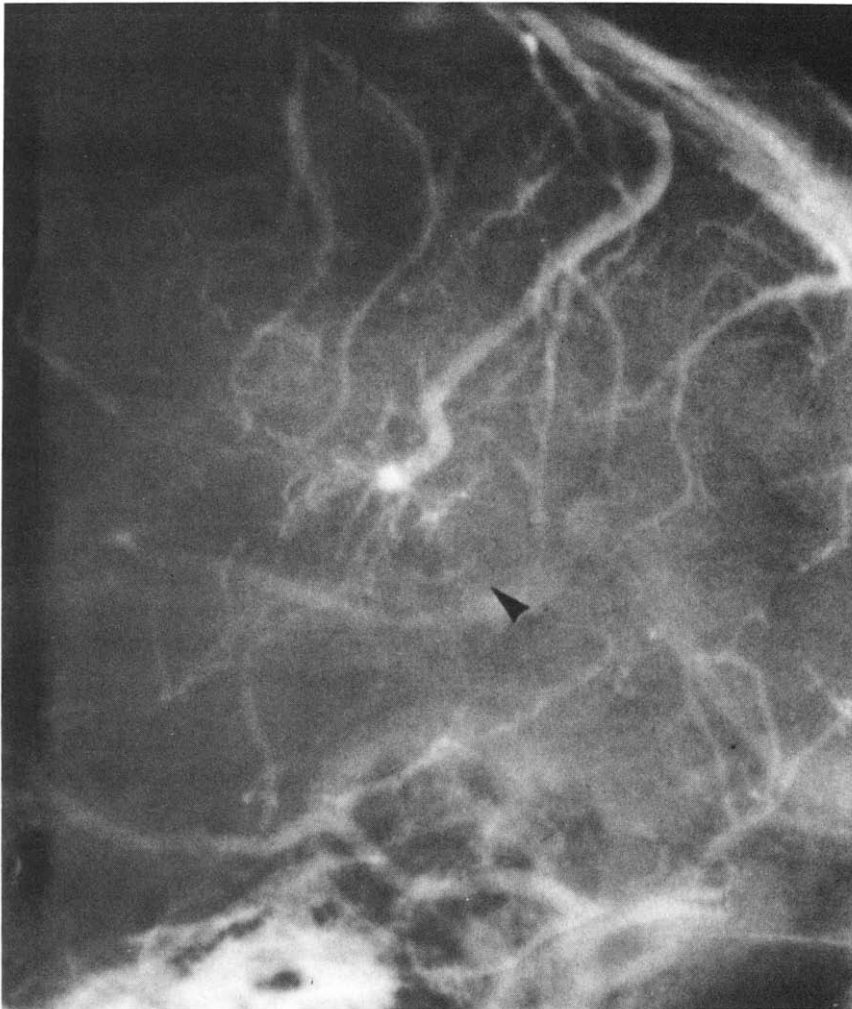


Figure 5. Case 2. A venous angioma (arrowhead) that hemorrhaged during pregnancy.

References

1. Amias AG. Cerebral vascular disease in pregnancy: I. Haemorrhage. *J Obstet Gynaecol Br Commonwealth* 1970;77:100-20.
2. Barno A, Freeman DW. Maternal deaths due to spontaneous subarachnoid hemorrhage. *Am J Obstet Gynecol* 1976;125:384-92.
3. Battaglia F, Prystowsky H, Smission C, Hellegers A, Bruns P. Effect of the administration of fluids intravenously to mothers upon the concentrations of water and electrolytes in plasma of human fetuses. *Pediatrics* 1970;25:2-10.
4. Biller J, Adams HP. Cerebrovascular disorders associated with pregnancy. *Am Fam Physician* 1986;33:125-32.
5. Boba A. Hypothermia, appraisal of risk in 110 consecutive patients. *J Neurosurg* 1962;19:924-33.
6. Cannell DE, Botterell EH. Subarachnoid hemorrhage and pregnancy. *Am J Obstet Gynecol* 1956;72:844-55.
7. Dalessio DJ. Seizure disorders and pregnancy. *N Engl J Med* 1985;312:559-63.
8. Dunn JM, Raskind R. Rupture of a cerebral arteriovenous malformation during pregnancy. *Obstet Gynecol* 1967;30:423-6.
9. Dunn JM, Weiss SR, Raskind R. Rupture of intracranial arteriovenous malformation in pregnancy. *Int Surg* 1968;49:241-7.
10. Fletcher AP, Alkjaersig NK, Burstein R. The influence of pregnancy upon blood coagulation and plasma fibrinolytic enzyme function. *Am J Obstet Gynecol* 1979;134:743-51.
11. Fliegner JRH, Hooper RS, Kloss M. Subarachnoid hemorrhage and pregnancy. *J Obstet Gynaecol Br Commonwealth* 1969;76:912-7.
12. Hiiilesmaa V, Bardy A, Teramo K. Obstetric outcome in women with epilepsy. *Am J Obstet Gynecol* 1985;152:499-504.
13. Kerr MG. Cardiovascular dynamics in pregnancy and labour. *Br Med Bull* 1968;24:19-24.
14. Knight AH, Rhind EG. Epilepsy and pregnancy: a study of 153 pregnancies in 59 patients. *Epilepsia* 1975;16:99-110.
15. Krumholz A. Epilepsy and pregnancy. In: Goldstein PJ, ed. *Neurological disorders of pregnancy*. New York: Futura, 1986:65-88.
16. Levy RH, Yerby MS. Effects of pregnancy on antiepileptic drug utilization. *Epilepsia* 1985;26(suppl):52-7.
17. Malik GM, Morgan JK, Boulos RS, Ausman JI. Venous angiomas: an underestimated cause of intracranial hemorrhage. *Surg Neurol* 1988;30:350-8.

18. Matsuki A, Oyama T. Operation under hypothermia in a pregnant woman with an intracranial arteriovenous malformation. *Can Anaesth Soc J* 1972;19:184-91.
19. McCausland A, Holmes F. Spinal fluid pressure during labour. *West J Surg Obstet Gynecol* 1957;65:220-33.
20. Nishimura K, Hawkins TD. Cerebral vasospasm with subarachnoid hemorrhage from arteriovenous malformations of the brain. *Neuroradiology* 1975;8:201-7.
21. Robertson IG. Epilepsy in pregnancy. *Clin Obstet Gynaecol* 1986;13:365-84.
22. Robinson JL, Hall CJ, Sedzimir CB. Arteriovenous malformations, aneurysms and pregnancy. *J Neurosurg* 1974;41:63-70.
23. Robinson JL, Hall CJ, Sedzimir CB. Subarachnoid hemorrhage in pregnancy. *J Neurosurg* 1972;36:27-33.
24. Sasaki T, Mayanagi Y, Yano H, Kim S. Cerebral vasospasm with subarachnoid hemorrhage from cerebral arteriovenous malformations. *Surg Neurol* 1981;16:183-7.
25. Stornelli SA, French JD. Subarachnoid hemorrhage—factors in prognosis and management. *J Neurosurg* 1964;21:769-80.
26. Tuttelman RM, Gleicher N. Central nervous system hemorrhage complicating pregnancy. *Obstet Gynecol* 1981;58:651-6.
27. Ueland K, Paver JT. Effects of estrogens on the cardiovascular system of the ewe. *Am J Obstet Gynecol* 1966;96:400-6.
28. VonHolst H, Ericson K, Haberbeck-Modesto M, Steiner L. Angiographic investigation of cerebral vasospasm in subarachnoid haemorrhage due to arteriovenous malformation. *Acta Neurochir (Wien)* 1988;94(3-4):129-32.
29. Wilkins RH. Natural history of intracranial vascular malformation: a review. *Neurosurgery* 1985;16:421-30.