

## **Visual Diagnosis in Emergency Medicine**

### **BILATERAL OCCIPITAL INFARCTION: AN UNCOMMON CAUSE OF BILATERAL VISUAL LOSS**

Khai Meng Chang, MD, Visvaraja Subrayan, MBBS, FRCS (EDINBURGH), FRCOPHTH, and Dinesh Kumar Patel, MMED (UM)

Department of Ophthalmology, University Malaya Medical Center, Kuala Lumpur, Malaysia  
Reprint Address: Khai Meng Chang, MD, Department of Ophthalmology, Faculty of Medicine, University of Malaya,  
50630 Kuala Lumpur, Malaysia

#### **CASE REPORT**

A 62-year-old man with a history of type 2 diabetes mellitus for 5 years presented to the Emergency Department with sudden onset of bilateral visual loss and dizziness for a day. He denied any other neurological symptoms, such as headache or fever. There was no history of trauma, migraine, or substance abuse.

The patient's blood pressure was 149/85 mm Hg, pulse rate was 89 beats/min and regular in rhythm. He was able to perceive only light in both eyes. Pupillary light reflex and accommodation reflex were normal. Fundus examination revealed mild diabetic retinopathy in both eyes with normal optic discs. A neurological examination was unremarkable. He did not have any cardiac murmurs and there was no carotid bruit heard.

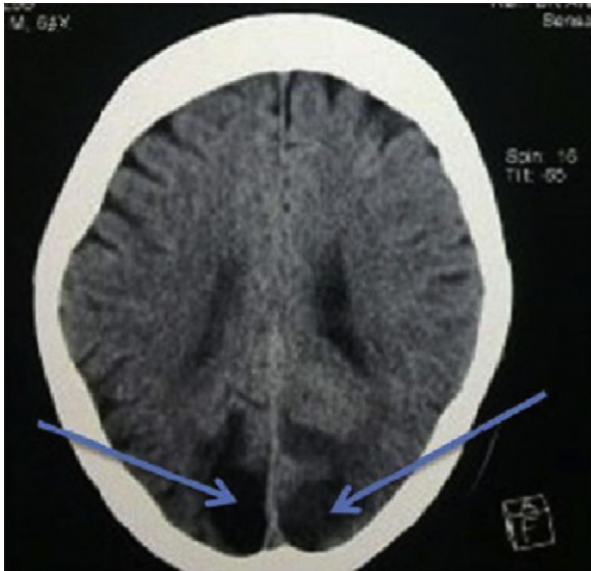
Apart from an elevated random blood sugar level of 216 mg/dL (12 mmol/L), all other blood tests were within normal range. However, an urgent computed tomography scan of the brain showed bilateral occipital infarcts (Figure 1). Further investigations, including echocardiography and carotid Doppler ultrasound, were performed and were normal. At 3-month follow-up, his visual acuity improved to counting fingers and at 6 months it was 6/36.

#### **DISCUSSION**

Sudden onset of bilateral visual loss is always a medical emergency. Patients frequently seek medical attention first at the Emergency Department. Recognition of this symptom is important because it often leads to the diagnosis of other serious systemic conditions, such as stroke.

Acute onset of bilateral visual loss with a normal ocular and pupillary examination often indicates that the lesion is located at the geniculocalcarine visual pathways. This condition is referred to as cerebral blindness. The common causes of cerebral blindness include trauma to the occipital region, migraine, occipital seizures, space-occupying lesions involving the occipital lobe, occipital infarcts that can be thromboembolic, vasculitic, or due to inadequate perfusion. There have been other reported rare causes of cerebral blindness, such as reversible posterior leukoencephalopathy syndrome; cardiac procedures, such as coronary angiography and cerebral angiography; and pre-eclampsia and eclampsia (1–6).

Unilateral occipital infarction is not uncommon, but bilateral occipital infarction is a rare phenomenon. In bilateral occipital infarction, patients can present with complete visual loss or tunnel vision. Rarely, patients can deny blindness or confabulate their visual perceptions;



**Figure 1.** Brain computed tomography scan shows bilateral occipital hypodense areas (arrows), suggestive of ischemic stroke.

this is known as Anton syndrome (7,8). On examination, apart from demonstrating features of cerebral blindness such as absence of blinking in response to visual threat, absence of optokinetic reflex, normal pupillary reflexes and fundi, it might be associated with other neurological deficits, depending on the extent of the stroke.

The main blood supply to the striate cortex is derived from branches of the posterior cerebral artery, mainly through the calcarine artery, with lesser supply from the posterior temporal and parieto-occipital arteries (9). There is an anastomosis between posterior cerebral arteries and the superior tempo-occipital sylvian artery from the middle cerebral artery (7). This dual blood supply to the area responsible for central vision explains the tunnel vision in certain patients with posterior cerebral artery occlusion (10).

Studies have shown that cardiac embolism is the most common cause of occipital infarction and posterior circulation stroke (11–13). The etiology of the infarction cannot be determined in at least 25% to 38% of patients, as in the case presented here (11–13). Other causes of occipital infarction include carotid artery disease, vertebrobasillar artery stenosis, in situ thrombosis in the circle of Willis, hypercoagulation, cardiac surgery, and migraine (7).

Neuroimaging should be considered in cases where an occipital infarction is suspected. Computed tomography

scan might be less expensive and can be performed in the Emergency setting; however, magnetic resonance imaging is more sensitive in detecting small infarction. Apart from this, echocardiography, carotid Doppler ultrasound, and magnetic resonance angiography are helpful in investigating the etiology of stroke (7).

## CONCLUSIONS

Bilateral occipital infarction, although rare, should be considered as an important differential diagnosis for sudden onset bilateral blindness, especially if pupillary reflexes and fundus examination are normal. Computed tomography scan or magnetic resonance imaging of the brain should be performed to facilitate the diagnosis.

*Acknowledgments*—The authors acknowledge Dr. Koay Chiang Ling from the Department of Ophthalmology of the University Malaya Medical Center for the proofreading of this article.

## REFERENCES

1. Kahana A, Rowley HA, Weinstein JM. Cortical blindness: clinical and radiologic findings in reversible posterior leukoencephalopathy syndrome: case report and review of the literature. *Ophthalmology* 2005;112:e7–11.
2. Alp BN, Bozbuğa N, Tuncer MA, et al. Transient cortical blindness after coronary angiography. *J Int Med Res* 2009;37:1246–51.
3. Kuruvilla A. Cortical blindness following coronary angiography. *Singapore Med J* 2001;42:394–5.
4. Aldrich MS, Alessi AG, Beck RW, et al. Cortical blindness: etiology, diagnosis, and prognosis. *Ann Neurol* 1987;21:149–58.
5. Llovera I, Roit Z, Johnson A, et al. Cortical Blindness, a rare complication of pre-eclampsia. *J Emerg Med* 2005;29:295–7.
6. Adali E, Kurdoglu M, Avcu S, et al. Reversible acute cortical blindness associated with eclampsia in complete hydatidiform mole. *Ir J Med Sci* 2011;180:287–90.
7. Liu GT, Volpe NJ, Galetta SL. *Neuro-Ophthalmology Diagnosis and Management*. 2nd edition. Philadelphia: Saunders/Elsevier; 2010:305–330.
8. Misra M, Rath S, Mohanty AB. Anton syndrome and cortical blindness due to bilateral occipital infarction. *Indian J Ophthalmol* 1989; 37:196.
9. Smith CG, Richardson WF. The course and distribution of the arteries supplying the visual (striate) cortex. *Am J Ophthalmol* 1966;61:1391–6.
10. Heider B, Landis T. Tunnel vision and topographic disorientation after bilateral occipital lobe damage. *Neurocase* 1997;3:185–92.
11. Pessin MS, Lathi ES, Cohen MB, et al. Clinical features and mechanism of occipital infarction. *Ann Neurol* 1987;21:290–9.
12. Brandt T, Steinke W, Thie A, et al. Posterior cerebral artery territory infarcts: clinical features, infarct topography, causes and outcome. Multicenter results and a review of the literature. *Cerebrovasc Dis* 2000;10:170–82.
13. Bruno A, LaKind E. Occipital infarction: carotid artery and cardiac findings. *J Stroke Cerebrovasc Dis* 1992;2:70–3.