

Unilateral Thalamic Vim and GPi Stimulation for the Treatment of Holmes' Tremor Caused by Midbrain Cavernoma: Case Report and Review of the Literature

Sabri Aydin¹ Bashar Abuzayed¹ Gunes Kiziltan² Aysegul Gunduz² Selin Yagci³ Murat Mengi⁴
Osman Kizilkilic⁵ Mustafa Uzan¹ Murat Hanci¹

¹Department of Neurosurgery, Cerrahpasa Medical Faculty, Istanbul University, Istanbul, Turkey

²Department of Neurology, Cerrahpasa Medical Faculty, Istanbul University, Istanbul, Turkey

³Department of Neuropsychology, Cerrahpasa Medical Faculty, Istanbul University, Istanbul, Turkey

⁴Department of Physiology, Cerrahpasa Medical Faculty, Istanbul University, Istanbul, Turkey

⁵Department of Neuroradiology, Cerrahpasa Medical Faculty, Istanbul University, Istanbul, Turkey

Address for correspondence Bashar Abuzayed, MD, Department of Neurosurgery, Cerrahpasa Medical Faculty, Istanbul University, K.M.P. Fatih, Istanbul 34089, Turkey (e-mail: sylvius@live.com).

J Neurol Surg A 2013;74:271–276.

Abstract

A 30-year-old man with brainstem cavernoma experienced hemorrhage and was operated in 2008. Six months after the operation, the patient presented with new complaints of left arm tremor namely Holmes' tremor. Neurological examination also revealed left-sided internuclear ophthalmoplegia, left-sided mild paresis, and increased deep tendon reflexes of the left upper extremity, truncal ataxia, and dysarthria. Brain magnetic resonance imaging showed a postoperative cavity and gliosis at the level of the superior and inferior colliculus in the right tegmentum and right red nucleus with extension to the substantia nigra. Fahn–Tolosa–Marin tremor rating scale (TRS) for his left upper extremity (Part A, score 6) was 11 for the proximal and the distal arm. After the failure of medical treatment, the patient underwent right globus pallidum internus and ventral intermediate thalamic nucleus deep brain stimulation. There were no side effects related to the stimulation. Final TRS months after operation was 3 for the proximal and 4 for the distal arm.

Keywords

- ▶ deep brain stimulation
- ▶ globus pallidus internus
- ▶ Holmes' tremor
- ▶ midbrain tremor
- ▶ ventralis intermedialis nucleus

Introduction

Holmes' tremor (HT), also called midbrain tremor, rubral tremor, and myorhythmia, is an uncommon movement disorder that involves a combination of rest, postural, and kinetic tremors, the latter having particularly disabling clinical effects.¹ This tremor occurs as in pathologies affecting cerebellar outflow pathways or the region of the red nucleus.² The most commonly reported surgical target for the treat-

ment of HT is the ventral intermediate thalamic nucleus (Vim).^{3–14} However, with an increasing pathophysiological understanding many other structures are being targeted (either alone or in combination) with good results, such as globus pallidum internus (GPi),¹⁵ subthalamic nucleus (STN),¹⁶ caudal zona incerta (cZI),¹⁷ and ventralis oralis anterior (VOA) and posterior.⁵ Among the cases treated with deep brain stimulation (DBS), there is only one reported

received

November 2, 2011

accepted after revision

December 13, 2011

published online

January 14, 2013

© 2013 Georg Thieme Verlag KG
Stuttgart · New York

DOI <http://dx.doi.org/>

10.1055/s-0032-1322549.

ISSN 2193-6315.

case of GPi DBS for the treatment of HT.¹⁵ In this report, we present our case of HT which was treated with unilateral Vim and GPi DBS. The difference between the surgical techniques and the results are discussed on the basis of review of the literature.

Case Report

A 30-year-old man presented in 2008 with sudden loss of consciousness due to brainstem hematoma. Brain magnetic resonance imaging (MRI) revealed a cavernoma located in the posterior right midbrain and pons, extending through the tectum and tegmentum to reach the substantia nigra (►Fig. 1A, B). The patient was operated by suboccipital and transtovelar approach to expose the fourth ventricle and resect the lesion. In the postoperative period hydrocephalus developed which required ventriculoperitoneal shunt placement.

Six months after operation, the patient presented with new complains of left arm tremor. The tremor was found to involve both the distal and proximal parts of the arm including the shoulder. The tremor was a combination of rest and postural low-frequency 4-Hz rhythmic movements exacerbating with intentional motion. He had accompanying dystonic movements in the left upper extremity. He had very

poor fine motor control of his left hand and was unable to write legibly. The tremor was evaluated with the Fahn–Tolosa–Marin tremor rating scale (TRS)¹⁸ for his left upper extremity (Part A, score 6). However, due to the differential involvement of the proximal and distal parts of the arm, the tremor scoring was performed separately for the proximal and distal upper extremity. Tremor score was 11 for the proximal and for the distal arm. Other neurologic findings included left-sided internuclear ophthalmoplegia, left-sided paresis, and increased deep tendon reflexes of the left upper extremity, truncal ataxia, and dysarthria. Brain MRI showed a cavity and gliosis in the previous location of the cavernoma in the brainstem. The lesion was located in the level of the superior and inferior colliculus in the right tegmentum and right red nucleus with extension to the substantia nigra (►Fig. 1C–F). Electrophysiological investigations revealed both rest and postural tremor with the frequency of 4 to 5 Hz. This characteristic tremor was more prominent in the proximal arm and these findings were consistent with the diagnosis of HT. Neuropsychological tests revealed reduced anterograde visual memory, retrograde episodic memory, attention in working memory, and verbal fluency. Trials of L-dopa 450 mg/day (8 months) and Keppra (levetiracetam) 1000 mg/day (2 months) were applied; however, they were ineffective to reduce the tremor. Surgical treatment with DBS

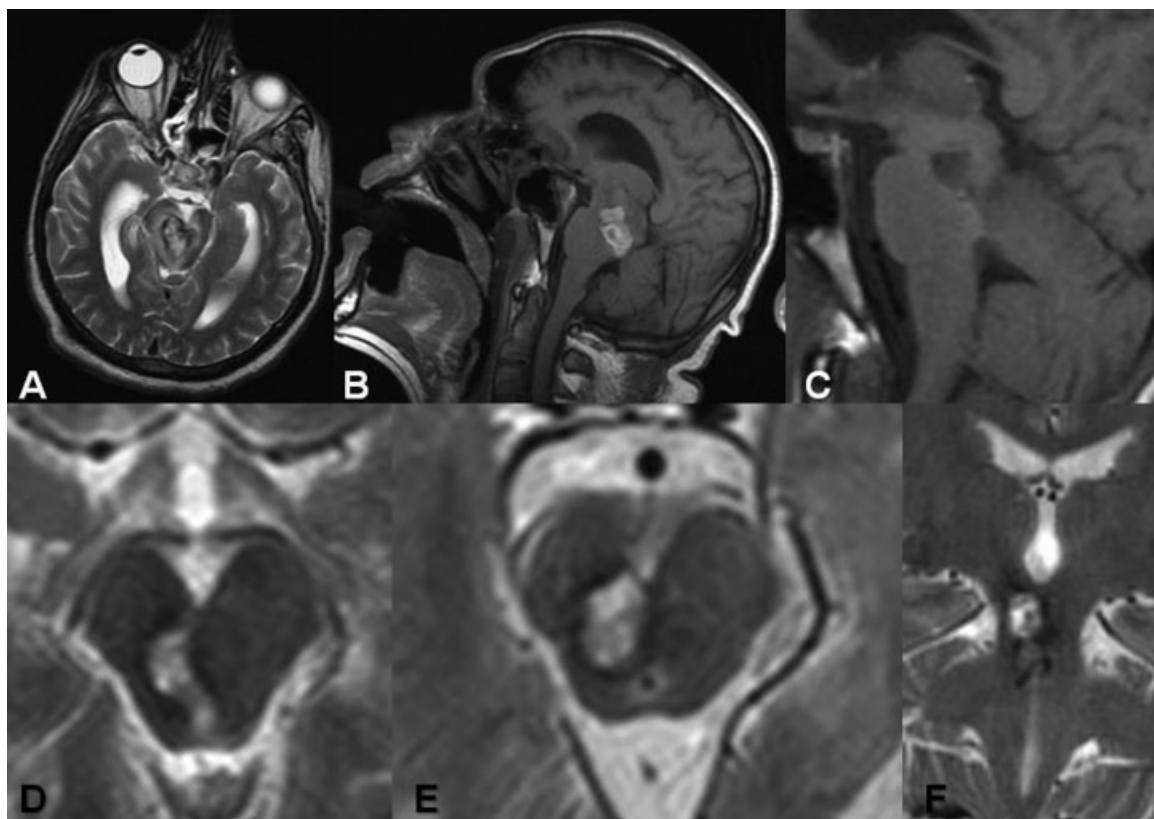


Fig. 1 (A) Axial T2-weighted and (B) sagittal T1-weighted brain MRI of our patient demonstrating a bled cavernoma located in the posterior of the right mesencephalon and pons, extending through the right tectum and tegmentum and right nucleus rubra and reaching the substantia nigra. (C) Sagittal T1 weighted, (D) axial T2 weighted MRI at the level of the superior colliculus, (E) axial T2 weighted MRI at the level of the inferior colliculus, and (F) coronal T2-weighted MRI after the microsurgical resection showing the cavity and gliosis in the previous location of the cavernoma in the brainstem. MRI, magnetic resonance imaging.

was decided after the failure of the medical treatment to improve the tremor.

The surgical procedure was performed under local anesthesia and sedation using the Leksell (Elekta, Stockholm, Sweden) stereotactic frame with ring system. The surgical targets were the right GPi and Vim. Their positions were localized anatomically by direct visualizing on T2-weighted and inversion recovery MRI. FrameLink 2.0 software (Medtronic, Inc., Minneapolis, MN, USA) was used for the application of computed tomography (CT)-MR fusion technique and reformatted the MR image to the anterior commissure-posterior commissure (AC-PC) plane to yield the calculated coordinates for the GPi and Vim, with the aid of Schaltenbrand and Wahren stereotactic atlas. Quadripolar electrodes (Model 3389, Medtronic, Inc.) were implanted in the right GPi and Vim in a single session. Electrode targeting was confirmed for GPi using microelectrode recordings (MERs) which demonstrated bursting pattern of the neurons (►Fig. 2A). This pattern was observed to be the most active in the central portion of our target, and continued to appear 3 mm below the target point, where the electrodes were finally implanted. Macrostimulation was performed for GPi and demonstrated no side effects. For Vim, only macrostimulation was performed without MER, which showed immediate response of the distal tremor pause with no side effects. The final stereotactic coordinates of the targeted right GPi were 16.3 mm lateral to the midline, 6.13 mm anterior to the mid-commissural point, and 0.6 mm below the AC-PC plane, and for the right Vim they were 14.1 mm lateral to the midline, 7.17 mm posterior to the mid-commissural point, and at the same level than the AC-PC plane (►Fig. 2B). A dual-channel pulse generator (Kinetra Model 7428, Medtronic, Inc.) was connected to the leads and im-

planted subclavicularly in the right chest wall during the same surgical procedure. No complication occurred during or after the surgery. Postoperative cranial CT scan was obtained and confirmed the position of the electrodes (►Fig. 2C, D). The activation of the electrodes took place 3 days after the surgery. The stimulation parameters were 1 V, 130 Hz, 90 μ s, with monopolar stimulation on contact 0 for both targets. Six months after stimulation tremor showed improvement, especially the resting component. The effect of the Vim and GPi stimulation was evaluated separately by individual activation of the leads and it was found that the head tremor was aggravated by Vim stimulation at high voltages. Final stimulation adjustments were 3 V, 90 μ s, 100 Hz for the Vim and 3 V, 210 μ s, 130 Hz for the GPi, and the final TRS score for his left upper extremity tremor (Part A, score 6) was 3 for the proximal and 4 for the distal arm. There were no side effects related to the stimulation.

Discussion

First described by Holmes in 1904,¹⁹ HT—also called rubral or midbrain tremor—is a tremor defined by a combination of rest and postural low-frequency rhythmic movements exacerbating with intentional motion. Diagnostic criteria of HT are: (1) Rest and intention tremors are present with sometimes irregular presentation. In many patients postural tremor is also present. The tremor is often not as rhythmical as other tremors. (2) Tremor is of low frequency, mostly below 4.5 Hz. (3) A variable delay (mostly 4 weeks until 2 years) between the lesion and the first occurrence of the tremor is typical.¹ HT has been described as sequelae of trauma,²⁰ hemorrhage and ischemia,¹⁴ multiple sclerosis,²¹ vascular malformation,²² and tumor.²³ This tremor is also a component of a constellation of symptoms known as Benedikt's syndrome that, in addition to tremor, manifests as oculomotor palsy and contralateral hemiparesis. This occurs with damage to the midbrain tegmentum, including fascicle of the oculomotor nerve, cerebral and cerebellar peduncles, red nucleus, and substantia nigra.

It is generally accepted that HT is a symptomatic tremor which is known to occur after different lesions centered to the brainstem/cerebellum and thalamus. Two systems, the dopaminergic nigrostriatal system and the cerebellothalamic system must be lesioned according to pathoanatomical,²⁴ positron emission tomography (PET)²⁵ single photon emission computed tomography (SPECT),² and tractography studies.²⁶ Simply, HT can be considered as a combination of basal ganglia and cerebellar tremor.¹ The presence of concomitant rest and kinetic tremor is explained by the combined dysfunction of the cerebellothalamic and nigrostriatal systems.¹ The basal ganglia outflow pathway from the GPi exerts a direct influence on not only the thalamus but also the brainstem motor centers such as the pedunculopontine nucleus related to the midbrain tegmental field that controls the axial and proximal appendicular musculature via the descending reticulospinal tract.¹⁴ Moreover, dysfunction of the olivocerebellar system may similarly contribute to tremor activity which is conveyed to the thalamus and the

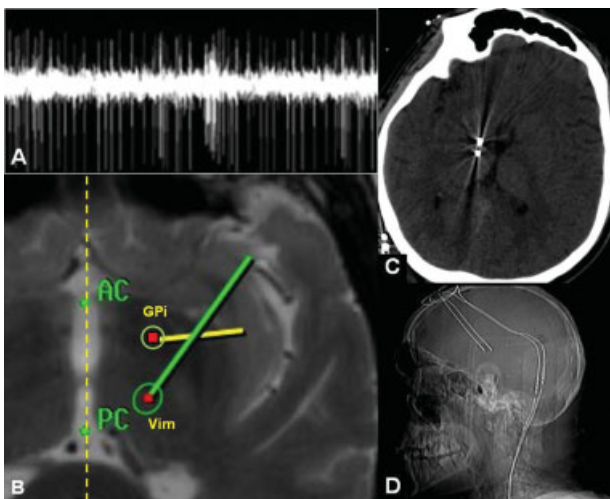


Fig. 2 (A) Intraoperative MRI showing the stereotactically targeted right GPi and Vim, and the planned trajectory of the electrodes. (B) MER of the right GPi demonstrating the burst pattern. (C) Postoperative brain CT scan and (D) lateral plain radiograph showing the final position of the electrodes in the right GPi and Vim. CT, computed tomography; GPi, globus pallidus internus; MER, microelectrode recording; MRI, magnetic resonance imaging; Vim, ventral intermediate thalamic nucleus.

thalamocortical system, thus effective thalamic DBS excites thalamocortical projections.²⁷ By high-frequency excitation, thalamic DBS may mask the abnormal input of synchronous oscillations to the motor cortex and therefore cancel the rhythmic entrainment of spinal motoneurons and muscles.²⁷ In addition, Herzog et al²⁷ found that neuromodulation of the dopaminergic system by high-frequency stimulation of the STN could drive downstream thalamic neurons resulting in the activation of cortical areas in PET imaging. These findings indicated that the pathophysiological changes responsible for the tremor generation may extend to include thalamocortical and striatocortical circuits. The conclusion that the pathophysiology of HT is centered upon both the motor striatal and thalamic circuits was the basis of the authors to favor electrode implanting at two different targets for the neuromodulation of these circuits.

The pathogenesis of a delayed HT after a pontine damage has been considered to involve the dentato-rubro-olivary system.¹⁴ In the present case, MRI showed a lesion in the mesencephalon and pons, which was extending through the tectum and tegmentum indicating transneuronal or trans-synaptic degeneration secondary to the interruption of the olivary afferent fibers of the pontine central tegmental tract (→Fig. 3). The latent period for the development of the tremor is thought to be due to the plasticity of the affected systems, especially the nigrostriatal system. Dopaminergic denervation followed by regeneration was demonstrated in SPECT and PET studies of the dopaminergic systems.²⁵ This aspect was supported with the findings of improvement in such cases treated with levodopa or dopamine agonists.²⁶ However, well reported levodopa-resistant cases, as our case, indicate that structural changes in the dopaminergic system may not exist.¹³ Gajos et al² performed Dopamine Transporter Scan (DaT-Scan) in 6 HT patients with different etiologies. They did not find significant abnormalities in the dopaminergic system

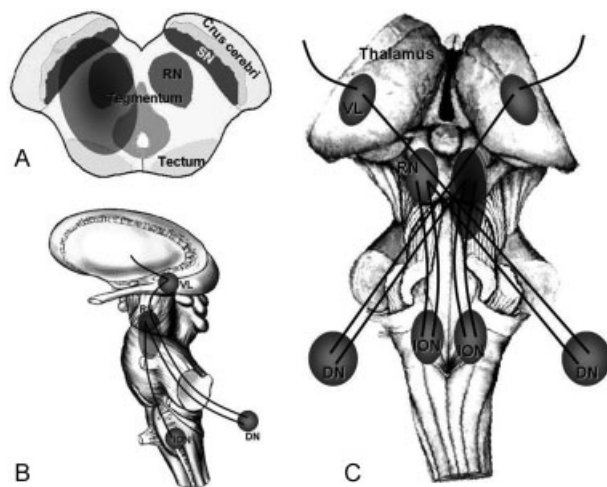


Fig. 3 A schematic drawing demonstrating the brainstem and the location of the lesion and the possible affected pathways responsible for the development of HT. (A) axial, (B) lateral, and (C) anterior views. DN, dentate nucleus; ION, inferior olivary nucleus; HT, Holmes' tremor; RN, red nucleus; SN, substantia nigra; VL, ventrolateral thalamic nucleus.

of the patients indicating that different pathophysiological processes may lead to the development of the phenomenology of HT.

Stereotactic Vim surgery, either thalamotomy or thalamic stimulation, is a mainstay in the surgical treatment of parkinsonian or essential tremors.²⁸ Its efficacy in tremor suppression is superior to that of pallidotomy in parkinsonian patients. Thalamic surgery interrupts the thalamocortical output that controls distal appendicular musculature via descending corticospinal and corticobulbar tracts. However, it does not always produce satisfactory results in patients with HT, particularly with respect to their proximal tremors.^{15,16} On the other hand, GPi surgery influences the control of otherwise inaccessible axial and proximal muscles. The GPi has two output pathways projecting both to the motor thalamus and the brainstem reticular formation, which contribute to the ascending pallidothalamocortical pathway and descending pallidoreticulospinal pathway, respectively.²⁹ In the somatotopy of the GPi obtained by intraoperative micro-recordings, representative areas of the extremities were located over a wide area and overlapped with each other, thus contributing to the efficacy of pallidal surgery for proximal tremor and generalized dystonia.³⁰ GPi stimulation can cause significant improvement in this component of tremor due to the known effect of GPi stimulation in improving dystonia, as seen in this case.

Due to the limited efficacy of Vim surgery on proximal tremors, the use of other or additional surgeries with greater effects, for example, pallidal surgery³¹ or subthalamic area stimulation,²² should be considered for the treatment of HT. A review of the English and French literature using the Medline database, showed 20 reported cases of HT treated with DBS (→Table 1). Most of these patients were treated with good results by Vim surgery. However, comparison of the results is difficult, as different techniques of tremor evaluation have been used. Quantitative tremor evaluation does not report the effect on concomitant dystonia or other coexisting abnormal movements. In addition, the details on the different subtypes of tremor were not reported. Nevertheless most patients had at least partial tremor improvement, documented for a follow-up period of at least 6 months. Interestingly, the beneficial effect was achieved in five patients only by dual stimulation, mostly in another part of the Vim.^{5,7,15-17} Romanelli et al¹⁶ implanted a Vim DBS electrode in a patient with HT and found improvement in the postural and kinetic aspects of the tremor with no change in the resting tremor. Subsequently, a second electrode was placed in the STN with complete resolution of the tremor. In one case study, however, Lim et al¹⁵ found that GPi DBS was more effective in controlling upper extremity HT than either Vim or VOA stimulation and that adding Vim/VOA stimulation produced little improvement. Additionally, Plaha et al¹⁷ have demonstrated that stimulation of the cZI effectively reduces both the action and resting components of proximal and distal tremors. They proposed that DBS of the cZI is likely to suppress distal tremor by overriding oscillations in the ventrolateral nucleus, interpositus, and the inferior olivary (IO) nucleus, and proximal tremor by overriding oscillations in the

Table 1 Summary of the Cases of Holmes' Tremor Reported in the Literature Which were Treated with DBS

Authors (year)	Age/sex	Etiology	Surgical Treatment	Follow-Up Period	Final Adjustments	Clinical Results (RT/PT/IT)
Shepherd et al (1997) ¹⁴	52/M	Pons hematoma	Thalamic	NA	NA/NA/160 Hz	+ +/+ +/+ +
Kudo et al (2001) ⁷	67/F	Midbrain and pons hematoma	Bilateral Vim	NA	R: 2.2 V/100 µs/150 Hz L: 1.7 V/100 µs/150 Hz	+ +/+ +/+ +
Pahwa et al (2002) ⁹	45/F	Midbrain cavernoma	R Vim	2 y	3.7 V/90 µs/170 Hz	+ +/+ +/+
Romanelli et al (2003) ¹⁶	79/M	None	L Vim and STN	2 y	Vim: 4.3 V/90 µs/185 Hz STN: 2.7 V/90 µs/145 Hz	+ +/+ +/+ +
Samadani et al (2003) ¹²	24/M	Midbrain bled cavernoma	L Vim	6 mo	2.5 V/90 µs/185 Hz	+ +/+ +/+ +
Nikkhah et al (2004) ⁸	47/F	R midbrain infarct	R Vim	7 mo	2.4 V/60 µs/130 Hz	+ +/+ +/+ +
Piette et al (2004) ¹¹	32/F	L midbrain and thalamic hematoma	L Vim	6 mo	3.4 V/90 µs/130 Hz	+ +/+ +/+ +
Goto and Yamada (2004) ³²	NA/F	Pons hematoma	R Vim	1.5 y	NA	+ +/+ +/+
Foot et al (2006) ⁵	53/F	Post-traumatic	L Vim + pallidotomy	NA	3.4 V/90 µs/130 Hz	+ +/+ +/+ + Palatal tremor unchanged
Hertel et al (2006) ⁶	24/M	Post-traumatic	R Vim + VOA/VOP	1 y	Vim: 4.1 V/90 µs/135 Hz VOA/VOP: 4 V/90 µs/185 Hz	+ +/+ +/+ +
Lim et al (2007) ²⁴	39/M	Post-traumatic	R Vim + VOA/VOP	6 mo	Vim: 3 V/60 µs/160 Hz VOA/VOP: 3.1 V/60 µs/145 Hz	+ +/+ +/+ +
Diederich et al (2008) ⁴	18/F	Post-traumatic	R Vim + VOA/VOP	8 mo	Vim: 3.6 V/120 µs/185 Hz VOA/VOP: 2.9 V/90 µs/135 Hz	+ +/+ +/+ +
Lim et al (2007) ²⁴	58/M	Midbrain infarct	L Vim	1.5 y	NA	+ +/+ +/+ +
Peker et al (2008) ¹⁰	28/M	Midbrain cavernoma	R GPi + Vim + VOA	8 mo	GPi: 6 V/210 µs/160 Hz Vim: 3.6 V/150 µs/185 Hz VOA: 3.5 V/90 µs/185 Hz	+ / + /+ (with GPi). No additional effect with Vim or VOA
Plaha et al (2008) ¹⁷	84/M	L pons venous angioma	L Vim	7 y	2.3 V/450 µs/130 Hz	+ /+ + /+ +
Sanborn et al (2009) ¹³	49/M	R midbrain hemiatrophy	R Vim	5 y	No stimulation	+ /+ + /-
Acar et al (2010) ³	14/F	Thalamic abscess	R Vim	2.5 y	4.8 V/90 µs/185 Hz	+ + /+ + /+ +
Present report	30/M	Midbrain and pons bled cavernoma	Bilateral cZi	NA	2.48 V/120 µs/147 Hz (mean values)	+ + /+ + /+ +
	31/M	Midbrain cystic degeneration	R Vim	2 y	1.6 V/NA/NA	+ + /+ + /+ +
	31/M	Subarachnoid hemorrhage	Bilateral Vim	NA	NA	+ + /+ + /+ +
	30/M	Midbrain and pons bled cavernoma	R Vim + GPi	6 mo	Vim: 3 V/90 µs/100 Hz GPi: 3 V/210 µs/130 Hz	+ + /+ + /+ +

DBS, deep brain stimulation; RT, resting tremor; PT, postural tremor; IT, intentional tremor; M, male; NA, no additional information; (+), minimal/moderate effect; (++) good/excellent effect; (-), no effect; F, female; Vim, ventral intermediate thalamic nucleus; R, right; L, left; y, year; STN, subthalamic nucleus; mo, month; VOA, ventralis oralis anterior; VOP, ventralis oralis posterior; cZi, caudal zona incerta; GPi, globus pallidus internus.

interpositus, IO, and medial reticular formation (MRF).¹⁷ In the review, our case is considered the second case of HT to be treated with Vim and GPi stimulation. We believe that in addition to Vim stimulation for controlling the distal tremor, GPi target is good choice for controlling the proximal tremor especially for cases accompanied with proximal dystonia, as in our case. The effect of chronic GPi stimulation on the proximal tremor was started to be noticed in the sixth week with marked improvement of this tremor. During this period, the Vim stimulation effect was stable since the operation with significant improvement of the distal tremor. These are the early results of our case and the patient is still under follow-up. We believe that long-term results will be better with established chronic stimulation.

References

- Deuschl G, Raethjen J, Lindemann M, Krack P. The pathophysiology of tremor. *Muscle Nerve* 2001;24(6):716–735
- Gajos A, Bogucki A, Schinwelski M, et al. The clinical and neuro-imaging studies in Holmes tremor. *Acta Neurol Scand* 2010; 122(5):360–366
- Acar G, Acar F, Bir LS, Kizilay Z, Cirak B. Vim stimulation in Holmes' tremor secondary to subarachnoid hemorrhage. *Neurol Res* 2010;32(9):992–994
- Diederich NJ, Verhagen Metman L, Bakay RA, Alesch F. Ventral intermediate thalamic stimulation in complex tremor syndromes. *Stereotact Funct Neurosurg* 2008;86(3):167–172
- Foot KD, Seignourel P, Fernandez HH, et al. Dual electrode thalamic deep brain stimulation for the treatment of posttraumatic and multiple sclerosis tremor. *Neurosurgery* 2006; 58(Suppl 2):ONS280–ONS285
- Hertel F, Züchner M, Decker C, et al. Unilateral Holmes tremor, clearly responsive to cerebrospinal fluid release, in a patient with an ischemic midbrain lesion and associated chronic hydrocephalic ventricle enlargement. Case report. *J Neurosurg* 2006;104(3): 448–451
- Kudo M, Goto S, Nishikawa S, et al. Bilateral thalamic stimulation for Holmes' tremor caused by unilateral brainstem lesion. *Mov Disord* 2001;16(1):170–174
- Nikkhah G, Prokop T, Hellwig B, Lücking CH, Ostertag CB. Deep brain stimulation of the nucleus ventralis intermedialis for Holmes (rubral) tremor and associated dystonia caused by upper brainstem lesions. Report of two cases. *J Neurosurg* 2004;100(6):1079–1083
- Pahwa R, Lyons KE, Kempf L, Wilkinson SB, Koller WC. Thalamic stimulation for midbrain tremor after partial hemangioma resection. *Mov Disord* 2002;17(2):404–407
- Peker S, Isik U, Akgun Y, Ozek M. Deep brain stimulation for Holmes' tremor related to a thalamic abscess. *Childs Nerv Syst* 2008;24(9):1057–1062
- Piette T, Mescola P, Henriot M, Cornil C, Jacquy J, Vanderkelen B. [A surgical approach to Holmes' tremor associated with high-frequency synchronous bursts]. *Rev Neurol (Paris)* 2004;160(6–7): 707–711
- Samadani U, Umemura A, Jaggi JL, Colcher A, Zager EL, Baltuch GH. Thalamic deep brain stimulation for disabling tremor after excision of a midbrain cavernous angioma. Case report. *J Neurosurg* 2003;98(4):888–890
- Sanborn MR, Danish SF, Ranalli NJ, Grady MS, Jaggi JL, Baltuch GH. Thalamic deep brain stimulation for midbrain tremor secondary to cystic degeneration of the brainstem. *Stereotact Funct Neurosurg* 2009;87(2):128–133
- Shepherd GM, Tauböll E, Bakke SJ, Nyberg-Hansen R. Midbrain tremor and hypertrophic olivary degeneration after pontine hemorrhage. *Mov Disord* 1997;12(3):432–437
- Lim DA, Khandhar SM, Heath S, Ostrem JL, Ringel N, Starr P. Multiple target deep brain stimulation for multiple sclerosis related and poststroke Holmes' tremor. *Stereotact Funct Neurosurg* 2007;85(4):144–149
- Romanelli P, Brontë-Stewart H, Courtney T, Heit G. Possible necessity for deep brain stimulation of both the ventralis intermedialis and subthalamic nuclei to resolve Holmes tremor. Case report. *J Neurosurg* 2003;99(3):566–571
- Plaha P, Khan S, Gill SS. Bilateral stimulation of the caudal zona incerta nucleus for tremor control. *J Neurol Neurosurg Psychiatry* 2008;79(5):504–513
- Fahn S, Tolosa E, Marin C. Clinical rating scale for tremor. In: Jankovic J, Tolosa E, eds. *Parkinson's Disease and Movement Disorders*. Baltimore, Munich: Urban & Schwarzenberg; 1988 225–234
- Holmes G. On certain tremors in organic cerebral lesions. *Brain* 1904;27:327–375
- Samie MR, Selhorst JB, Koller WC. Post-traumatic midbrain tremors. *Neurology* 1990;40(1):62–66
- Aisen ML, Holzer M, Rosen M, Dietz M, McDowell F. Glutethimide treatment of disabling action tremor in patients with multiple sclerosis and traumatic brain injury. *Arch Neurol* 1991;48(5): 513–515
- Kitagawa M, Murata J, Kikuchi S, et al. Deep brain stimulation of subthalamic area for severe proximal tremor. *Neurology* 2000; 55(1):114–116
- Kim MC, Son BC, Miyagi Y, Kang JK. Vim thalamotomy for Holmes' tremor secondary to midbrain tumour. *J Neurol Neurosurg Psychiatry* 2002;73(4):453–455
- Masucci EF, Kurtzke JF, Saini N. Myorhythmia: a widespread movement disorder. Clinicopathological correlations. *Brain* 1984;107(Pt 1):53–79
- Remy P, de Recondo A, Defer G, et al. Peduncular 'rubral' tremor and dopaminergic denervation: a PET study. *Neurology* 1995; 45(3 Pt 1):472–477
- Seidel S, Kasprian G, Leutmezer F, Prayer D, Auff E. Disruption of nigrostriatal and cerebellothalamic pathways in dopamine responsive Holmes' tremor. *J Neurol Neurosurg Psychiatry* 2009;80(8):921–923
- Herzog J, Hamel W, Wenzelburger R, et al. Kinematic analysis of thalamic versus subthalamic neurostimulation in postural and intention tremor. *Brain* 2007;130(Pt 6):1608–1625
- Schuurman PR, Bosch DA, Bossuyt PM, et al. A comparison of continuous thalamic stimulation and thalamotomy for suppression of severe tremor. *N Engl J Med* 2000;342(7):461–468
- Iacono RP, Henderson JM, Lonser RR. Combined stereotactic thalamotomy and posteroventral pallidotomy for Parkinson's disease. *J Image Guid Surg* 1995;1(3):133–140
- Shima F, Ishido K, Kato M. [Roles of the basal ganglia outputs in movement disorders: a viewpoint based on experiences of stereotactic surgery for idiopathic dystonia]. *No To Hattatsu* 1997; 29(3):206–212[article in Japanese]
- Miyagi Y, Shima F, Ishido K, Moriguchi M, Kamikaseda K. Posteroventral pallidotomy for midbrain tremor after a pontine hemorrhage. Case report. *J Neurosurg* 1999;91(5):885–888
- Goto S, Yamada K. Combination of thalamic Vim stimulation and Gpi pallidotomy synergistically abolishes Holmes' tremor. *J Neurol Neurosurg Psychiatry* 2004;75(8):1203–1204

Copyright of Journal of Neurological Surgery. Part A. Central European Neurosurgery is the property of Georg Thieme Verlag Stuttgart and its content may not be copied or emailed to multiple sites or posted to a listserv without the copyright holder's express written permission. However, users may print, download, or email articles for individual use.