

# Repeated Injection of Contrast Medium Inducing Dysfunction of the Blood-Brain Barrier

## —Case Report—

Tomonori IWATA,<sup>1</sup> Takahisa MORI,<sup>1</sup> Hiroyuki TAJIRI,<sup>1</sup>  
Yuichi MIYAZAKI,<sup>1</sup> and Masahito NAKAZAKI<sup>1</sup>

<sup>1</sup>Department of Stroke Treatment, Shonan Kamakura General Hospital Stroke Center,  
Kamakura, Kanagawa

### Abstract

An early 60s-year-old man suffered reversible dysfunction of the blood-brain barrier (BBB) induced by repeated injection of contrast medium during coil embolization of intracranial unruptured aneurysm. He presented with convulsion during coil embolization, and neurological symptoms of aphasia and right hemiparesis continued for 5 days, and then improved completely. All transient radiological abnormalities were limited to the territory of the left internal carotid artery, where contrast medium was injected repeatedly. Repeated computed tomography, magnetic resonance imaging, single-photon emission computed tomography, and cerebrospinal fluid test findings indicated that temporary dysfunction of the BBB might have occurred. Dysfunction of the BBB in the anterior circulation induced by contrast medium is rare. Tolerance to toxicity of contrast medium may depend on the individual patient, and repeated injection of contrast medium may cause dysfunction of the BBB, leading to toxic dysfunction directly in the brain.

Key words: blood-brain barrier, coil embolization, contrast medium

### Introduction

Contrast medium is known to carry the risk of inducing dysfunction of the blood-brain barrier (BBB) in posterior circulation after coil embolization,<sup>3-5)</sup> but few cases in the anterior circulation have been confirmed by computed tomography (CT), magnetic resonance (MR) imaging, and single-photon emission computed tomography.<sup>6)</sup> We report an unusual case of a patient with probable dysfunction of the BBB induced by repeated injection of contrast medium.

### Case Report

An early 60s-year-old man underwent brain check with MR imaging, which showed an intracranial unruptured aneurysm. There was no history of allergic reactions to contrast medium. He underwent cerebral angiography, which demonstrated a saccular aneurysm (9 × 9 × 7 mm) in the anterior communicating artery (Fig. 1A). Coil embolization was started under local anesthesia and left internal carotid angiography was repeated. Systemic convulsion occurred during injection of a total of 72 ml iopamidol (300 mg/ml) into the left internal carotid artery (ICA). Left internal carotid angiography just after ictus demonstrated neither intracranial artery occlusion nor an-

giographic aneurysm rupture. Therefore, coil embolization was continued and completed under sedation. After all the procedures were completed (Fig. 1B), a total of 120 ml iopamidol was injected into the left ICA over 2 hours. CT immediately after the procedures showed neither intracerebral hemorrhage nor subarachnoid hemorrhage, but demonstrated moderate enhancement in the territory

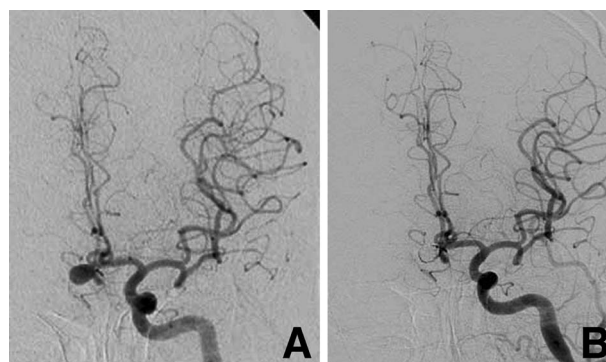
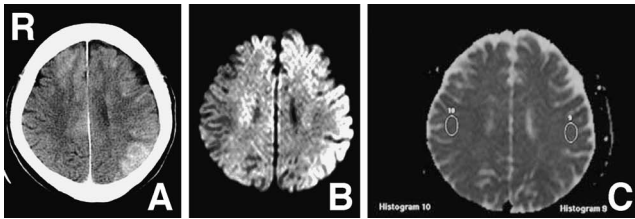
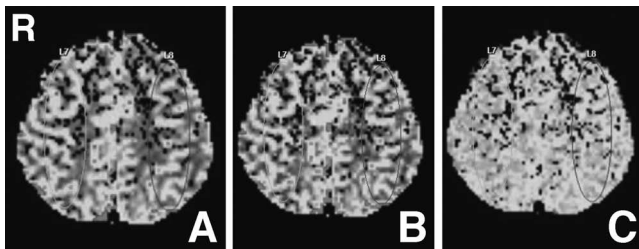


Fig. 1 A: Left internal carotid angiogram (anteroposterior projection) showing an unruptured intracranial saccular aneurysm (9 × 9 × 7 mm) in the anterior communicating artery. B: Left internal carotid angiogram (anteroposterior projection) showing complete obliteration of the embolized aneurysm.



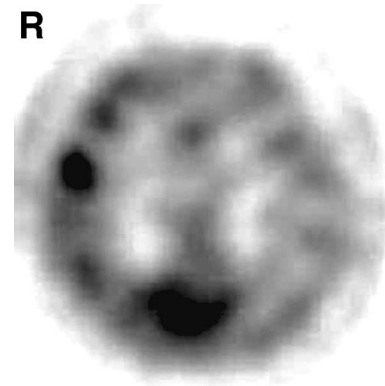
**Fig. 2** A: Brain computed tomography scan immediately after the procedures showing moderate enhancement in the territory of the left internal carotid artery. B: Diffusion-weighted magnetic resonance image 20 hours after the procedures showing high intensity in the territory of the left internal carotid artery. C: Apparent diffusion coefficient map 20 hours after the procedures showing no low or high intensity in the territory of the left internal carotid artery.



**Fig. 3** Perfusion-weighted magnetic resonance images 20 hours after the procedures demonstrating no abnormalities. A: Relative cerebral blood flow showing no reduction in the territory of the left internal carotid artery. B: Relative cerebral blood volume showing no decrease in the territory of the left internal carotid artery. C: Relative mean transit time showing no delay in the territory of the left internal carotid artery.

of the bilateral anterior cerebral arteries and the left middle cerebral artery, i.e., in the territory of the left ICA (Fig. 2A). His level of consciousness continued to be disturbed after the procedures. Some inflammatory changes may have occurred, so methylprednisolone pulse therapy and antiepileptic drug administration were started.

Diffusion-weighted imaging 20 hours after the procedures showed high intensity in the territory of the left ICA (Fig. 2B). The apparent diffusion coefficient map displayed no low or high intensity in the territory of the left ICA (Fig. 2C). MR angiography showed no intracranial artery occlusion. Perfusion-weighted imaging demonstrated normal blood flow in the territory of the left ICA (Fig. 3). Technetium-99m ethyl cysteinate dimer single-photon emission computed tomography 27 hours after the procedures showed reduced or impaired uptake of radioisotopes in the territory of the left ICA (Fig. 4). Cerebrospinal fluid (CSF) tap test about 24 hours after the procedures showed the CSF pressure was elevated (25 cmH<sub>2</sub>O) and found pleocytosis (cell 7/mm<sup>3</sup>, polymorphonuclear cell 6/mm<sup>3</sup>). Disturbed level of consciousness and right hemiparesis continued for 5 days following the procedures but improved completely within 7 days. CT, diffusion-weighted imaging, single-photon emission com-



**Fig. 4** Technetium-99m ethyl cysteinate dimer single-photon emission computed tomography scan 27 hours after the procedures showing reduced or impaired uptake of radioisotopes in the territory of the left internal carotid artery.

puted tomography, and CSF tap test were performed again and showed no abnormal findings.

## Discussion

All transient radiological abnormalities in our case were limited to the territory of the left ICA, where contrast medium was injected repeatedly. Just after coil embolization, CT showed extensive enhancement in the territory of the left ICA, indicating that the BBB had allowed leakage of the contrast medium. Diffusion-weighted imaging showed extensive high intensity, single-photon emission computed tomography showed reduced uptake of radioisotopes in the same territory, and the CSF tap test indicated abnormal findings, suggesting that neuronal edema might have occurred, resulting in dysfunction or disruption of neurons. These abnormal findings cannot be explained by status epilepticus since perfusion-weighted imaging often shows increase at the ictus focus, even though diffusion-weighted imaging often shows cortical high intensity in patients with status epilepticus.<sup>7)</sup> In addition, the findings cannot be explained by extensive cerebral infarcts since no occlusion of any branches of the left ICA was detected and perfusion-weighted imaging demonstrated normal intravascular blood flow in its territory. Considering all findings, toxic encephalopathy caused by the contrast medium might have occurred in the territory where contrast medium was injected repeatedly. Contrast medium might induce dysfunction of the BBB, increase the permeability of the BBB, pass through the BBB, and cause toxic changes directly in the brain.<sup>9)</sup> If the toxicity is too high, changes in the brain may be irreversible.<sup>4,5)</sup>

We cannot explain why the convulsion occurred during the procedures. Indeed, abandoning the procedures and performing immediate CT to confirm absence of intracranial hemorrhage might be an option, but partial embolization of the aneurysm might also lead to aneurysm rupture or parent artery occlusion, and will probably limit subsequent treatment. Left internal carotid angiography

just after ictus demonstrated neither intracranial artery occlusion nor angiographic aneurysm rupture, and the ictus stopped after injection of diazepam. Therefore, after controlling the ictus, we continued and completed all procedures within 2.5 hours. Switching treatment from embolization to clipping seemed dangerous because we had no idea of why the convulsion occurred.

Convulsion, disturbance of consciousness level, and cortical blindness are known just after CT or angiography.<sup>1-3,6)</sup> However, why contrast medium causes these complications remains unknown. In cases of systemic administration of contrast medium (350 or 370 mg/ml), a total of 300 to 400 ml contrast medium was administered within a few minutes,<sup>2)</sup> whereas in cases of coil embolization, a total of 50 to 300 ml contrast medium (300 mg/ml) was injected selectively within a few hours.<sup>3-5)</sup> In cases of systemic administration, 300 ml or more contrast medium may be the threshold level of toxicity, whereas in cases of intracranial selective injection, a smaller volume may cause toxicity for the BBB, although the toxic tolerance of the BBB depends on the individual patient.<sup>8)</sup> Therefore, the range to cause toxicity is from 50 ml to 300 ml of contrast medium. In our case, administration of only 72 ml of contrast medium was sufficient to cause toxicity, dysfunction of the BBB, and changes in the brain.<sup>4,8)</sup>

This unusual case of contrast medium inducing dysfunction of the BBB in the anterior circulation during coil embolization of an intracranial unruptured aneurysm was confirmed by repeated CT, MR imaging, and single-photon emission computed tomography. Tolerance to toxicity of contrast medium probably depends on the individual patient, but repeated injection of contrast medium may cause dysfunction of the BBB, pass through the BBB, and lead to toxic changes directly in the brain.

### Conflicts of Interest Disclosure

The authors have no personal financial or institutional interest in any of the drugs, materials, or devices in the article. All authors who are members of The Japan Neurosurgical Society (JNS) have registered online Self-reported COI Disclosure Statement Forms through the website for JNS members.

### References

- 1) Lantos G: Cortical blindness due to osmotic disruption of the blood-brain barrier by angiographic contrast material: CT and MRI studies. *Neurology* 39: 567-571, 1989
- 2) Merchut MP, Richie B: Transient visuospatial disorder from angiographic contrast. *Arch Neurol* 59: 851-854, 2002
- 3) Mutoh T, Ishikawa T, Sawada M, Moroi J, Tamakawa N, Hikichi K, Suzuki A, Yasui N: [Cerebral complications induced by neurotoxicity of nonionic contrast medium after embolization of unruptured cerebral aneurysms: reports of 2 cases]. *No Shinkei Geka* 38: 163-170, 2010 (Japanese)
- 4) Niimi Y, Kupersmith MJ, Ahmad S, Song J, Berenstein A: Cortical blindness, transient and otherwise, associated with detachable coil embolization of intracranial aneurysms. *AJNR Am J Neuroradiol* 29: 603-607, 2008
- 5) Shinoda J, Ajimi Y, Yamada M, Onozuka S: Cortical blindness during coil embolization of an unruptured intracranial aneurysm—case report. *Neurol Med Chir (Tokyo)* 44: 416-419, 2004
- 6) Sticherling C, Berkefeld J, Auch-Schwelk W, Lanfermann H: Transient bilateral cortical blindness after coronary angiography. *Lancet* 351: 570, 1998
- 7) Szabo K, Poepel A, Pohlmann-Eden B, Back T, Sedlaczek O, Hennerici M, Gass A: Diffusion-weighted and perfusion MRI demonstrates parenchymal changes in complex partial status epilepticus. *Brain* 128: 1369-1376, 2005
- 8) Uchiyama Y, Abe T, Hirohata M, Tanaka N, Kojima K, Nishimura H, Norbash AM, Hayabuchi N: Blood brain-barrier disruption of nonionic iodinated contrast medium following coil embolization of a ruptured intracerebral aneurysm. *AJNR Am J Neuroradiol* 25: 1783-1786, 2004
- 9) Zlokovic BV, Skundric DS, Segal MB, Colover J, Jankov RM, Pejnovic N, Lackovic V, Mackic J, Lipovac MN, Davson H: Blood-brain barrier permeability changes during acute allergic encephalomyelitis induced in the guinea pig. *Metab Brain Dis* 4: 33-40, 1989

---

Address reprint requests to: Takahisa Mori, MD, PhD, Department of Stroke Treatment, Shonan Kamakura General Hospital Stroke Center, 1370-1 Okamoto, Kamakura, Kanagawa 247-8533, Japan.  
e-mail: morit-koc@umin.net