

Bilateral Acute Necrosis of the Globi Pallidi and Rhabdomyolysis Due to Combined Methadone and Benzodiazepine Toxicity

Robert F. Corliss, MD,* Rakesh Mandal, MBBS, MS, MPH,† and Benjamin J. Soriano, MD*

Abstract: Methadone continues to be a widely used maintenance therapy for opiate dependence. However, methadone-related deaths have been reported frequently for over 4 decades now. Anoxic brain injury with pulmonary edema secondary to respiratory depression is the recognized mechanism of methadone death, although pathological intracranial findings are rarely described in methadone deaths. A selective area of brain injury has never been reported with methadone use. We present a case of a 23-year-old man who had acute necrosis of the bilateral globi pallidi in the brain and systemic rhabdomyolysis after ingesting methadone and nasally insufflating alprazolam. We also present a review of the literature on deaths following opioid use and associated brain injury.

Key Words: methadone toxicity, benzodiazepine toxicity, globus pallidus injury, rhabdomyolysis, opioid death

(*Am J Forensic Med Pathol* 2013;34: 1–4)

Reports related to methadone deaths have been accumulating over the past 40 years.^{1,2} Mikolaenko et al³ reported 101 deaths related to methadone, and 60 deaths among those had co-intoxication with methadone and benzodiazepines. Caplehorn⁴ found most of the methadone-related deaths occurring within the first 2 weeks of methadone maintenance therapy. A review by Corkery et al⁵ attributed these early maintenance therapy deaths potentially to methadone's longer half-life and lack of cross-tolerance with other opioids.

Selective brain injury induced by multiple compounds has been described in both forensic and neuropathologic literatures; examples include isolated lesions of the putamen following methanol ingestion⁶ and necrosis of the globi pallidi due to carbon monoxide toxicity.⁷ Selective pallidal lesions have also been described in heroin addicts.⁸ We describe isolated bilateral acute necrosis of the globi pallidi in a patient who used methadone and benzodiazepine concomitantly.

CASE REPORT

A 23-year-old white man was found unconscious and unresponsive lying on his bed by his girlfriend. He was found pulseless

and breathless by emergency medical personnel. He was resuscitated and taken to a local emergency department and then airlifted to a regional tertiary care facility within 2 hours of being discovered. An emergency admission urine drug screen was positive for methadone, benzodiazepines, and cannabinoids. Clinical evaluation revealed multiorgan failure with likely anoxic brain injury and rhabdomyolysis (total creatine kinase, 25,541 U/L) with acute kidney injury (blood urea nitrogen, 28 mg/dL; creatinine, 3.4 mg/dL). An infection workup performed during that time was negative. His Glasgow Coma Scale score was 3, and pupils were narrow and fixed with no pupillary or corneal reflexes. Approximately 24 hours after initial presentation, given his poor prognosis, life support measures were withdrawn. He died shortly thereafter, and the autopsy was performed the following day (22 hours after death pronouncement).

History obtained from medical records and the decedent's girlfriend indicated multiple years of polysubstance abuse including alcohol, heroin, methadone, and other drugs. He had recently been incarcerated for 12 days. The day following his release, he reportedly nasally insufflated 3 mg of alprazolam and ingested 40 mg of methadone, both of which he had obtained illicitly. The following morning, approximately 1 hour before being discovered unresponsive, he was witnessed to be alive and snoring by his girlfriend.

Autopsy Findings

The external examination was negative for any acute injury or evidence of any recent or remote intravenous drug use. The brain revealed bilateral brown and mottled cystic degeneration of the globi pallidi, which were soft and friable on cut surfaces (Fig. 1). No other gray or white matter lesions were present grossly. Pulmonary edema was identified (combined lung weight = 1460 g), and kidneys showed dotlike, pale-yellow corticomedullary lesions. Gastric content was viscous brown fluid, which did not contain pills or pill sediment on thorough examination.

Histological Findings

The hematoxylin-eosin-stained sections of the basal ganglia revealed acute necrosis with a "punched out" cystic type separation of the globus pallidus from the surrounding intact parenchyma on low power (Fig. 2). Acute hypoxic/ischemic-type neuronal injury, hypereosinophilic acute neuropil degeneration, and focal acute hemorrhages were identified on high-power examination (Fig. 3). Histopathologic neuronal injury consisting of darkening and shrinkage is nonspecific and, although usually due to hypoxic/ischemic insult, may be a manifestation of toxic or metabolic injury as well.

Concentric vascular siderocalcinosis was identified in the lentiform nuclei bilaterally as well, although no evidence of recent or remote infarct, hemorrhage, or gliosis was observed. Mild to moderate hypoxic/ischemic neuronal changes were identified in the

Manuscript received May 11, 2011; accepted September 2, 2011.
From the *Department of Pathology and Laboratory Medicine and †Waisman Center, University of Wisconsin, Madison, WI.
The authors report no conflicts of interest.
Reprints: Robert F. Corliss, MD, Department of Pathology and Laboratory Medicine, 600 Highland Ave, University of Wisconsin, Madison, WI 53792. E-mail: RCorliss@uwhealth.org.
Copyright © 2013 by Lippincott Williams & Wilkins
ISSN: 0195-7910/13/3401-0001
DOI: 10.1097/PAF.0b013e31823a8b1e

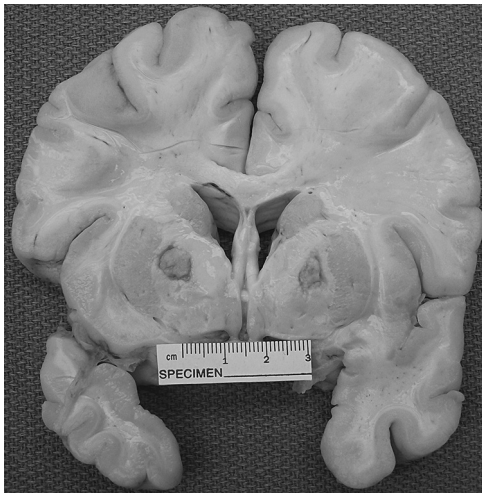


FIGURE 1. Coronal brain section showing bilateral and symmetric cystic degeneration of the globi pallidi.

cerebellar piriform cells, hippocampi, and frontal cortex, although acute necrosis or hemorrhage was notably absent in these areas. Microscopic examination of the kidneys revealed pigmented cast in the tubules consistent with rhabdomyolysis (Fig. 4).

Toxicological Findings

A urine toxicology screen performed by an outside emergency department was positive for cannabinoids, benzodiazepines, and methadone. Hospital admission blood and autopsy vitreous samples were sent to the American Institute of Toxicology (AIT Laboratories) in Indianapolis, Ind, for additional testing. Blood methadone level was reported at 154 ng/mL (therapeutic range, 50–1000 ng/mL), alprazolam level was 14.1 ng/mL (therapeutic range, 10–40 ng/mL), and blood was also positive for the cannabinoid carboxy-tetrahydrocannabinol at 5.9 ng/mL. The methadone metabolite 2-ethylidene-1,5-dimethyl-3,3-diphenylpyrrolidine was not detected. Blood carbon monoxide and other comprehensive drug panel tests

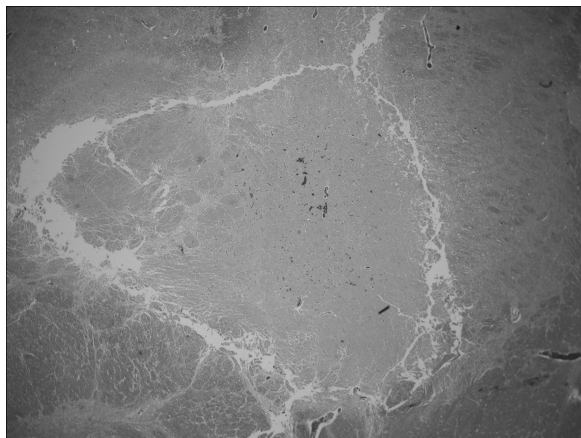


FIGURE 2. Low-power hematoxylin-eosin-stained section showing cystic “punched out” appearance of globus pallidus, which also displays pallor, vascular congestion, and focal hemorrhages.

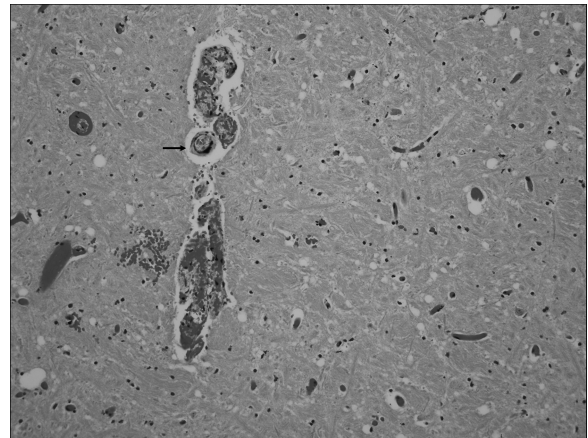


FIGURE 3. High-power view of globus pallidus showing acute injury including shrunken, “ghosted” neurons, hypereosinophilic neuropil degeneration, and vascular congestion with focal acute blood extravasation. Concentric vascular siderocalcinosis (arrow) is also identified.

including amphetamines, fentanyl, opiates, ethanol, barbiturates, analgesics, anticonvulsants, antidepressants, and antipsychotics were negative. Blood and vitreous samples were negative for alcohols.

DISCUSSION

As methadone-related deaths are frequently encountered in our and many forensic practices, methadone and/or benzodiazepine toxicity was not unexpected as the cause of death in the present case. The selective acute injury of bilateral globi pallidi was, however, unexplained. This finding raised the question as to whether mixed drug toxicity with methadone and benzodiazepines, or other metabolic dysregulation, in this patient provided a toxic mechanism for this selective brain damage.

Our literature review did not yield any case report of isolated globi pallidi injury with the use of methadone and alprazolam. However, selective globi pallidi injury, with or without injury

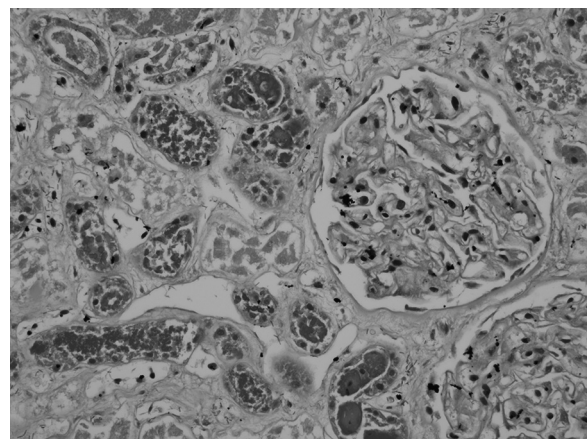


FIGURE 4. Hematoxylin-eosin-stained kidney section showing prominent intraluminal granular tubular casts consistent with the clinical diagnosis of rhabdomyolysis. Autolytic changes and postmortem bacterial overgrowth are evident, although inflammatory infiltrates are notably absent.

to other brain areas, has been described with the use of heroin and heroin and methadone combined (Table 1). Hsu et al⁹ reported a case of rhabdomyolysis and brain ischemic stroke in a 33-year-old heroin-dependent man under methadone maintenance therapy. They reported “old brain damage in the bilateral globus pallidus” on magnetic resonance imaging in their patient with acute ischemic strokes in the bilateral corona radiatae and frontoparietotemporal white matter. De Roock et al¹⁰ reported a case of cocaine use and globi pallidi injury, but the patient was also positive for recent methadone use. Isolated injury of globi pallidi or pallidal injury combined with other brain area injury has also been described with carbon monoxide toxicity,⁷ but the present case has a negative history, as well as a blood test negative for carbon monoxide. The topographically restricted bilateral pallidal injury is rarely reported, and we think this varies depending on how long an individual survives following drug intake. For example, although globi pallidi injury may be occurring first, in cases with rapid-onset respiratory depression, anoxic brain injury, and death, gross and histopathologic changes of acute injury may not have time to develop.

Given the absence of significant natural disease processes, the prominent and acute selective bipallidal lesions in the decedent were attributable only to the recent methadone and/or benzodiazepine ingestion in some way. The known mechanism of opioid fatality includes respiratory depression resulting in pulmonary edema, hypoxia, and death. This sequence occurs following opioid receptor-mediated inhibition of central respiratory drive and decreased chemoreceptor sensitivity. A reduction in tidal volume is seen with low concentrations of exogenous opioids, with both tidal volume and respiratory rate falling at higher concentrations.¹¹ Although protracted respiratory depression fatalities due to opioid toxicity are well known, with evident hypoxic neuronal injury and even early bronchopneumonia development, isolated or relatively prominent selective acute injury to the globus pallidus has not been reported. The literature does suggest pallidal injury with chronic heroin use. Although the decedent in this case has a history of heroin abuse in the past, remote pallidal injury is not evident, and these lesions were clearly acute.

Both methadone and heroin are opioids, and they act through binding on μ -, κ -, and δ -opioid receptor subtypes.¹¹ Methadone is highly lipid soluble, and it can be readily absorbed in the brain. Its metabolism is unpredictable and complex with median half-life of 128 hours at the start of treatment in opioid addicts.¹² Methadone alone appears insufficient to cause selective acute brain injury, as this finding has not been reported in fatalities where

methadone was the sole substance detected. A study by Pearson et al¹³ included 11 brains from heroin addicts and described consistent reduction of neurons in the globi pallidi; 3 of their cases had methadone present in addition to heroin. This is consistent with direct neuronal toxicity, as both drugs have similar chemical properties and receptor-mediated actions, which may be causing injury in the same anatomic region. A direct toxicity hypothesis is further supported by the fact that, in several other cases of protracted respiratory depression and systemic hypoxia, isolated globus pallidus injury has not been reported. As the opioids inhibit the respiratory centers, it is biologically plausible that they could adversely affect other brain regions as well. Future studies may elucidate if the globus pallidus is a site of predilection for binding or toxicity of methadone or heroin. Other emerging mechanisms of methadone death, such as the disruption of cardiac conduction system,¹⁴ also suggest that methadone may have additional toxic properties.

Contrary to the direct toxicity hypothesis, case reports of globus pallidus injury with barbiturates, methanol, carbon monoxide intoxication, and even with high-altitude mountain climbing¹⁵ suggest that the common phenomenon in these deaths may be hypoxia-ischemia induced by cerebral edema, with subsequent compression of the pallidal branch of the anterior choroidal artery as suggested by Lindenberg.¹⁶ However, in our case, there was no evidence of significant cerebral edema, brain swelling, tentorial impression, or uncal herniation.

The therapeutic range of methadone is wide, ranging over an entire magnitude of power, and lethal doses can vary widely between individuals. In methadone-related deaths, lethal blood methadone levels in those without a history of treatment have been reported to be lower compared with those undergoing treatment (mean, 0.43 vs 0.62 $\mu\text{g/mL}$).¹⁷ In another study, the fatal mean blood concentration in those not undergoing treatment was found to be almost half that of those in treatment programs (0.27 vs 0.47 $\mu\text{g/mL}$).¹⁸ This may be due to relative lack of tolerance in nonmaintenance patients or selection bias of illicit and inappropriate use in the nontreatment groups. Low plasma concentrations in some fatal cases may in part be due to the highly lipophilic property of methadone that allows it to quickly disperse into tissues.¹⁹ The blood methadone level in the present case was much lower (0.154 $\mu\text{g/mL}$) than either reported nontreatment group, suggesting a possible mixed drug toxicity or other metabolic dysregulation. Benzodiazepine potentiation and rhabdomyolysis are potential contributing factors in this case. Although the respiratory inhibitory effect of opioids is mediated via μ and

TABLE 1. Brain Lesions in Addition to Globus Pallidal Lesions in Patients With Substance Abuse

Reference	Drugs/Compounds	Areas of Brain Injury	No. Cases	Age, yr/Sex
Present case	Methadone + alprazolam	Acute GP only	1	23, M
Hsu et al ⁹	Heroin + methadone maintenance	GP and cerebral ischemic infarction	1	33, M
Anderson and Skullerud ⁸	Heroin	GP only	5	—
Anderson and Skullerud ⁸	Heroin	Acute GP and diffuse hypoxic ischemic damage	2	—
Anderson and Skullerud ⁸	Heroin	Acute GP and old cerebellar infarct	1	—
Anderson and Skullerud ⁸	Heroin	GP and bilateral hippocampal sclerosis	1	—
Pearson et al ¹³	Heroin + methadone	Neuronal depletion in GP	3	—
Pearson et al ¹³	Heroin	Neuronal depletion in GP	8	—
De Roock et al ¹⁰	Cocaine + methadone + heroin	GP, corpus callosum, and white matter	1	46, M
Cottencin et al ²⁵	Methadone + smoked heroin	GP and Frontal brain	1	38, M

Cases from the literature review and present case.

GP indicates globus pallidus.

possibly δ receptors, benzodiazepines have been described to potentiate this inhibition, mediated by activation of GABA_A receptors. GABA_A receptors are ligand-gated chloride ion channels which are allosterically regulated by several compounds including benzodiazepines. GABA receptor activation produces central inhibition in the physiologic respiratory cycle. Synergistic or additive central respiratory depression may well result from the combined inhibitory effects of opioid binding at μ receptors and benzodiazepine binding of GABA_A receptors.¹¹ In addition, benzodiazepines, like many other drugs, have been found to interfere with hepatic methadone metabolism.²⁰ When methadone is used in combination with other drugs, its effects may be diminished or potentiated as the drugs can compete for the same receptors in the brain or microsomes of methadone metabolism in the liver such as CYP3A4, CYP2C9, and CYP2C19.^{21,22}

The present case also had rhabdomyolysis as manifested by the acute renal failure, elevated creatine kinase, hyperkalemia, and myoglobin casts in the kidney. Rhabdomyolysis and acute renal failure attributed to methadone have been reported in the past.^{9,23} Rhabdomyolysis is known to occur with traumatic or nontraumatic muscle injury, drugs and toxins, infections, and electrolyte disorders, but it has not been reported to cause selective brain damage in isolation. Hypotheses to explain rhabdomyolysis in opioid toxicity include vascular insufficiency and muscle compression due to prolonged immobility and direct myotoxic effects of drugs.⁹ Similarly, benzodiazepines have also been reported to produce rhabdomyolysis. The use of cannabinoids in this patient was recent, although cannabinoids have been reported to be neuroprotective²⁴ and have not been shown to cause rhabdomyolysis.

CONCLUSIONS

Although methadone continues to be a widely used maintenance therapy for opiate dependence, its use in combination with benzodiazepines, heroin, or other addictive substances is harmful and may have fatal outcomes. Besides the known respiratory depression effect of methadone, our case study and literature review suggest potential mechanisms leading to acute and prominent globus pallidus injury. Future studies are needed to elucidate the process of globus pallidus injury with methadone and benzodiazepine cointoxication and to see if it is mediated through pure hypoxic or ischemic effects, direct neuronal toxicity, or systemic metabolic complications such as rhabdomyolysis.

REFERENCES

1. Baden MM. Methadone related deaths in New York City. *Int J Addict*. 1970;5:489–498.
2. Gardner R. Methadone misuse and death by overdosage. *Br J Addict Alcohol Other Drugs*. 1970;65:113–118.
3. Mikolaenko I, Robinson CA Jr, Davis GG. A review of methadone deaths in Jefferson County, Alabama. *Am J Forensic Med Pathol*. 2002;23:299–304.
4. Caplehorn JR. Deaths in the first two weeks of maintenance treatment in NSW in 1994: identifying cases of iatrogenic methadone toxicity. *Drug Alcohol Rev*. 1998;1:9–17.
5. Corkery JM, Schifano F, Ghodse AH, et al. The effects of methadone and its role in fatalities. *Hum Psychopharmacol*. 2004;19:565–576.
6. Pelletier J, Habib MH, Khalil R, et al. Putaminal necrosis after methanol intoxication. *J Neurol Neurosurg Psychiatry*. 1992;55:234–235.
7. Hopkins RO, Fearing MA, Weaver LK, et al. Basal ganglia lesions following carbon monoxide poisoning. *Brain Inj*. 2006;3:273–281.
8. Andersen SN, Skullerud K. Hypoxic/ischaemic brain damage, especially pallidal lesions, in heroin addicts. *Forensic Sci Int*. 1999;102(1):51–59.
9. Hsu WY, Chiu NY, Liao YC. Rhabdomyolysis and brain ischemic stroke in a heroin-dependent male under methadone maintenance therapy. *Acta Psychiatr Scand*. 2009;120(1):76–79.
10. De Roock S, Hantson P, Laterre PF, et al. Extensive pallidal and white matter injury following cocaine overdose. *Intensive Care Med*. 2007;33:2030–2031.
11. White JM, Irvine RJ. Mechanisms of fatal opioid overdose. *Addiction*. 1999;94:961–972.
12. Wolff K, Rostami-Hodjegan A, Hay AW, et al. Population-based pharmacokinetic approach for methadone monitoring of opiate addicts: potential clinical utility. *Addiction*. 2000;95:1771–1783.
13. Pearson J, Baden MB, Richter RW. Neuronal depletion in the globus pallidus of heroin addicts. *Drug Alcohol Depend*. 1976;5:349–356.
14. Wu CH, Henry JA. Deaths of heroin addicts starting on methadone maintenance. *Lancet*. 1990;335:424.
15. Jeong JH, Kwon JC, Chin J, et al. Globus pallidus lesions associated with high mountain climbing. *J Korean Med Sci*. 2002;17:861–863.
16. Lindenberg R. Compression of brain arteries as pathogenetic factor for tissue necroses and their areas of predilection. *J Neuropathol Exp Neurol*. 1955;14:223–243.
17. Heinemann A, Iwersen-Bergmann S, Stein S, et al. Methadone-related fatalities in Hamburg 1990–1999: implications for quality standards in maintenance treatment? *Forensic Sci Int*. 2000;113(1–3):449–455.
18. Worm K, Steentoft A, Kringsholm B. Methadone and drug addicts [in Danish]. *Ugeskr Laeger*. 1993;155:2245–2247.
19. Dole VP, Kreek MJ. Methadone plasma level: sustained by a reservoir of drug in tissue. *Proc Natl Acad Sci U S A*. 1973;70:10.
20. Spaulding TC, Minium L, Kotake AN, et al. The effect of diazepam on the metabolism of methadone by the liver of methadone-dependent rats. *Drug Metab Dispos*. 1974;2:458–463.
21. Maurer PM, Bartkowski RR. Drug interactions of clinical significance with opioid analgesics. *Drug Saf*. 1993;8:30–48.
22. Karch SB, Stephens BG. Toxicology and pathology of deaths related to methadone: retrospective review. *West J Med*. 2000;172:11–14.
23. Hojs R, Sinkovic A. Rhabdomyolysis and acute renal failure following methadone abuse. *Nephron*. 1992;62:362.
24. Alvarez FJ, Lafuente H, Rey-Santano MC, et al. Neuroprotective effects of the nonpsychoactive cannabinoid cannabidiol in hypoxic-ischemic newborn piglets. *Pediatr Res*. 2008;64:653–658.
25. Cottencin O, Guardia D, Warembourg F, et al. Methadone overdose, auto-activation deficit, and catatonia: a case study. *Prim Care Companion J Clin Psychiatry*. 2009;11:275–276.