

## CASE REPORT

# Stroke due to typical thrombotic thrombocytopenic purpura treated successfully with intravenous thrombolysis and therapeutic plasma exchange

Matteo Boattini,<sup>1</sup> Gaetano Procaccianti<sup>2</sup>

<sup>1</sup>Department of Internal Medicine, Santa Marta's Hospital, Lisbon, Portugal  
<sup>2</sup>Stroke Unit, Ospedale Maggiore, IRCCS, Bologna, Italy

**Correspondence to**  
 Dr Matteo Boattini,  
 matteoboattini@gmail.com

## SUMMARY

We report a case of a 39-year-old man with expressive aphasia due to occlusion of the temporal stem of the left middle cerebral artery. Laboratory tests showed microangiopathic haemolytic anaemia and thrombocytopenia. A thrombotic thrombocytopenic purpura (TTP) was diagnosed, and thrombolytic therapy (TT) with alteplase followed by therapeutic plasma exchange (TPE) were performed with complete resolution of symptoms. The gold standard TTP treatment is TPE, and its delay can be lethal. The use of TT in TTP is controversial and has potential risks. This case shows a successful TT in a patient with typical TTP presenting as a stroke due to a large cerebral artery occlusion.

## BACKGROUND

Thrombotic thrombocytopenic purpura (TTP) is an uncommon and severe disease with an incidence of 3.7 cases/million /year in adults.<sup>1</sup> Ischaemic stroke has been reported as a consequence of TTP.<sup>2–4</sup> However, strokes due to a large cerebral artery occlusion (LCAO) are rare in patients with TTP.<sup>2</sup> Standard TTP treatment is therapeutic plasma exchange (TPE). The prognosis is generally good when TTP is diagnosed early. Thrombolytic therapy (TT) is of proven benefit for selected patients with acute cerebral ischaemia,<sup>5</sup> and its use has been reported only in atypical TTP with normal platelet count.<sup>2–4</sup> We report a case of a patient with typical TTP (tTTP) and a stroke due to LCAO whose neurological deficits recovered after combined TT and TPE.

Can TT have contributed to TPE in saving brain parenchyma and vessels in this case of tTTP presenting with a stroke due to LCAO?

## CASE PRESENTATION

A previously healthy 39-year-old man was referred to our Stroke Unit for headache, sudden speaking difficulty and right limbs paresthesias started in the preceding 90 min. He did not smoke, drink alcohol or use any drug. His family history was negative for premature strokes or thrombotic disorders. On examination, he presented with expressive aphasia; National Institute of Health Stroke Score (NIHSS) was 4. Blood pressure was 130/70mm Hg pulse rate 88 bpm, respiratory rate 16/min and temperature 38.3°C. The air oxygen saturation was 98%.

## INVESTIGATIONS

Brain CT did not show any sign of ischaemia or haemorrhage. CT angiography showed normal carotids and vertebral arteries but revealed occlusion of the temporal stem of the left middle cerebral artery (TSLMCA; figure 1A, white arrow). Haemoglobin was 7.4 g/dl (normal values, 14–16), white blood cells WBC count 11 830/mm<sup>3</sup> (4 200–9000), platelet count 27 000/mm<sup>3</sup> (130 000–450 000), D-dimer 394 µg/l (<280), international normalised ratio (INR) 1.16, total bilirubin 1.35 mg/dl (0.1–1.0), indirect bilirubin 1.16 mg/dl (<0.80), aspartate aminotransferase (AST) 47 U/l (<38), lactate dehydrogenase (LDH) 2058 U/l (<480), C reactive protein (CRP) 1.21 mg/dl (<0.50), erythrocyte sedimentation rate 2 mm/h (<20), glycosylated haemoglobin HbA1c 4.9% (<6.1). Renal function, electrolytes, urinalysis, lipid profile, serum iron, ferritin, transferrin and homocysteine were normal. Reticulocyte count was elevated. Peripheral blood smear showed schistocytes; Coombs test was negative. Serum tests for antinuclear, anti-DNA, anti-Sm, anti-RNP, anticardiolipin antibody titres and lupus anticoagulants were negative. HIV, hepatitis B virus (HBV) and hepatitis C virus (HCV) serology were negative as well.

## DIFFERENTIAL DIAGNOSIS

There was no history of bloody diarrhoea or recent infection. He was not on any drug.

A diagnosis of tTTP was made, based on microangiopathic haemolytic anaemia (MAHA), thrombocytopenia, fever and stroke. In a young patient with no atherosclerotic risk factors who presents with stroke and thrombocytopenia, differential diagnosis includes vasculitis, antiphospholipid syndrome, infections, toxic drugs and thrombophilia.<sup>2</sup>

## TREATMENT

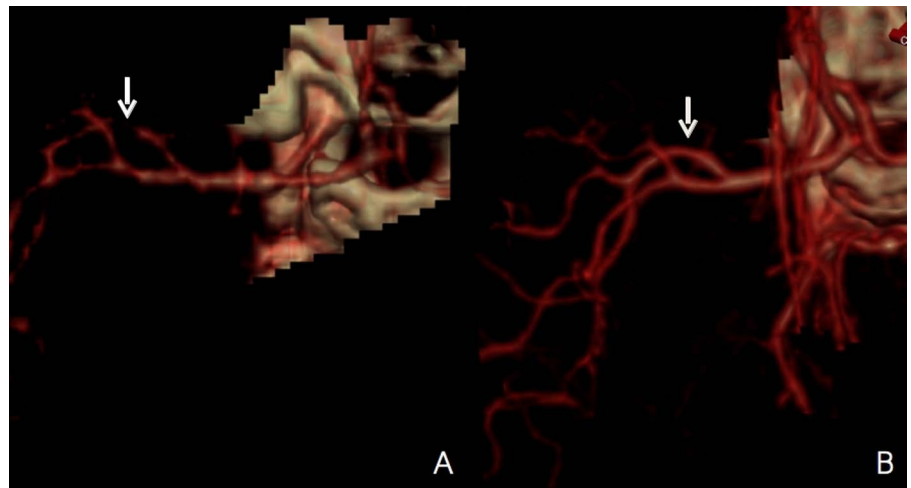
Informed consent was obtained, and intravenous TT with alteplase was performed 100 min after the onset of symptoms. The paresthesias of the right limbs resolved, and TPE was performed after 6 h. The patient's conditions improved over the next 24 h (NIHSS=0) and CT angiography on day 7 showed complete recanalisation of the TSLMCA (figure 1B, white arrow) and no sign of ischaemia or haemorrhage.

## OUTCOME AND FOLLOW-UP

No TT complication was observed. MAHA gradually improved and platelet count normalised.

**To cite:** Boattini M, Procaccianti G. *BMJ Case Reports* Published online: [please include Day Month Year] doi:10.1136/bcr-2012-008426

**Figure 1** Three-dimensional CT angiography showed occlusion of the temporal stem of the left middle cerebral artery (TSLMCA; A, white arrow), and on day 7, it showed complete recanalisation of the TSLMCA (B, white arrow).



He was discharged on day 15 in good clinical condition and never relapsed.

## DISCUSSION

TTP, first described by Moschowitz in 1925, is an acute syndrome with multiorgan abnormalities. Although they have different epidemiologies, aetiology, response to therapy and prognosis, TTP and haemolytic uraemic syndrome (HUS) are commonly associated and referred to as TTP-HUS. The diagnostic pentad of TTP-HUS includes MAHA, thrombocytopenia, neurological symptoms, renal failure and fever.

Predominant neurological symptoms and signs (such as headache, confusion, seizures, focal abnormalities, transient ischaemic attack, stroke and coma) are suggestive of TTP, whereas severe renal failure is more suggestive of HUS.

TTP is associated with a deficit in the activity of ADAMTS13, a von Willebrand factor cleaving protease, which produces platelet clumping and subsequent microvascular thrombosis with fibrin deposition, red blood cell fragmentation (schistocytes), release of inflammatory cytokines, high levels of plasminogen-activator inhibitor type 1 and other prothrombotic mediators. TTP can be idiopathic, acquired or due to congenital ADAMTS13 deficiency. ADAMTS13 deficiency (<10%) and the presence of ADAMTS13 inhibitor distinguish idiopathic and acquired TTP from the congenital form.<sup>6</sup>

Secondary TTP is due to infections, autoimmune disease, vasculitis, pregnancy, bone marrow transplantation, cardiovascular surgery, drugs (quinine, immunosuppressive or cancer therapy, antiplatelet agents such as ticlopidine and clopidogrel), antiphospholipid syndrome or unusual thrombophilia.<sup>2</sup>

Clinical findings can be non-specific; laboratory findings distinguish tTTP, with MAHA and thrombocytopenia, from atypical TTP (aTTP), which has no specific alteration, and this is why the diagnosis is challenging.

Testing ADAMTS13 deficiency is not recommended for confirming the diagnosis because it can be present in other conditions such as sepsis with disseminated intravascular coagulation or ischaemic organ failure.<sup>7</sup> However, ADAMTS13 deficiency can anticipate the long-term relapse risk, because patients with severe ADAMTS13 deficiency relapse more frequently.<sup>8</sup>

Standard TTP treatment is TPE; the use of TT in acute ischaemic TTP stroke is controversial and can lead to negative consequences.<sup>9</sup>

To our knowledge, only two cases of aTTP with ischaemic stroke due to LCAO treated with TT have been reported.<sup>2-4</sup> Idowu *et al* described the case of a 48-year-old Afro-American woman with a history of recurrent ischaemic strokes and aTTP. She presented with an acute M2 right middle cerebral artery (MCA) occlusion and underwent intra-arterial TT and thrombectomy. Her neurological symptoms did not improve, and new right MCA ischaemic areas with haemorrhagic change were detected on brain MRI.

Sevy *et al* described a case of a 30-year-old woman with an acute myeloblastic leukaemia M1 right MCA occlusion who underwent intravenous TT. Her focal deficits partially recovered; however, her clinical conditions worsened due to an M2 right MCA residual thrombus, which was treated by unfractionated heparin.

In both these cases, TTP was initially misdiagnosed and TPE was delayed.

Early TT is a proven success in acute ischaemic stroke in order to restore cerebral blood flow and reduce ischaemic damage of tissue and vessels. In the case reported by Sevy *et al*, TT seemed to re-establish cerebral blood flow, which however worsened lately due to a new thrombotic phenomenon. In the case we report, TT promptly restored cerebral blood flow and early TPE prevented arterial reocclusion. However, it is unclear to disentangle the efficacy of TT on clinical improvement, because its effect overlapped with TPE.

Haemorrhagic complications of TT in TTP patients should be always considered.

Thrombocytopenia in TTP is due to platelet clumping and microvascular thrombosis with fibrin deposition, which is the target of TT. For this reason, thrombocytopenia could be probably considered as a relative contraindication of TT in TTP stroke. Only the patient described by Idowu *et al* presented a haemorrhagic complication, which was probably due to the preexistence of small foci of petechial haemorrhage.

In conclusion, in the presence of an acute ischaemic stroke due to LCAO, especially in young adults, it is important to consider TTP diagnosis and, when consistent, to plan emergency TPE, which is the gold standard treatment. Further data are needed to understand the real therapeutic value and safety of TT in TTP stroke due to LCAO.

## Learning points

- ▶ Thrombotic thrombocytopenic purpura (TTP) is characterised by the pentad of microangiopathic haemolytic anaemia, thrombocytopenia, neurological symptoms, renal insufficiency and fever.
- ▶ Thrombotic thrombocytopenic purpura should be always considered in young adults with ischaemic stroke.
- ▶ Gold standard treatment for TTP is therapeutic plasma exchange.
- ▶ Further data are needed to understand the role of thrombolytic therapy in stroke due to large cerebral artery occlusion LCAO in patients with TTP.

**Competing interests** None.

**Patient consent** Obtained.

**Provenance and peer review** Not commissioned; externally peer reviewed.

## REFERENCES

- 1 Torok TJ, Holman RC, Chorba TL. Increasing mortality from thrombotic thrombocytopenic purpura in the United States-analysis of national mortality data. *Am J Hematol* 1995;50:84–90.
- 2 Idowu M, Reddy P. Atypical thrombotic thrombocytopenic purpura in a middle-aged woman who presented with a recurrent stroke. *Am J Hematol* 2012. doi:10.1002/ajh.23249.
- 3 Downes KA, Yomtavian R, Tsai HM, *et al.* Relapsed thrombotic thrombocytopenic purpura presenting as an acute cerebrovascular accident. *J Clin Apher* 2004;19:86–9.
- 4 Sevy A, Doche E, Squarcioni C, *et al.* Stroke in a young patient treated by alteplase heralding an acquired thrombotic thrombocytopenic purpura. *J Clin Apher* 2011;26:152–5.
- 5 Adams HP Jr, Del Zoppo G, Alberts MJ, *et al.* Guidelines for the early management of adults with ischemic stroke: a guideline from the American Heart Association/American Stroke Association Stroke Council, Clinical Cardiology Council, cardiovascular radiology and intervention council, and the atherosclerotic peripheral vascular disease and Quality Of Care Outcomes In Research Interdisciplinary Working Groups: the American Academy of Neurology affirms the value of this guideline as an educational tool for neurologists. *Stroke* 2007;38:1655–711.
- 6 Furlan M, Robles R, Galbusera M, *et al.* von Willebrand factor–cleaving protease in thrombotic thrombocytopenic purpura and the hemolytic-uremic syndrome. *N Engl J Med* 1998;339:1578–84.
- 7 Ono T, Mimuro J, Madoiwa S, *et al.* Severe secondary deficiency of von Willebrand factor-cleaving protease (ADAMTS13) in patients with sepsis-induced disseminated intravascular coagulation: its correlation with development of renal failure. *Blood* 2006;107:528–34.
- 8 Hovinga JA, Kremer, Vesely SK, Terrel DR, *et al.* Survival and relapse in patients with thrombotic thrombocytopenic purpura. *Blood* 2010;115:1500–11.
- 9 Aksay E, Kiyani S, Ersel M, *et al.* Thrombotic thrombocytopenic purpura mimicking acute ischemic stroke. *Emerg J Med* 2006;23:e51.

Copyright 2013 BMJ Publishing Group. All rights reserved. For permission to reuse any of this content visit <http://group.bmj.com/group/rights-licensing/permissions>.  
BMJ Case Report Fellows may re-use this article for personal use and teaching without any further permission.

Become a Fellow of BMJ Case Reports today and you can:

- ▶ Submit as many cases as you like
- ▶ Enjoy fast sympathetic peer review and rapid publication of accepted articles
- ▶ Access all the published articles
- ▶ Re-use any of the published material for personal use and teaching without further permission

For information on Institutional Fellowships contact [consortiasales@bmjgroup.com](mailto:consortiasales@bmjgroup.com)

Visit [casereports.bmj.com](http://casereports.bmj.com) for more articles like this and to become a Fellow