


This article was downloaded by: [University of Arizona]

On: 19 December 2014, At: 01:09

Publisher: Routledge

Informa Ltd Registered in England and Wales Registered Number: 1072954 Registered office: Mortimer House, 37-41 Mortimer Street, London W1T 3JH, UK



Neurocase: The Neural Basis of Cognition

Publication details, including instructions for authors and subscription information:
<http://www.tandfonline.com/loi/nncs20>

Susceptibility to interference and intrusion errors in consequence of the dominant hemisphere's hippocampal infarct: A case report

Mónika Andrejkovics^a, Petra Balla^a & Dániel Bereczki^b

^a Department of Psychiatry, Medical and Health Science Center, University of Debrecen, Debrecen, Hungary H-4032 Debrecen, Nagyerdei krt. 98

^b Department of Neurology, Semmelweis University, Budapest, Hungary H-1083 Budapest, Balassa u. 6

Published online: 13 Feb 2013.



[Click for updates](#)

To cite this article: Mónika Andrejkovics, Petra Balla & Dániel Bereczki (2014) Susceptibility to interference and intrusion errors in consequence of the dominant hemisphere's hippocampal infarct: A case report, *Neurocase: The Neural Basis of Cognition*, 20:2, 183-191, DOI: [10.1080/13554794.2012.741256](https://doi.org/10.1080/13554794.2012.741256)

To link to this article: <http://dx.doi.org/10.1080/13554794.2012.741256>

PLEASE SCROLL DOWN FOR ARTICLE

Taylor & Francis makes every effort to ensure the accuracy of all the information (the "Content") contained in the publications on our platform. However, Taylor & Francis, our agents, and our licensors make no representations or warranties whatsoever as to the accuracy, completeness, or suitability for any purpose of the Content. Any opinions and views expressed in this publication are the opinions and views of the authors, and are not the views of or endorsed by Taylor & Francis. The accuracy of the Content should not be relied upon and should be independently verified with primary sources of information. Taylor and Francis shall not be liable for any losses, actions, claims, proceedings, demands, costs, expenses, damages, and other liabilities whatsoever or howsoever caused arising directly or indirectly in connection with, in relation to or arising out of the use of the Content.

This article may be used for research, teaching, and private study purposes. Any substantial or systematic reproduction, redistribution, reselling, loan, sub-licensing, systematic supply, or distribution in any form to anyone is expressly forbidden. Terms & Conditions of access and use can be found at <http://www.tandfonline.com/page/terms-and-conditions>

Susceptibility to interference and intrusion errors in consequence of the dominant hemisphere's hippocampal infarct: A case report

Mónika Andrejkovics¹, Petra Balla¹, and Dániel Bereczki²

¹Department of Psychiatry, Medical and Health Science Center, University of Debrecen, Debrecen, Hungary H-4032 Debrecen, Nagyerdei krt. 98

²Department of Neurology, Semmelweis University, Budapest, Hungary H-1083 Budapest, Balassa u. 6

We present a case of a man with an ischemic lesion of the left hippocampus. Detailed neuropsychological assessment revealed susceptibility to retroactive interference and a tendency to make intrusion errors in addition to mild deficits in the verbal memory processes. Although retroactive interference and intrusion errors are normally considered to be the manifestations of frontal lobe dysfunctions, the idea of susceptibility to interference has recently begun to emerge in the literature, as an explanation of medial temporal lobe amnesia. Our data support this new theory, suggesting that one role of the hippocampus is to decrease the interference during the learning processes.

Keywords: Left hippocampus; Susceptibility to interference; Intrusion error; Memory functions; Case report.

INTRODUCTION

During the last six decades a huge amount of evidence has been collected on the role of the hippocampus in memory and learning processes. Some of the main functions of the hippocampus are to form explicit or declarative memories (conscious memory for facts and events) (e.g., Bechara et al., 1995; Squire, Stark, & Clark, 2004); to transfer information to longer-term storage (e.g., Alvarez & Squire, 1994; Winocur, Moscovitch, & Bontempi, 2010); and to store and retrieve information relayed in the parahippocampal gyrus (e.g., Eichenbaum, 1997; Gabrieli, Brewer, Desmond, & Glover, 1997). The left and right temporal lobes have long been assumed to be specialized for verbal

or non-verbal cognitive functions, respectively (e.g., Coleshill et al., 2004; Golby et al., 2001; Jones-Gotman et al., 1997; Milner, 1971; Papanicolaou et al., 2002; Powell et al., 2005). People with lesions to the hippocampus often exhibit anterograde amnesia (Milner, Corkin, & Treuber, 1968; Scoville & Milner, 1957), and mild retrograde amnesia is usually also present. In a previous study, the more damage was found in the hippocampus, the more severe were the memory deficits (Rempel-Clower, Zola, Squire, & Amaral, 1996). However, little is known about the role of the hippocampus in such processes as susceptibility to interference or making intrusion errors during learning.

Retroactive interference is an empirical phenomenon that occurs when subsequent material

Address correspondence to Mónika Andrejkovics, Nagyerdei krt. 98. H-4032 Debrecen, Hungary. (E-mail: andrejkovicsm@gmail.com).

The work was partly supported by grant No. TAMOP-4.2.1.B-09/1/KMR. Mónika Andrejkovics would like to express her gratitude to István Degrell, the former lead professor of the Psychiatric Department of University of Debrecen, Hungary for motivating and supporting her to become a neuropsychologist.

disrupts memory for previously learned information causing performance decrements (Solesio et al., 2009). In this case the storage of new experiences interferes with memories encoded at an earlier time, mostly if they are similar (Crouse, 1971). Retroactive interference can be one of the main reasons for everyday forgetting (for review see Wixted, 2004). Retroactive interference has traditionally been thought to be a manifestation of frontal lobe dysfunction and supposed to be in close connection with executive control mechanisms (e.g., Anderson, 2003; Luria, 1966; Shallice, 1988; Shimamura & Jurica, 1994; Smith & Jonides, 1999; Stuss et al., 1982). According to these authors the inhibitory control of unwanted memories is a function which can overcome the interference (i.e., controlling the influence of activated and distracting memories). These authors emphasize the importance of monitoring irrelevant or inappropriate information, selecting appropriate responses, and discriminating signals from noise as part of the inhibitory control.

Recently, the idea of susceptibility to interference has begun to emerge in the literature for the explanation of medial temporal lobe amnesia. Shapiro and Olton (1994) proposed that an important function of the hippocampus is to reduce associative interference during the learning process. Therefore, memory impairment in amnesia can be accounted for the inability to resist interference from irrelevant information. Winocur, Becker, Luu, Rosenzweig, & Wojtowicz (2012) have shown that adult hippocampal neurogenesis has a role in the mechanism that controls interference in memory. The authors have pointed out that newly generated dentate gyrus cells are involved in the formation of new contextual associations within the hippocampus and help to differentiate between conflicting content-dependent memories.

Intrusion error is an incorrect free recall of material not presented during the target list or passage (Fridberg, Brenner, & Lysaker, 2010). It represents false recollections and is one type of memory distortion. Patients who make intrusion errors tend to have difficulties in maintaining the distinction between information coming from the outside and their own associations and tend to confuse data obtained at different times (Lezak, 2004, p. 424). Intrusion can be interpreted as a sub-clinical tendency to confabulate (Dalla Barba, Parlato, Iavarone, & Boller, 1995). Intrusion – like susceptibility to interference – is generally thought to be a consequence of frontal lobe dysfunction,

mainly impaired self-monitoring, deficit of source-monitoring or impaired filtering (e.g., Dalla Barba et al., 1995; De Anna et al., 2008; Incisa della Rocchetta & Milner, 1993; Kopelman, 1978; Luria, 1966). However, there is also evidence suggesting a role of the hippocampal formation in this process (Crosson, Sartor, Jenny III, Nabors, & Moberg, 1993; Desgranges et al., 2002; Deweer et al., 1995; Lee, Loring, Flanigin, Smith, & Meador, 1988). Nevertheless, an entirely clear picture has not yet emerged either on the potential role of the hippocampus in interference processes or on its part in making intrusion errors.

In the present article we describe a case of a young man, who had an ischemic lesion in the dominant (left) hippocampus due to occlusion of the posterior cerebral artery. The subsequent neuropsychological consequences, particularly susceptibility to retroactive interference and tendency for making intrusion errors are discussed.

CASE HISTORY

Neurological and neuroradiological findings

TN, a 31-year-old man, had an ischemic lesion in the dominant (left) hippocampus. With the exception of a small lacunar lesion in the left thalamus (in the ventral lateral nucleus), no other lesions were detected. Following neurological investigation, he underwent a detailed neuropsychological assessment.

TN had no remarkable disease or any risk factors for cerebrovascular diseases (hypertension, diabetes, heart-disease, thrombotic disturbance, immunological disease or any other risk factors for cerebrovascular disease) in his history. On the night of his initial admission (in March of 2003) he woke up feeling numbness and weakness in his right extremities.

General physical examination revealed normal findings. He reported mild hypesthesia on the right side of the body, very mild paresis was suspected in the right upper extremity, and slight uncertainty was seen on the right side during the finger-nose test. TN was fully alert, oriented and anxious. Considering the mild objective signs the anxiety seemed to be disproportionately severe. It led to the initial diagnosis of conversion reaction. The immediate CT examination did not find any lesions. Due to the persisting complaint of hypesthesia an MRI scan was performed eight days later that

revealed a focal lesion of the left hippocampus, and a small, approximately 2 mm lacunar lesion in the left thalamus (in the ventral lateral nucleus). MR angiography found occlusion of the left posterior cerebral artery (Figure 1). Carotid and vertebral Doppler examination and MR angiography did not find any atherosclerotic lesions in the large cranial vessels. Transthoracic and transesophageal echocardiography excluded any possible source of cardiac embolization. Detailed investigations did not find any cause for thrombophilia that would have justified anticoagulant treatment. TN received antiplatelet medication and the right sided paraesthesia lasted for nine months before remission.

Although TN had no complaints of his cognitive functions, he underwent a neuropsychological examination because of the identified focal lesion of the left hippocampus. During this period his only complaint was the numbness of his right arm. He attended school for 13 years. He had worked as a chemist technician. He was right-handed.

Method of the neuropsychological assessment

The detailed neuropsychological examination was carried out at the Psychiatric Department of the University of Debrecen in multiple sessions in May 2003 (six sessions over three weeks) and was repeated in September 2003 (five sessions over two weeks).

The Hungarian version of the Wechsler Adult Intelligence Scale-Revised (WAIS-R) (Kun & Szegedi, 1996; Szakács, 1995) and the Raven's Progressive Matrices (Raven, 1996) were used to test TN's IQ. Attention functions were assessed by means of the Toulouse-Piéron Attention Test (Toulouse & Piéron, 1986) and the Bells Test (Gauthier, Dehaut, & Joanette, 1989). The Digits Forward part of the Digit Span subtest of the WAIS-R was used to measure the immediate memory span for digits. The Rey Auditory-Verbal Learning Test was taken (AVLT) (Rey, 1964;

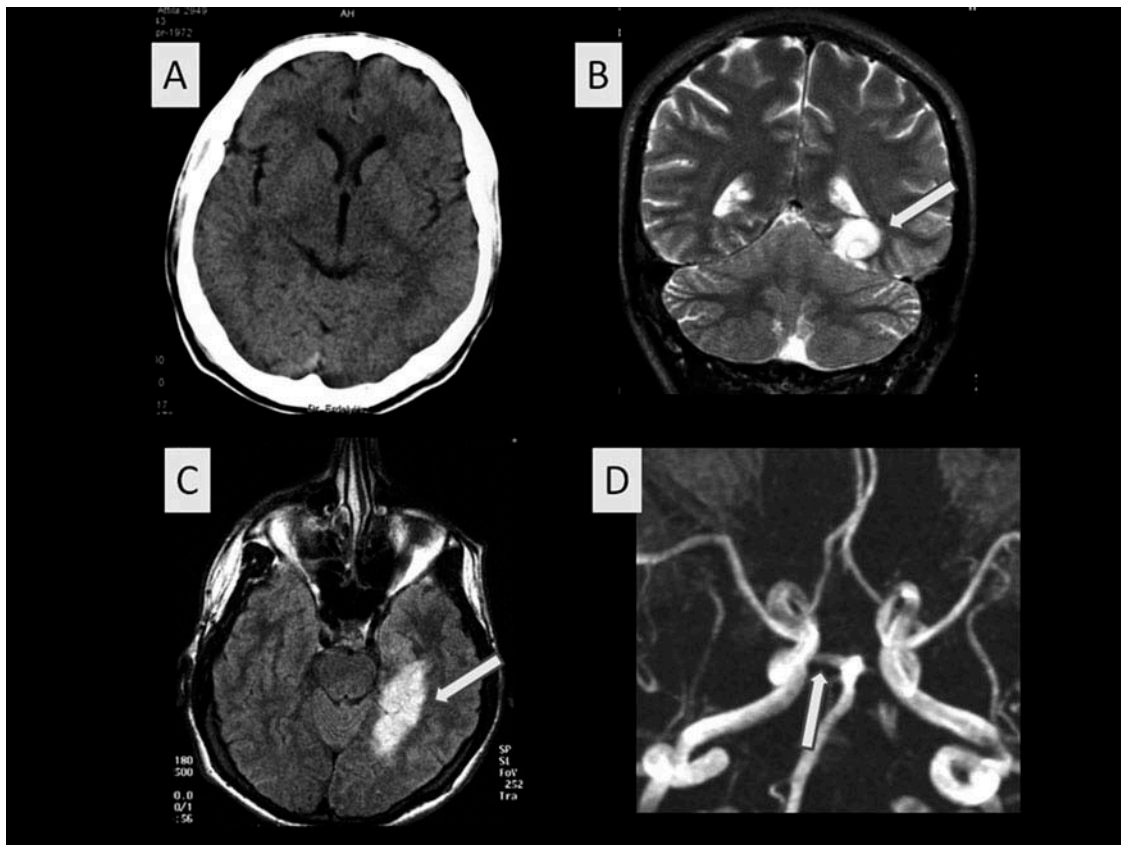


Figure 1. No changes can be seen on the CT image made in the acute phase (A). MRI reveals ischemic lesion restricted to the left hippocampus (B and C, arrows). With MR angiography the right posterior cerebral artery originating from the basilar artery can be clearly seen (D, arrow), but there is no flow in the left posterior cerebral artery.

Spreeen & Strauss, 1998) to assess the immediate word span, verbal learning, susceptibility to interference and delayed recall of words. Paired associate word learning was examined by the Hungarian Ranschburg-Ziehen probe (Nyírő, 1961). Recalling a coherent verbal material (a newspaper article) was measured by the Story Recall of the Rivermead Behavioural Memory Test (RBMT) (Wilson, Cockburn & Baddeley, 1985). The Benton Visual Retention Test (BVRT) (Sivan, 1992) and the Rey-Osterrieth Complex Figure Test–Recall (ROCF) (Osterrieth, 1944; Spreeen & Strauss, 1998) were used to assess the visual memory. The Rey Visual Design Learning Test (VDLT) (Rey, 1964) was applied to measure the visual learning processes. The Controlled Oral Word Association Test (COWAT) (Benton & Hamsher, 1989; Spreeen & Strauss, 1998) was used as a measure of the verbal (letter) fluency and the Five-point Test (Regard, Strauss & Knapp, 1982; Spreeen & Strauss, 1998) was done to assess the figural fluency. Constructional praxis was measured by the ROCF-Copy test (Osterrieth, 1944; Spreeen & Strauss, 1998).

Result of the neuropsychological assessment

General intellectual function

TN's Full Scale IQ in the Hungarian version of the WAIS-R score was 123, indicating a very high level of intelligence. His verbal IQ score was also 123, and his performance IQ score was 121 showing balanced intelligence-structure (Table 1). This test showed no impairment. TN scored 46/60 on the Raven's Progressive Matrices indicating a high level of conceptualizing spatial and numerical relationships.

Further main results of the detailed neuropsychological examination are summarized in Table 2.

Attention. The attention tests indicated no deficits in TN. He had an appropriate scanning strategy, and his attention performance was good.

Verbal memory and learning. TN's result of the digits forward task was within the normal range. His immediate word span had an average level under overload condition (Rey AVLT Trial I). TN exhibited some deficit in verbal learning, which did not improve four months later. At time of the

TABLE 1
TN's scores of the Hungarian version of the WAIS-R

Full Scale IQ	123
Verbal IQ	123
Performance IQ	121
Information	130
Comprehension	107
Digit Span	128
Arithmetic	116
Similarities	112
Digit Symbol Coding	139
Picture Arrangement	109
Picture Completion	122
Block Design	108
Object Assembly	102

first examination there were signs of susceptibility to interference (retroactive inhibition) and there was a tendency for making intrusion errors, mainly semantic type (i.e., semantically related to the word to memorize). The retroactive inhibition improved, but the tendency for making intrusion errors did not change four months later. Mild deficit was found in the delayed recall, which showed improvement four months later. TN performed poorly on the test of paired associate word learning, both in immediate and delayed recall. The learning of "easy associations" (e.g., girl–boy) was nearly intact, but the number of mistakes went up while learning "harder" word pairs (e.g., wall–mirror). By the time of the second examination his immediate and delayed recall had become normal, which was a significant improvement. Story recall was almost intact with a mild tendency for intrusion errors.

Visuo-spatial memory and learning. On the BVRT TN performed at the highest level, which indicated spared immediate visuo-spatial memory and reconstruction. In the immediate recall of the ROCF test TN reached a good level. TN's visual learning process proved to be intact by the use of Rey VDLT.

Executive functions. On the COWAT, TN's adjusted score was on the 'low normal' level. Since his verbal IQ was very high, this COWAT value revealed difficulties in generating words under controlled conditions. There were no errors, but his reaction time was long at the first letter, and became normal at the second and third letters (20, 5, and 5 seconds respectively). In the Five-point Test TN accomplished the task within the time-limit without any mistakes. He used rotation as a strategy. The test refers to fluid and flexible visuo-spatial

TABLE 2
TN's neuropsychological profile

<i>Cognitive function</i>	<i>Result</i>
Accuracy of attention (Toulouse-Piéron Attention Test)	99%
Visual scanning strategy (Bells Test)	intact
Verbal memory:	
Immediate digit span	8
Immediate word span	7/15
Immediate word span 4 months later	9/15
Word-list learning process (Rey AVLT)	7-9-13-13-12 +
Word-list learning process (Rey AVLT) 4 months later	9-8-11-13-12 +
Proactive inhibition (Rey AVLT)	7→6
Proactive inhibition (Rey AVLT) 4 months later	9→10
Retroactive inhibition (Rey AVLT)	12→6 ++
Retroactive inhibition (Rey AVLT) 4 months later	12→9 +
Intrusion errors (Rey AVLT)	yes +
Intrusion errors (Rey AVLT) 4 months later	yes +
Delayed recall of words (Rey AVLT)	8/15 +
Delayed recall of words (Rey AVLT) 4 months later	11/15
Paired associate word learning, immediate recall (Ranschburg-Ziehen probe)	18/25 ++
Paired associate word learning, immediate recall (Ranschburg-Ziehen probe) 4 months later	24/25
Paired associate word learning, delayed recall (Ranschburg-Ziehen probe)	13/25 +++
Paired associate word learning, delayed recall (Ranschburg-Ziehen probe) 4 months later	23/25
Story recall, immediately (RBMT)	12/21 *
Story recall, immediately (RBMT) 4 months later	12/21 *
Story recall, delayed (RBMT)	11/21 *
Story recall, delayed (RBMT) 4 months later	11/21 *
Visuo-spatial memory:	
Immediate recall (BVRT)	10/10
Immediate recall, incidental memory (ROCF - Recall)	24.5/36
Learning process (Rey VDLT)	6- 9-12-14-14
Delayed recall (Rey VDLT)	14/15
Constructional praxis (ROCF - Copy)	36/36
Executive functions: verbal (letter) fluency (COWAT F-A-S)	29 +
Executive functions: figural fluency (Five-point Test)	35/35

The neuropsychological examination revealed susceptibility to retroactive interference and a tendency to make intrusion errors. Furthermore, the verbal memory functions have been impaired and the visuo-spatial memory processes have been spared. Some of these mild deficits disappeared four months later.

+ mild deficit; ++ moderated deficit; +++ severe deficit

* was intact apart from a few intrusion errors

thinking and good ability to generate novel responses.

Constructional praxis. TN completed the ROCF-Copy test without making any mistakes, and he had an appropriate strategy for visuo-spatial construction. In the Block Design of the WAIS-R he achieved an average level which also shows intact constructional praxis.

Summary of the patient's neuropsychological profile

TN had a very high level of general intelligence with balanced verbal and performance IQ levels. He had

intact attention functions, visuo-spatial memory, visuo-spatial learning functions and constructional praxis. He had mild difficulties with processing verbal material. He showed a mild deficit in the verbal learning ability which did not improve four months later. There were signs of susceptibility to interference (retroactive inhibition) and a tendency for making intrusion errors, mainly of semantic type. The retroactive inhibition improved, but the tendency for making intrusion errors did not change four months later. The result of the delayed recall revealed a mild deficit showing a slightly diminished retention of the learned verbal material. This problem showed improvement by the second examination. On the paired-associate word learning test, TN's achievement was poor, but four months later

his immediate and delayed recall showed significant improvement. Story recall was almost intact with some tendency for intrusions. In addition, TN had slight difficulties in generating words (in letter fluency).

DISCUSSION

In the case of this 31-year-old man with an ischemic lesion in the dominant (left) hippocampus, the neuropsychological assessment revealed a susceptibility to interference (retroactive inhibition type), and a tendency for making intrusion errors (semantic type). Retroactive interference is usually considered to be a sign of frontal lobe dysfunctions, since the frontal cortex is supposed to be involved in the executive control of inhibition functions and selective retrieval (e.g., Luria, 1966; Shallice, 1988; Shimamura & Jurica, 1994; Smith & Jonides, 1999; Stuss, et al., 1982). However, there are data showing the importance of the medial temporal lobe in retroactive interference as well. In patients undergone medial temporal lobectomy, García et al. (2008) revealed a positive correlation between the volume of resection and the resulting retroactive interference. Solesio et al. (2009) detected increased activity in the left medial temporal lobe and the left anterior ventral prefrontal cortex by magnetoencephalography in healthy elderly subjects during retroactive interference. Recently, an explanation of medial temporal lobe amnesia with the help of the idea of susceptibility to interference has been emerging. Wixted (2004) has linked the notion of increased susceptibility to interference with the storage/consolidation impairment, arguing that structures in the medial temporal lobe are critical for the consolidation of the new memories. There are other authors who also suggest that temporal lobe amnesia can be characterized by an increased susceptibility to interference (Shapiro et al., 1994; Winocur, 1985). Shapiro and Olton (1994) proposed that a major function of the hippocampus is to reduce associative interference during learning. They argue that the hippocampus is active in tasks carrying substantial negative transfer from interference, and that hippocampal function is crucial for accurate performance. Consequently, one of the functions of the hippocampus may be to organize to-be-remembered information so that positive transfer, when possible, is maximized, and negative transfer, when present, is minimized.

Furthermore, TN had a tendency for making intrusion errors, mainly of semantic type. Rouleau,

Imbault, Laframboise, & Bédard (2001) pointed out that semantically related intrusions, which may reflect encoding of the words to remember on a deeper semantic level than unrelated or prior list errors, are not resulting exclusively from frontal lobe pathology. Dalla Barba et al. (1995) also mentioned that it might be possible that frontal lobe dysfunction could be responsible for only severe intrusions (e.g., semantically unrelated intrusions). In the case of our patient, the intrusions were semantically related to the original words, thus cannot be considered to be severe – i.e., frontal type – intrusion errors, but it might refer to an impaired hippocampal function.

Further results of TN's neuropsychological examination are in line with the findings of previous research: 1. TN had mild difficulties in the processing of verbal, but not visuo-spatial material. It has long been recognized that there is a material-dependent lateralization in the brain (e.g., De Renzi, Zambolin, & Crisi, 1987; Golby et al., 2001; Jones-Gotman et al., 1997; Milner, 1971; Papanicolaou et al., 2002; Powell, et al., 2005; Vallar, Papagno, & Cappa, 1988). 2. TN's verbal memory span (digit span, and immediate recall of a word list and a story) was intact, while his list-learning ability was mildly deficient. Previous research has shown that the hippocampus is essential for the learning process but not for the memory span (Cave & Squire, 1992; MacKinnon & Squire, 1989; Spiers, Maguire, & Burgess, 2001; Squire, 1992; Victor & Agamanolis, 1990). Clinical and research data indicate that patients with amnesia – even with very different etiologies – have a relatively intact short-term memory capacity with significant long-term memory impairments in common (Baddeley & Warrington, 1970; O'Connor & Verfaellie, 2002). TN's memory performance was similar to the results of amnesic patients. 3. In our subject, the result of the delayed recall revealed a mild deficit showing a slightly diminished retention of the learned verbal material. Researchers have indicated that the hippocampus plays a role in the delayed recall (Helmstaedter & Elger, 1993, 1996; Kilpatrick et al., 1997). 4. In the paired associate word learning task TN's achievement was poor, but the story recall was almost intact except for a mild tendency to make intrusion errors. Previous research has shown that formation of the new item-item associations is critically dependent on medial temporal structures, but learning verbal information with high semantic structure (e.g., text) is often intact or only mildly impaired in patients with medial temporal pathology (Saling et al., 1993;

Squire, 1992; Wood, Saling, O'Shea, Berkovic, & Jackson, 2000).

It has to be noted that besides the focal lesion in the hippocampus, TN also had a small lacunar lesion in the left thalamus (in the ventral lateral nucleus). Although the thalamus is a critical brain structure in the mediation of different cognitive processes, among them memory functions, the ventral lateral nucleus of the thalamus is not supposed to be involved in memory processes (Vallar, 1999). All things considered, all of the above-mentioned impairments can be attributed to the lesion of the left hippocampus.

CONCLUSIONS

Our data have shown that lesion of the dominant (left) hippocampus can lead to increased susceptibility to retroactive interference and to a tendency to make semantically related intrusion errors. These phenomena were detectable while executing verbal but not visuo-spatial memory tasks. Our data support those new theories which propose that one of the main roles of the hippocampus is to decrease interference during the learning process. Nevertheless, further research is required to learn more about the exact nature of this function.

Consistent with previous findings, we also found mild signs of deficits in the verbal memory processes. Some of these difficulties disappeared four months later. These mild and transitory symptoms did not cause any problems in TN's activities of daily living. Mild memory problems can be the only manifestation of strokes that are limited to the hippocampus. However, in some cases there is not apparent clinical manifestation of the memory impairment and only comprehensive neuropsychological examination may reveal the subtle deficits of the memory.

Original manuscript received 23 February 2012
 Revised manuscript accepted 20 September 2012
 First published online 12 February 2013

REFERENCES

- Alvarez, P., & Squire, L. R. (1994). Memory consolidation and the medial temporal lobe: A simple network model. *Proceedings of the National Academy of Sciences of USA*, *91*, 7041–7045.
- Anderson, M. C. (2003). Rethinking interference theory: executive control and the mechanisms of forgetting. *Journal of Memory and Language*, *49*, 415–445.
- Baddeley, A. D. (1992). Working memory. *Science*, *255*, 566–559.
- Baddeley, A. D., & Warrington, E. K. (1970). Amnesia and the distinction between long- and short-term memory. *Journal of Verbal Learning and Verbal Behavior*, *9*, 176–189.
- Bechara, A., Tranel, D., Damasio, H., Adolphs, R., Rockland, C., & Damasio, A. R. (1995). Double dissociation of conditioning and declarative knowledge relative to the amygdala and hippocampus in humans. *Science*, *26*, 1115–1118.
- Benton, A. L., & Hamsher, K. (1989). *Multilingual aphasia examination*. Iowa City: AJA Associates.
- Cave, C. B., & Squire, L. R. (1992). Intact verbal and nonverbal short-term memory following damage to the human hippocampus. *Hippocampus*, *2*, 151–163.
- Coleshill, S. G., Binnie, C. D., Morris, R. G., Alarcon, G., van Emde Boas, W., Velis, D. N., . . . van Rijen, P. C. (2004). Material-specific recognition memory deficits elicited by unilateral hippocampal electrical stimulation. *Journal of Neuroscience*, *24*, 1612–1616.
- Crosson, B., Sartor, K. J., Jenny III, A.B., Nabors, N. A., & Moberg, P. J. (1993). Increased intrusions during verbal recall in traumatic and nontraumatic lesions of the temporal lobe. *Neuropsychology*, *7*, 193–208.
- Crouse, J. H. (1971). Retroactive interference in reading prose materials. *Journal of Educational Psychology*, *62*, 39–44.
- Dalla Barba, G., Parlato, V., Iavarone, A., & Boller, F. (1995). Anosognosia, Intrusions and 'frontal' functions in Alzheimer's Disease and depression. *Neuropsychologia*, *33*, 247–259.
- De Anna, F., Attali, E., Freynet, L., Foubert, L., Laurent, A., Dubois, B., & Dalla Barba, G. (2008). Intrusions in story recall: When over-learned information interferes with episodic memory recall. Evidence from Alzheimer's Disease. *Cortex*, *44*, 305–311.
- De Renzi, E., Zambolin, A., & Crisi, G. (1987). The pattern of neuropsychological impairment associated with left posterior cerebral artery infarcts. *Brain*, *110*, 1099–1116.
- Desgranges, B., Baron, J. C., Giffard, B., Chételat, G., Lalevée, C., Viader, F., . . . Eustache, F. (2002). The neural basis of intrusion in free recall and cued recall: A PET study in Alzheimer's Disease. *Neuroimage*, *17*, 1658–1664.
- Deweert, B., Lehericy, S., Pillon, B., Baulac, M., Chiras, J., Marsault, C., . . . Dubois, B. (1995). Memory disorders in probable Alzheimer's disease: The role of hippocampal atrophy as shown with MRI. *Journal of Neurology, Neurosurgery, and Psychiatry*, *58*, 590–597.
- Eichenbaum, H. (1997). How does the brain organize memories? *Science*, *277*, 330–332.
- Fridberg, D. J., Brenner, A., & Lysaker, P. H. (2010). Verbal memory intrusions in schizophrenia: Associations with self-reflectivity, symptomatology, and neurocognition. *Psychiatric Research*, *179*, 6–11.
- Gabrieli, J. D., Brewer, J. B., Desmond, J. E., & Glover, G. H. (1997). Separate neural bases of two fundamental memory processes in the human medial temporal lobe. *Science*, *276*, 264–266.
- García, M. E., Morales, L. M., Trápaga, O., Bobes León, M. A., Lorigados, L., García, I., . . . Bender, J. E. (2008). The episodic memory, retroactive interference and volume of the temporomesial structure. *Clinical Neurophysiology*, *119*, e160.

- Gauthier, L., Dehaut, F., & Joanette, Y. (1989). The Bells test: A quantitative and qualitative test for visual neglect. *International Journal of Clinical Neuropsychology*, *11*, 49–54.
- Golby, A. J., Poldrack, R. A., Brewer, J. B., Spencer, D., Desmond, J. E., Aron, A. P., & Gabrieli, J. D. E. (2001). Material-specific lateralization in the medial temporal lobe and prefrontal cortex during memory encoding. *Brain*, *124*, 1841–1854.
- Helmstaedter, C., & Elger, C. E. (1993). Cognitive consequences of left temporal lobectomy: comparison with pre-existing deficits. *Epilepsia*, *34*(2), 67.
- Helmstaedter, C., & Elger, C. E. (1996). Short term cognitive consequences of 2/3 anterior temporal lobectomy in 144 patients. *Epilepsia*, *37*, 171–180.
- Incisa della Rocchetta, A., & Milner, B. (1993). Strategic search and retrieval inhibition: The role of the frontal lobes. *Neuropsychologia*, *31*, 503–524.
- Jones-Gotman, M., Zatorre, R. J., Olivier, A., Andermann, F., Cendes, F., Staunton, H., . . . Wieser, H. G. (1997). Learning and retention of words and designs following excision from medial or lateral temporal-lobe structures. *Neuropsychologia*, *35*, 963–973.
- Kilpatrick, C., Murrie, V., Cooka, M., Andrewes, D., Desmind, P., & Hopper, J. (1997). Degree of left hippocampal atrophy correlates with severity of neuropsychological deficits. *Seizure*, *6*, 213–218.
- Kopelman, M. D. (1987). Two types of confabulation. *Journal of Neurology, Neurosurgery, and Psychiatry*, *50*, 1482–1487.
- Kun M. & Szegedi M. (1996). *The measurement of the intelligence*. Budapest: Akadémia Kiadó, Hungarian.
- Lee, G. P., Loring, D. W., Flanigin, H. F., Smith, J. R., & Meador, K. J. (1988). Electrical stimulation of the hippocampus produces verbal intrusions during memory testing. *Neuropsychologia*, *26*, 623–627.
- Lezak, M. D., Howieson, D. B., & Loring, D. W. (2004). *Neuropsychological assessment* (4th ed.). New York, NY: Oxford University Press.
- Luria, A. R. (1966). *Higher cognitive functions in Man*. New York: Basic Books.
- MacKinnon, D., & Squire, L. R. (1989). Autobiographical memory in amnesia. *Psychobiology*, *17*, 247–256.
- Milner, B. (1971). Interhemispheric differences in the localization of psychological processes in man. *British Medical Bulletin*, *27*, 272–277.
- Milner, B., Corkin, S., & Treuber, H. L. (1968). Further analysis of the hippocampal amnesic syndrome: fourteen year follow up study of H. M. *Neuropsychologia*, *6*, 214–234.
- Nyiró, G. Y. (1961). *Psychiatry*. Budapest: Medicina, Hungarian
- O'Connor, M. G., & Verfaellie, M. (2002). The amnesic syndrome: Overview and subtypes. In A. D. Baddeley, M. D. Kopleman, & B. A. Wilson (Eds.), *The handbook of memory Disorders*. Chichester: Wiley.
- Osterrieth, P. A. (1944). Le test de copie d'une figure complexe: Contribution à l'étude de la perception et de la memoire [A test of copying a complex figure: A contribution to the study of perception and memory]. *Archives de Psychologie, Geneva*, *30*, 205–220.
- Papanicolaou, A. C., Simos, P. G., Castillo, E. M., Breier, J. I., Katz, J. S., & Wright, A. A. (2002). The hippocampus and memory of verbal and pictorial material. *Learning and Memory*, *9*, 99–104.
- Powell, H. W., Koeppe, M. J., Symms, M. R., Boulby, P. A., Salek-Haddadi, A., Thompson, P. J., . . . Richardson, M. P. (2005). Material-specific lateralization of memory encoding in the medial temporal lobe: Blocked versus event-related design. *Neuroimage*, *27*, 231–239.
- Raven, J. C. (1996). *Raven's Progressive Matrices: A perceptual test for intelligence*. Oxford: Oxford Psychologists Press.
- Regard, M., Strauss, E., & Knapp, P. (1982). Children's production on verbal and non-verbal fluency tasks. *Perceptual and Motor Skills*, *55*, 839–844.
- Rempel-Clower, N. L., Zola, S. M., Squire, L. S., & Amaral, D. G. (1996). Three cases of enduring memory impairment after bilateral damage to the hippocampal formation. *Journal of Neuroscience*, *16*, 5233–5255.
- Rey, A. (1964). *L'examen clinique en psychologie*. Paris: Presses Universitaires de France.
- Rouleau, I., Imbault, H., Laframboise, M., & Bédard, M. A. (2001). Pattern of intrusions in verbal recall: comparison of Alzheimer's Disease, Parkinson's disease, and frontal lobe dementia. *Brain and Cognition*, *46*, 244–249.
- Saling, M. M., Berkovic, S. F., O'Shea, M. F., Kalnins, R. M., Darby, D. G., & Bladin, P. F. (1993). Lateralization of verbal memory and unilateral hippocampal sclerosis: Evidence of task-specific effects. *Journal of Clinical and Experimental Neuropsychology*, *15*, 608–618.
- Scoville, W. B., & Milner, B. (1957). Loss of recent memory after bilateral hippocampal lesions. *The Journal of Neurology, Neurosurgery and Psychiatry*, *20*, 11–21.
- Shallice, T. (1988). *From Neuropsychology to Mental Structure*. Cambridge, UK: Cambridge University Press.
- Shapiro, M. L., & Olton, D. S. (1994). Hippocampal function and interference. In D. L. Schachter & E. Tulving (Eds.), *Memory systems* (pp. 141–146). Cambridge, MA: MIT Press.
- Shimamura, A. P., & Jurica, P. J. (1994). Memory interference effects and aging: Findings from a test of frontal lobe function. *Neuropsychology*, *8*, 408–412.
- Sivan, A. B. (1992). *Benton visual retention test* (5th ed.). San Antonio, TX: The Psychological Corporation.
- Smith, E. E., & Jonides, J. (1999). Storage and executive processes in the frontal lobes. *Science*, *283*, 1657–1661.
- Solesio, E., Lorenzo-López, L., Campo P., López-Frutos, J. M., Ruiz-Vargas J. M., & Maestú, F. (2009). Retroactive interference in normal aging: A magnetoencephalography study. *Neuroscience Letters*, *456*, 85–88.
- Spiers, H. J., Maguire, E. A., & Burgess, N. (2001). Hippocampal amnesia. *Neurocase*, *7*, 357–382.

- Spreen, O., & Strauss, E (1998). *A compendium of neuropsychological tests. Administration, norms and commentary*. New York, NY: Oxford University Press.
- Squire, L. R. (1992). Memory and the hippocampus: A synthesis from findings with rats, monkeys, and humans. *Psychological Review*, *99*, 195–231.
- Squire, L. R., Stark, C. E., & Clark, R. E. (2004). The medial temporal lobe. *Annual Review of Neuroscience*, *27*, 279–306.
- Stuss, D. T., Kaplan, E. F., Benson, D. F., Weir, W. S., Chiulli, S., & Sarazin, F. F. (1982). Evidence for involvement of orbitofrontal cortex in memory functions: An interference effect. *Journal of Comparative and Physiological Psychology*, *96*, 913–925.
- Szakács, F. (1995). *Types of deficits in intelligence*. Budapest: Medicina Könyvkiadó Rt, Hungarian.
- Toulouse, E., & Piéron, H. (1986). *Toulouse-Piéron. Pruebas perceptiva y de atención [Test of perception and attention]*. Madrid: TEA.
- Vallar, G. (1999). Neuropsychological disorders of memory. In G. Denes & L. Pizzamiglio (Eds.), *Handbook of clinical and experimental neuropsychology* (pp. 321–368). East Sussex, UK: Psychology Press.
- Vallar, G., Papagno, C., & Cappa, S. F. (1988). Latent aphasia after left hemisphere lesions. A lexical-semantic and verbal memory deficit. *Aphasiology*, *2*, 463–478.
- Victor, M., & Agamanolis, D. (1990). Amnesia due to lesions confined to the hippocampus: A clinical-pathologic study. *Journal of Cognitive Neuroscience*, *2*, 246–257.
- Wilson, B. A., Cockburn, J., & Baddeley, A. (1985). *The rivermead behavioral memory test*. Bury St. Edmunds, UK: Thames Valley Test.
- Winocur, G. (1985). The hippocampus and thalamus: Their roles in short- and long-term memory and the effects of interference. *Behavioural Brain Research*, *16*, 135–152.
- Winocur, G., Becker, S., Luu, P., Rosenzweig, S., & Wojtowicz, J. M. (2012). Adult hippocampal neurogenesis and memory interference. *Behavioural Brain Research*, *227*, 464–469.
- Winocur, G., Moscovith, M., & Bontempi, B. (2010). Memory formation and long-term retention in humans and animals: Convergence toward a transformation account of hippocampal-neocortical interactions. *Neuropsychologia*, *48*, 2339–2356.
- Wixted, J. T. (2004). The psychology and neuroscience of forgetting. *Annual Review of Psychology*, *55*, 235–269.
- Wood, A. G., Saling, M. M., O'Shea, M. F., Berkovic, S. F., & Jackson, G. D. (2000). Components of verbal learning and hippocampal damage assessed by T2 relaxometry. *Journal of the International Neuropsychological Society*, *6*, 529–538.