

FULL CASES

Parakinesia brachialis oscitans during thrombolytic therapy

Francis Paciornik Zorzetto,¹ Vera Lucia Braatz,² Olivier Walusinski,³ Helio Afonso Guizoni Teive⁴

¹Department of Neurology, Hospital das Clínicas of Federal University of Paraná, Curitiba, Parana, Brazil

²Department of Neurology Service, Hospital de Clínicas, Curitiba, Parana, Brazil

³Cabinet Medical, Brou, France

⁴Movement Disorders Unit, Neurology Service, Hospital de Clínicas, Federal University of Paraná, Curitiba, Parana, Brazil

Correspondence to

Francis Paciornik Zorzetto, francispac@hotmail.com

SUMMARY

The authors describe a case report of a patient with parakinesia brachialis oscitans, which occurred during thrombolytic therapy, in a patient with left-middle cerebral artery occlusion.

BACKGROUND

The involuntary movement of a paralysed upper limb following the act of yawning was described by Walusinski *et al*^{1,2} as parakinesia brachialis oscitans (PBO). This under-recognised phenomenon is scantily described in the literature, in most cases secondary to haemorrhagic or ischaemic stroke. The precise physiopathology remains unclear, and from a topographic standpoint, lesions have been described in the brainstem or areas supplied by the middle cerebral artery (MCA).

Here we describe a case of PBO observed during thrombolytic therapy (TPA) in a patient with left MCA, which resolved within 24 h, although there was no motor neurological improvement.

CASE PRESENTATION

A 60-year-old man, right-handed, presented with sudden onset of aphasia and right-sided weakness. Medical history was positive for hypertension and myocardial infarction 10 years before. Brain CT scan was normal upon admission. Within 4 h of symptom onset, intravenous TPA was initiated. During the infusion and the following hours, the patient was drowsy and yawned deeply in an abnormally frequent and repeated way. At the beginning of each yawn, the right arm involuntarily rose with flexion of the elbow and adduction, remaining still for a couple of seconds, and slowly returning to its primary rest position. During the initial 24 h, this phenomenon occurred repeatedly, disappearing thereafter. After TPA infusion, the neurological deficits remained unchanged with mild improvement during the following days. A follow-up CT scan, performed 24 h after treatment revealed a large ischaemic stroke in the left MCA territory (figures 1 and 2).

INVESTIGATIONS

Additional investigations included transthoracic, transoesophageal and carotid Doppler ultrasound, showing no significant abnormalities. Transcranial Doppler ultrasound scan showed subtle asymmetry of velocity between the MCA (R>L).

OUTCOME AND FOLLOW-UP

The patient was discharged with NIHSS 15, reaching a score of 12 on clinical follow-ups. Since then, no further episodes of PBO have been detected.

DISCUSSION

Since the early 19th century, a few cases of movements of a paralysed arm during yawning have been reported; however, the term PBO has only recently been coined.¹ ‘Parakinesia’ is defined as an abnormal involuntary movement that replaces a normal movement. Differing from synkinesia, which involves involuntary muscle contraction that accompanies voluntary movements, parakinesia refers to a reflex movement.^{1,2} Parakinesia may appear right after the event’s onset, during the flaccid phase, or later, during the spastic phase, while synkinesia occurs more often during the spastic phase. The aetiology of the motor deficit is variable in the literature, including ischaemic or haemorrhagic stroke, amyotrophic lateral sclerosis or brainstem tuberculoma. Two main locations are closely linked to this abnormal movement: a lesion in the MCA territory, leading to infarction in the internal capsule and basal ganglia or a pontomedullary lesion.

Classically, yawning is thought to recruit specific control systems, including the paraventricular nucleus of the hypothalamus, the locus coeruleus and reticular activating system and the brainstem including the nuclei of cranial nerves (V, VII, IX, X, XI, XII and C1–C4). Neocortical brain areas possibly have an inhibitory effect on these systems. In the case of specific MCA strokes, these systems become abnormally excitable, leading to repetitive yawning.³ In addition, Walusinski *et al*⁴ also argued that a lesion in the internal capsule affecting inhibitory pathways liberates certain subcortical structures that coordinate the massive inspiration of yawning and the motor control associated with quadrupedal locomotion.⁴

To date, there have been no cases of PBO reported during thrombolysis. Our patient presented an infarction of the MCA territory, a location that is known to be associated with PBO. The phenomenon was short-lived (not observed after the first 24 h) with no significant improvement of hemiplegia. It is possible that the relatively short duration of PBO was influenced by thrombolysis. Lesions generally reflect substantial disruption of energy metabolism, which leads to irreversibly damaged tissue. But the mechanisms also generate oxygen radicals and provoke changes in calcium

To cite: Zorzetto FP, Braatz VL, Walusinski O, *et al*. *BMJ Case Reports* Published online: [please include Day Month Year] doi:10.1136/bcr-2012-007079

Figure 1 Patient with right hemiplegia, due to ischaemic stroke, during thrombolytic therapy, presenting an involuntary raising of the paralysed right arm, after initiation of yawning (parakinesia brachialis oscitan).

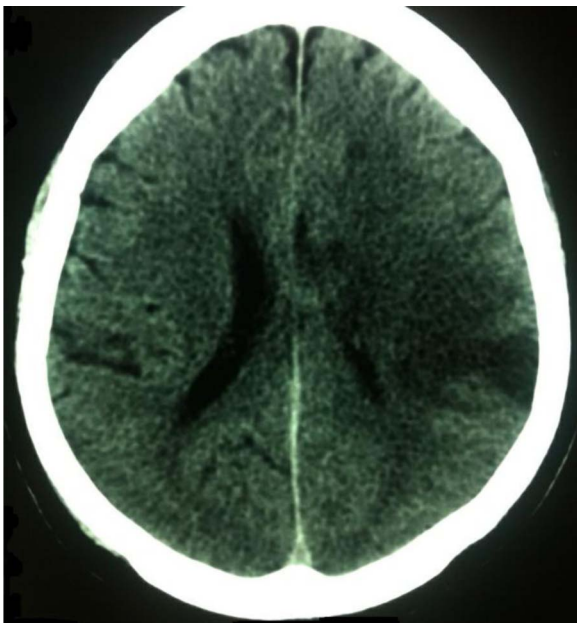
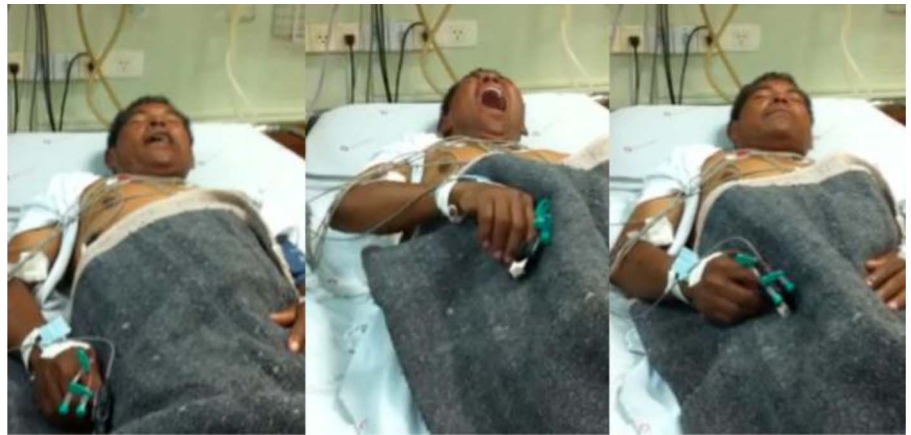

Figure 2 Brain CT the day after thrombolytic therapy, showing an area of infarction in the left-middle cerebral artery territory.

homeostasis or adenosine, during the thrombolysis itself. This metabolic process may secondarily alter the arousal response to stimulation of the cortex by the reticular activating system of the brainstem, which can trigger recurrent yawning. The literature describes additional cases in which the duration was not specifically described.^{1–6} Further studies are necessary to determine the exact physiopathological basis involved in PBO during stroke and the implications of thrombolytic therapy.

Learning points

- ▶ Parakinesia brachialis oscitans (PBO) is the involuntary movement of a paralysed upper limb following the act of yawning.
- ▶ PBO is an under-recognised phenomenon, in most cases secondary to haemorrhagic or ischaemic stroke.
- ▶ The precise physiopathology of PBO remains unclear, and from a topographic standpoint, lesions have been described in the brainstem or areas supplied by the middle cerebral artery.

Competing interests None.

Patient consent Obtained.

Provenance and peer review Not commissioned; externally peer reviewed.

REFERENCES

- 1 Walusinski O, Quoirin E, Neau JP. La parakinesie brachiale oscitante. *Rev Neurol* 2005;161:193–200.
- 2 Walusinski O, Neau JP, Bogousslavsky J. Hand up! Yawn and raise your arm. *Int J Stroke* 2010;5:21–7.
- 3 Singer OC, Humpich MC, Lanfermann H, et al. Yawning in acute anterior circulation stroke. *J Neurol Neurosurg Psychiatry* 2007;78:1253–4.
- 4 Walusinski O. Can Stroke localization be used to map out the neural network for yawning behavior? *J Neurol Neurosurg Psychiatry* 2007;78:1166.
- 5 Jung N, Ahn B, Park K, et al. A case of parakinesia brachialis oscitans. *Clin Neurol Neurosurg* 2012;114:156–8.
- 6 Lima PMG, Munhoz RP, Becker N, et al. Parakinesia brachialis oscitans: report of three cases. *Parkinsonism Relat Disord* 2012;18:204–6.

Copyright 2013 BMJ Publishing Group. All rights reserved. For permission to reuse any of this content visit <http://group.bmj.com/group/rights-licensing/permissions>.
BMJ Case Report Fellows may re-use this article for personal use and teaching without any further permission.

Become a Fellow of BMJ Case Reports today and you can:

- ▶ Submit as many cases as you like
- ▶ Enjoy fast sympathetic peer review and rapid publication of accepted articles
- ▶ Access all the published articles
- ▶ Re-use any of the published material for personal use and teaching without further permission

For information on Institutional Fellowships contact consortiasales@bmjgroup.com

Visit casereports.bmj.com for more articles like this and to become a Fellow