

# Pallidal Deep Brain Stimulation for a Case of Hemidystonia Secondary to a Striatal Stroke

Jonathan Fuller<sup>a</sup> Ian A. Prescott<sup>b</sup> Elena Moro<sup>c</sup> Hiroki Toda<sup>e</sup> Andres Lozano<sup>d</sup>  
William D. Hutchison<sup>b, d</sup>

<sup>a</sup>Faculty of Medicine and <sup>b</sup>Department of Physiology, University of Toronto, and Divisions of <sup>c</sup>Neurology and <sup>d</sup>Neurosurgery, Toronto Western Hospital, Toronto, Ont., Canada; <sup>e</sup>Department of Neurosurgery, Tazuke Kofukai Medical Research Institute and Kitano Hospital, Osaka, Japan

## Key Words

Secondary dystonia • Stroke • Striatum • Deep brain stimulation • Globus pallidus internal segment • Intraoperative recordings

## Abstract

**Background:** The efficacy of bilateral globus pallidus internus (GPi) deep brain stimulation (DBS) for medically refractory idiopathic generalized dystonia has been demonstrated repeatedly. More variable outcomes have been reported in the treatment of secondary dystonia with GPi DBS. **Objectives:** The present study seeks to examine the pallidal physiology and clinical outcome of GPi DBS in a case of secondary dystonia. **Methods:** We report on a 43-year-old man who at the age of 9 suffered a left basal ganglia stroke and at the age of 21 developed severe disabling hemidystonia. Following unsuccessful medical management for many years and an axial involvement of the dystonia, he underwent bilateral GPi DBS with dual microelectrode mapping of cell firing and evoked field potentials (fEP). **Results:** On the intact side we found regular firing of pallidal neurons and normal fEP indicative of functioning striatopallidal pathways. The affected side was found to include a higher frequency of bursting

pallidal neurons. fEP could not be evoked on the affected side, suggesting their origin to be striatal GABAergic afferents. **Conclusions:** The patient had marked benefit from bilateral GPi DBS, which suggests that the therapeutic effects of DBS were mediated by the intact pathways in this case of hemidystonia.

Copyright © 2013 S. Karger AG, Basel

## Introduction

Dystonia describes disordered movements of one or more body parts, involving sustained muscle contractions that cause repetitive or twisting movements and abnormal postures [1]. Dystonia may be isolated to one body part (focal) or generalized, affecting both legs and at least one other body part [2]. In hemidystonia, one side of the body is affected. As a clinical syndrome, dystonia has diverse etiologies that form a basis for its classification. Primary dystonia occurs in the absence of an anatomical abnormality or known insult to the central nervous system (CNS), while secondary dystonia occurs in conjunction with a known insult [3].

Primary dystonia is often hereditary with childhood presentation, such as the DYT1 phenotype [4]. Slow, irregular neuronal firing in the internal segment of the globus pallidus (GPi) is a common correlate [5–8]. Pharmacologic intervention is usually attempted to resolve symptoms before surgery is considered. Among surgical options, bilateral GPi deep brain stimulation (DBS) has become the preferred surgical technique to restore basal ganglia (BG) function in idiopathic dystonia. Although GPi DBS has shown long-term, significant clinical efficacy for primary dystonia [9, 10], empirical support for its use has accumulated unaccompanied by an understanding of its mechanisms of action.

In contrast to the consistent benefit shown for primary dystonia, surgical outcomes in secondary dystonia have been less consistent [11]. Some studies have suggested that abnormal activity in striatal neurons projecting to the pallidum may be implicated in patients with primary dystonia [12]. Several cases of secondary dystonia arising from striatal degeneration or stroke have also been reported [13, 14].

Unilateral stroke of one or more of the BG nuclei presents a rare opportunity to compare function and electrophysiology between intact and degenerated sides in the same patient during DBS surgery. Here, we report the case of an adult patient with hemidystonia secondary to a left subcortical stroke who underwent implantation of bilateral DBS electrodes in GPi in 2008.

## Case Report

### History

The patient was a 42-year-old, right-handed male with no family history of movement disorders. At the age of 9 years, he suffered an intraparenchymal hemorrhagic stroke of the left cerebral hemisphere of unknown etiology. He recovered with mild spastic right hemiparesis. Around the age of 20 years, he developed spasms of the right side of his neck and right arm, which produced severe pain. He later presented with marked torticollis and right laterocollis. Subsequent brain MRI revealed residual encephalomalacia involving the caudate, anterior putamen, and anterior limb of the internal capsule, and eventually left cerebral peduncle atrophy. His dystonic features progressed to include contralateral involvement.

The patient underwent dorsal rhizotomy, with only mild improvement in symptoms. Intrathecal baclofen treatment was also attempted without success. Alcohol and stress worsened his dystonia. The patient was receiving botulinum toxin injections three times per year, which improved pain and dystonic symptoms by about 20%. Although anticholinergic drugs were helping with his dystonia, he was experiencing blurred vision and memory loss while on the medication.

The patient presented to our clinic with predominantly right-sided dystonia (with some bilateral involvement). He demonstrat-

ed spasms in both arms and both shoulders, moderate retrocollis and left torticollis, moderate scoliosis, and diffuse dystonic tremor. He also had dystonia of the right and left legs, slight dystonia of the left arm, obvious dystonia of the right arm, moderate pulling of the neck and definite bending of the trunk, which were intermittent at rest. The patient suffered from moderate pain (6/10; 0 = no pain, 10 = worst imaginable pain) most of the time. Though independent, he struggled with fine motor tasks, including writing with his right hand. He was somewhat prone to clumsiness while performing daily tasks and had an abnormal gait. The preoperative Burke-Fahn-Marsden Dystonia Rating Scale (BFMDRS) movement score was 30.5/120. MRI (1.5 T) revealed degeneration of the left caudate, anterior putamen, and anterior limb of the internal capsule (fig. 1a).

Given that the patient was markedly disabled by dystonic movements and pain despite standard medical therapy and botulinum toxin injections, bilateral GPi DBS was indicated.

### Stereotactic Surgery and Microelectrode Recordings

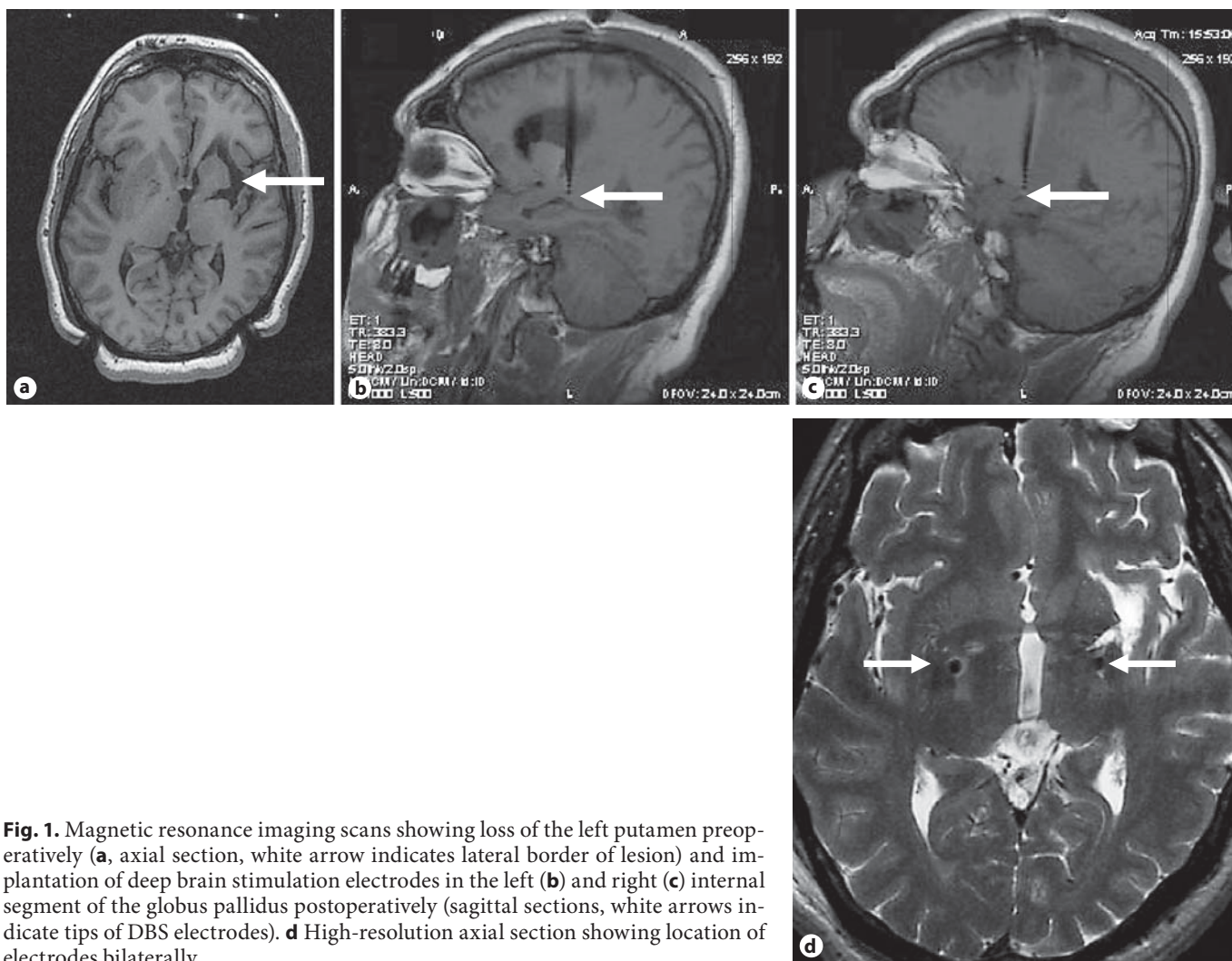
The patient underwent bilateral GPi DBS surgery in August 2008. The patient gave free and informed written consent and all protocols were approved by the Research Ethics Board at the UHN. The target in posteroventral GPi was prospectively chosen through stereotactic brain MRI. Microelectrode recordings were used to help determine the final target based on characteristic patterns of neuronal activity and response to microstimulation, as previously described [15]. The tentative target based on imaging was chosen as 20 mm lateral to the midline, 4 mm below the AC-PC line, and 2 mm behind the midcommissural point. A DBS quadripolar electrode (Medtronic model 3387) was implanted in the final target on both sides, determined by the results of microelectrode mapping placing the lowest contact near the site of the last recorded pallidal neuron and 2 mm above the most superior site that showed visual phosphenes upon microstimulation at 100  $\mu$ A (1 s, 200 Hz). Implantation of electrodes in posteroventral GPi was confirmed by postoperative MRI (fig. 1b, c).

During the procedure, dual independently driven microelectrodes (25  $\mu$ m tip length, axes 600  $\mu$ m apart, 0.2–0.4 M $\Omega$  impedance at 1,000 Hz) were used for extracellular recordings at various locations along the track. Recordings were amplified 5,000–10,000 times and filtered at 10–5,000 Hz (analog Butterworth filters: high-pass, one pole; low-pass, two poles) using two Guideline System GS3000 amplifiers (Axon Instruments). Microelectrode data were sampled and digitized at 15 kHz with a CED micro 1401 (Cambridge Electronic Design). Movement of the contralateral arm was monitored by electromyograph (EMG) and accelerometers.

Field potentials were evoked in GPi by stimulating with single pulses at 100  $\mu$ A and 0.3 ms biphasic pulse width from one electrode and were recorded from the second electrode, while electrodes were separated mediolaterally by 0.5–1.0 mm. Different depths were examined in some cases by moving the stimulating electrode in 250  $\mu$ m increments above and below the recording site to confirm that misalignment of microelectrode tip position was not responsible for the absence of cell firing and evoked field potentials (fEP).

### Data Analysis

Spike2 software version 7 (Cambridge Electronic Design) was used for offline analysis of MER. Single-unit firing was extracted



**Fig. 1.** Magnetic resonance imaging scans showing loss of the left putamen preoperatively (**a**, axial section, white arrow indicates lateral border of lesion) and implantation of deep brain stimulation electrodes in the left (**b**) and right (**c**) internal segment of the globus pallidus postoperatively (sagittal sections, white arrows indicate tips of DBS electrodes). **d** High-resolution axial section showing location of electrodes bilaterally.

from raw extracellular recordings using a spike matching template algorithm and confirmed by spike interval analysis. Templates that included spikes that were separated by an interval of less than 2.0 ms were excluded due to an absence of the absolute refractory period.

An in-house burst detection algorithm in MatLab was used to determine the burst index for single units and characterize their firing pattern into regular, random, or bursty as described by Kaneoke and Vitek [16]. Firing rate (Hz) and burst index were averaged across 7–8 single units within each side of GPi. Mean firing rate and burst index were compared between sides by the Student *t* test. Statistical significance was accepted at  $p < 0.05$ .

Poststimulus time histograms (PSTH, bin width = 250  $\mu$ s, time course = 150 ms) were generated based on firing of a single unit, averaged across 9 or more poststimulus intervals. fEPs were averaged within each side across raw traces recorded from various depths along the track.

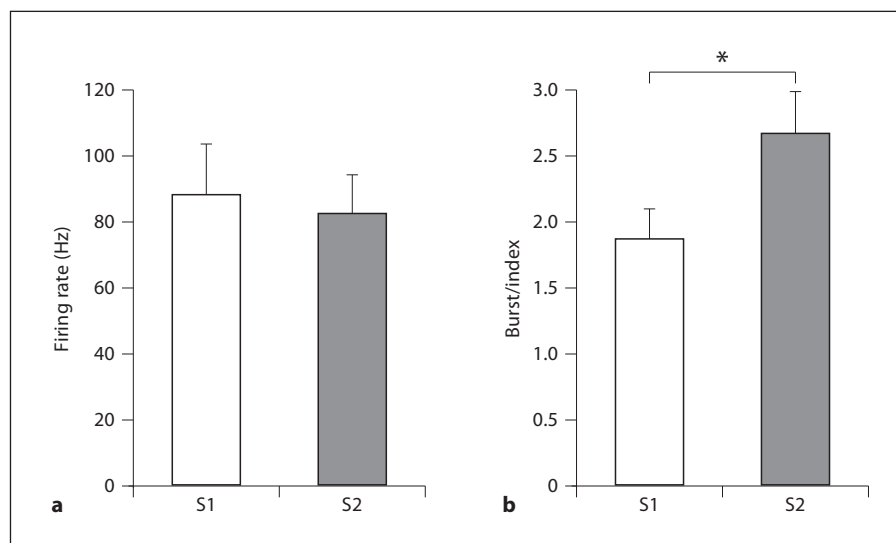
## Results

### *Spontaneous Activity*

A high background noise and a high density of rapidly firing cells characterized GPi on both sides. Most cells fired at a frequency between 70 and 100 Hz. There were no discernable differences in patterns of spontaneous activity among dorsoventral levels in GPi. The mean firing rate of single units in the right side (S1; 87 Hz) was not significantly different compared to that measured in the left side (S2; 82 Hz; fig. 2). However, the mean burst index was significantly higher (1.4-fold,  $p < 0.001$ ) across neurons in S2, suggesting greater bursting in S2 compared to more stable firing in S1. The burst detection algorithm further characterized the firing pattern of all neurons analyzed in S1 as ‘regular’. Of neuronal firing



**Fig. 2.** Neuronal firing rates and bursting in the internal segment of the GPi. **a** Single-unit firing rates are averaged within S1 (intact putamen,  $n = 8$ ) and S2 (degenerated putamen,  $n = 7$ ). The mean firing rate did not differ significantly between sides. **b** Burst index values for single units are averaged within S1 ( $n = 8$ ) and S2 ( $n = 7$ ). The average burst index was significantly greater within S2 (\*  $p < 0.001$ ), suggesting a greater occurrence of bursting neurons.



patterns analyzed in S2, 42.9% were characterized as 'regular', 28.6% as 'bursty', and 28.6% as 'random'.

#### Results: fEP

Field potentials evoked by single pulse stimulation at multiple sites in S1 were positive extracellular potentials (fig. 3). The mean peak amplitude (122  $\mu$ V) had a latency of 3.9 ms (fig. 3a). A PSTH showed an inhibition of cell firing during the peak of the fEP (fig. 3b). Cell firing resumed 20 ms poststimulus and the firing rate rapidly returned to a stable baseline. In comparison, no fEP could be evoked in S2, despite the presence of a similar stimulus artifact (fig. 3c). A PSTH did not show any pause in cell firing, and the firing rate showed greater fluctuations compared with S1 (fig. 3d).

#### Clinical Follow-Up

The patient developed right hemiparesis and speech impairment soon after surgery. This was attributed to the stress of the operation on a previously injured brain as postoperative MRI did not show evidence of acute bleeding or ischemic stroke. At 1 month of follow-up, almost complete recovery from these new signs was observed, although speech impairment was still noticeable. Compared to preoperative assessment, the patient reported a substantial improvement in pain and 38% improvement in BFMDRS movement score (fig. 4). There was a marked improvement in his dystonic tremor and no trunk spasms were seen. He no longer had dystonia of the left arm or leg. He could now write with his right hand, with some difficulty. Stimulator parameters were optimized to 60  $\mu$ s pulse width and 130

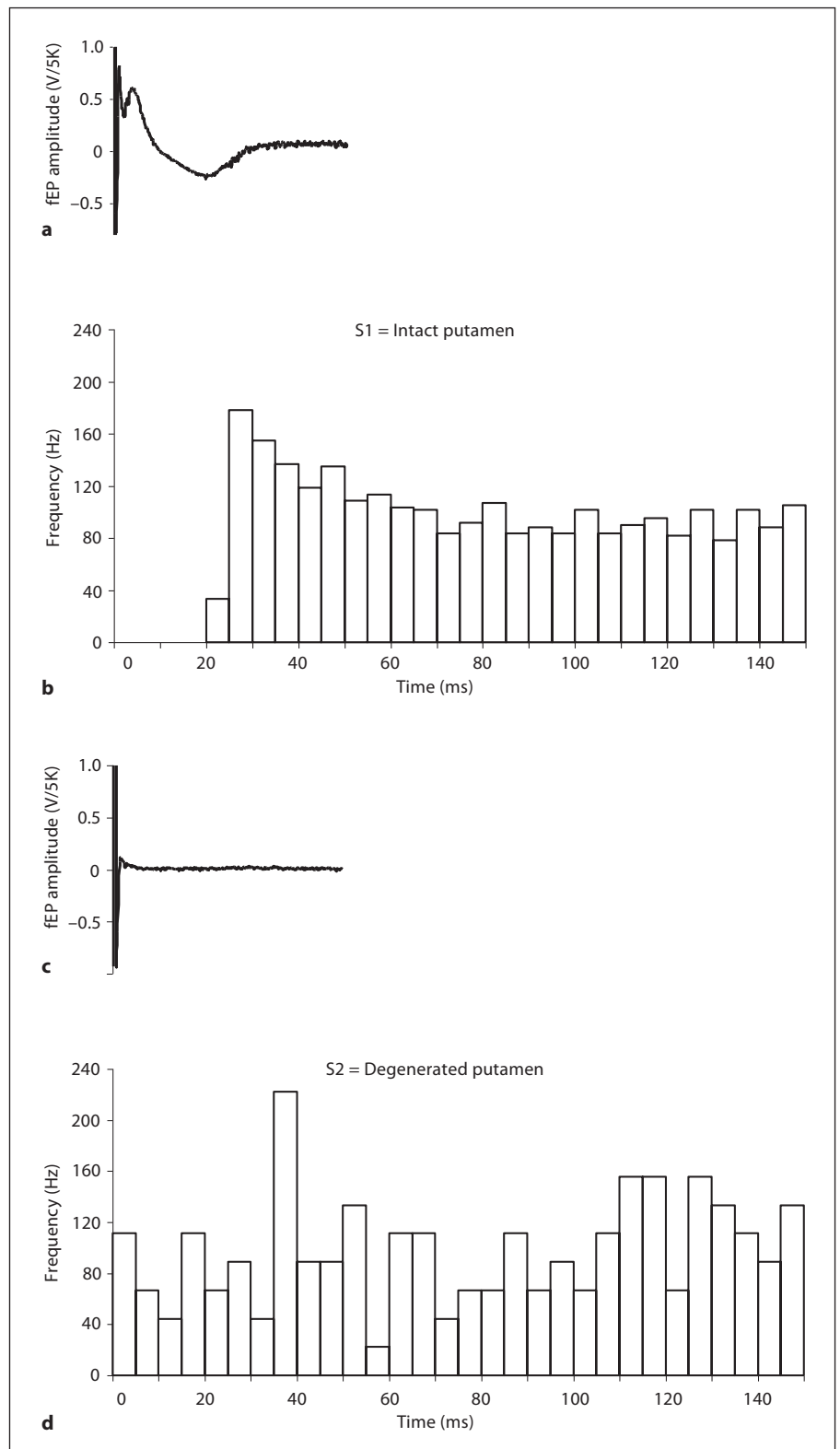
Hz frequency on both sides, with amplitude 2.3 V in S1 (contact C+ 1-) and 1.6 V in S2 (contact C+ 5-).

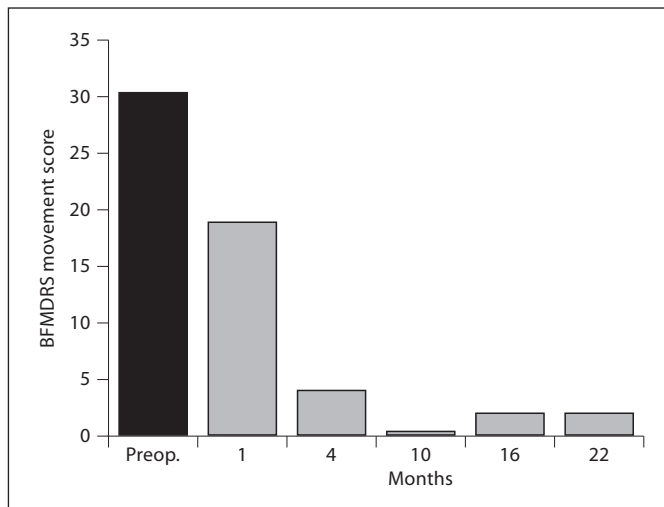
The patient demonstrated further marked improvements at follow-up 3 months later, including complete amelioration of his trunk dystonia and improvement in severity of right arm dystonia and pulling of the neck. His speech was no longer affected. All subsequent follow-up examinations were made at Kitano Hospital in Osaka, Japan. During the subsequent 6 months, the patient's right arm and leg dystonia were resolved. At most recent examination (22 months postoperative), only mild neck dystonia was seen to persist, accompanied by mild pain. The BFMDRS movement score was 2 (fig. 4). Although his gait was still abnormal, this was less exaggerated compared to preoperative assessment. He no longer experienced tremors, clumsiness, or trouble with fine motor tasks and could write without difficulty. Stimulator parameters were adjusted several times since the surgery. Current parameters are 90  $\mu$ s pulse width and 160 Hz frequency on both sides, with amplitude 3.8 V in S1 (contact C+ 1-) and 3.0 V in S2 (contact C+ 5-).

#### Discussion

This patient with hemidystonia and severe damage to the left BG markedly improved after bilateral GPi DBS, despite the delayed onset and delayed treatment. The clinical presentation of some generalized dystonic features was surprising considering that brain MRI revealed only unilateral lesions to BG. To our knowledge, the oc-

**Fig. 3.** PSTH of neuronal fEP in the internal segment of the GPi. Traces show mean fEP recorded from S1 (n = 160; **a**) and S2 (n = 99; **c**) of the GPi overlaid on a PSTH of the same time course (**b**, **d**). The stimulus artifact appears at t = 0 s on both fEP traces. The positive peak of the fEP in S1 occurs during inhibition of neuronal firing. In S2, neither the fEP nor inhibition of neuronal firing were detected after stimulus.





**Fig. 4.** Preoperative and postoperative BFMDRS movement scores.

currence of generalized dystonic features in patients with unilateral structural lesions has not been reported, although inter-hemispheric connections between BG nuclei have been shown [17]. Alternatively, partial damage not revealed by the 1.5-T resolution of the brain MRI could have also affected the right BG, inducing dystonic contractions of the contralateral muscles.

That the mean firing rate of GPi neurons was not significantly different between sides might also seem surprising given that GPi is an output nucleus of the BG and influences the excitability of motor cortical areas and the muscles that these areas program [12]. In many previous cases, GPi neurons in patients with dystonia were found to discharge at a lower frequency compared with the healthy population [5–8]; however, those in the present study fired at a mean frequency of 82–87 Hz, which is typical for GPi [18]. This suggests that a reduction in absolute firing rate of GPi neurons is not sufficient for the development of dystonia in all cases.

Instead, an alteration in the pattern of discharge of pallidal neurons may be ultimately responsible for dystonic symptoms. Consistent with this hypothesis, pallidal neurons in the left side of BG (S2, degenerated putamen) showed a less regular firing pattern and more bursts compared with S1. Left GPi contains a topographic representation of the right side of the body [19], in which the patient's dystonia was more pronounced and clinically relevant. Bursting in neurons of GPi has previously been associated with primary dystonia [20], and may alter the

activity of target sensorimotor neurons in the thalamus through temporal summation of inhibitory postsynaptic potentials.

While the spontaneous firing pattern describes tonic activity in GPi, the fEP represents the combined phasic activity of several neuronal elements. The absence of the fEP in left GPi (S2, degenerated putamen) compared with a robust fEP in the contralateral side suggests that putamenal fibers terminating in GPi are primarily responsible for this inhibitory field. These fibers account for 70% of all those terminating in GPi [21]. While previous results in a primate model of dystonia demonstrated an overactivity of the direct striatopallidal pathway [22], a complete loss of function of this pathway was seen here. Striatal projection neurons are not tonically active but discharge phasically [23]. Their death thus represents the loss of the major phasic GABAergic input to GPi.

While transient inhibitory postsynaptic potentials mediated by GABA<sub>A</sub> channels [24] are thought responsible for the inhibition of neuronal firing in the intact side of GPi, neuronal firing was random and uninhibited in the partially deafferented side. A consequence of this loss of phasic control may be a less precise selection of intended muscles during voluntary movement, represented by GPi neurons inhibited by direct striatopallidal projections. A second consequence may be a less precise inhibition of unintended muscles, represented by GPi neurons released from inhibition by the indirect pathway [25]. The result may be the co-contraction of opposing muscles during voluntary movements, which is a hallmark of dystonia [20].

The benefits of DBS for secondary dystonia have been inconsistent, varying from overwhelmingly positive in some cases of tardive dystonia [26], to less robust in other cases arising from various cerebral insults [27] (for review, see [28]). Loher et al. [29] have reported a long-term (10 years) follow-up showing 50% improvement of pain, dystonia and tremor after unilateral GPi DBS in a case of hemidystonia secondary to post-traumatic injury at age 24. Kang et al. [30] recently presented a case of post-traumatic hemidystonia showing onset in the right foot and moving to the ipsilateral arm 1 year after the incident. Unilateral GPi DBS improved the foot dystonia moderately from a BFMDRS movement score of six to a score of two. From their review of hemidystonia cases, the authors suggest that benefit from DBS may be dependent on the lesion being small and discrete. Our results do not support this finding, since we observed GPi DBS to produce marked improvement for hemidystonia secondary to a large lesion.

In the present study, the latency of development of dystonia was approximately a decade, and once established, dystonic symptoms and pain advanced and worsened with time. A similar delay in the advance of the disease was reported in a case of generalized dystonia secondary to bilateral striatal necrosis caused by mitochondrial DNA mutations [14]. The delayed onset of dystonia and its progression in spite of a seemingly static injury raises questions concerning the cellular mechanisms involved. Previous studies have considered injury-induced aberrant neuronal sprouting, transsynaptic neuronal degeneration or receptor supersensitivity secondary to denervation as possible explanations for the appearance of delayed brain lesions [31, 32].

Although successful in treating many forms of dystonia, the mechanism of DBS is unclear. Of the many possible modes of action suggested in the literature, the lack of an inhibitory field in left GPi suggests that repetitive high frequency stimulation by the active DBS contact could not be driving GABA inhibitory input to GPi in this patient in order to normalize or silence abnormal neuronal activity. Nor is it likely that antidromic activation of striatum was involved in therapeutic effects, since much of it was not present; more likely is a 'downstream' effect on motor thalamus.

The early therapeutic effects on phasic dystonic movements and pain and further gradual improvements in dystonic symptoms experienced by our patient over the following months are consistent in pattern with improvements in other dystonia patients that underwent implantation of bilateral DBS electrodes [33]. Gradual improve-

ments may be indicative of slow, plastic changes occurring in the BG or downstream targets. These may have compensated or corrected for the virtual lack of phasic inhibitory input to GPi during voluntary movements, the presence of abnormal patterns of spontaneous activity in GPi neurons, or both phenomena.

Further results are needed to determine whether implantation of unilateral or bilateral DBS electrodes in posteroventral GPi is indeed indicated for patients with dystonia secondary to degeneration of the putamen or other BG nuclei. Intraoperative recordings from these procedures might reveal more concerning the common correlates of diverse cases of dystonia and assist towards a better understanding of its physiological basis and treatment; however, clinical outcomes from pallidal and thalamic stimulation will likely remain variable among patients.

### Acknowledgements

The authors would like to thank Ms. Yu-Yan Poon, RN, for helping provide clinical data for the study. Support from CIHR MOP 98006, Dystonia Medical Research Foundation and Medtronic Inc. (W.D.H.) is gratefully acknowledged.

### Disclosure Statement

W.D. Hutchison, E. Moro and A. Lozano have had grants and/or travel funds and/or lecture honoraria from Medtronic Inc.

### References

- Ostrem JL, Starr PA: Treatment of dystonia with deep brain stimulation. *Neurotherapeutics* 2008;5:320–330.
- Wadia PM, Lang AE, Moro E: Selecting appropriate dystonic patients for GPi stimulation; in Bain P, Aziz T, Liu X, Nandi D (eds): *Deep Brain Stimulation*. New York, Oxford University Press, 2009, pp 107–114.
- Eltahawy HA, Saint-Cyr J, Giladi N, Lang AE, Lozano AM: Primary dystonia is more responsive than secondary dystonia to pallidal interventions: outcome after pallidotomy or pallidal deep brain stimulation. *Neurosurgery* 2004;54:613–621.
- Ozelius LJ, Hewett JW, Page CE, Bressman SB, Kramer PL, Shalish C, et al: The early-onset torsion dystonia gene (DYT1) encodes an ATP-binding protein. *Nat Genet* 1997;17:40–48.
- Vitek JL, Chockkan V, Zhang JY, Kaneoke Y, Evatt M, DeLong MR, et al: Neuronal activity in the basal ganglia in patients with generalized dystonia and hemiballismus. *Ann Neurol* 1999;46:22–35.
- Sanghera MK, Grossman RG, Kalhorn CG, Hamilton WJ, Ondo WG, Jankovic J: Basal ganglia neuronal discharge in primary and secondary dystonia. *Adv Neurol* 2004;94:29–36.
- Starr PA, Rau GM, Davis V, Marks WJ, Jr, Ostrem JL, Simmons D, et al: Spontaneous pallidal neuronal activity in human dystonia: comparison with parkinson's disease and normal macaque. *J Neurophysiol* 2005;93:3165–3176.
- Tang JK, Moro E, Mahant N, Hutchison WD, Lang AE, Lozano AM, et al: Neuronal firing rates and patterns in the globus pallidus internus of patients with cervical dystonia differ from those with Parkinson's disease. *J Neurophysiol* 2007;98:720–729.
- Vidailhet M, Vercueil L, Houeto JL, Krystkowiak P, Benabid AL, Cornu P, et al: Bilateral deep-brain stimulation of the globus pallidus in primary generalized dystonia. *N Engl J Med* 2005;352:459–467.
- Kupsch A, Benecke R, Muller J, Trottenberg T, Schneider GH, Poewe W, et al: Pallidal deep-brain stimulation in primary generalized or segmental dystonia. *N Engl J Med* 2006;355:1978–1990.

- 11 Andrews C, Aviles-Olmos I, Hariz M, Foltynie T: Which patients with dystonia benefit from deep brain stimulation? A metaregression of individual patient outcomes. *J Neurol Neurosurg Psychiatry* 2010; 81:1383–1389.
- 12 Berardelli A, Rothwell JC, Hallett M, Thompson PD, Manfredi M, Marsden CD: The pathophysiology of primary dystonia. *Brain* 1998;121:1195–1212.
- 13 Krystkowiak P, Martinat P, Defebvre L, Pruvo JP, Leys D, Destee A: Dystonia after striatopallidal and thalamic stroke: clinicoradiological correlations and pathophysiological mechanisms. *J Neurol Neurosurg Psychiatry* 1998;65:703–708.
- 14 Aniello MS, Martino D, Petruzzella V, Eleopra R, Mancuso M, Dell'Aglia R, et al: Bilateral striatal necrosis, dystonia and multiple mitochondrial DNA deletions: case study and effect of deep brain stimulation. *Mov Disord* 2008;23:114–118.
- 15 Hutchison WD, Lozano AM, Davis KD, Saint-Cyr JA, Lang AE, Dostrovsky JO: Differential neuronal activity in segments of globus pallidus in Parkinson's disease patients. *Neuroreport* 1994;5:1533–1537.
- 16 Kaneoke Y, Vitek JL: Burst and oscillation as disparate neuronal properties. *J Neurosci Methods* 1996;68:211–223.
- 17 Torres CV, Moro E, Dostrovsky JO, Hutchison WD, Poon YY, Hodaie M: Unilateral pallidal deep brain stimulation in a patient with cervical dystonia and tremor. *J Neurosurg* 2010;113:1230–1233.
- 18 Hutchison WD, Lang AE, Dostrovsky JO, Lozano AM: Pallidal neuronal activity: Implications for models of dystonia. *Ann Neurol* 2003;53:480–488.
- 19 Baker KB, Lee JY, Mavinkurve G, Russo GS, Walter B, DeLong MR, et al: Somatotopic organization in the internal segment of the globus pallidus in Parkinson's disease. *Exp Neurol* 2010;222:219–225.
- 20 Vitek JL, Zhang J, Evatt M, Mewes K, DeLong MR, Hashimoto T, et al: GPi pallidotomy for dystonia: clinical outcome and neuronal activity. *Adv Neurol* 1998;78:211–219.
- 21 Shink E, Smith Y: Differential synaptic innervation of neurons in the internal and external segments of the globus pallidus by the GABA- and glutamate-containing terminals in the squirrel monkey. *J Comp Neurol* 1995; 358:119–141.
- 22 Mitchell IJ, Luquin R, Boyce S, Clarke CE, Robertson RG, Sambrook MA, et al: Neural mechanisms of dystonia: evidence from a 2-deoxyglucose uptake study in a primate model of dopamine agonist-induced dystonia. *Mov Disord* 1990;5:49–54.
- 23 Nambu A: Globus pallidus internal segment. *Prog Brain Res* 2007;160:135–150.
- 24 Kita H: Neostriatal and globus pallidus stimulation induced inhibitory postsynaptic potentials in entopeduncular neurons in rat brain slice preparations. *Neuroscience* 2001; 105:871–879.
- 25 Mink JW: The basal ganglia: focused selection and inhibition of competing motor programs. *Prog Neurobiol* 1996;50:381–425.
- 26 Trottenberg T, Volkmann J, Deuschl G, Kuhn AA, Schneider GH, Muller J, et al: Treatment of severe tardive dystonia with pallidal deep brain stimulation. *Neurology* 2005;64:344–346.
- 27 Cif L, El Fertit H, Vayssiere N, Hemm S, Hardouin E, Gannau A, et al: Treatment of dystonic syndromes by chronic electrical stimulation of the internal globus pallidus. *J Neurosurg Sci* 2003;47:52–55.
- 28 Krauss JK: Deep brain stimulation for dystonia in adults. Overview and developments. *Stereotact Funct Neurosurg* 2002;78:168–182.
- 29 Lohr TJ, Capelle HH, Kaelin-Lang A, Weber S, Weigel R, Burgunder JM, Krauss JK: Deep brain stimulation for dystonia: outcome at long-term follow-up. *J Neurol* 2008; 255:881–884.
- 30 Kang DW, Kang JH, Lee MS, Chang JW: Posttraumatic hemidystonia treated with unilateral globus pallidus interna stimulation: long-term follow-up and radiologic features. *Neuromodulation* 2010;13:261–264.
- 31 Marsden CD, Obeso JA, Zarranz JJ, Lang AE: The anatomical basis of symptomatic hemidystonia. *Brain* 1985;108:463–483.
- 32 Pettigrew LC, Jankovic J: Hemidystonia: a report of 22 patients and a review of the literature. *J Neurol Neurosurg Psychiatry* 1985; 48:650–657.
- 33 O'Riordan S: The results of GPi stimulation for generalized dystonia; in Bain P, Aziz T, Liu X, Nandi D (eds): *Deep Brain Stimulation*. New York, Oxford University Press, 2009, pp 115–125.