

## References

1. Gauden AJ, Khurana VG, Tsui AE, et al. Intracranial neuroenteric cysts: a concise review including an illustrative patient. *J Clin Neurosci* 2012;**19**: 352–9.
2. Perrini P, Rutherford SA, King AT, et al. Enterogenous cysts of the cerebellopontine angle: short review illustrated by two new patients. *Acta Neurochir (Wien)* 2008;**150**:177–84 [discussion 184].
3. Wang L, Zhang J, Wu Z, et al. Diagnosis and management of adult intracranial neuroenteric cysts. *Neurosurgery* 2011;**68**:44–52 [discussion 52].

doi:<http://dx.doi.org/10.1016/j.jocn.2012.04.026>

## Hemichorea caused by intracranial hemorrhage following contralateral herpes zoster ophthalmicus

Min-Ji Kim<sup>a</sup>, Kee Ook Lee<sup>a,b,\*</sup>, Kyung-Yul Lee<sup>b</sup>, Seung Hun Oh<sup>c</sup>, Sang-Jun Na<sup>a</sup>, Bora Yoon<sup>a</sup>, Yong-Duk Kim<sup>a</sup>

<sup>a</sup> Department of Neurology, College of Medicine, Konyang University, 685 Gasuwon-dong, Seo-gu, Daejeon-city 302-718, Republic of Korea

<sup>b</sup> Departments of Neurology, Yonsei University College of Medicine, Seoul, Republic of Korea

<sup>c</sup> Department of Neurology, CHA University College of Medicine, Seongnam, Republic of Korea

### ARTICLE INFO

#### Article history:

Received 17 February 2012

Accepted 14 April 2012

#### Keywords:

Hemichorea

Herpes zoster ophthalmicus

Intracranial hemorrhage

### ABSTRACT

A healthy, 66-year-old, right-handed man was admitted to our university hospital and diagnosed with herpes zoster ophthalmicus (HZO). After 4 weeks, he complained of hemichorea on his left side. Brain MRI showed a focal hemorrhage in the right subthalamic area. No evidence of aneurysmal lesion or cerebral angiitis was observed on cerebral angiography.

© 2012 Elsevier Ltd. All rights reserved.

### 1. Introduction

Herpes zoster ophthalmicus (HZO) with delayed contralateral hemiplegia is a widely known syndrome. It was first reported by Dumary in 1896.<sup>1</sup> This syndrome has since formed a separate clinical disease entity, although it has been reported rarely.

HZO with delayed contralateral hemiplegia is primarily associated with ipsilateral cerebral infarction.<sup>2</sup> However, a few incidences of this syndrome have been reported caused by intracranial hemorrhage.<sup>3,4</sup> We describe a patient with hemichorea caused by intracranial hemorrhage following contralateral HZO.

### 2. Case report

A healthy, 66-year-old, right-handed man was admitted to our university hospital because of lethargy, a vesicular rash and severe pain of the right forehead. He had no history of hypertension, diabetes or other medical problems. His skin was denuded and rough, and a vesicular rash had spread on the right ophthalmic branch area of the trigeminal nerve. He was diagnosed with HZO and treated with acyclovir 1800 mg daily for 2 weeks. After 3 weeks, his symptoms were nearly fully resolved, except a mild tingling sensation in the right orbitofrontal area.

After 4 weeks, the patient complained of acute onset of hemichorea on the left side. He also complained of mild dysarthria and dysphagia. The right pupil was circular and slightly larger than that on the left. Both pupils reacted briskly to light and accommodation. Bilateral corneal reflexes were intact. Visual fields, visual acuity and ocular movements were also normal, and there was no Keyser-Fleischer ring. There was no past history of

rheumatic fever, neuroleptic drugs, jaundice or hepatic disease or collagen vascular diseases. The hemichoreic movements consisted extension and flexion of the left fingers, rotatory supination and pronation of the left forearm and shoulder shrugging, and these were more prominent in the upper extremity. The results of routine laboratory and specialized tests, including thyroid function test, serum lead level, antistreptolysin O, anti-streptokinase antibody, rheumatoid factor, lupus anticoagulant, antinuclear antibody, anti dsDNA, antiphospholipid antibody, antineutrophil cytoplasmic antibody and anti-Ro/La antibody, were normal.

On the day of symptom onset, MRI showed focal hemorrhage in the right subthalamic area (Fig. 1). Two days after his admission to hospital, cerebral angiography showed no cerebral vascular abnormality or aneurysmal lesion.

After 2 weeks, his hemichorea gradually reduced. After 1 month, the hemichorea developed only for a few seconds when he changed posture. He had no hemiparesis, sensory change or other neurological sequelae. Two months after the onset of symptoms, his hemichorea was completely resolved.

### 3. Discussion

A lesion of the subthalamic nucleus (STN) may cause a loss of subthalamic excitation in the medial pallidum. It can also reduce striato-pallidal inhibitory influences and lead to reduced excitatory projections from the STN to the pars interna of the globus pallidus followed by disinhibition of the thalamic neurons.<sup>5</sup>

In the present patient, a lesion in the subthalamic region was likely to be responsible for the hemichorea. There were no other significant abnormalities that may have induced hemichorea.

The pathophysiology of HZO with delayed contralateral hemiplegia is controversial, although many authors have attempted to clarify it. It may be associated with cerebral granulomatous angii-

\* Corresponding author. Tel.: +82 42 600 8814; fax: +82 42 545 0050.  
E-mail address: niceiatros@naver.com (K.O. Lee).

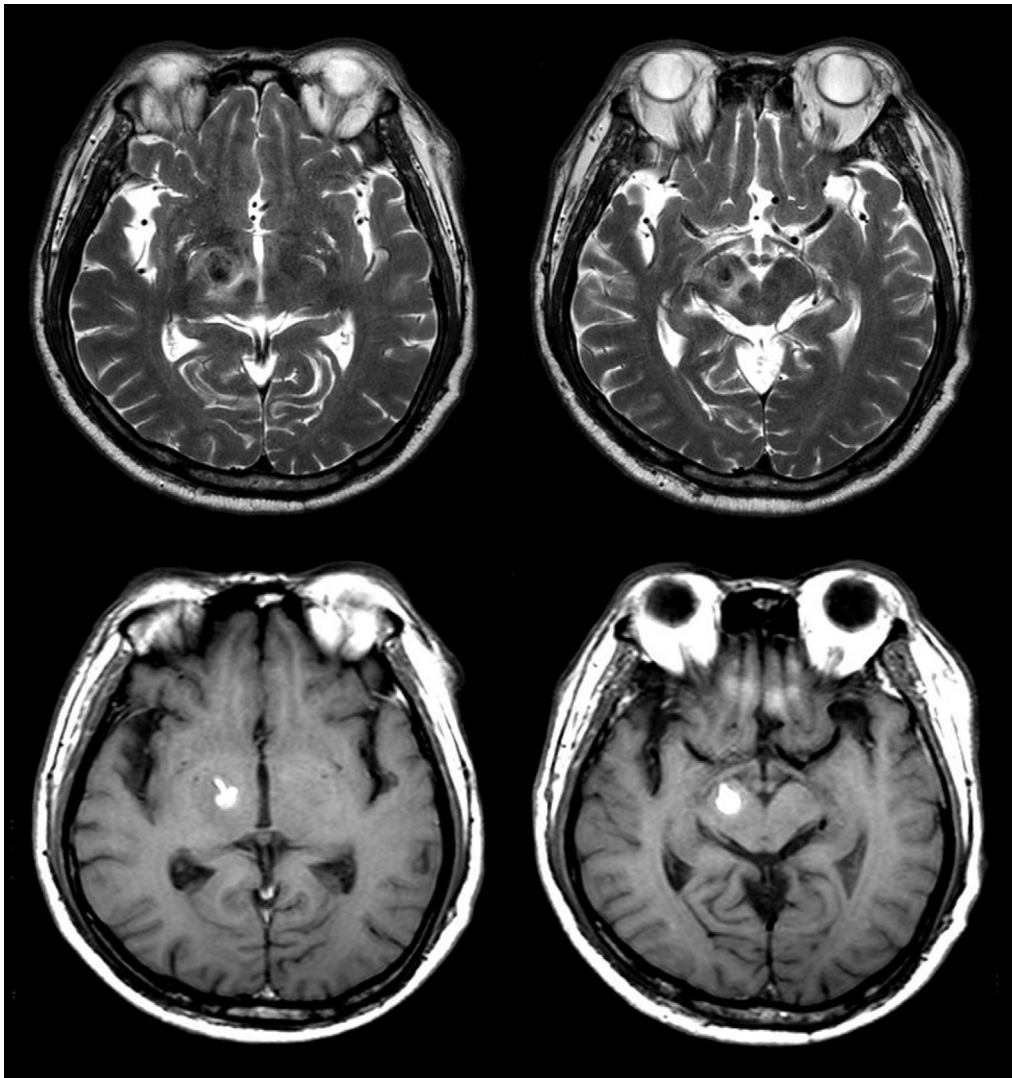


Fig. 1. Axial T2-weighted MRI (upper row) and T1-weighted MRI (lower row) showing acute focal hemorrhage in the right subthalamic area.

tis.<sup>2,6</sup> Autopsy studies have also reported small vessel arteritis in the posterior circulation.<sup>6</sup>

Many hypotheses have been proposed regarding the pathophysiology of involvement of the central nervous system in HZO. Diffuse invasion with vascular thrombosis, local tissue invasion, perivascular infiltration and a direct invasion by the virus are some of the hypotheses investigated.<sup>7</sup> Among them, direct viral invasion of blood vessels is believed to be the most probable mechanism.<sup>6,8</sup> Electron microscopy has revealed virus-like particles in the outer layers of vessel walls, but not in the endothelial cells. These results support the hypothesis of direct viral invasion of blood vessels, possibly by contiguous spread from cranial nerves.<sup>6,8</sup>

Considering other risk factors and the timing of the symptoms, hemorrhage in this case appears to be closely related to the HZO. This was thought to be a primary hemorrhage. But, we must also consider the possibility of hemorrhagic transformation of an initial ischemic lesion.

Even though a brain biopsy was not performed, there was no evidence of cerebral angiitis in the cerebral angiography. This suggested other possible factors associated with the pathophysiology

could be present, in addition to cerebral vasculitis. We considered the possibility of hematogenous spread. However, we suggest that localized angiitis was the most likely cause of hemorrhage in this patient. Further studies are needed to elucidate the exact pathophysiology.

## References

- Hilt DC, Buchholz D, Krumholz A, et al. Herpes zoster ophthalmicus and delayed contralateral hemiparesis caused by cerebral angiitis: diagnosis and management approaches. *Ann Neurol* 1983;**14**:543–53.
- Bourdette DN, Rosenberg NL, Yatsu FM. Herpes zoster ophthalmicus and delayed ipsilateral cerebral infarction. *Neurology* 1983;**33**:1428–32.
- Mossuto-Agatiello L, Iovine C, Kniahynicki C. Herpes zoster ophthalmicus and delayed ipsilateral intracerebral hemorrhage. *Neurology* 1987;**37**:1264–5.
- Elble RJ. Intracerebral hemorrhage with herpes zoster ophthalmicus. *Ann Neurol* 1983;**14**:591–2.
- Alexander GE, Crutcher MD. Functional architecture of basal ganglia circuits: neural substrates of parallel processing. *Trends Neurosci* 1990;**13**:266–71.
- Linnemann Jr CC, Alvira MM. Pathogenesis of varicella-zoster angiitis in the CNS. *Arch Neurol* 1980;**37**:239–40.
- Tojo K, Onozawa T, Toyohara K, et al. Herpes zoster ophthalmicus with delayed contralateral hemiparesis. *Jpn J Med* 1990;**29**:99–103.
- MacKenzie RA, Forbes GS, Karnes WE. Angiographic findings in herpes zoster arteritis. *Ann Neurol* 1981;**10**:458–64.