
Clinical Correspondence

Type III Sturge-Weber Syndrome With Migraine-Like Attacks Associated With Prolonged Visual Aura

Hung Yu Huang, MD; Kang-Hsu Lin, MD; Jui-Cheng Chen, MD; Yi-Ting Hsu, MD

Sturge-Weber syndrome is known to be associated with migraine attacks and prolong aura even without cerebral infarction. We report the case of a 36-year-old woman with type III Sturge-Weber syndrome developing with prolonged left homonymous hemianopsia after an intractable migraine-like headache and becoming a permanent visual field defect at 18-month follow up. By adopting a multimodality imaging study, we suggested that the underlying mechanism of prolonged visual field defect was due to blood flow disturbance and vasogenic leakage under the leptomeningeal angioma combining with atrophy and the damaged integrity of white matter in right occipital lobe.

Key words: Sturge-Weber syndrome, migraine, prolonged visual aura

Abbreviations: DTI diffuse tensor imaging, SPECT single photon emission computed tomography, SWS Sturge-Weber syndrome, VAS visual analog scale

(*Headache* 2013;53:845-849)

Sturge-Weber syndrome (SWS) is a neurocutaneous disorder with congenital unilateral port-wine nevus, leptomeningeal angioma, or abnormal blood vessels in the eye. SWS can be subdivided into type I (facial and leptomeningeal angioma), type II (facial angioma without intracranial involvement), and type III (leptomeningeal angioma without facial nevus). Type III SWS is a rare variant. The clinical features of SWS include epilepsy, hemiplegia, mental retardation, and glaucoma.¹ Migraine-like headache with

transient neurological deficits including hemiplegia and hemianopsia is also a recognized manifestation.²⁻⁴ Prolong homonymous hemianopia becoming permanent visual loss without cerebral infarction is, however, rarely reported. Here, we describe the clinical manifestation and treatment response of a patient with type III SWS, who had migraine-like attacks with prolonged visual field defect. We also review the mechanism further by adopting a multimodality imaging study.

CASE REPORT

The 36-year-old woman was admitted due to intractable headache with prolonged visual aura. Her psychomotor development was normal, and family history was negative for migraine. At the age of 10, she began to have headaches 1-2 times per year, pulsating in character, predominantly locating in right occipital area. The headache was always preceded by

From the Neuroscience Laboratory, Department of Neurology, China Medical University Hospital, Taichung, Taiwan (H.Y. Huang, K-H. Lin, J-C. Chen, and Y-T. Hsu); School of Medicine, Medical College, China Medical University, Taichung, Taiwan (H.Y. Huang, K-H. Lin, J-C. Chen, and Y-T. Hsu).

Address all correspondence to Y-T. Hsu, Department of Neurology, China Medical University Hospital, Taichung 404, Taiwan.

Accepted for publication December 13, 2012.

Conflict of Interest: None.

sudden onset of visual aura such as bright scintillation or foggy blurring vision, which usually started within 30 minutes before headache and disappeared when the headache subsided, typically within 30 minutes to 1 hour. One week before admission, she began to see bright scintillation followed by visual blurring in the left visual field and occipital headache. The headache was moderate to severe, visual analog scale (VAS) 8-9, aggravated by routine physical activity and associated symptoms of photophobia and nausea. She suffered from intractable migrainous headache consecutively for 21 days along with persistent vision loss in the left visual field even after the headache resolved. Before this event, she had taken oral pills for 3 days because of dysmenorrhea.

No facial angioma was found on physical examination. She had left visual field defect on confrontation test and Goldmann perimetry (Fig. A). Routine blood tests and coagulation profile were within the normal range. Neither a history of seizures nor cognitive deterioration was documented. The electroencephalogram (EEG) conducted during headache with vision loss did not show epileptic activity. Brain computed tomography revealed gyriform calcification in the right occipital lobe (Fig. B). Diffusion-weighted magnetic resonance imaging (MRI) was unremarkable (Fig. C) and enhanced T1 MRI, with gadolinium-diethylenetriaminepentacetate (DTPA) revealed increased gyriform enhancement and atrophy of the right occipital lobe (Fig. D). Conventional angiography did not find vascular malformations. These findings were compatible with pial angioma, and type III SWS was diagnosed. We ascribed her headache with prolong visual aura to leptomeningeal angiomatosis according to the second

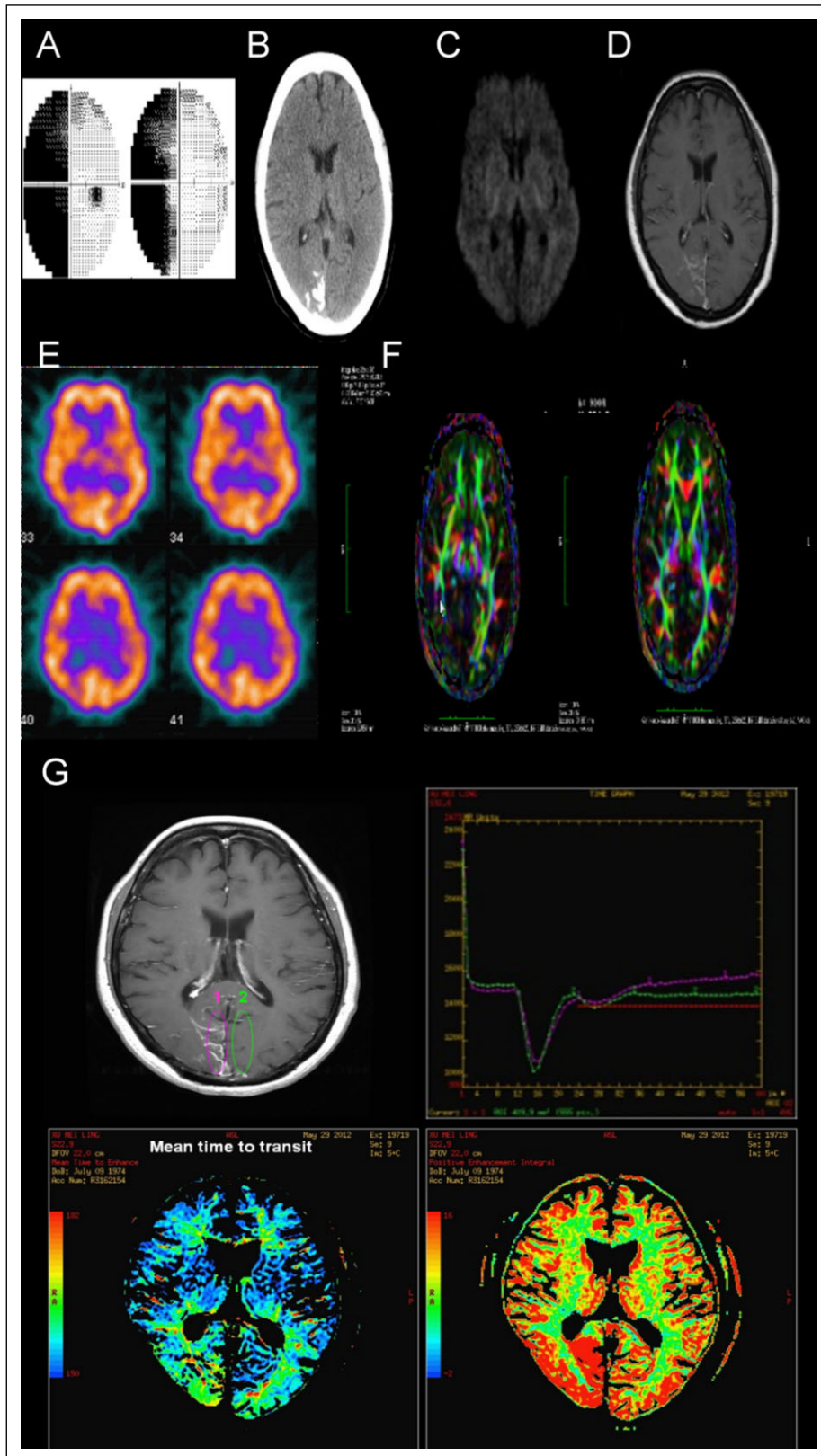
edition of International Classification of Headache Disorders.⁵

Brain perfusion single photon emission computed tomography (SPECT) performed at day 14 after headache onset revealed hypoperfusion in the right occipital lobe when headache and vision loss persisted (Fig. E). Diffuse tensor imaging (DTI) color maps showed severe loss and disorganization of white matter in the right occipital area (Fig. F). Nonsteroidal anti-inflammatory drugs, valproic acid, and flunarizine were administered for migraine-like attacks and aspirin for vasomotor disturbance, and the headache improved gradually to VAS 1 at day 21. Two months later, another migraine-like attack with visual aura manifested and persisted for 2 weeks. That particular attack was relieved after using dihydroergotamine and nonsteroidal anti-inflammatory drugs. Follow-up brain MRI at 1 year after discharge did not disclose new lesion, but a dynamic perfusion study showed venous contrast leakage in the right occipital lobe (Fig. G). The patient continued to take aspirin, valproic acid, and flunarizine and has not suffered from severe headache with persistent left visual field defect at 18-month follow up.

DISCUSSION

The mechanism of migrainous attacks in SWS is suggested to be chronic focal ischemia, abnormal venous outflow, and subsequent impaired neuronal function, which might lower the threshold for cortical spreading depression and increase the susceptibility of the migrainous attacks.¹⁻⁴ As for migraine with prolonged aura, there are some reports elucidating the possible pathophysiology. Iizuka et al³ described a case of SWS with episodes of migraine headaches

Figure.—(A) Goldmann perimetry during acute phase of headache confirmed the presence of left homonymous hemianopsia. (B) Cranial computed tomography revealed gyriform calcifications in the right occipital lobe. (C) The finding of diffusion-weighted brain magnetic resonance imaging (MRI) was unremarkable. (D) Postgadolinium T1-weighted MR images showed a pial angioma in the right occipital lobe. (E) Brain perfusion single photon emission computed tomography revealed reduced cerebral blood flow in the right occipital area. (F) Diffuse tensor imaging color vector map image showed loss and disorganization of white matter in the right occipital area (arrow). Fiber directions are color-coded based and are assigned to the colors of red (left–right direction), green (anteroposterior direction), and blue (superior–inferior direction). (G) Followed up MRI at 1 year, postgadolinium T1-weighted MR images showed similar finding as 1 year ago. On the MR perfusion time intensity curve(right upper panel), data from bolus tracking MR perfusion studies are obtained dynamically as the contrast bolus passes through the brain. This area (voxel 1, magenta curve) shows similar arterial bolus arrival and venous clearance in comparing to the left occipital lobe (voxel 2, green curve, a normal brain area). However, after venous clearance of contrast, there was higher intensity in magenta curve, right occipital lobe, which might suggest the occurrence of venous contrast leakage (right lower panel).



associated with prolonged visual field deficits, which were completely resolved within 3 weeks. They suggested that migraine in SWS might result from an increased vasogenic leakage of plasma and neuropeptides, producing neuronal dysfunction and vasodilatation in the corresponding cortex. Another report related to a 21-year-old SWS case developing a prolonged attack of hemiplegic migraine that resolved in 2 weeks. Complex changes of both cerebral and glucose metabolism contributed to the clinical manifestation.² However, focal neurologic defect associated with migraine-like events in SWS is not always benign and could become permanent. Shimakawa et al previously reported permanent visual loss after migraine-like attacks in SWS. They speculated that the recurrence of blood flow disturbance caused by the pial angioma might have caused a cerebral infarction resulting in an irreversible visual field defect.⁶ Although our patient did not have acute cerebral infarction, the occurrence of vasogenic leakage and perfusion impairment might suggest a breakdown of the blood-brain barrier and ischemic injury with neuronal dysfunction of right occipital lobe underlying the leptomeningeal angioma, which correlated closely with a permanent visual field defect.

The severity of white matter atrophy was associated with clinical impairment in cognition and fine motor function in SWS. Low brain tissue perfusion and hypoxic injury due to impaired venous drainage of affected brain tissue leading to progressive neuronal death, astrogliosis, and atrophy were considered as the putative mechanism causing white matter injury.⁷ An advanced MRI study using susceptibility-weighted imaging and DTI revealed microstructural white matter damage extending beyond cortical abnormalities in SWS.⁸ This is in contrast with the conventional notion that SWS pathology is mostly confined to gray matter or regions of anomalous venous drainage. Our DTI study discloses severe loss and disorganization of right inferior longitudinal fasciculus and optic radiation, which are important tracts of visual pathway, and the damaged subcortical white matter integrity might increase the susceptibility of prolonged visual defect in this case when concurring with blood flow disturbance and vasogenic leakage.

Although migraine is common in SWS, the treatment options are poorly described. Standard abortive medications are suggested for headaches and migraines in SWS and, when frequent or severe, preventative medications are used. Kossoff et al⁹ reported good efficacy and safety of triptans in SWS. Additionally, our patient responded well to dihydroergotamine. This may be due to blood flow disturbance in migraine-like headaches associated with SWS. Nonsteroidal anti-inflammatory drugs and prophylactic agents such as valproate and topiramate might appear to be helpful. Low-dose daily aspirin is generally empirically used when stroke-like episodes have occurred.¹⁰ However, a lack of prospective trials and conclusive data for the treatment in these patients persists.

In summary, our report supports the evidence of vasogenic leakage and hypoperfusion of the brain underlying the leptomeningeal angioma in the mechanism of migraine with permanent visual defect in SWS and further provides the involvement of disorganized white matter within the pathophysiology. The efficacy of aspirin, abortive and preventive medications, could prevent migraine-like attacks but has a limited role in the permanent visual defect in our patient.

REFERENCES

1. Comi AM. Presentation, diagnosis, pathophysiology, and treatment of the neurological features of Sturge-Weber syndrome. *Neurologist*. 2011;17:179-184.
2. Freilinger T, Peters N, Remi J, et al. A case of Sturge-Weber syndrome with symptomatic hemiplegic migraine: Clinical and multimodality imaging data during a prolonged attack. *J Neurol Sci*. 2009; 287:271-274.
3. Iizuka T, Sakai F, Yamakawa K, Suzuki K, Suzuki N. Vasogenic leakage and the mechanism of migraine with prolonged aura in Sturge-Weber syndrome. *Cephalalgia*. 2004;24:767-770.
4. Lisotto C, Mainardi F, Maggioni F, Zanchin G. Headache in Sturge-Weber syndrome: A case report and review of the literature. *Cephalalgia*. 2004;24: 1001-1004.
5. Headache Classification Subcommittee of the International Headache Society. The International Clas-

- sification of Headache Disorders: 2nd edition. *Cephalalgia*. 2004;24(Suppl. 1):9-160.
6. Shimakawa S, Miyamoto R, Tanabe T, Tamai H. Prolonged left homonymous hemianopsia associated with migraine-like attacks in a child with Sturge-Weber syndrome. *Brain Dev*. 2010;32:681-684.
 7. Miao Y, Juhasz C, Wu J, et al. Clinical correlates of white matter blood flow perfusion changes in Sturge-Weber syndrome: A dynamic MR perfusion-weighted imaging study. *AJNR Am J Neuroradiol*. 2011;32:1280-1285.
 8. Juhasz C, Haacke EM, Hu J, et al. Multimodality imaging of cortical and white matter abnormalities in Sturge-Weber syndrome. *AJNR Am J Neuroradiol*. 2007;28:900-906.
 9. Kossoff EH, Balasta M, Hatfield LM, Lehmann CU, Comi AM. Self-reported treatment patterns in patients with Sturge-Weber syndrome and migraines. *J Child Neurol*. 2007;22:720-726.
 10. Bay MJ, Kossoff EH, Lehmann CU, Zabel TA, Comi AM. Survey of aspirin use in Sturge-Weber syndrome. *J Child Neurol*. 2011;26:692-702.