

Isolated Central Nervous System Histoplasmosis Presenting With Ischemic Pontine Stroke and Meningitis in an Immune-Competent Patient

Frederic N. Nguyen, MD; Jitesh K. Kar, MD, MPH; Asma Zakaria, MD; Mya C. Schiess, MD

Importance: Histoplasmosis, a systemic mycosis caused by the fungus *Histoplasma capsulatum*, primarily affects immune-suppressed patients and commonly involves the lung and rarely the central nervous system (CNS). Herein, we report a case of isolated CNS histoplasmosis presenting with pontine stroke and meningitis.

Observations: A 35-year-old, white, immune-competent man was transferred from an outside facility with worsening dysarthria and confusion after having presented 4 weeks prior with dysarthria, gait ataxia, and bilateral upper extremity weakness. Brain magnetic resonance imaging revealed bilateral pontine strokes, and the working diagnosis was ischemic infarctions, presumed secondary to small vessel vasculitis. Cerebral spinal fluid (CSF) examination showed marked abnormalities including an elevated protein level (320 mg/dL), low glucose level (2 mg/dL), and high white blood cell count (330/mm³; 28% lymphocytes, 56% neutrophils, and 16% monocytes) suggestive of a bacterial, fungal, or tuberculosis meningitis. Empirical antibiotics and a second trial of intravenous steroids were started before infectious etiologies of meningitis were ultimately ruled out. Repeated magnetic resonance imaging of the brain revealed no evidence of new ischemic lesions. On hospital

day 11, results of his CSF *Histoplasma* antigen and urine antigen tests were positive. His CSF culture also was positive for *H capsulatum*. The patient was treated initially with liposomal amphotericin B, 430 mg daily, but changed to voriconazole, 300 mg twice daily, secondary to renal insufficiency and eventually continued treatment with itraconazole cyclodextrin, 100 mg twice daily. Computed tomographic imaging revealed obstructive hydrocephalus, and a ventriculoperitoneal shunt was placed that successfully decompressed the ventricles. At 1 year, the patient demonstrated good clinical improvement and results of follow-up CSF cultures were negative.

Conclusions and Relevance: While pulmonary involvement of histoplasmosis in immune-suppressed patients is common, systemic presentation of this fungal infection in immune-competent patients is rare and self-limiting. Isolated CNS histoplasmosis is exceedingly rare. Clinicians should consider CNS histoplasmosis in the differential diagnosis in atypical stroke cases, particularly those presenting with meningitis.

JAMA Neurol. 2013;70(5):638-641. Published online March 11, 2013. doi:10.1001/jamaneurol.2013.1043

HISTOPLASMOSIS, A SYSTEMIC mycosis caused by the fungus *Histoplasma capsulatum*, primarily affects immune-suppressed patients and commonly involves the lung and rarely the central nervous system (CNS). Herein, we report a case of isolated CNS histoplasmosis presenting with pontine stroke and meningitis.

REPORT OF A CASE

Author Affiliations:
Departments of Neurology (Drs Nguyen, Kar, and Schiess) and Neurosurgery (Dr Zakaria), UT Health, University of Texas Medical School at Houston, Houston.

A 35-year-old white man with a negative medical history except for hyperlipidemia presented initially to an outside hospital with dysarthria, gait ataxia, and bilateral upper extremity weakness. His

neurological evaluation included magnetic resonance imaging of the brain and magnetic resonance angiography and computed tomography (CT) angiography of the head and neck. He was diagnosed with bilateral pontine ischemic strokes, likely related to small vessel vasculitis, and started treatment with high-dose steroids but failed to show improvement. The patient was transitioned to postacute rehabilitation with continuation of an oral steroid taper. He presented to our hospital 2 weeks later for evaluation of confusion, decreased oral intake, and worsening dysarthria.

This patient had no history of communicable diseases, including human immunodeficiency virus and sexually transmitted diseases. He denied high-risk behavior

including intravenous drug use, multiple sexual partners, or travels to endemic areas. He also had no prior treatment with immunosuppressants. His family history was negative for neurological disorders and social history was pertinent for mechanical work in the sod industry.

On examination, he was found to be afebrile and normotensive. His general pulmonary and cardiovascular evaluation was normal. He was drowsy but easily arousable and oriented to person and place but not time. He followed simple commands and had hypophonic speech with mild dysarthria without aphasia. There were no cranial nerve abnormalities. He had nuchal rigidity and a positive Kernig sign. He was found to have mild generalized weakness on motor examination and his sensory evaluation was intact to all modalities. Appendicular ataxia and dyssynergia were noted with the left arm more affected than the right arm. Deep tendon reflexes were 3+ symmetric throughout with nonsustained clonus at the ankles. He was unsteady on gait examination but able to ambulate with assistance. He denied myalgia or arthralgia and no appreciable skin lesions were noted.

Cerebral spinal fluid (CSF) studies, obtained within 1 month of initial symptoms, were consistent with severe abnormalities including an elevated protein level (320 mg/dL), low glucose level (2 mg/dL), and neutrophilic pleocytosis with an elevated opening pressure of 320 mm of water (**Table**), suggestive of a bacterial, fungal, viral, tuberculosis, or malignant leptomenigeal process. He started treatment with empirical antibiotics and antivirals (vancomycin hydrochloride, amoxicillin, ceftriaxone sodium, and acyclovir) and continued intravenous steroid treatment. Repeated magnetic resonance imaging of the brain revealed diffusion-weighted imaging restricted diffusion in the bilateral pons, without new ischemic lesions (**Figure**, A and B). There was no evidence of leptomenigeal disease. At 11 days, CSF cultures returned positive for *H capsulatum* and results of CSF *Histoplasma* antigen testing were positive in the CSF and urine.

The patient was initially treated with liposomal amphotericin B, 430 mg daily, receiving 15 of 35 treatments before developing complications of renal insufficiency. He was then treated with voriconazole, 300 mg twice daily for 11 months. He later developed a generalized erythematous, desquamating rash, requiring the initiation and continued use of itraconazole cyclodextrin, 100 mg twice daily.

Signs of *H capsulatum* infection outside of the CNS, including pulmonary involvement, never developed in this patient. The patient's initial chest radiograph was negative and follow-up CT of the chest, abdomen, and pelvis revealed no evidence of systemic *H capsulatum*. A negative echocardiogram provided no evidence of *H capsulatum* endocarditis. Additional causes of bacterial, viral, other fungal, tuberculosis, and mycoplasma infectious meningitis were unsubstantiated and therefore excluded (**Table**). Head CT at 4 weeks into the hospitalization was consistent with obstructive hydrocephalus (**Figure**, D). He underwent placement of a ventriculoperitoneal shunt with successful decompression (postoperative images not shown).

At 1-year follow-up, the patient had made tremendous recovery. His orientation and cognition remained at baseline. His speech was without dysarthria or aphasia. Motor examination revealed full strength throughout and his ataxia had resolved. His gait revealed normal stance and he was able to ambulate without assistance.

Repeated CSF studies done after 1 year of therapy showed an increased protein level, normal glucose level, elevated white blood cell count with a lymphocytic predominance (**Table**), and negative bacterial and fungal culture results. His renal function had also returned to normal. Follow-up imaging studies revealed no new strokes, with normalization of ventricular size (images not shown) and opening of pressure of 160 mm of water.

COMMENT

We report a case of CNS histoplasmosis with ischemic pontine stroke and meningitis in an immune-competent patient. Histoplasmosis is a fungal infection of *H capsulatum*, which is commonly found in the soil and contaminated material (ie, bat or bird guano) of certain endemic areas of the United States, especially the St Lawrence river valley, Ohio, and Mississippi.¹ Spread of the disease occurs via inhalation of spores from disturbed guano or soil. In immune-competent persons, spore inhalation commonly results in an asymptomatic infection.² Exposure in immune-incompetent patients can lead to chronic pulmonary histoplasmosis and/or disseminated disease.¹

Histoplasmosis of the CNS is rare² and the exact pathophysiologic mechanism is not known. The fungal infection can occur via hematogenous spread, as a direct event without systemic involvement, with associated disseminated infection, or with recurrence after previous systemic infection.^{1,2} Previously described clinical syndromes of CNS histoplasmosis include meningitis, encephalitis, abscess formation, stroke secondary to infected emboli, and focal lesions involving the brain or spinal cord.^{1,3}

Our patient had no history to suggest an immune-suppressed state and his evaluation was negative for pulmonary histoplasmosis or disseminated disease. It was also unlikely that his pontine lesions were a result of abscesses or embolism from *H capsulatum* endocarditis. Repeated cerebral vessel imaging studies were not suggestive of primary CNS vasculitis. The initial neutrophilic predominance seen on CSF analysis also forced consideration of alternative infectious etiologies including bacterial, fungal (tuberculosis), viral (herpes simplex virus and cytomegalovirus), or malignant leptomenigeal processes,^{1,4} all of which were subsequently ruled out with further diagnostic evaluation (**Table**).

The gold standard for diagnosis remains positive fungal culture of *H capsulatum* in CSF, parenchymal tissue, or other sites.^{1,4} Obtaining an adequate sample, however, can often be a challenge.¹ Ancillary tests, particularly in culture-negative cases, include positive *H capsulatum* antigen from CSF, urine, or blood.^{1,4} Neuroimaging studies with CT and magnetic resonance imaging may be useful, but the findings are often nonspecific.^{1,4}

Table. Summary of CSF and Pertinent Laboratory Study Results at Presentation and 1 Year Later

	CSF 1 (Within 1 mo of Initial Symptoms)	CSF 2 (at 1 y)
CSF		
Color and appearance	Clear and colorless	Clear and colorless
Opening pressure, mm of water (ref range, 70-180 mm of water)	320 (High)	160
Glucose level, mg/dL (ref range, 45-80 mg/dL)	2 (Low)	50
Protein level, mg/dL (ref range, 15-45 mg/dL)	320 (High)	208 (High)
WBC count, /mm ³ (ref range, 0-5/mm ³)	330 (High)	28 (High)
RBC count, /mm ³ (ref range, 0-5/mm ³)	4	2
Predominant line		
Lymphocytes, % (ref range, 40%-80%)	28 (Low)	84 (High)
Monocytes, % (ref range, 15%-45%)	16	13 (Low)
Neutrophils, % (ref range, 0%-6%)	56 (High)	3
Infectious disease laboratory test		
	Result (at Initial Hospitalization)	Result (at 1 y)
<i>Coccidioides</i> Abs	Negative	...
West Nile encephalitis Abs	Negative	...
St Louis encephalitis Abs	Negative	...
California viral encephalitis Abs	Negative	...
<i>Bartonella henselae</i> Abs IgM and IgG	Negative	...
Typhus Abs IgM and IgG	Negative	...
Lyme Abs IgG	Negative	...
CSF enterovirus PCR	Negative	...
CSF VZV PCR	Negative	...
CSF <i>Histoplasma</i> antigen, ng/mL	Positive high >39.0	Negative
CSF cryptococcal antigen	Negative	Negative
Bacterial culture, serum	Negative	...
Bacterial culture, CSF	Negative	Negative
Fungal culture, serum	Negative	Negative
Fungal culture with india ink, CSF	Positive for <i>Histoplasma capsulatum</i>	Negative
Urine <i>Histoplasma</i> antigen, ng/mL (ref range positive low, 0.6-3.9 ng/mL)	Positive low <0.6	Negative
HIV	Negative	Negative
RPR	Negative	...
VDRL	Nonreactive	...
Hepatitis panel, A, B, C	Negative	...
TB QuantiFERON Gold ^a test	Negative	...
Routine chemistry test		
	Result (at Initial Presentation)	Result (at 1 y)
WBC count, /cm ² (ref range, 3.7-10.4/cm ²)	15.7 (High)	6.7
Hemoglobin level, g/dL (ref range, 14-18 g/dL)	15.8	10.3 (Low)
Hematocrit level, % (ref range, 42%-54%)	45.9	30.5 (Low)
Platelet count, /cm ² (ref range, 133-450/cm ²)	195	149
Differential		
Segmented neutrophils, % (ref range, 45%-75%)	88.2 (High)	74.7
Lymphocytes, % (ref range, 20%-40%)	5.2 (Low)	10.5 (Low)
Monocytes, % (ref range, 2%-12%)	5.7	9.1
Eosinophils, % (ref range, 0%-4%)	0.7	5.3 (High)
Basophils, % (ref range, 0%-1%)	0.2	0.4
Sodium level, mEq/L (ref range, 135-145 mEq/L)	132 (Low)	139
Creatinine level, mg/dL (ref range, 0.5-1.4 mg/dL)	3.4 (High)	1.5 (High)
AST level, U/L (ref range, 0-65 U/L)	21	29
ALT level, U/L (ref range, 0-37 U/L)	32	23
PT, s (ref range, 12-14.7 s)	14.4	24.6 (High)
INR (ref range, 0.85-1.17)	1.1	2.19 (High)
PTT, s (ref range, 22.9-35.8 s)	25.7	34.4
c-ANCA	Negative	...
p-ANCA	Negative	...
ESR, mm/h (ref range, 0-15 mm/h)	13	...

Abbreviations: Abs, antibodies; ALT, alanine aminotransferase; AST, aspartate aminotransferase; c-ANCA, antineutrophil cytoplasmic antibody; CSF, cerebral spinal fluid; ellipses, the test was not performed; ESR, erythrocyte sedimentation rate; HIV, human immunodeficiency virus; INR, international normalized ratio; p-ANCA, perinuclear antineutrophil cytoplasmic antibody; PCR, polymerase chain reaction; PT, prothrombin time; PTT, partial thromboplastin time; RBC, red blood cell; ref range, reference range; RPR, rapid plasma reagin; TB, tuberculosis; VDRL, Venereal Disease Research Laboratory; VZV, varicella zoster virus; WBC, white blood cell.

^aManufactured by Cellestis Ltd.

This case had several features reported to occur in CNS histoplasmosis, including meningitis, encephalitis, stroke, and the complication of hydrocephalus.^{1,5-8} As demonstrated with this patient's initial presentation, the wide

range of clinical symptoms and laboratory abnormalities can often make the diagnosis of histoplasmosis in the CNS difficult and may delay initiation of antifungal therapy.

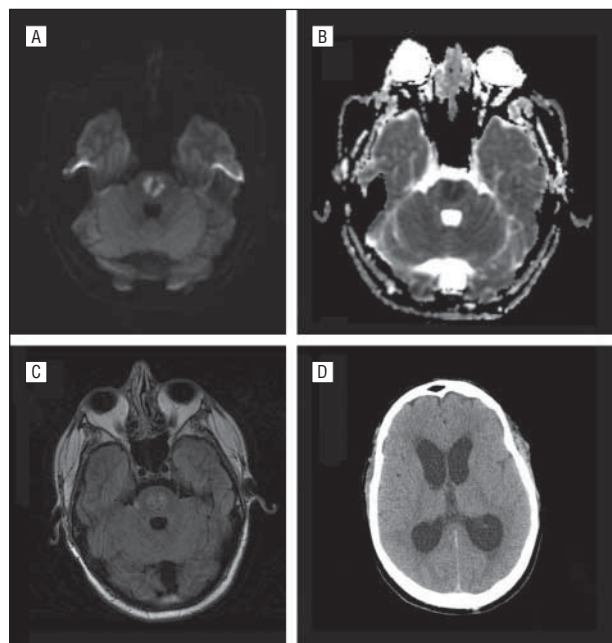


Figure. Brain images demonstrating acute bilateral pontine infarctions and hydrocephalus. A, Diffusion-weighted image. B, Corresponding apparent diffusion coefficient image. C, T2-weighted fluid-attenuated inversion recovery image. D, Computed tomography brain image at 4 weeks (preshunting) demonstrating hydrocephalus.

While the standard of care remains aggressive and long-term treatment with antifungal therapy, there remains no consensus regarding specifics for such treatment.^{3,4} In patients who develop complications of hydrocephalus, studies have suggested that shunt placement should be offered 2 weeks after treatment with antifungal therapy.⁴ In our case, the patient had his shunt placed 4 weeks after presentation, which was preceded by treatment at an outside hospital consisting of antibiotics and steroids and 7 days of antifungal therapy at our facility. Antifungal therapy can also be associated with adverse effects, high initial failure, and high relapse rate.^{4,5}

At 1 year, following initial treatment and continuing with itraconazole cyclodextrin treatment, this patient's CSF analysis demonstrated persistent protein elevation, lymphocytic pleocytosis, normal glucose level, and no evidence of active disease. These findings were likely consistent with chronic meningitis due to inflammatory changes in the subarachnoid space.¹⁻⁴

In summary, primary CNS presentation of histoplasmosis remains exceedingly rare, particularly in young immune-competent individuals.^{7,8} Clinicians should consider CNS histoplasmosis in the differential diagnosis in unusual stroke cases, especially those presenting with meningitis.

Accepted for Publication: September 24, 2012.

Published Online: March 11, 2013. doi:10.1001/jamaneurol.2013.1043

Correspondence: Mya C. Schiess, MD, Department of Neurology, UT Health, University of Texas Medical School at Houston, 6431 Fannin, Ste 7.044, Houston, TX 77030 (mya.c.schiess@uth.tmc.edu).

Author Contributions: All authors have substantially contributed to the project, both conception and preparation of the manuscript, and approved the submission. **Study concept and design:** All authors. **Acquisition of data:** Nguyen, Zakaria, and Schiess. **Analysis and interpretation of data:** Nguyen, Zakaria, and Schiess. **Drafting of the manuscript for important intellectual content:** Nguyen, Zakaria, and Schiess. **Study supervision:** Nguyen, Zakaria, and Schiess.

Conflict of Interest Disclosures: None reported.

Additional Information: Informed consent was obtained from the patient.

REFERENCES

1. Zalduondo FM, Provenzale JM, Hulette C, Gorecki JP. Meningitis, vasculitis, and cerebritis caused by CNS histoplasmosis: radiologic-pathologic correlation. *AJR Am J Roentgenol*. 1996;166(1):194-196.
2. Carod-Artal FJ, Venturini M, Gomes E, de Mello MT. Chronic central nervous system histoplasmosis in an immunocompetent patient [in Spanish]. *Neurologia*. 2008;23(4):263-268.
3. Saccante M. Central nervous system histoplasmosis. *Curr Treat Options Neurol*. 2008;10(3):161-167.
4. Wheat LJ, Musial CE, Jenny-Avital E. Diagnosis and management of central nervous system histoplasmosis. *Clin Infect Dis*. 2005;40(6):844-852.
5. Hamada M, Tsuji S. Central nervous system histoplasmosis [in Japanese]. *Brain Nerve*. 2009;61(2):129-134.
6. Zeller V, Lortholary O. Vasculitis secondary to fungal infections [in French]. *Presse Med*. 2004;33(19, pt 2):1385-1388.
7. Vos MJ, Debets-Ossenkopp YJ, Claessen FA, Hazenberg GJ, Heimans JJ. Cerebellar and medullary histoplasmosis. *Neurology*. 2000;54(7):1441.
8. Tan V, Wilkins P, Badve S, et al. Histoplasmosis of the central nervous system. *J Neurol Neurosurg Psychiatry*. 1992;55(7):619-622.