

CASE REPORT

An atypical case of contrast-induced encephalopathy after carotid artery stenting

D Menna, L Capoccia, A R Rizzo, E Sbarigia and F Speziale

Neurotoxicity caused by contrast agents is a rare and less known complication of percutaneous carotid and coronary interventions. Radiological signs, such as cortical enhancement and brain edema, are of utmost importance in diagnosis. A 70-year-old female patient underwent left carotid artery stenting to treat a post-traumatic asymptomatic carotid dissection. Three hours after intervention, a mild aphasia developed with no brain alteration on diffusion-weighted magnetic resonance imaging (DW-MRI). Twelve hours after intervention, symptoms worsened but a new DW-MRI scan showed no pathological findings. Since a contrast-induced encephalopathy was diagnosed, fluid administration was raised to 2 mL/kg/h and the neurological status progressively improved. In the following three days, neurological deficit slowly regressed. Two weeks after intervention, aphasia had disappeared and a further cerebral DW-MRI scan detected no brain alteration. Typical radiological signs are described in association to contrast encephalopathy. Nevertheless, vascular interventional physicians should be well aware of this condition also when those signs are lacking.

Key words: carotid dissection; carotid artery stenting; contrast encephalopathy; hyperfusion syndrome

Introduction

Neurotoxicity caused by contrast agents is a less known complication of percutaneous carotid and coronary interventions.^{1–3} The incidence of contrast encephalopathy ranges between 0.3% and 1.0% but can reach 4% when hyperosmolar iodinated contrast agents are used.^{4,5} The explanation of this phenomenon can be found in chemical and physical properties of high doses of contrast causing osmotic disruption of the blood–brain barrier, resulting in fluid extravasation and cerebral edema.^{4,6–8} Although cortical blindness is the most common symptom as occipital cortex has lower vascular autoregulatory capacity,⁹ contrast-induced encephalopathy (CIE) may be characterized by other focal neurological deficits, which often pose some differential diagnosis issues.^{2,10–12}

Because of inhomogeneity of clinical presentation, radiological signs associated with contrast encephalopathy, such

as cortical enhancement and brain edema, are of utmost importance in differentiating this condition from other neurological pathologies.

Brain computed tomography (CT) without contrast may show diffuse cortical hyperattenuation similar to subarachnoid hemorrhage, in most cases without mass effect or signs of hemorrhage,⁴ while magnetic resonance imaging (MRI) findings have included areas of increased signal on T2- and fluid attenuated inversion recovery (FLAIR) weighted images located in the cortex.⁹

We report a very unusual case of transient encephalopathy after carotid artery stenting, with no pathological findings at neuroimaging.

Case report

A 70-year-old female patient, heavy smoker, in therapy with thyroxine for multinodular thyreopathy, was referred to our hospital after a car accident, reporting skeletal thoracic pain. No relevant past medical history was reported. At admission, her blood pressure was normal, she had normal serum hemoglobin, normal creatinine level (0.7 mg/mL, estimated creatinine clearance 71 mL/min) and no sign of cardiac disease. No neurological impairment was detected. She

Accepted April 30, 2012

Vascular Surgery Unit, Department 'Paride Stefanini', Policlinico Umberto I, 'Sapienza' University, Rome, Italy

Correspondence to: Dr Menna Danilo, Via Ciamarra, 129, 03100 Frosinone, Italy; e-mail: dmenna@hotmail.it

underwent a total body enhanced CT scan revealing a left carotid axis dissection narrowing the proximal tract of internal carotid artery for 1 cm in length. The false lumen caused a 50% stenosis of internal carotid artery true lumen. Neither brain hemorrhage nor ischemia was detected. After thorough medical counselling, and according to the acuity of the lesion, a carotid artery stenting (CAS) procedure was performed.

Following our antibiotic prophylaxis protocols, a single administration of cefuroxime sodium 2 g was given before intervention. The CAS procedure was performed under local anesthesia via right percutaneous transfemoral access, with no sedative use throughout the entire procedure.

Because of the absence of carotid plaques or aortic arch thrombus, no distal protection device was used (Figure 1).

The true lumen catheterization was difficult, requiring about 30 minutes and many angiograms. As the true lumen was entered, a metallic stent (Wallstent 7 × 40; Boston Scientific, Natick, MA, USA) was deployed. On the final angiogram, the false lumen was no longer patent and the intracranial angiogram showed normal flow all over the stent and distal arterial bed.

The entire procedure took about 70 minutes, requiring the use of 130 mL of low osmolarity iodinated contrast agent (Iomeron 300 mg/mL) and i.v. 5000 IU of heparin sodium.

The patient remained asymptomatic during the whole CAS procedure, with no sign of hemodynamic instability. In the postoperative period, clopidogrel 150 mg and i.v. fluid (1 mL/kg/hour) administration was started.

Three hours after intervention, a mild aphasia developed, so the patient underwent neurological examination with a score 1 at National Institutes of Health Stroke Scale evaluation (NIHSS).

Carotid duplex ultrasound, cerebral CT scans and diffusion-weighted MRI (DW-MRI) were promptly

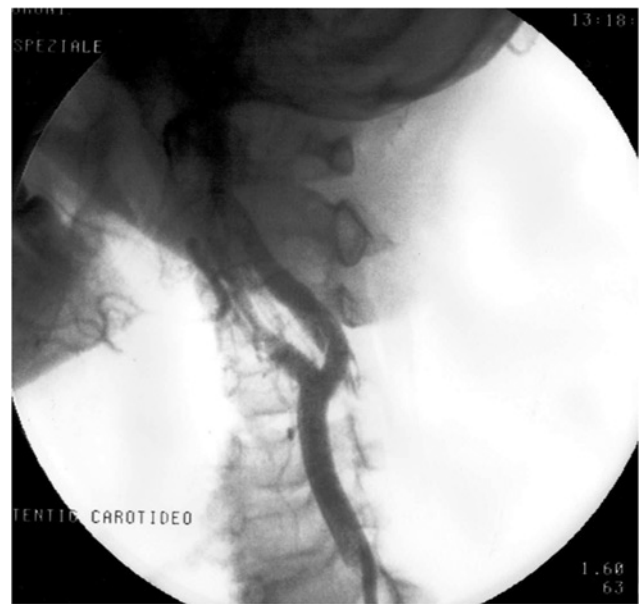

Figure 1 Angiogram showing left internal carotid artery dissection

performed. A patent left carotid axis and no ischemic or hemorrhagic brain lesion, no brain edema or blood–brain barrier disruption were detected (Figure 2).

Routine administration of i.v. saline solution was continued, together with 200 mL mannitol 15%.

Twelve hours after intervention, the aphasia worsened and restlessness developed (NIHSS score = 4). The patient underwent a new cerebral DW-MRI scan that showed no pathological findings (Figure 3).

On the basis of radiological findings, neurologic embolic/haemorrhagic events were excluded, so CIE was supposed.

Continuous e.v. fluid administration was raised to 2 mL/kg/hour in order to improve renal clearance of the

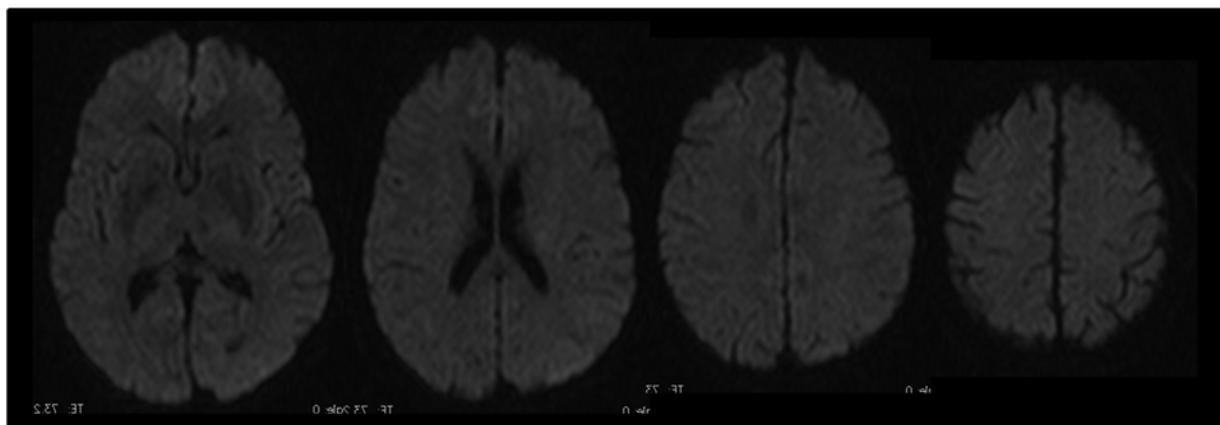


Figure 2 Brain magnetic resonance imaging performed after onset of symptoms

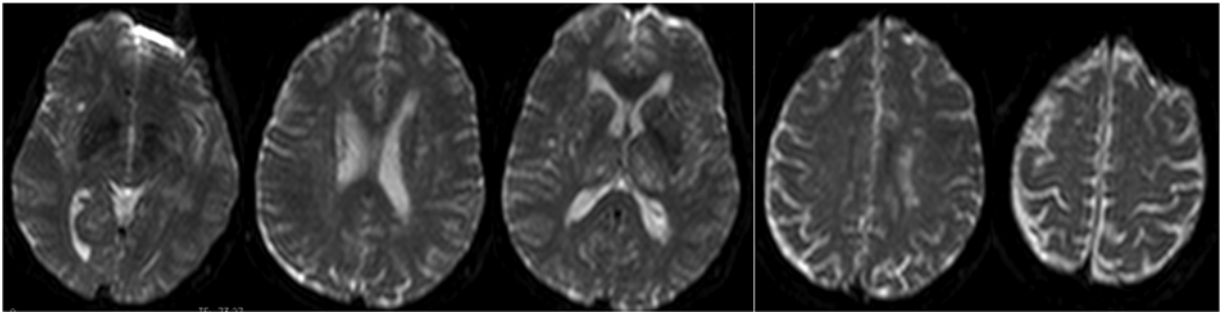


Figure 3 Brain magnetic resonance imaging performed 12 hours after intervention

contrast agent; creatinine serum level remained stable in all postoperative blood tests.

Twenty hours after onset of symptoms, the neurological status mildly improved (NIHSS score = 2).

In the following three days, *e.v.* saline solution administration was continued without any oral fluid intake restriction, and neurological deficit slowly regressed. On the sixth postoperative day, the patient was discharged home under dual antiplatelet therapy, with a residual mild aphasia (NIHSS score = 1).

Two weeks after intervention, aphasia had disappeared and a further cerebral DW-MRI scan detected no brain alteration.

Discussion

As postoperative aphasia occurred in our patient, we immediately supposed an embolic event, but early CT scans and DW-MRI, performed two hours after intervention, showed no brain alteration. Also after symptoms worsening, a new MRI scan (performed 10 hours after onset of symptoms) detected no brain infarction or hemorrhage. Again, embolic or hemorrhagic etiology was not confirmed.

Hyperperfusion syndrome was also considered as a possible cause of symptoms. It is widely reported that this condition is likely to occur after carotid revascularization in hypertensive patients with a high-degree carotid stenosis, because of a suddenly increased intracranial blood flow after revascularization.^{13,14} Our patient did not match these features, as the dissection false lumen caused a mild carotid stenosis and blood pressure always remained normal in the postoperative course, with normal flow detected by postoperative transcranial Doppler on the left middle cerebral artery.

Due to the chemical and physical properties of iodinated contrast agent, in predisposed patients, a blood–brain barrier disruption may occur, thus accounting for the

radiological findings of brain edema detected by CT scans and/or MRI.^{4,6–9} This finding is believed to reflect increased intracellular fluid and decreased extracellular fluid resulting from reduced activity of Na^+ and K^+ -ATPase. Vasogenic edema can also be visualized as increased signal intensity on DW-MRI ('T2 shine-through effect').¹⁵ These pathological changes in brain cells may sometimes have a clinical counterpart in focal neurological deficit development.

CIE occurs when great volumes of iodinated contrast agent are employed.^{16–20} As we used almost 130 mL of low osmolarity iodinated contrast agent to complete the CAS procedure, the diagnosis of CIE was highly presumable, even without the associated typical radiological signs. Indeed, two early postoperative MRI scans showed no brain edema.

It is reported that contrast encephalopathy generally resolves spontaneously as the contrast agent is cleared by the kidneys. Iodinated contrast agent is mainly eliminated via the kidney, with an excretion of up to 40% in the first hour and the remainder in the following hours. In renal impairment, iodinated contrast agent can be eliminated through alternative pathways, such as salivary glands and other excretory organs. In our patient, neurological symptoms slowly improved with only fluid administration, as for metabolic impairment.

Conclusions

Transient encephalopathy after endovascular interventions is a rare complication, with different clinical presentations. In this case, contrast encephalopathy remains the most likely hypothesis on the basis of intraoperative data and postoperative course, despite typical radiological findings being lacking. To our knowledge, this is the first report of contrast encephalopathy without radiological alterations. Further reports are warranted to confirm this rare pathology.

Declarations

Conflicts of interest: None.

References

- 1 Fang HY, Kuo YL, Wu CJ. Transient contrast encephalopathy after carotid artery stenting mimicking diffuse subarachnoid hemorrhage: a case report. *Catheter Cardiovasc Interv* 2009;**73**:123–6
- 2 Dangas G, Monsein LH, Laureno R, et al. Transient contrast encephalopathy after carotid artery stenting. *J Endovasc Ther* 2001;**8**:111–3
- 3 Kocabay G, Karabay CY. Iopromide-induced encephalopathy following coronary angioplasty. *Perfusion* 2011;**26**:67–70
- 4 Potsi S, Chourmouzi D, Moutzouglou A, Nikiforaki A, Gkouvas K, Drevelegas A. Transient contrast encephalopathy after carotid angiography mimicking diffuse subarachnoid haemorrhage. *Neurol Sci* 2012;**33**:445–8
- 5 De Bono D. Complications of diagnostic cardiac catheterization: results from 34,041 patients in the United Kingdom confidential enquiry into cardiac catheterization complications. *Br Heart J* 1993;**70**:297–300
- 6 Studdard WE, Davis DO, Young SW. Cortical blindness after cerebral angiography. *J Neurosurg* 1981;**54**:240–4
- 7 Utz R, Ekholm SE, Isaac L, et al. Local blood–brain barrier penetration following systemic contrast medium administration. *Acta Radiol* 1988;**29**:237–42
- 8 Caille JM, Allard M. Neurotoxicity of hydrosoluble iodine contrast media. *Invest Radiol* 1988;**23**(Suppl. 1):5210–2
- 9 Merchut MP, Richie B. Transient visuospatial disorder from angiographic contrast. *Arch Neurol* 2002;**59**:851–4
- 10 Kermode AG, Chakera T, Mastaglia FL. Low osmolar and non-ionic X-ray contrast media and cortical blindness. *Clin Exp Neurol* 1992;**29**:272–6
- 11 Sticherling C, Berkefeld J, Auch-Schwelk W, et al. Transient bilateral cortical blindness after coronary angiography. *Lancet* 1998;**351**:570
- 12 Kamata J, Fukami K, Yoshida H, et al. Transient cortical blindness following bypass graft angiography. A case report. *Angiology* 1995;**46**:937–46
- 13 Medel R, Crowley RW, Dumont AS. Hyperperfusion syndrome following endovascular cerebral revascularization. *Neurosurg Focus* 2009;**26**:E4
- 14 Van Mook WN, Rennenberg RJ, Schurink GW, et al. Cerebral hyperperfusion syndrome. *Lancet Neurol* 2005;**4**:877–88
- 15 Kono Y, Itoh Y. Diffusion-weighted imaging of encephalopathy related to idiopathic hypereosinophilic syndrome. *Clin Neurol Neurosurg* 2009;**111**:551–3
- 16 Guimaraens L, Vivas E, Fonnegra A, et al. Transient encephalopathy from angiographic contrast: a rare complication in neurointerventional procedures. *Cardiovasc Intervent Radiol* 2010;**33**:383–8
- 17 Heistad DD. Protection of the blood–brain barrier during acute and chronic hypertension. *Fed Proc* 1984;**43**:205–9
- 18 Parry R, Rees JR, Wilde P. Transient cortical blindness after coronary angiography. *Br Heart J* 1993;**70**:563–4
- 19 Ay H, Buonanno FS, Schaefer PW, et al. Posterior leuko-encephalopathy without severe hypertension: utility of diffusion weighted MRI. *Neurology* 1998;**51**:1369–76
- 20 Skinner JS, Jackson MJ, Gholkar A, Adams PC. Cortical blindness during left internal mammary angiography. *Int J Cardiol* 1995;**52**:119–23