

Isolated hypoglossal nerve palsy due to spontaneous carotid artery dissection: a neuroimaging study

Edoardo Ferlazzo · Sara Gasparini · Luciano Arcudi ·
Paolo Versace · Umberto Aguglia

Received: 11 February 2013 / Accepted: 5 March 2013 / Published online: 14 March 2013
© Springer-Verlag Italia 2013

Internal carotid artery dissection (ICAD) is a common cause of ischemic stroke in young patients. It usually presents with neck pain or headache, ipsilateral Horner Syndrome, followed by signs of cerebral ischemia. Palsy of XIIth nerve, alone or in combination with involvement of nerves IX, X or XI, may occur in about 5 % of patients with extracranial ICAD [1, 2]. Two mechanisms have been proposed to explain lower cranial nerves (LCN) involvement in the setting of ICAD, i.e., compression or stretching of nerves below the jugular foramen by an expanded or aneurysmatic ICA, or impairment (mechanical, embolic or hemodynamic) of the blood supply to the LCN [1]. Herein, we report a patient with ICAD presenting XIIth nerve palsy, in whom the MRI revealed compression of such nerve in parapharyngeal space.

A previously healthy 37-year-old man presented to the emergency room with 6-day-history of left mandibular angle pain, followed by dysarthria 24 h after onset. No major neck trauma was reported. Neurological examination only revealed left deviation of protruded tongue (Fig. 1). Brain CT angiography scan revealed mild narrowing of the artery vessel with surrounding hematoma. MRI and time-of-flight magnetic resonance angiography (TOF-MRA) showed left ICAD with intramural hematoma surrounding the artery with a semilunar shape with mild narrowing of the arterial lumen; ICAD clearly expanded into parapharyngeal space (Fig. 2). MRI including the diffusion-weighted imaging (DWI) showed no brain or brainstem lesion. Patient was then given anticoagulant treatment with partial regression of symptoms at 1-month follow-up.

We presented a young man with isolated XIIth nerve palsy. Isolated hypoglossal palsy may recognize different etiologies including base skull tumor, infections, injury, and carotid artery surgery, but often no etiology may be found [3]. In our patient, we considered that the isolated XIIth nerve palsy was due to the compression by ICAD in the parapharyngeal space. In the same patient, the supposed role of the reduction of blood supply to XII nerve [1] remains questionable. We also showed that both MRI and TOF-MRA are useful to visualize intramural hematoma with surrounding tissues, clarifying the pathogenesis of nerve palsy. The absence of brain ischemic lesion in our patient could probably be explained by the fact that hematoma was likely located in subadventitial layer, without significantly narrowing the lumen [3]. On the contrary, when hematoma locates in subintimal layer, with significant lumen narrowing or occlusion, embolism may easily lead to ischemic brain lesions [3]. Our report highlights the importance of looking for ICAD and to perform

E. Ferlazzo · S. Gasparini · U. Aguglia
Regional Epilepsy Centre and Department of Medical
and Surgical Sciences, Magna Græcia University,
Catanzaro, Italy

E. Ferlazzo · S. Gasparini · L. Arcudi · U. Aguglia (✉)
Unit of Neurology, “Bianchi-Melacrino-Morelli” Hospital,
Reggio, Calabria, Italy
e-mail: u.aguglia@tin.it

P. Versace
Unit of Neuroradiology, “Bianchi-Melacrino-Morelli” Hospital,
Reggio, Calabria, Italy

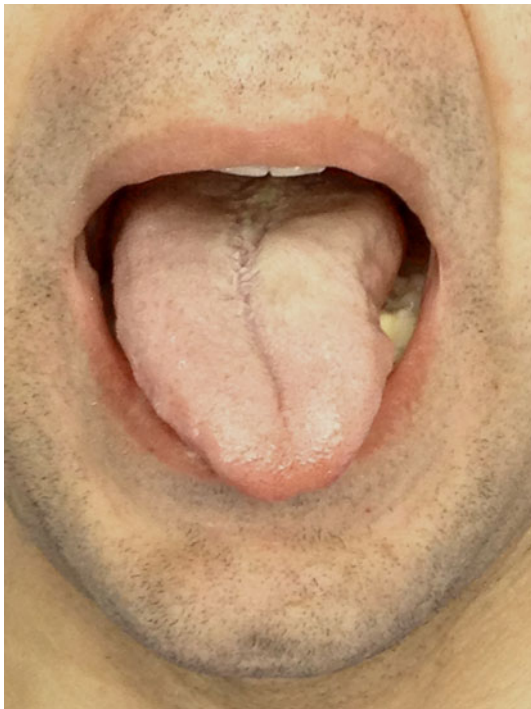


Fig. 1 Left deviation of protruded tongue

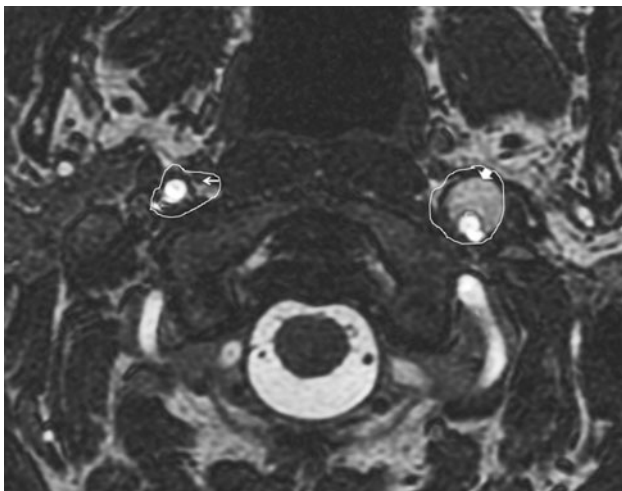


Fig. 2 Brain TOF-MRA. Boundaries of both parapharyngeal spaces are delimited by *white lines*. Note LCN (*arrow*) in right parapharyngeal space. Intramural hematoma surrounding left carotid artery lumen (*arrowhead*) occupies left parapharyngeal space, where LCN are not visible

both MRI and TOF-MRA in patients presenting with isolated XIIth nerve palsy.

References

1. Mokri B, Silbert PL, Schievink WI, Piepgras DG (1996) Cranial nerve palsy in spontaneous dissection of the extracranial internal carotid artery. *Neurology* 46:356–359
2. Olzowy B, Lorenzl S, Guerkov R (2006) Bilateral and unilateral internal carotid artery dissection causing isolated hypoglossal nerve palsy: a case report and review of the literature. *Eur Arch Otorhinolaryngol* 263:390–393
3. Spitzer C, Mull M, Töpper R (2001) Isolated hypoglossal nerve palsy caused by carotid artery dissection the necessity of MRI for diagnosis. *J Neurol* 248:909–910