

Visual outcomes for surgical treatment of large and giant carotid ophthalmic segment aneurysms: a case series utilizing retrograde suction decompression (the “Dallas technique”)

Clinical article

THOMAS MATTINGLY, M.D.,¹ MAX K. KOLE, M.D.,² DAVID NICOLLE, M.D.,¹
MEL BOULTON, M.D., PH.D.,¹ DAVID PELZ, M.D.,¹ AND STEPHEN P. LOWNIE, M.D., F.R.C.S.C.¹

¹Department of Clinical Neurological Sciences, University of Western Ontario, London Health Sciences Centre, London, Ontario, Canada; and ²Department of Neurosurgery, Henry Ford Health System, Detroit, Michigan

Object. The authors report their results in a series of large or giant carotid ophthalmic segment aneurysms clipped using retrograde suction decompression.

Methods. A retrospective review of clinical data and treatment summaries was performed for 18 patients with large or giant carotid artery ophthalmic segment aneurysms managed operatively via retrograde suction decompression. Visual outcomes, Glasgow Outcome Scale (GOS) scores, and operative complications were determined. Postoperative angiography was assessed.

Results. During a 17-year period, 18 patients underwent surgery performed using retrograde suction decompression. The mean aneurysm size was 26 mm. Three patients presented with subarachnoid hemorrhage. Fourteen of 18 patients presented with visual symptoms. Eleven (79%) of these 14 patients experienced visual improvement and the remaining 3 (21%) experienced worsened vision after surgery. Of 3 patients without visual symptoms and a complete visual examination before and after surgery, 1 had visual worsening postoperatively. One aneurysm required trapping and bypass, and all others could be clipped. Postoperative angiography demonstrated complete occlusion in 9 of 17 clipped aneurysms and neck remnants in the other 8 clipped aneurysms. One (5.5%) of 18 patients experienced a stroke. Eighteen patients had a GOS score of 5 (good outcome), and 1 patient had a GOS score of 4 (moderately disabled). There were no deaths. There was no morbidity related to the second incision or decompression procedure. Prolonged improvement did occur, and even in some cases of visual worsening in 1 eye, the overall vision did improve enough to allow driving.

Conclusions. Retrograde suction decompression greatly facilitates surgical clipping for large and giant aneurysms of the ophthalmic segment. Visual preservation and improvement occur in the majority of these cases and is an important outcome measure. Developing endovascular technology must show equivalence or superiority to surgery for this specific outcome.

(<http://thejns.org/doi/abs/10.3171/2013.2.JNS12735>)

KEY WORDS • retrograde suction decompression • giant aneurysm • carotid ophthalmic segment aneurysm • visual outcome • vascular disorders

SINCE the publication of the International Subarachnoid Aneurysm Trial,²⁸ there has been a paradigm shift in the treatment of intracranial aneurysms, and more aneurysms are referred for endovascular coiling. Despite this recent trend and the continuing evolution of endovascular treatments, large and giant ophthalmic

Abbreviations used in this paper: BTO = balloon test occlusion; CCA = common carotid artery; ECA = external carotid artery; GDC = Guglielmi detachable coil; GOS = Glasgow Outcome Scale; ICA = internal carotid artery.

segment aneurysms present a unique dilemma. From the surgical perspective, this aneurysm subgroup poses technical challenges with regard to proximal control and safe intracranial exposure, decompression, and clipping due to brisk retrograde flow through the ophthalmic artery and cavernous branches. Simple trapping of the aneurysm between the cervical ICA and intracranial carotid artery may not adequately soften the aneurysm sufficiently for clip reconstruction.⁴ Furthermore, excessive manipulation of the optic apparatus may contribute to poor visual outcomes.³³ On the endovascular side, coiling of large or gi-

ant aneurysms is an attractive minimally invasive solution but has low rates of complete occlusion and high rates of recanalization.²⁹ Furthermore, there are now numerous warnings of visual worsening in patients with carotid ophthalmic large or giant aneurysms treated with coil occlusion.^{23,34,35,40,41}

One solution offered from the surgical side is retrograde suction decompression. Initially described by Batjer and Samson,⁴ this technique has been reported to facilitate direct surgical clipping of this subgroup of aneurysms. This has been the preferred technique at our institution for the treatment of large to giant carotid ophthalmic aneurysms. At our institution, it is known as the Dallas technique, a descriptive term first coined by Dr. Charles Drake. It provides indirect decompression of the aneurysm, facilitating clip reconstruction with minimal optic nerve manipulation. We report our series of surgically treated large to giant carotid ophthalmic aneurysms with particular attention to the visual outcomes. In light of the continued evolution of endovascular solutions, especially flow-diverting stents, we believe that a surgical standard with detailed visual outcomes is necessary so that future comparisons can be appropriately made.

Methods

Clinical data and treatment summaries for all patients with large or giant carotid artery ophthalmic segment aneurysms managed operatively via retrograde suction decompression over a 17-year period were reviewed. All operations were performed by a single surgeon (S.P.L.). The carotid ophthalmic segment was defined as the portion of the ICA from the point of dural penetration beneath the anterior clinoid process to the origin of the posterior communicating artery. The technique used for suction decompression was similar to that originally described by Batjer and Samson with some minor modifications (detailed below). Operative complications and GOS scores²² were recorded retrospectively. Visual changes were objectively assessed by a neuroophthalmologist (D.N.) pre- and postoperatively, although in some cases outside ophthalmology records were used. Postoperative angiography was performed in all patients and was independently reviewed by a neuroradiologist (D.P.).

Patient Demographics

Eighteen patients with large or giant carotid artery ophthalmic segment aneurysms were treated between 1992 and 2009 using the retrograde suction decompression technique (Table 1). Sixteen patients were women, and the average age in the cohort was 54 years (range 38–74 years). Three presented with subarachnoid hemorrhage. Ten aneurysms were giant (> 2.4 cm), and the mean size was 2.6 cm (range 2.0–3.2 cm). Case 12 is illustrated in Fig. 1.

Eleven patients underwent preoperative 30-minute BTO of the proximal carotid artery, and all passed. Balloon test occlusion was increasingly used both to predict tolerance to prolonged ICA occlusion intraoperatively and as a safety measure in case the ICA had to be permanently occluded.

Neuroophthalmological Assessment

Neuroophthalmological examinations were performed both pre- and postoperatively (Table 2). Although some patients were referred for evaluation based on visual symptoms and outside examinations, all patients had their neuroophthalmological evaluation within days to weeks of surgery. Visual acuity, ophthalmoscopy, and visual fields were assessed. The available visual fields were obtained using either Goldmann or automated Humphrey methods, which are both accepted by the Ministry of Transportation of Ontario.

Surgical Technique

The patient was positioned with the head rotated 30°–45° to the contralateral side. A sandbag was placed under the patient's shoulders to gain adequate access to the carotid artery in the neck. The CCA, ECA, and ICA were surgically exposed and isolated. A standard pterional craniotomy was performed with aggressive resection of the sphenoid ridge. The sylvian fissure was widely split. The anterior clinoid process was drilled, and the optic canal was opened if necessary.

The final dissection was carried out with the aid of retrograde suction decompression to soften the aneurysm and allow for more aggressive manipulation of the aneurysm sac and definitive clipping. A 16-gauge angiocatheter was inserted into the CCA rather than the ICA. This approach may decrease the risk of traumatic dissection of the ICA or entering an atherosclerotic plaque at the bifurcation.¹¹ The angiocatheter was connected to sterile extension tubing with a 3-way stopcock. The 3-way stopcock was connected to a 60-ml syringe and heparinized tubing to allow for cell-saving techniques. The CCA and ECA were temporarily clamped. The ICA distal to the aneurysm but proximal to the posterior communicating artery was temporarily clipped, thus trapping the aneurysm. The 60-ml syringe was then used to aspirate and deflate the aneurysm. Trapping was done in an intermittent fashion for several minutes at a time, with clamp removal to allow reperfusion. The listed trap times are summations. Aspiration with the syringe was repeated several times. The 3-way stopcock was turned, and the aspirated blood was collected for cell saving and reinfusion by the anesthesiologist. After the aneurysm was clipped, the distal temporary ICA clip and the temporary clamps on the CCA and ECA as well as the 16 gauge angiocatheter were removed. A 6-0 Prolene vertical mattress suture was placed at the puncture site in the CCA, and closure of the craniotomy and the neck incision was performed.

Results

Ophthalmological Results

There were preoperative visual symptoms in 14 (77%) of 18 patients. In the majority of cases, the visual loss was slowly progressive, but in 3 cases the visual loss was abrupt. The duration of visual symptoms before surgical intervention was highly variable, from several days up to 5 years. According to the regulations of the Ministry of Transportation (Table 3), it is likely that 4 patients (Cases

TABLE 1: Summary of clinical data*

Case No.	Age (yrs), Sex	Symptoms	Symptom Duration	Side	Size (cm)	BTO	Aneurysm Softening	Trap Time (mins)	Angiographic Result	Complication	GOS Score
1	63, F	sudden HA 4 mos prior	4 mos	lt	2.6	passed, 30 min	yes	26	obliteration	word-finding difficulty, seizures	5
2	47, F	TIA (speech) 5 yrs ago, fall causing worsening HA	3 wks	lt	2.9	passed, 30 min	no	60	obliteration	no	5
3	55, F	rt progressive visual loss	1 mo	rt	3.0	no	yes	24	neck remnant	intraop rupture	5
4	58, F	possible SAH 1 mo prior, lt progressive visual loss	1 mo	lt	2.2	passed, 30 min	yes	35	obliteration	no	5
5	48, F	SAH, lt VF impairment	days	rt	2.3	passed, 30 min	yes	9	obliteration	CSDH	5
6	67, F	rt APD, central scotoma	7 mos	rt	2.4	no	yes	23	3-mm remnant	no	5
7	38, F	rt APD, abrupt blindness	3 mos	rt	3.2	passed, 30 min	yes	45 (CCA), 11 (ICA)	tiny remnant	no	5
8	49, F	rt APD, finger counting	9 mos	rt	2.6	no	yes	21	obliteration	no	5
9	58, F	rt APD, superotemporal VF	7 mos	rt	2.2	no	yes	13	obliteration	no	5
10	40, M	rt nasal field cut, unable to read	3-4 yrs	rt	3.2	passed, 30 min	yes	66	remnant	no	5
11	46, F	lt APD, visual impairment	10 mos	lt	3.0	passed, 30 min	no	30	unclippable, trapped then bypass	lt frontal ICH, aphasia; bypass occlusion 2 yrs later	4
12	71, F	lt visual impairment	1 yr	lt	3.2	passed, 30 min	mild	23	remnant	no	5
13	74, M	bitemporal VF cut	6 mos	rt	2.5	passed, 30 min	yes	NA	cavernous remnant	intraop rupture	5
14	48, F	HA		lt	2.3	no	yes	13	obliteration	no	5
15	62, F	abrupt lt visual loss	9 mos	lt	2.2	no	yes	20	remnant, 2 x 4 mm	no	5
16	46, F	HA, lt APD	4.5-5 yrs	lt	2.3	passed, 30 min	yes	17	remnant	lt EDH	5
17	49, F	HA/TIA, lt visual impairment	episodic, 2 yrs	lt	2.0	no	no	35	obliteration	no	5
18	52, F	SAH		rt	2.5	passed, 30 min	intraop rupture	31	obliteration	intraop rupture	5

* APD = afferent pupillary defect; CSDH = chronic subdural hematoma; EDH = epidural hematoma; HA = headache; ICH = intracerebral hematoma; NA = not available; SAH = subarachnoid hemorrhage; TIA = transient ischemic attack; VF = visual field.

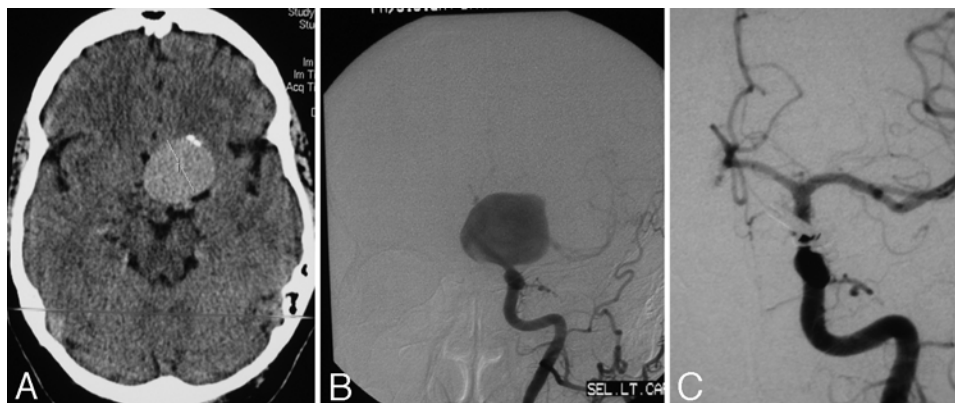


Fig. 1. Case 12. A: Preoperative CT. B: Preoperative anteroposterior angiogram. C: Postoperative anteroposterior angiogram.

5, 8, 13, and 16) would not have been given clearance to drive preoperatively.

Of the 14 patients with preoperative visual symptoms, postoperatively 11 (79%) had improved vision and 3 (21%) had worsened vision in the affected eye. Interestingly, in 2 of 4 cases in which vision worsened in the ipsilateral eye, vision improved in the contralateral eye. In terms of visual acuity, 10 patients (53%) improved, some significantly (Cases 3, 6, 7, 11, and 15), while 3 (16%) worsened and 6 (32%) remained unchanged. In terms of visual fields, only 17 patients had both pre- and postoperative examinations. Of these patients, 6 (41%) improved, 6 (35%) were unchanged, 2 (12%) exhibited worsening in the ipsilateral eye but improvement in the contralateral eye, and 2 exhibited worsening overall. For those with afferent pupillary defect and/or optic disc pallor, 2 had worsening in each category, and the conditions of the remaining patients were unchanged. These corresponded to the 3 cases of visual acuity worsening (Cases 9, 13, and 16). The patient in Case 1 was preoperatively normal but has a postoperative inferior altitudinal defect with intact acuity. There were 3 patients (Cases 1, 2, and 14) with normal preoperative vision, both acuity and fields, and 2 of the 3 patients retained normal vision postoperatively.

Operative Complications

One (5.5%) of 18 patients experienced a stroke. The patient in Case 11 underwent exploration and was determined intraoperatively to have an unclippable aneurysm that required proximal occlusion with subsequent saphenous vein extracranial-intracranial bypass. This was complicated by a left frontal hematoma. When the graft occluded 2 years after surgery, the patient suffered an additional stroke. Two (11%) of 19 patients required craniotomy reopening for postoperative fluid collections. No patient suffered any complications due to the proximal carotid exposure in the neck. There were 3 intraoperative ruptures (Cases 3, 13, and 18), which seem to have no clear relation to visual outcome or clinical outcome. There were no deaths in this series. The patient in Case 1 suffered postoperative seizures.

Clinical and Angiographic Results

Postoperative angiography demonstrated complete

occlusion of the aneurysm for 9 of 17 clipped aneurysms, some remnant in another 8, and 1 unclippable aneurysm treated with proximal occlusion and bypass. In 1 case, the remnant was in the cavernous sinus. The GOS scores were 5 (good) for 18 of 19 patients. The 1 patient (Case 11) with a GOS score of 4 (moderate disability) had fluctuating ischemic symptoms despite passing a preoperative BTO. A saphenous vein extracranial-intracranial bypass was performed on postoperative Day 13, which was complicated by a left frontal hematoma (see *Operative Complications*). She continued to have some language difficulties and right hemiparesis, and she returned home but not to work.

Discussion

The treatment of large and giant intracranial aneurysms remains controversial. In particular, aneurysms of this size at the carotid ophthalmic segment of the ICA pose a special challenge because of the relationship to the optic apparatus. The majority of these cases present unruptured and often with significant visual compromise. There are several different ways to handle these lesions, each of which has its advantages and disadvantages. Open surgery most often consists of direct clipping, but proximal ligation with or without bypass is still an option. Endovascular solutions are in evolution but most often involve coiling. Flow-diverting stents are showing interesting results, but we believe that more information is needed before we can routinely recommend this modality.

Direct Surgical Clipping: Technical Aspects

For the surgeon, these lesions present several challenges. Proximal control of these aneurysms is difficult due to their intimate relationship with the skull base and anterior clinoid process. These aneurysms have a tendency to compress adjacent brain and the optic nerves, thus increasing the risk of surgical injury. The sheer size and bulk of these aneurysms inhibits adequate surgical exposure of the anterior clinoid process, the neck of the aneurysm, the parent vessel, and the adjacent branches. Incorporation and expansion of the aneurysm neck into the ICA and adjacent branches can preclude simple clipping.

With improvements in microsurgical techniques





Vision after aneurysm clipping with suction decompression

TABLE 2: Summary of visual data*

Case No.	APD	Optic Disc Pallor	Preop Acuity		Postop Acuity		Preop VF		Postop VF		Vision
			Lt	Rt	Lt	Rt	Lt	Rt	Lt	Rt	
1	no	no	20/25	20/25	20/20	20/20					worsened
2	no	no	20/25	20/25	6	6					unchanged
3	rt	no	20/20	20/400	20/20	20/20					improved
4	lt	yes	20/200	20/20	20/25	20/25					improved
5	no	no	20/30	20/40	20/30	20/40					improved
6	rt	rt temp	20/25	20/200	20/25	20/25					improved
7	rt	rt temp	20/40	HM	20/40	20/70					improved
8	rt	rt	20/40	FC	20/40	20/400					improved
9	rt	no	20/20	20/25	20/20	FC					worsened
10	rt	rt	20/20	20/80	20/20	20/40					improved
11	lt	lt	20/400	20/25	20/40	20/20					improved
12	no	no	20/150	20/30	20/50	20/25					improved
13	no	rt atrophy, lt temp	20/50	20/50	20/40	no light					rt worse, lt improved
14	no	no	20/25	20/25	20/25	20/25					unchanged
15	lt	lt temp	20/800	20/25	20/60	20/25					improved
16	lt	lt temp	20/40	20/25	LP	20/25					lt worse, rt improved

(continued)

TABLE 2: Summary of visual data* (continued)

Case No.	APD	Optic Disc Pallor	Preop Acuity		Postop Acuity		Preop VF		Postop VF		Vision
			Lt	Rt	Lt	Rt	Lt	Rt	Lt	Rt	
17	no	no	20/100	20/20	20/25	20/20					improved
18	no	no	20/20	20/20	20/20	20/20	NA	NA	NA	NA	unchanged

* FC = finger counting; HM = hand motion; LP = light perception; temp = temporal.

and instrumentation, direct surgical approaches for clip obliteration of large and giant ophthalmic aneurysms have evolved. Proximal control of these lesions can be accomplished by exposing the carotid artery in the neck; however, this may not decompress the dome adequately due to collateral filling of the aneurysm through the ophthalmic artery and cavernous branches.³ Direct puncture and “suction decompression” of giant aneurysms via a No. 21 butterfly-type scalp vein needle was described by Flamm.¹³ This method adequately decompresses the aneurysm and aids the dissection and clipping, but it necessitates another hand in the surgical field, and if the needle slips out, may lead to bleeding just at the moment of clip application.^{3,20} In a recent series of 15 patients with visually symptomatic aneurysms, direct aneurysm puncture was performed with or without aneurysmotomy to decompress the optic nerves during clipping.⁸

In 1990, Batjer and Samson⁴ described the technique of retrograde suction decompression via direct cannulation of the cervical ICA with an 18-gauge angiocatheter followed by gentle aspiration using a 20-ml syringe. They reported success in achieving aneurysmal collapse and clipping in more than 40 cases using retrograde suction decompression. The single complication occurred in an elderly patient with severe extracranial and intracranial atherosclerosis in which an arterial dissection necessitated emergency carotid endarterectomy.⁴ Noting this problem, Fan et al.¹¹ revised the technique making use of the carotid bifurcation. Instead of direct clamping of the ICA, the CCA and ECA were isolated, and suction decompression was carried out via the ECA. In addition the aspirated blood was saved for autotransfusion. This tech-

nique was successfully performed in 2 elderly patients with good results. The technique we use here is similar in that we avoid direct puncture of the ICA by cannulating the CCA instead. We also save the aspirate for autotransfusion using cell-saving techniques.

An endovascular modification of the suction-decompression technique was described soon after the original open technique.³⁷ Temporary proximal occlusion of the ICA was accomplished via a transfemoral approach with a 5-Fr 100-cm double lumen occlusion balloon catheter. The aneurysm was collapsed by gentle aspiration through the distal lumen of the balloon catheter. Several reports using variations of this technique have since appeared.^{1,2,10,27,32,44} The advantages include eliminating the need for exposure of the carotid artery in the neck and the simultaneous ability to perform intraoperative angiography. However, multiple complications have been described, including thromboembolism and vessel dissection, and one group calculated a 16% complication rate from available series.³² There is difficulty separating thromboembolic complications into etiological categories, some of which are most certainly intrinsic to the operation itself and some may be due to the addition of endovascular suction decompression. More recently, a comparison of complications between ophthalmic artery aneurysms treated with and without endovascular suction decompression at a single center found no statistically significant difference in complications.¹⁵

Proximal ligation is still a viable option for treatment of giant aneurysms of the carotid artery. In the series reported by Drake et al.⁹ concerning 109 giant carotid ophthalmic or carotid-paraophthalmic aneurysms, 23 were

TABLE 3: Canadian Council of Motor Transport Administrators (CCMTA) Medical Standards for Drivers

Parameter	Definition	Comment
visual acuity	not less than 6/15 (20/50)	both eyes open & examined together
visual field	120 continuous degrees along the horizontal meridian, & 15° above & below fixation	both eyes open & examined together; testing should be performed w/ a standard apparatus, e.g., the Goldmann 3.4e or equivalent measuring procedure w/ a radius of 33 cm
hemianopia & quadrant field defects	complete homonymous or bitemporal hemianopia	license suspended
	complete homonymous or bitemporal inferior quadrantanopia	license suspended
	partial quadrantanopia	may be eligible to operate any class of motor vehicle provided the individual can satisfy the VF standards for that class

Vision after aneurysm clipping with suction decompression

treated with carotid occlusion, of which 86% had excellent or good outcomes. There were 2 strokes and 1 rehemorrhage in that subgroup. The authors noted that this treatment was used more frequently in the early part of their series. Nevertheless, this treatment modality is still used^{3,19,33} sometimes as a salvage maneuver and remains a good fallback option. Case 11 in our series was deemed unclippable, and the patient was treated with trapping and bypass, with excellent visual outcome.

It is for this rare but significant situation that a preoperative BTO should be considered while evaluating treatment options. This may not be required in every case (we used it in only 11 cases), and it is not always accurate. In our single case of trapping and bypass (Case 11), the patient had tolerated a BTO to 30 minutes preoperatively, but following the index trapping surgery, developed a stuttering ischemic clinical course. A CT perfusion study showed relative cerebral hypoperfusion despite adequate angiographic flow, and bypass was performed in delayed fashion on postoperative Day 13.

Endovascular Approaches

Given the technical difficulties inherent in surgical treatment of large and giant paraophthalmic artery aneurysms, endovascular approaches have been developed. These include occlusion of the parent artery, endovascular coiling, stent-assisted coiling, and the newest technical advance, flow diversion.

Permanent balloon occlusion of the parent artery is the endovascular version of proximal surgical ligation. This can be accomplished via coils or balloons within the parent artery itself.^{5,9,14} It is simple, inexpensive, and can be quite effective.⁴² As with surgical carotid ligation, a BTO should be tolerated or bypass should be considered. Obliteration rates of 77%–94% have been quoted, although the suggestion has been made that ICA aneurysms below the ophthalmic artery may be more susceptible to proximal artery occlusion.^{5,14}

Coiling is problematic for large and giant aneurysms. Aneurysm residual rates are high, and recanalization rates can be 35%–59% using GDC coils.²⁹ In a recent retrospective series of unruptured ophthalmic aneurysms and visual compromise, initial coiling results were 50% near complete occlusion and 37.5% significant aneurysm residual. Some degree of coil compaction was noted in 83% on follow-up angiography.¹⁹ At the end of follow-up for 16 patients, only 50% had complete occlusion, 2 deaths were attributed to ruptured aneurysms that were not completely occluded (12.5%), and 13 (76%) of 17 required at least 1 retreatment, which consisted of carotid artery sacrifice in 7 patients, recoiling in 5 patients, and optic nerve decompression in 1 patient.

Adding stents to the construct does not appear to help occlusion rates. In 15 large and giant carotid aneurysms treated mostly with stent-assisted coiling, only 47% had complete or nearly complete occlusion at last follow-up, and 80% of patients required retreatment to reach final outcomes.¹⁸ It seems that coiling, with or without stenting, may not result in complete occlusion of large and giant carotid artery aneurysms. It is still unclear how this may impact the natural history of these lesions.¹⁸

A radical new way of treating aneurysms using mesh stents to modify flow is now being evaluated. These devices can be used as an adjunct to coiling or as stand-alone devices relying on flow diversion to cause aneurysm thrombosis.^{24,25,31,38} The majority of target aneurysms in series evaluating the Pipeline embolization device (ev3, Inc.) are paraophthalmic, and some of these are large to giant.^{25,31,38} The possibility for complete aneurysm thrombosis and involution is suggested by their results.

Visual Outcomes

Visual outcomes are an important consideration in the management of large and giant carotid ophthalmic aneurysms. In published series of ophthalmic segment aneurysms, between one-quarter and one-third are found to be associated with visual symptoms, and most of these aneurysms are large or giant.^{6,7,12,16} In the majority of cases, vision either improves or stabilizes following surgical clipping without the use of adjunctive decompressive methods.^{6,7,12}

However, visual worsening can occur following surgery in those without preoperative visual symptoms.^{7,15,21,30} It has even been suggested that direct clipping of large and giant paraclinoid aneurysms may be associated with worse visual outcomes, and carotid occlusion may be a better solution.³³ Visual worsening occurred in 3 (21%) of 14 cases in this series in patients with preexisting visual deficits. In 1 patient (Case 1), a definite postoperative visual field deficit was noted despite being normal preoperatively. Notably, 5 patients in the current series exhibited progressive improvement in visual fields over time following surgery (Table 4). Some of these patients had worsened fields initially that subsequently improved. Other authors have described this phenomenon after surgery.^{8,30} It appears that postoperative visual parameters may continue to improve over several months.

Evaluating the effect of aneurysm decompression on visual outcome is difficult. It is hypothesized that reduction of mass effect has beneficial effects on cranial nerve recovery.^{6,8,33} A modern surgical series treating a heterogeneous group of visually symptomatic aneurysms used direct aneurysm aspiration and/or aneurysmotomy (for example, the Flamm method); 14 of 15 patients either improved or recovered with respect to vision.⁸ One of the original descriptions of retrograde suction decompression evaluated 4 patients with visually symptomatic giant aneurysms, and none had postoperative visual worsening, but improvement was not documented.³⁹ Another series comparing complications of endovascular retrograde suction decompression with no decompression found similar rates of visual worsening in both groups.¹⁵

Until now, no specific assessment of indirect decompression of the optic apparatus (for example, retrograde suction decompression) on visual outcome could be made. Our study gives the first detailed visual outcomes for open suction decompression used for a specific subgroup of large and giant aneurysms. Visual worsening continues to be an issue, but in 2 of our cases, loss of vision in the ipsilateral eye was accompanied by a significant improvement in visual field in the contralateral eye. In all 4 cases of visual worsening, the visual outcome

TABLE 4: Late improvement

Case No.	Preop VF		Immediate Postop VF		Late Postop VF	
	Lt	Rt	Lt	Rt	Lt	Rt
3						
6						
7						
10						
11						

would permit the patient to legally drive according to the Ministry of Transportation of Ontario. We do not have information on whether the patients actually returned to driving, but we can discern from our comprehensive visual database that they would meet the legal standard for having a driving permit. By comparison, 4 patients (Cases 5, 8, 13, and 16) preoperatively would not have met legal vision requirements to hold a driving permit in Ontario but would have improved sufficiently in at least 1 eye to be allowed to drive. Furthermore, we have documented a few cases of prolonged visual improvement after initial worsening (Table 4). This suggests that longer follow-up may be necessary to determine final visual outcome in these cases.

Coiling of large or giant aneurysms does not appear to be preferable to clipping with respect to visual outcome. Endovascular therapy improves cranial neuropathy in 45%–67% of large and giant aneurysms.^{17,26} However, with respect to compressive optic neuropathy, one series of 19 patients with inoperable giant aneurysms treated with endovascular techniques had improved vision in only 37%, unchanged in 58%, and worsened in 5%.⁴³ These results were obtained using detachable balloons in 12 patients and GDC coils in 7 patients, but the goals of treatment included occlusion of the aneurysm or proximal artery occlusion, and the aneurysms treated were found throughout the carotid system. Subsequently, the same group analyzed 17 patients with visually symptomatic ICA aneurysms (paraophthalmic or superior hypophysial) of large to giant size (12–35 mm).¹⁹ All were treated initially using GDC coils, with final visual outcomes of 50% improved, 25% unchanged, and 25% worsened.

There are numerous case reports and series that warn

against the use of coils in visually symptomatic large to giant aneurysms.^{23,34,35,40,41} In these cases, visual worsening occurred perioperatively in a delayed fashion, thought to be due to inflammation and/or increase in size of the aneurysm as it thrombosed. In this situation, surgical decompression and clipping,^{23,40} carotid sacrifice,¹⁹ or steroids^{35,41} have been advocated as possible solutions.

A recent meta-analysis of 21 series concluded that visual outcomes appeared to be superior for surgical clipping in the subgroup of visually symptomatic aneurysms.³⁶ Specifically, 70% of patients who underwent aneurysm clipping had improved vision, compared with 43% of those who underwent coiling. Additionally, post-treatment worsening was found in 9% of clipped aneurysms compared with 26% of coiled aneurysms. While this meta-analysis contains a heterogeneous aneurysm population both in location and size, this is comparable with our own highly selected experience in which 79% of visually symptomatic patients improved overall vision, while 21% worsened.

Flow-diverting stents, also referred to as endoluminal reconstruction, offer a new option in the management of large and giant carotid ophthalmic aneurysms. The involution of thrombosed giant ophthalmic segment aneurysms with resulting decreased mass effect has been demonstrated graphically.³¹ However, the visual outcomes have not been documented. In the Buenos Aires Pipeline trial, 5 patients had preoperative visual deficits, but there are no outcomes for those patients and there are no visually asymptomatic but at-risk patients (for example, large or giant ophthalmic segment aneurysms).²⁵ Of those with preoperative cranial nerve palsy, 50% had delayed deterioration, but all 3 had improvement with steroids.

Conclusions

Our aim is to provide one of the most complete visual outcomes for a modern surgical aneurysm cohort. Our series is specific for large and giant paraophthalmic aneurysms treated surgically using open retrograde suction decompression in the manner of Batjer and Samson. This is a safe and effective method of decompression of giant aneurysms, minimizing optic nerve manipulation and facilitating reconstruction of the parent artery. This aneurysm subgroup does indeed present a formidable challenge, but our results and those of others suggest that open surgery is still the best way to improve or preserve vision. New flow-diverting stents such as the Pipeline (ev3, Inc.) provide an attractive alternative to open surgery for this patient population. This technology appears to cause aneurysm involution after thrombosis, resulting in relief of mass effect on the optic apparatus while preserving the parent artery. However, we caution that flow diversion studies should document visual outcomes carefully so that proper comparison can be made. This series and others will serve as a baseline for comparison with new flow-diversion technologies.

Disclosure

The authors report no conflict of interest concerning the materials or methods used in this study or the findings specified in this paper.

Author contributions to the study and manuscript preparation include the following. Conception and design: Kole, Lownie. Acquisition of data: all authors. Analysis and interpretation of data: Mattingly, Kole, Nicolle, Pelz, Lownie. Drafting the article: Mattingly, Kole. Critically revising the article: all authors. Reviewed submitted version of manuscript: all authors. Approved the final version of the manuscript on behalf of all authors: Mattingly. Administrative/technical/material support: Lownie. Study supervision: Lownie.

References

- Albert FK, Forsting M, Aschoff A, Krieger D, Kunze S: Clipping of proximal paraclinoid aneurysms with support of the balloon-catheter “trapping- evacuation” technique. Technical note. *Acta Neurochir (Wien)* **125**:138–141, 1993
- Arnautović KI, Al-Mefty O, Angtuaco E: A combined microsurgical skull-base and endovascular approach to giant and large paraclinoid aneurysms. *Surg Neurol* **50**:504–520, 1998
- Batjer HH, Kopitnik TA, Giller CA, Samson DS: Surgery for paraclinoid carotid artery aneurysms. *J Neurosurg* **80**:650–658, 1994
- Batjer HH, Samson DS: Retrograde suction decompression of giant paraclinoid aneurysms. Technical note. *J Neurosurg* **73**:305–306, 1990
- Clarençon F, Bonneville F, Boch AL, Lejean L, Biondi A: Parent artery occlusion is not obsolete in giant aneurysms of the ICA. Experience with very-long-term follow-up. *Neuroradiology* **53**:973–982, 2011
- Date I, Asari S, Ohmoto T: Cerebral aneurysms causing visual symptoms: their features and surgical outcome. *Clin Neurol Neurosurg* **100**:259–267, 1998
- Day AL: Aneurysms of the ophthalmic segment. A clinical and anatomical analysis. *J Neurosurg* **72**:677–691, 1990
- de Oliveira JG, Borba LAB, Rassi-Neto A, de Moura SM, Sanchez-Júnior SL, Rassi MS, et al: Intracranial aneurysms presenting with mass effect over the anterior optic pathways: neurosurgical management and outcomes. *Neurosurg Focus* **26**(5):E3, 2009
- Drake CG, Peerless SJ, Ferguson GG: Hunterian proximal arterial occlusion for giant aneurysms of the carotid circulation. *J Neurosurg* **81**:656–665, 1994
- Fahlbusch R, Nimsky C, Huk W: Open surgery of giant paraclinoid aneurysms improved by intraoperative angiography and endovascular retrograde suction decompression. *Acta Neurochir (Wien)* **139**:1026–1032, 1997
- Fan YW, Chan KH, Lui WM, Hung KN: Retrograde suction decompression of paraclinoid aneurysm—a revised technique. *Surg Neurol* **51**:129–131, 1999
- Ferguson GG, Drake CG: Carotid-ophthalmic aneurysms: visual abnormalities in 32 patients and the results of treatment. *Surg Neurol* **16**:1–8, 1981
- Flamm ES: Suction decompression of aneurysms. Technical note. *J Neurosurg* **54**:275–276, 1981
- Fox AJ, Viñuela F, Pelz DM, Peerless SJ, Ferguson GG, Drake CG, et al: Use of detachable balloons for proximal artery occlusion in the treatment of unclippable cerebral aneurysms. *J Neurosurg* **66**:40–46, 1987
- Fulkerson DH, Horner TG, Payner TD, Leipzig TJ, Scott JA, DeNardo AJ, et al: Endovascular retrograde suction decompression as an adjunct to surgical treatment of ophthalmic aneurysms: analysis of risks and clinical outcomes. *Neurosurgery* **64** (3 Suppl):ons107–ons112, 2009
- Fulkerson DH, Horner TG, Payner TD, Leipzig TJ, Scott JA, DeNardo AJ, et al: Results, outcomes, and follow-up of remnants in the treatment of ophthalmic aneurysms: a 16-year experience of a combined neurosurgical and endovascular team. *Neurosurgery* **64**:218–230, 2009
- Gruber A, Killer M, Bavinzski G, Richling B: Clinical and angiographic results of endosaccular coiling treatment of giant and very large intracranial aneurysms: a 7-year, single-center experience. *Neurosurgery* **45**:793–804, 1999
- Hauck EF, Welch BG, White JA, Replogle RE, Purdy PD, Pride LG, et al: Stent/coil treatment of very large and giant unruptured ophthalmic and cavernous aneurysms. *Surg Neurol* **71**:19–24, 2009
- Heran NS, Song JK, Kupersmith MJ, Niimi Y, Namba K, Langer DJ, et al: Large ophthalmic segment aneurysms with anterior optic pathway compression: assessment of anatomical and visual outcomes after endosaccular coil therapy. *J Neurosurg* **106**:968–975, 2007
- Heros RC, Nelson PB, Ojemann RG, Crowell RM, DeBrun G: Large and giant paraclinoid aneurysms: surgical techniques, complications, and results. *Neurosurgery* **12**:153–163, 1983
- Hoh BL, Carter BS, Budzik RF, Putman CM, Ogilvy CS: Results after surgical and endovascular treatment of paraclinoid aneurysms by a combined neurovascular team. *Neurosurgery* **48**:78–90, 2001
- Jennett B, Bond M: Assessment of outcome after severe brain damage. *Lancet* **1**:480–484, 1975
- Litofsky NS, Viñuela F, Giannotta SL: Progressive visual loss after electrothrombosis treatment of a giant intracranial aneurysm: case report. *Neurosurgery* **34**:548–551, 1994
- Lubicz B, Collignon L, Raphaeli G, De Witte O: Pipeline flow-diverter stent for endovascular treatment of intracranial aneurysms: preliminary experience in 20 patients with 27 aneurysms. *World Neurosurg* **76**:114–119, 2011
- Lylyk P, Miranda C, Ceratto R, Ferrario A, Scrivano E, Luna HR, et al: Curative endovascular reconstruction of cerebral aneurysms with the pipeline embolization device: the Buenos Aires experience. *Neurosurgery* **64**:632–643, 2009
- Malisch TW, Guglielmi G, Viñuela F, Duckwiler G, Gobin YP, Martin NA, et al: Unruptured aneurysms presenting with mass effect symptoms: response to endosaccular treatment with Guglielmi detachable coils. Part I. Symptoms of cranial nerve dysfunction. *J Neurosurg* **89**:956–961, 1998
- Mizoi K, Kinouchi H, Takahashi A, Yoshimoto T: Surgical treatment of giant internal carotid artery aneurysms. *Int Congr Ser* **1247**:75–84, 2002

28. Molyneux A, Kerr R, Stratton I, Sandercock P, Clarke M, Shrimpton J, et al: International Subarachnoid Aneurysm Trial (ISAT) of neurosurgical clipping versus endovascular coiling in 2143 patients with ruptured intracranial aneurysms: a randomised trial. **Lancet** **360**:1267–1274, 2002
29. Murayama Y, Nien YL, Duckwiler G, Gobin YP, Jahan R, Frazee J, et al: Guglielmi detachable coil embolization of cerebral aneurysms: 11 years' experience. **J Neurosurg** **98**:959–966, 2003
30. Nanda A, Javalkar V: Microneurosurgical management of ophthalmic segment of the internal carotid artery aneurysms: single-surgeon operative experience from Louisiana State University, Shreveport. **Neurosurgery** **68**:355–371, 2011
31. Nelson PK, Lylyk P, Szikora I, Wetzel SG, Wanke I, Fiorella D: The pipeline embolization device for the intracranial treatment of aneurysms trial. **AJNR Am J Neuroradiol** **32**:34–40, 2011
32. Ng PY, Huddle D, Gunel M, Awad IA: Intraoperative endovascular treatment as an adjunct to microsurgical clipping of paraclinoid aneurysms. **J Neurosurg** **93**:554–560, 2000
33. Nonaka T, Haraguchi K, Baba T, Koyanagi I, Houkin K: Clinical manifestations and surgical results for paraclinoid cerebral aneurysms presenting with visual symptoms. **Surg Neurol** **67**:612–619, 2007
34. Pickett GE, Laitt RD, Herwadkar A, Hughes DG: Visual pathway compromise after hydrocoil treatment of large ophthalmic aneurysms. **Neurosurgery** **61**:E873–E874, 2007
35. Schmidt GW, Oster SF, Golnik KC, Tumialán LM, Biousse V, Turbin R, et al: Isolated progressive visual loss after coiling of paraclinoid aneurysms. **AJNR Am J Neuroradiol** **28**:1882–1889, 2007
36. Schuss P, Güresir E, Berkefeld J, Seifert V, Vatter H: Influence of surgical or endovascular treatment on visual symptoms caused by intracranial aneurysms: single-center series and systematic review. Clinical article. **J Neurosurg** **115**:694–699, 2011
37. Scott JA, Horner TG, Leipzig TJ: Retrograde suction decompression of an ophthalmic artery aneurysm using balloon occlusion. Technical note. **J Neurosurg** **75**:146–147, 1991
38. Szikora I, Berentei Z, Kulcsar Z, Marosfoi M, Vajda ZS, Lee W, et al: Treatment of intracranial aneurysms by functional reconstruction of the parent artery: the Budapest experience with the pipeline embolization device. **AJNR Am J Neuroradiol** **31**:1139–1147, 2010
39. Tamaki N, Kim S, Ehara K, Asada M, Fujita K, Taomoto K, et al: Giant carotid-ophthalmic artery aneurysms: direct clipping utilizing the “trapping-evacuation” technique. **J Neurosurg** **74**:567–572, 1991
40. Tawk RG, Villalobos HJ, Levy EI, Hopkins LN: Surgical decompression and coil removal for the recovery of vision after coiling and proximal occlusion of a clinoidal segment aneurysm: technical case report. **Neurosurgery** **58**:E1217, 2006
41. Turner RD, Byrne JV, Kelly ME, Mitsos AP, Gonugunta V, Lalloo S, et al: Delayed visual deficits and monocular blindness after endovascular treatment of large and giant paraophthalmic aneurysms. **Neurosurgery** **63**:469–475, 2008
42. van Rooij WJ, Sluzewski M: Unruptured large and giant carotid artery aneurysms presenting with cranial nerve palsy: comparison of clinical recovery after selective aneurysm coiling and therapeutic carotid artery occlusion. **AJNR Am J Neuroradiol** **29**:997–1002, 2008
43. Vargas ME, Kupersmith MJ, Setton A, Nelson K, Berenstein A: Endovascular treatment of giant aneurysms which cause visual loss. **Ophthalmology** **101**:1091–1098, 1994
44. Vega-Basulto S: [Retrograde suction decompression technique for paraclinoidal aneurysms.] **Rev Neurol** **37**:312–317, 2003 (Span)

Manuscript submitted April 10, 2012.

Accepted February 4, 2013.

Please include this information when citing this paper: published online March 22, 2013; DOI: 10.3171/2013.2.JNS12735.

Address correspondence to: Thomas Mattingly, M.D., Department of Clinical Neurological Sciences, University of Western Ontario, London Health Sciences Centre, 339 Windermere Road, London, Ontario N6A 5A5, Canada. email: Thomas.Mattingly@londonhospitals.ca.