

## CASE REPORT

# Blunt traumatic internal carotid artery dissection with delayed stroke in a young skydiver

Michael Abbo,<sup>1</sup> Kosar Hussain,<sup>2</sup> Mohammad Baqer Mohammad Ali<sup>3</sup>

<sup>1</sup>Department of Emergency Medicine, Rashid Hospital Trauma Center, Dubai Health Authority, Dubai, UAE

<sup>2</sup>Department of Internal Medicine, Dubai Health Authority, Dubai, UAE

<sup>3</sup>Medical ICU, Rashid Hospital, Dubai Health Authority, Dubai, UAE

## Correspondence to

Dr Kosar Hussain,  
koshussain@dha.gov.ae

## SUMMARY

We describe a case of a 33-year-old skydiver who presented to the emergency department after a traumatic landing following a parachuting episode. He initially presented with right knee pain secondary to a tibial plateau fracture. There were no neurological symptoms or signs at the initial assessment. While he was still in the emergency department, he suddenly developed headache and left-sided hemiplegia. An urgent work-up showed right middle cerebral artery thrombosis with right internal carotid thrombosis and dissection. We have discussed some possible mechanism of injury in skydiving that may have predisposed to the occurrence of cervical dissection in our patient.

## BACKGROUND

To the best of our knowledge no previous cases of internal cervical artery dissection causing stroke after a skydiving episode has been previously reported in the literature.

Internal carotid artery dissection is one of the important causes of stroke in young adults, which can lead to a potentially life-threatening condition. Failure to consider, diagnose and treat this condition promptly may result in long-term neurological disability or death.

## CASE PRESENTATION

A 32-year-old man presented to the emergency department with right knee pain and swelling that occurred after a traumatic landing following a skydiving episode in a canopy-piloting tournament. Gaining popularity with competitors, freestyle canopy-piloting puts the skydiver in contact with the water at high speeds, increasing the risk of a unique deceleration injury. Following an uneventful initial free-fall he landed on water surface and tumbled many times prior to coming to a halt. The patient, who was a professional skydiver, did not recall any forced hyperextension, hyperflexion or rotation of the neck during the take-off or free-fall. There was no direct head trauma or loss of consciousness. Besides his right knee pain he was completely asymptomatic. There was no head or neck pain. At initial assessment his Glasgow Coma Scale (GCS) was 15/15 and his vitals signs were stable. There was no sign of any neurological deficit (in particular no clinical signs suggestive of a Horner syndrome were noted). He had no phenotypic features of a connective tissue disease. He was reviewed by the trauma team and his x-ray showed a right tibial plateau fracture with minimal effusion.

After a time interval of 6 h, while the patient was still in the emergency department, he suddenly developed a generalised headache and left-sided weakness. On examination he was found to have a dense left-sided hemiplegia, an upper motor neuron lesion of the left facial nerve, dysarthria and a left-sided neglect.

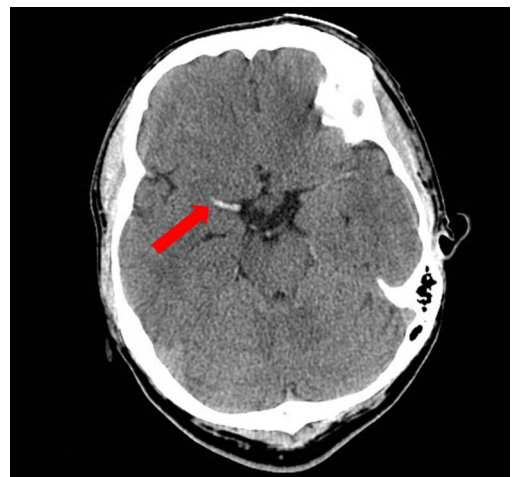## INVESTIGATIONS

An urgent brain CT showed a hyperdense right middle cerebral artery (MCA) sign, which was suggestive of right MCA thrombosis (figure 1). Based on the preceding history of trauma, an urgent cerebral and carotid CT angiography was carried out which showed right MCA thrombosis and right internal carotid (ICA) thrombosis and dissection (figures 2–4).

## TREATMENT

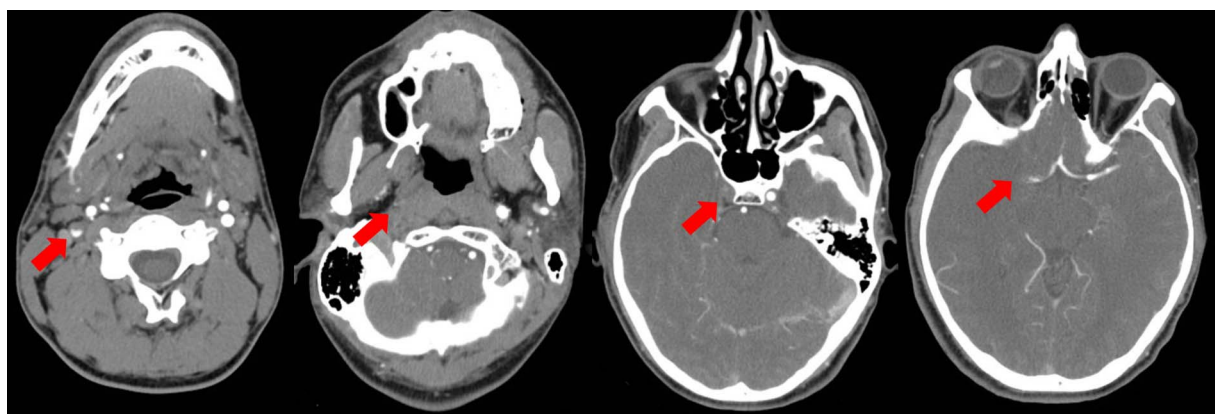
The neurological and neurosurgical teams were consulted. They decided to manage the patient conservatively with aspirin. He was admitted to the ICU for close observation of his vital signs and neurological status.

Other therapeutic options that we considered for this patient was thrombolysis with tissue plasminogen activator (t-PA); however, it was deemed inappropriate as it was a massive stroke with a high risk of haemorrhagic transformation and also due to the recent history of trauma causing a fracture in the right tibia. Therapeutic anticoagulation was also not started because of the high risk of bleeding in this patient.



**Figure 1** The initial brain CT showed a hyperdense right middle cerebral artery sign.

**To cite:** Abbo M, Hussain K, Ali MBM. *BMJ Case Rep* Published online: [please include Day Month Year] doi:10.1136/bcr-2012-008412



**Figure 2** Carotid and cerebral CT angiogram showed a filling defect in right internal carotid artery and right middle cerebral artery.

While in the ICU the patient continued to have dense left-sided hemiplegia. He was occasionally drowsy, however responding to verbal stimuli. GCS was fluctuating between 12 and 15. Throughout the course of his stay in the ICU he was haemodynamically stable and did not require any ventilator support. Brain CT scan was repeated after 2 days and it showed a large hypodense lesion in the frontotemporoparietal region with a mild mass effect on the right lateral ventricle with a midline shift (figure 5). He was reviewed by the neurosurgical team and they advised conservative management with close observation and administration of intravenous mannitol.

A repeat brain CT after a week did not show any gross interval changes. His GCS improved to 15 and his vitals remained stable. He was then started on prophylactic dose of low-molecular-weight heparin and physiotherapy with assisted out-of-bed mobilisation.

### OUTCOME AND FOLLOW-UP

The patient was discharged after 3 weeks. GCS at discharge was 15. His dysarthria had improved significantly; however, the power on his left side continued to be 0/5.

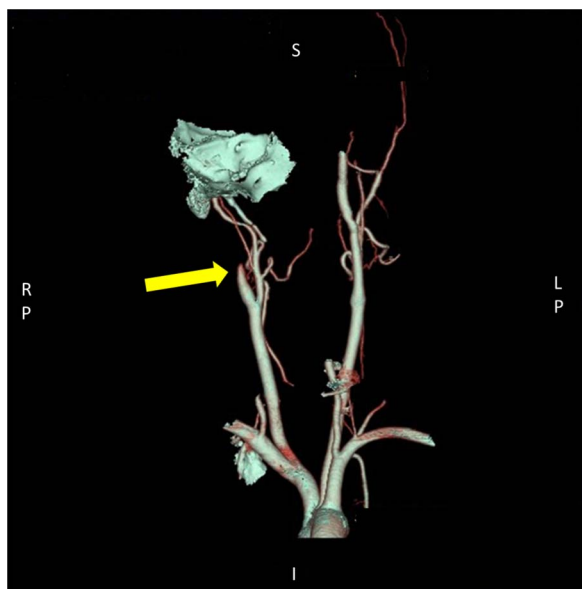
He was discharged on an antiplatelet agent with a recommendation to follow-up with the neurologist.

### DISCUSSION

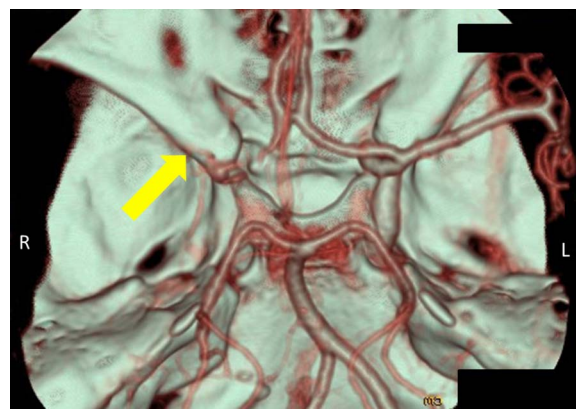
Cervicocerebral dissection is a potentially life-threatening condition, that is, increasingly being recognised as one of the main causes of ischaemic strokes among young adults.<sup>1</sup> This condition may involve both the intracranial and extracranial segments of ICA and vertebral artery. However, the extracranial segments are more likely to be injured due to their mobility and proximity to surrounding bony structures.<sup>2</sup> Patients who have had a stroke secondary to ICA dissection are generally younger and have a worst prognosis compared to those who have had stroke secondary to atherothrombotic occlusions.<sup>3</sup>

Dissection starts as an intimal tear which causes blood to enter the arterial wall to form an intramural haematoma. This can progress to either stenosis or an aneurysmal dilation of the artery. Damage of the endothelial lining can activate platelets and the coagulation pathway, which eventually leads to a thrombus formation.<sup>4</sup> The signs and symptoms of ICA dissection are either due to localised mass effect due to compression of surrounding structures or cerebral ischaemia. A dissection may lead to cerebral ischaemia either by haemodynamic insufficiency or by distal embolisation.<sup>5 6</sup>

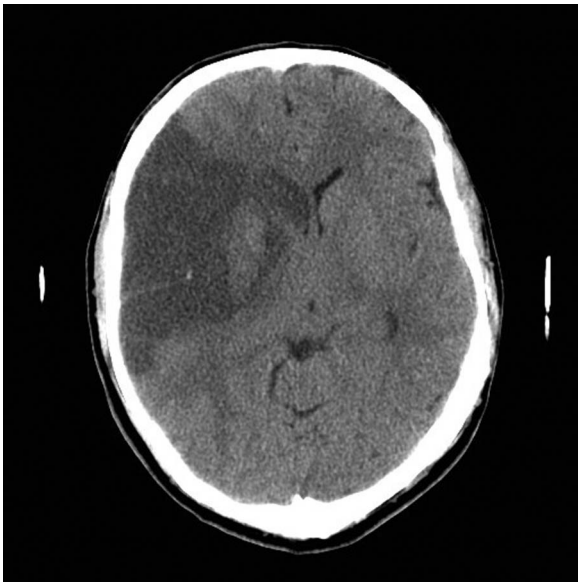
In cases of ICA dissection, the lesion frequently involves the distal parts of the ICA.<sup>7</sup> However in our case the dissection was more proximally located in the right ICA.



**Figure 3** Three-dimensional reconstruction of carotid CT angiogram images showed a complete obliteration of blood flow in right internal carotid artery.



**Figure 4** Three-dimensional reconstruction of cerebral CT angiogram images showed a complete obliteration of blood flow in right middle cerebral artery.



**Figure 5** Repeat brain CT showed a large hypodense lesion in the frontotemporoparietal region with a mild mass effect on the right lateral ventricle and a midline shift.

Cervicocerebral artery dissection can be either traumatic or spontaneous. Spontaneous dissection is more often seen in persons with underlying structural weakness in the vessel wall. In traumatic dissections, the severity of the trauma can range from a mild impact such as a forceful cough to severe impacts such as blunt head and neck injuries in polytrauma victims.<sup>8 9</sup>

The availability of improved imaging modalities has led to increased recognition of sport-related cervicocerebral artery dissection. A prospective study by Schneidereit *et al* evaluated the role of CT angiography-based screening protocols in patients with blunt trauma. They found the incidence of blunt vascular neck injuries to be 1.1%, which was significantly higher than the 0.17% incidence before radiological screening of the cases.<sup>10</sup>

In addition to the direct impact of trauma, the pathogenesis of ICA dissection in sport-related activities is postulated to be related to a number of other causes. This includes structural aberrations in the vessel wall and weaknesses in the connective tissue.<sup>11</sup> Zhou *et al* have described a case of a young man who presented with stroke symptoms that occurred 2 h after a bungee-jumping event. The impact from sudden deceleration involved in this activity was postulated to have caused carotid artery dissection, which subsequently led to stroke.<sup>12</sup> Other sports that are reported to be implicated in causing cervicocerebral artery dissection include scuba diving, basketball, wakeboarding, diving and martial arts.<sup>13–17</sup> Several cases that reported the occurrence of cervicocerebral dissection after roller coaster rides have been described in literature.<sup>18–20</sup> Interestingly, Schneck *et al*<sup>19</sup> described a case of bilateral vertebral artery dissection that was diagnosed months after a bumpy roller coaster ride.

Skydiving is a form of extreme sports which carries with it inherent risks of traumatic injuries. However after reviewing medical literature, we could not find any reported case of ICA dissection after parachuting. Unedited internet blogs have described this phenomenon. This is perhaps due to under-reporting of such cases and thus calls for increasing awareness about such an association.

There are many possible mechanisms that may predispose skydivers to carotid dissection. One possibility is ‘hard-opening’ of the parachute may cause forced hyperextension of the neck, which may attribute to traumatic ICA dissection. Another mechanism, which we believe caused the dissection in our patient, is related to the increasing popularity of canopy-piloting. An aspect of this sport is ‘pond swooping’ which typically uses a body of water to touch or display a skill prior to landing on solid ground on the other side. This type of canopy piloting is increasingly gaining popularity among both skydivers and spectators. This manoeuvre involves trying to hit the surface at high speeds and then decelerating, while dragging through the surface of water. The smallest error in landing predisposes the skydiver to various impact injuries and this is what had happened to our patient.

In cases of cervicocerebral artery dissection, the local signs and symptoms often precede the cerebral ischaemic symptoms. Classically ICA dissection presents with a triad of craniocervical pain or Horner syndrome, that is, followed after a latency period of hours-to-days by ischaemic manifestations. Although such classic symptoms are seen in less than a third of the cases, the presence of two of the above criteria are highly suggestive of a diagnosis.<sup>2</sup> However, our patient did not exhibit any of the usual warning symptoms of ICA dissection prior to the onset of stroke. In view of this latent period and the lack of warning symptoms in the majority of patients who go on to stroke, clinicians should maintain a high suspicion and low threshold to perform diagnostic studies based on mechanism of injury.

Currently MRI angiography is the preferred modality for diagnosis of cervicocerebral artery dissection due to its high sensitivity and specificity. It also does not involve exposure to harmful radiations. However in conditions where MRI is inaccessible, CT angiography is considered the next best option. Colour Doppler ultrasonography is another non-invasive modality; but it lacks sensitivity.<sup>21</sup>

There are no randomised control trials conducted to compare the various treatment modalities in cases of cervicocerebral artery dissection. A Cochrane systematic review by Lyrer *et al* assessed the use of antiplatelet and anticoagulant medications in cases of traumatic and spontaneous extracranial internal carotid artery dissection. They reported that there was no significant difference between the antiplatelet and anticoagulant groups.<sup>22</sup> It is generally recommended to treat each patient on a case-by-case basis.<sup>21</sup> In our case, the patient was initially started on antiplatelet agents. Anticoagulants were not initiated immediately due to the recent history of trauma and high risk for haemorrhagic transformation of the infarct.

### Learning points

- ▶ Traumatic carotid dissection may be silent until secondary ischaemia occurs.
- ▶ Carotid dissection is described in ‘canopy-piloting’ which is gaining in popularity.
- ▶ Physicians should be vigilant to pick up the early subtle signs of cervicocerebral artery dissections.
- ▶ A diagnosis of traumatic cervicocerebral artery dissections can be missed as there can be an asymptomatic ‘latent period’ so diagnostic studies are advocated if the mechanism is appropriate.
- ▶ Use of anticoagulants is controversial and need to be considered on a case-by-case basis.

**Competing interests** None.

**Patient consent** Obtained.

**Provenance and peer review** Not commissioned; externally peer reviewed.

## REFERENCES

- 1 Leys D, Bandu L, Henon H, *et al.* Clinical outcome in 287 consecutive young adults (15 to 45 years) with ischemic stroke. *Neurology* 2002;59:26–33.
- 2 Schievink WI. Spontaneous dissection of the carotid and vertebral arteries. *N Engl J Med* 2001;344:898–906.
- 3 Milhaud D, De Freitas GR, Van Melle G, *et al.* Occlusion due to carotid artery dissection: a more severe disease than previously suggested. *Arch Neurol* 2002;59:557–61.
- 4 Redekop GJ. Extracranial carotid and vertebral artery dissection: a review. *Can J Neurol Sci* 2008;35:146–52.
- 5 Weiller C, Mullges W, Ringelstein EB, *et al.* Patterns of brain infarctions in internal carotid artery dissections. *Neurosurg Rev* 1991;14:111–13.
- 6 Lucas C, Moulin T, Deplanque D, *et al.* Stroke patterns of internal carotid artery dissection in 40 patients. *Stroke* 1998;29:2646–8.
- 7 Thanvi B, Munshi SK, Dawson SL, *et al.* Carotid and vertebral artery dissection syndromes. *Postgrad Med J* 2005;81:383–8.
- 8 Caso V, Paciaroni M, Bogousslavsky J. Environmental factors and cervical artery dissection. *Front Neurol Neurosci* 2005;20:44–53.
- 9 Mutze S, Rademacher G, Matthes G, *et al.* Blunt cerebrovascular injury in patients with blunt multiple trauma: diagnostic accuracy of duplex Doppler US and early CT angiography. *Radiology* 2005;237:884–92.
- 10 Schneiderei NP, Simons R, Nicolaou S, *et al.* Utility of screening for blunt vascular neck injuries with computed tomographic angiography. *J Trauma* 2006;60:209–15; discussion 215–16.
- 11 Dharmasaroja P, Dharmasaroja P. Sports-related internal carotid artery dissection: pathogenesis and therapeutic point of view. *Neurologist* 2008;14:307–11.
- 12 Zhou W, Huynh TT, Koungias P, *et al.* Traumatic carotid artery dissection caused by bungee jumping. *J Vasc Surg* 2007;46:1044–6.
- 13 Konno K, Kurita H, Ito N, *et al.* Extracranial vertebral artery dissection caused by scuba diving. *J Neurol* 2001;248:816–17.
- 14 De Giorgio F, Vetrugno G, De Mercurio D, *et al.* 1. Dissection of the vertebral artery during a basketball game: a case report. *Med Sci Law* 2004;44:80–6.
- 15 Fridley J, Mackey J, Hampton C, *et al.* Internal carotid artery dissection and stroke associated with wakeboarding. *J Clin Neurosci* 2011;18:1258–60.
- 16 Furtner M, Werner P, Felber S, *et al.* Bilateral carotid artery dissection caused by springboard diving. *Clin J Sport Med* 2006;16:76–8.
- 17 Slowey M, Maw G, Furey J. Case report on vertebral artery dissection in mixed martial arts. *Emerg Med Australas* 2012;24:203–6.
- 18 Sa Leita D, Mendonca D, Iyer H, *et al.* Neurologic complication after a roller coaster ride. *Am J Emerg Med* 2012;30:249.e5–7.
- 19 Schneck M, Simionescu M, Bijari A. Bilateral vertebral artery dissection possibly precipitated in delayed fashion as a result of roller coaster rides. *J Stroke Cerebrovasc Dis* 2008;17:39–41.
- 20 Stahlfeld KR, Roozrokh HC. Traumatic bilateral ECCA injury in a roller coaster enthusiast. *Ann Vasc Surg* 2002;16:505–8.
- 21 Debette S, Leys D. Cervical-artery dissections: predisposing factors, diagnosis, and outcome. *Lancet Neurol* 2009;8:668–78.
- 22 Lyer P, Engelter S. Antithrombotic drugs for carotid artery dissection. *Cochrane Database Syst Rev* 2010(10):CD000255.

Copyright 2013 BMJ Publishing Group. All rights reserved. For permission to reuse any of this content visit <http://group.bmj.com/group/rights-licensing/permissions>.  
BMJ Case Report Fellows may re-use this article for personal use and teaching without any further permission.

Become a Fellow of BMJ Case Reports today and you can:

- ▶ Submit as many cases as you like
- ▶ Enjoy fast sympathetic peer review and rapid publication of accepted articles
- ▶ Access all the published articles
- ▶ Re-use any of the published material for personal use and teaching without further permission

For information on Institutional Fellowships contact [consortiasales@bmjgroup.com](mailto:consortiasales@bmjgroup.com)

Visit [casereports.bmj.com](http://casereports.bmj.com) for more articles like this and to become a Fellow