

Moyamoya disease with mesial temporal sclerosis

Case report

SUBASH LOHANI, M.D.,¹ JOSEPH R. MADSEN, M.D.,¹ ANN M. BERGIN, M.B., Sc.M.,²
AND EDWARD R. SMITH, M.D.¹

Departments of ¹Neurosurgery and ²Neurology, Boston Children's Hospital, Boston, Massachusetts

The combination of moyamoya syndrome and symptomatic mesial temporal sclerosis (MTS) has not previously been reported. The authors present the case of a 5-year-old boy with symptomatic MTS who developed progressive moyamoya syndrome. This combination of progressive moyamoya and a structural seizure focus presented a unique clinical problem, with the natural history of MTS predicting a high likelihood of needing resection in the future, which could be challenging following any type of moyamoya-related revascularization surgery. In anticipation of this problem, the patient underwent resection of the right inferior and mesial temporal lobe followed by right pial synangiosis as a 1-day combined operation. Postoperatively he recovered well without any neurological deficits and had an uneventful hospital stay. This case of moyamoya is unique in its association with MTS, and for the simultaneous operations for pial synangiosis and temporal lobectomy, highlighting the importance of surgical planning in patients with dual pathological processes.

(<http://thejns.org/doi/abs/10.3171/2013.3.PEDS12437>)

KEY WORDS • moyamoya • seizure disorder • mesial temporal sclerosis •
pial synangiosis • temporal lobectomy • vascular disorders

MOYAMOYA is a cerebrovascular condition that predisposes affected patients to stroke in association with progressive stenosis of the intracranial internal carotid arteries and their proximal branches. Although moyamoya is found in association with numerous medical conditions (including presenting with seizures), to date we are unaware of reports linking moyamoya with MTS.⁷ The presence of MTS is particularly important because it is a distinct cause of epilepsy known to be amenable to surgical treatment.² The natural history of MTS in children predicts a high likelihood of needing operative intervention at some point to control the seizures. In addition, there are data to support a role for surgical revascularization of progressive moyamoya in children (even if they are asymptomatic).⁶ Coexistence of these 2 distinct pathologies is both interesting and has implications for planning long-term treatment strategies.

Case Report

History and Examination. This patient was born at full term, without complications. Seizures started at 3 months of age with infantile spasms involving bilateral arm and leg extension, and evolved over the subsequent

year to clusters of arm and shoulder stiffening with eye squeezing. He was evaluated with EEG, which revealed hypsarrhythmia without focality; and MRI, which revealed a small right temporal arachnoid cyst (2 × 1.5 cm), a possible right medial temporal cortical dysplasia, and right MTS (Fig. 1). Of interest, no arteriopathy was noted at 2 years of age. Initial attempts to treat seizures with adrenocorticotrophic hormone, pyridoxine, Klonopin, and Topamax were unsuccessful, but ultimately seizure control was obtained with Keppra and zonisamide. Because of improved medical control of his seizures, a planned right temporal lobectomy was deferred. At the age of 5 years, he began to manifest new symptoms, described as brief episodes (seconds to minutes in length) of speech arrest, left-sided weakness, and lethargy. Repeat imaging revealed a right-sided arteriopathy consistent with moyamoya. An arteriogram was done that demonstrated Suzuki Stage III moyamoya on the right side (Fig. 1). His family history was unremarkable for moyamoya or other neurovascular disease. Low-dose (41.5 mg) aspirin therapy was started at that time and he was referred for potential surgical treatment.

Repeat video-EEG telemetry performed at the age of 5 years captured 18 seizures on EEG studies after anti-

Abbreviations used in this paper: EEG = electroencephalography; MTS = mesial temporal sclerosis.

This article contains some figures that are displayed in color online but in black-and-white in the print edition.

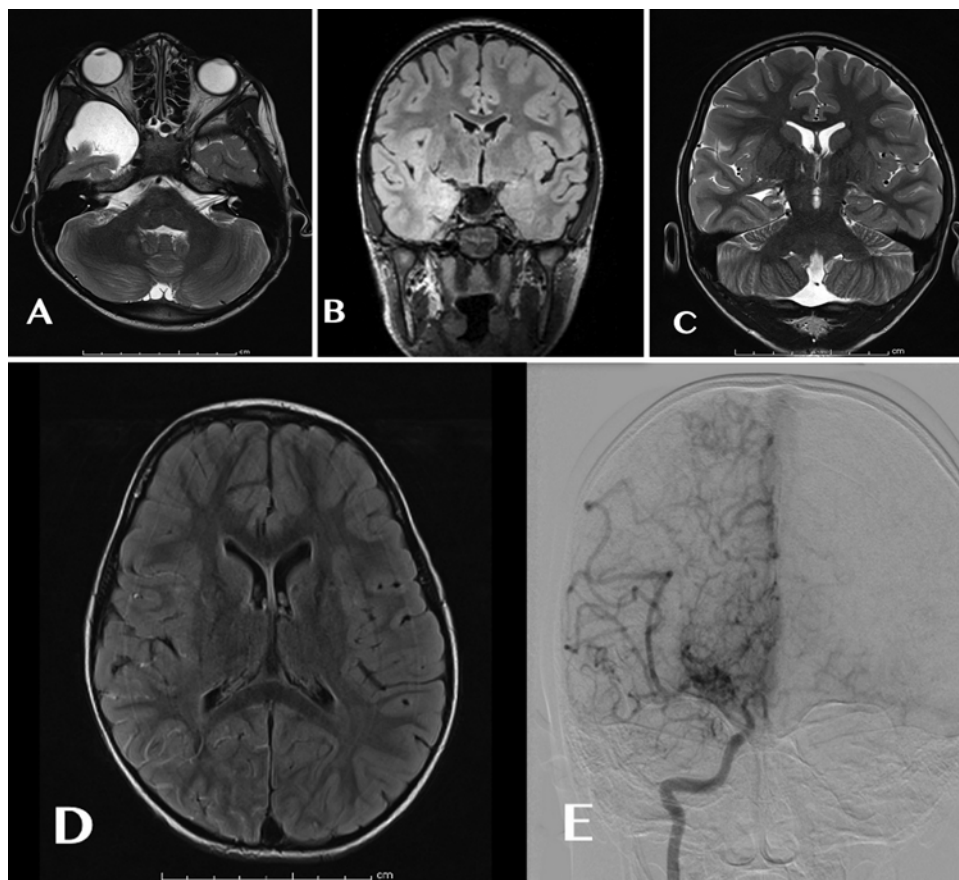


FIG. 1. Preoperative images. **A:** Axial T2-weighted MR image revealing a right middle cranial fossa arachnoid cyst. **B:** Coronal FLAIR MR image revealing mild asymmetrical increased signal of the medial aspect of the right medial temporal lobe, representing focal cortical dysplasia. **C:** Coronal T2-weighted MR image showing atrophic changes of the right hippocampus with associated ex vacuo dilation of the right lateral ventricle, compatible with MTS. **D:** Axial FLAIR image demonstrating slow flow in the right temporoparietal region represented by bright signal in the sulci (ivy sign). **E:** Right internal carotid artery injection (anteroposterior view) arteriogram showing severe right-sided stenocclusive changes particularly involving the right M_1 with corresponding perforating vessel proliferation consistent with moyamoya disease, Suzuki Stage III.

convulsant medication withdrawal. Seizures arose in the right midposterior temporal region, and some were associated with subtle behavioral arrest with low-amplitude, high-frequency body jerks. These were identified by the parent as his typical seizures. In many electroencephalographic events, no clinical correlate was appreciated.

Surgical Decision Making. At the time of referral to neurosurgery for evaluation of his moyamoya, the child had been followed up for his epilepsy. A multidisciplinary discussion was undertaken, involving the epilepsy neurologists, neurosurgeons, and neurovascular team. It was decided that revascularization was needed for the progressive moyamoya, and debate centered on the risks and benefits of temporal lobectomy during the same operation. Under consideration was the likelihood of needing surgical treatment of his MTS later in life (despite good current control of his seizures), given the difficulty in performing a lobectomy in the setting of established surgical collateral vessels versus the added risk of doing a combined surgery in a single sitting. It was decided to proceed with a combined operation in the same sitting, including both mesial temporal lobectomy and pial synangiosis.

Operation and Postoperative Course. The patient was taken to the operating room for a single-stage operation: right frontotemporal craniotomy, corticography with selective resection of the mesial temporal lobe, and pial synangiosis. (As part of the approach, the small arachnoid cyst was fenestrated.) The sequence of the operation was 1) dissection of the superficial temporal artery; 2) opening a wide frontotemporal craniotomy, with emphasis on exposing the anterior temporal region; 3) mesial temporal lobectomy (with intraoperative corticography and fenestration of the arachnoid cyst); and 4) pial synangiosis with wide opening of the arachnoid and placement of the pial sutures (Fig. 2).

Intraoperative EEG studies demonstrated symmetrical, continuous activity, mostly sharply contoured high-voltage (60–70 μ V) beta with admixed theta and delta activity. There were no clear epileptiform discharges and no electroencephalographic seizures were seen. No significant electroencephalographic slowing was observed during the case. Intraoperative corticography recording was performed in the right temporal region. Recordings made prior to resection showed spikes arising from the mesial

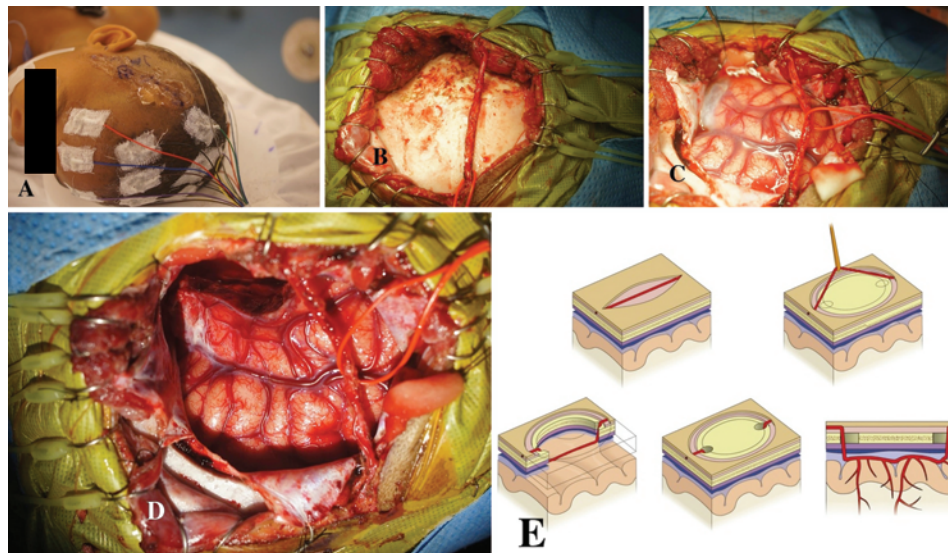


Fig. 2. Intraoperative photographs and schematic drawings. **A:** Patient positioned supine with his right side up and with EEG leads attached for intraoperative monitoring, allowing exposure of the operative field. **B:** Right superficial temporal artery dissected in preparation of pial synangiosis. **C:** Right frontotemporal craniotomy is done and the dura mater opened, exposing the right frontal and temporal lobes. **D:** Postresection photograph of right temporal lobe structures and arachnoid cyst. **E:** Schematic representations of the key steps in pial synangiosis.

temporal structures. Postresection corticography showed resolution of these spikes.

Postoperatively the patient developed no new neurological deficits. His hospital course was uneventful, and he was discharged home on postoperative Day 5. He had no further seizures. A 6-month postoperative MRI study revealed excellent collateral development and no new strokes, along with reversal of the previous “ivy sign”—a linear, high signal that follows the sulci, resulting from diminished cortical blood flow as seen in FLAIR sequences on MRI.⁷

Pathological Findings. Cerebral cortex and subcortical white matter demonstrated mild gliosis and focal neuronal loss. The hippocampus specimen had neuronal depletion of pyramidal cells and moderate gliosis consistent with MTS. There were some SM131-labeled neurons, raising the possibility of mild heterotopic change. Fragments of arachnoid and dense fibroconnective tissue were noted in the arachnoid cyst specimen.

Discussion

This case highlights 2 interesting issues. First is the association of moyamoya syndrome with MTS. Given that moyamoya and MTS (and also in this case an arachnoid cyst) may lead to seizures, this case demonstrates the need to pay careful attention to the clinical presentation.^{2,3,7,9} This child presented initially with infantile spasms. Later, seizure semiology changed and clinical evaluation led to the discovery of the new condition of moyamoya. This underscores the importance of a careful and continued evaluation, especially if there is an altered presentation, because there is always the possibility of a missed diagnosis influencing the clinical manifestation, even in patients with an apparently established diagnosis.

The second issue is the challenge faced in surgical treatment of these 2 conditions. There is abundant evidence supporting the role for surgical revascularization of both symptomatic and asymptomatic moyamoya in children with operations such as pial synangiosis.^{5–8} Regarding the MTS, the American Academy of Neurology practice parameter recommends surgery as the treatment of choice for medically intractable temporal lobe epilepsy.⁴ The patient’s seizures in this case were controlled with medication at the time of diagnosis of moyamoya, but the natural history of MTS suggests that a minority of children will continue to attain seizure control on medication alone, whereas nearly two-thirds of children can experience long-term seizure control after selective temporal lobectomy (as studied in a Class I randomized, controlled trial).^{1,3,4,10} If the child needed a temporal lobectomy at a point in time after surgical revascularization for his moyamoya, there would be increased risk of encountering scar tissue and, more importantly, potentially interrupting critical surgical collateral vessels. Given these data, and with documentation that typical seizures arose in the right temporal lobe, the decision was made to offer a selective temporal lobectomy at the same time as the pial synangiosis, as described in this report. The case highlights the need for careful intradisciplinary discussion and preoperative planning.

The combined approach was successful, but several risks were reviewed with the treating physicians and family. The extensive intraparenchymal dissection required for the selective lobectomy could have resulted in disruption of existing collateral vessels associated with the moyamoya, or it could have increased the risk of hemorrhage perioperatively, given the use of low-dose aspirin in the first few days after surgery. It was unclear if the greater extent of dissection and length of operating time would

increase the risk of perioperative stroke or seizure in the setting of the 2 conditions. Last, the additional communication of CSF spaces resulting from the fenestration of the arachnoid cyst, larger craniotomy, and dissection inherent to the lobectomy could potentially increase the risk of CSF leakage postoperatively.

Fortunately, the case was uncomplicated and the child was discharged after a 5-day hospital stay (including a preoperative admission for planned intravenous hydration). He has done well, with no further seizures and a 6-month postoperative MRI sequence revealing good collateral development and no new strokes, along with reversal of the previous ivy sign (indicating improved blood flow after pial synangiosis).

This case is unique because this is the first one to our knowledge in which moyamoya was found in association with MTS. It also elucidates the importance of surgical planning in similar situations with dual pathological processes. Although this case centers on epilepsy, this type of team-based strategy and anticipation of future patient surgical needs may be similarly relevant in the setting of other conditions, such as tumors, vascular lesions (arteriovenous malformation, aneurysm, and so on), or shunts. We recognize that this is not a technically novel case, but rather hope that its illustration may offer an example of a potential surgical strategy that has been used successfully in a patient with moyamoya and an associated colocalized surgical lesion.

Conclusions

This case demonstrates the coexistence of MTS and newly diagnosed moyamoya—with progression—in 1 patient. The finding of dual intracranial pathological processes in patients with moyamoya mandates careful consideration of potential future surgical needs, to properly anticipate treatment strategies. Resection of an intraparenchymal lesion can be performed successfully along with a pial synangiosis during a single induction of anesthesia when the surgical teams coordinate their approaches; such an example is demonstrated in this patient.

Disclosure

The authors report no conflict of interest concerning the materials or methods used in this study or the findings specified in this paper.

Author contributions to the study and manuscript preparation include the following. Conception and design: Smith. Acquisition of data: Lohani. Analysis and interpretation of data: Lohani. Drafting

the article: Lohani. Critically revising the article: all authors. Reviewed submitted version of manuscript: all authors. Approved the final version of the manuscript on behalf of all authors: Lohani. Administrative/technical/material support: Madsen, Smith. Study supervision: Smith.

References

1. Al-Holou WN, Yew AY, Boomsaad ZE, Garton HJL, Muraszko KM, Maher CO: Prevalence and natural history of arachnoid cysts in children. Clinical article. **J Neurosurg Pediatr** **5**:578–585, 2010
2. Cersósimo R, Flesler S, Bartuluchi M, Soprano AM, Pomata H, Caraballo R: Mesial temporal lobe epilepsy with hippocampal sclerosis: study of 42 children. **Seizure** **20**:131–137, 2011
3. Chern JJ, Patel AJ, Jea A, Curry DJ, Comair YG: Surgical outcome for focal cortical dysplasia: an analysis of recent surgical series. A review. **J Neurosurg Pediatr** **6**:452–458, 2010
4. Engel J Jr, Wiebe S, French J, Sperling M, Williamson P, Spencer D, et al: Practice parameter: temporal lobe and localized neocortical resections for epilepsy: report of the Quality Standards Subcommittee of the American Academy of Neurology, in association with the American Epilepsy Society and the American Association of Neurological Surgeons. **Neurology** **60**:538–547, 2003
5. Fung LW, Thompson D, Ganesan V: Revascularisation surgery for paediatric moyamoya: a review of the literature. **Childs Nerv Syst** **21**:358–364, 2005
6. Lin N, Baird L, Koss M, Kopecky KE, Gone E, Ullrich NJ, et al: Discovery of asymptomatic moyamoya arteriopathy in pediatric syndromic populations: radiographic and clinical progression. **Neurosurg Focus** **31**(6):E6, 2011
7. Scott RM, Smith ER: Moyamoya disease and moyamoya syndrome. **N Engl J Med** **360**:1226–1237, 2009
8. Scott RM, Smith JL, Robertson RL, Madsen JR, Soriano SG, Rockoff MA: Long-term outcome in children with moyamoya syndrome after cranial revascularization by pial synangiosis. **J Neurosurg** **100** (2 Suppl Pediatrics):142–149, 2004
9. Westermaier T, Schweitzer T, Ernestus RI: Arachnoid cysts. **Adv Exp Med Biol** **724**:37–50, 2012
10. Wieser HG: ILAE Commission Report. Mesial temporal lobe epilepsy with hippocampal sclerosis. **Epilepsia** **45**:695–714, 2004

Manuscript submitted August 27, 2012.

Accepted March 5, 2013.

Please include this information when citing this paper: published online April 5, 2013; DOI: 10.3171/2013.3.PEDS12437.

Address correspondence to: Subash Lohani, M.D., Department of Neurosurgery, Boston Children's Hospital, 300 Longwood Avenue, Hunnewell-2, Boston, Massachusetts 02115. email: subash.lohani@childrens.harvard.edu.