

# Posterior Fossa Syndrome After Cerebellar Stroke

Peter Mariën · Lieven Verslegers · Maarten Moens ·  
Guido Dua · Piet Herregods · Jo Verhoeven

© Springer Science+Business Media New York 2013

**Abstract** Posterior fossa syndrome (PFS) due to vascular etiology is rare in children and adults. To the best of our knowledge, PFS due to cerebellar stroke has only been reported in patients who also underwent surgical treatment of the underlying vascular cause. We report longitudinal clinical, neurocognitive and neuroradiological findings in a 71-year-old right-handed patient who developed PFS following a right cerebellar haemorrhage that was not

surgically evacuated. During follow-up, functional neuroimaging was conducted by means of quantified Tc-99m-ECD SPECT studies. After a 10-day period of akinetic mutism, the clinical picture developed into cerebellar cognitive affective syndrome (CCAS) with reversion to a previously learnt accent, consistent with neurogenic foreign accent syndrome (FAS). No psychometric evidence for dementia was found. Quantified Tc-99m-ECD SPECT studies consistently disclosed perfusional deficits in the anatomoclinically suspected but structurally intact bilateral prefrontal brain regions. Since no surgical treatment of the cerebellar haematoma was performed, this case report is presumably the first description of pure, “non-surgical vascular PFS”. In addition, reversion to a previously learnt accent which represents a subtype of FAS has never been reported after cerebellar damage. The combination of this unique constellation of poststroke neurobehavioural changes reflected on SPECT shows that the cerebellum is crucially implicated in the modulation of neurocognitive and affective processes. A decrease of excitatory impulses from the lesioned cerebellum to the structurally intact supratentorial network subserving cognitive, behavioural and affective processes constitutes the likely pathophysiological mechanism underlying PFS and CCAS in this patient.

---

Peter Mariën and Lieven Verslegers contributed equally to the manuscript.

P. Mariën · L. Verslegers  
Department of Neurology and Memory Clinic,  
ZNA Middelheim General Hospital, Antwerp, Belgium

G. Dua  
Department of Neurosurgery, ZNA Middelheim General Hospital,  
Antwerp, Belgium

P. Herregods  
Department of Neurorehabilitation, ZNA Middelheim General  
Hospital, Antwerp, Belgium

M. Moens  
Department of Neurosurgery, UZ Brussel, Brussels, Belgium

J. Verhoeven  
Department of Language and Communication Science,  
City University London, London, UK

P. Mariën  
Department of Clinical and Experimental Neurolinguistics,  
Vrije Universiteit Brussel, Brussels, Belgium

P. Mariën · J. Verhoeven  
VLAC (Vlaams Academisch Centrum); Advanced Studies  
Institute of the Royal Flemish Academy of Belgium for Sciences  
and the Arts, Brussels, Belgium

P. Mariën (✉)  
Department of Neurology and Memory Clinic,  
ZNA Middelheim, Lindendreef 1,  
B-2020, Antwerp, Belgium  
e-mail: peter.marien5@telenet.be

**Keywords** Posterior fossa syndrome · Cerebellar cognitive affective syndrome · Foreign accent syndrome · Stroke · SPECT · Cerebellum

## Introduction

Posterior fossa syndrome (PFS) is an aetiologically heterogeneous condition typically characterized by cerebellar mutism of variable duration and behavioural and affective disturbances. Post-mutism neurocognitive and neurobehavioural abnormalities closely resemble the cerebellar cognitive affective syndrome (CCAS), which consists of a cluster of

impairments in executive function, visuo-spatial cognition, linguistic processing and behavioural-affective regulation [1, 2]. PFS typically develops in children following PF tumour resection and, although this is documented in more than 350 cases, PFS has only rarely been described in adults: in children the incidence of the PFS after PF tumour resection is estimated to range between 8 % [3] and 31 % [4]. A detailed survey of the literature on cerebellar mutism in adults following PF surgery yielded reports on only 21 patients over the age of 18, published between 1969 and January 2011 [5]. Moreover, PFS due to vascular etiology is extremely rare and has only been described in four adult cases [6–9]. All patients underwent PF surgery for a vascular pathology and none of them became mute before surgery.

We report detailed clinical, neuropsychological and functional neuroimaging findings in an adult patient with PFS, CCAS and neurogenic foreign accent syndrome (FAS) [10] following an intracerebellar haemorrhage. In addition to the fact that only a handful of adult cases of vascular PFS have been reported, there have been no observations of vascular PFS in which no surgical treatment of the vascular pathology was performed. Moreover, only very few observations of FAS exist in which reversion to a previously learnt accent occurred after CNS damage (neurogenic FAS). None of these cases involved cerebellar damage although recent evidence suggests that the cerebellum is implicated in the pathophysiology of FAS [11, 12].

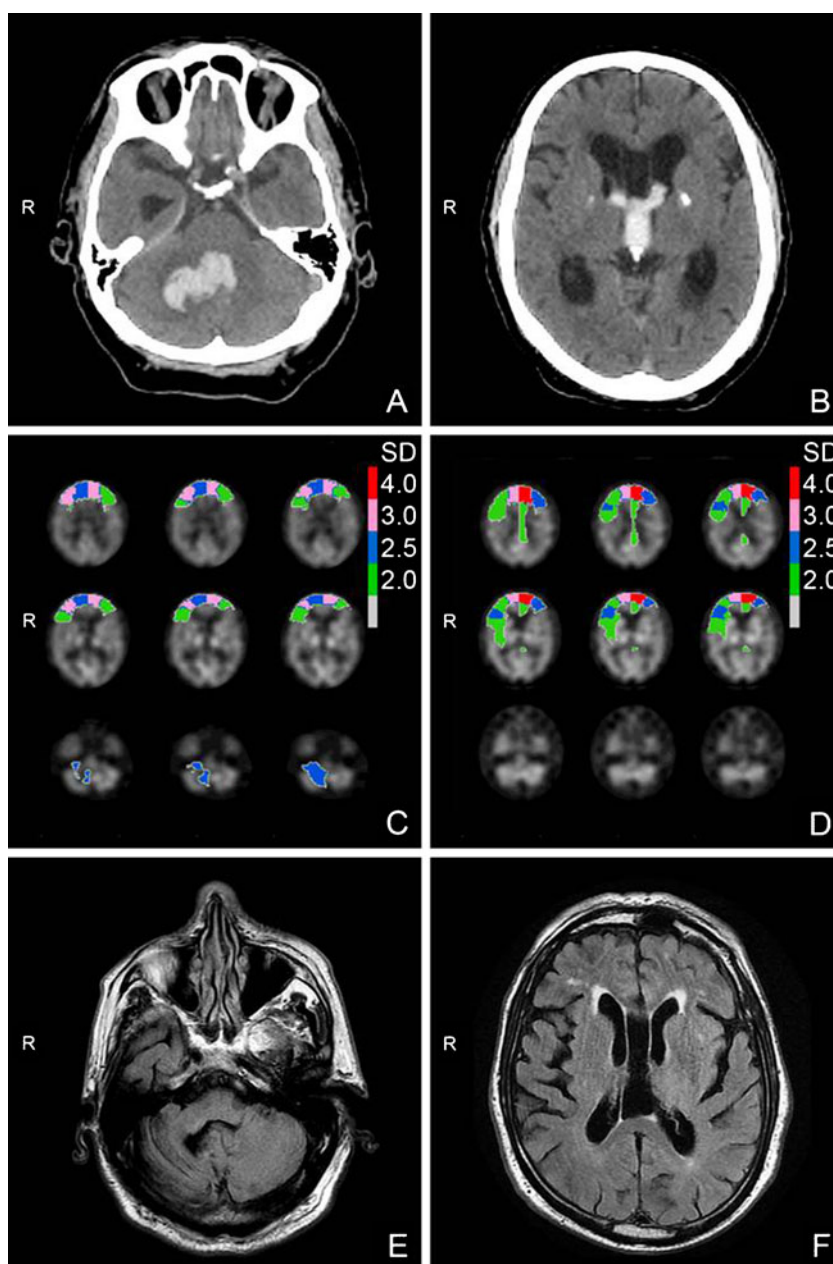
## Case History

A previously healthy 71-year-old right-handed man acutely developed headache, postural instability and gait disturbances. The patient was born and raised in Germany and emigrated to Flanders, Belgium at the age of 31. He had an educational level of 11 years. He married a Dutch-speaking woman and spoke Dutch most of the time. The neurological examination on admission showed a cerebellar deficit with distinct midline cerebellar dysfunction, right appendicular ataxia, right ataxic hemiparesis (Medical Research Council (MRC) scale for muscle strength: 3+/5) with involvement of the corticopontocerebellar pathway and ataxic dysarthria. A very slight German accent was observed in speech. CT of the brain disclosed a hemorrhagic lesion in the right cerebellar hemisphere extending into the third and fourth ventricle (Fig. 1a). Secondary hydrocephalus and bilateral calcifications in the globus pallidus were found as well (Fig. 1b).

As consciousness progressively decreased (Glasgow Coma Scale (GSC): 6/15) an external ventricular drain was surgically installed 2 days poststroke: this rapidly normalized consciousness (GCS 14/15) and ventricular volumes. However, after 1 week, the patient developed a state of akinetic mutism lasting for 10 days. Repeat CT disclosed

no new findings and as indicated by an Evan's index  $<0.3$ , no evidence was found for recurring hydrocephalus. When mutism resolved, speech was characterized by ataxic dysarthria and echolalia. In a 3.5-min bedside conversation 72.7 % (16/22) of the patient's answers consisted of echo-responses. The patient literally repeated 7 of the 22 questions asked by the examiner (immediate echo-answers: 31.8 %) and 9 of the 22 answers were mitigated echo-responses (40.9 %) in which the examiner's questions were grammatically adapted. In this conversation, the patient produced a total of 90 words: none of these words were German, but three Dutch words (3.33 %) were pronounced with a clear German accent. At the behavioural and affective level there was marked apathy and emotional blunting. After 1 month, spontaneous speech reappeared, echolalia diminished and apathy gradually resolved. As shown in Table 1, poststroke neurocognitive test results on general cognitive measures (Mini Mental State Examination) were abnormal [13]. Full-Scale Intelligence Quotient (IQ), as measured by the Wechsler Adult Intelligence Scale-III (WAIS-III) was within the pathological range (greater than  $-2SD$ ) [14]. No significant discrepancy was found between the deviant verbal ( $=69$ ) and performance ( $=66$ ) IQ. As demonstrated by the memory indices on the Repeatable Battery for the Assessment of Neuropsychological Status (RBANS) immediate and delayed memory were profoundly impaired [15]. The patient also obtained defective results on visuo-spatial and visuo-constructive tasks (RBANS; visuo-perceptual skills index). A depressed result was found for Raven's Coloured Progressive Matrices (CPM) indicating problems with regard to visuo-spatial problem solving and inductive reasoning [16]. Visual confrontation naming as tested by means of the Boston Naming Test scored well within the normal range [17]. A deficient score on a semantic verbal fluency task consisting of one minute generation of names of animals, means of transport, vegetables, and clothes (unpublished norms) indicated distorted language dynamics. As reflected by an attention index of 46 ( $-3.6 SD$ ) on the RBANS, sustained visuo-motor attention and auditory-verbal attention span were severely disrupted. Results on the Trial Making Test assessing attention, mental flexibility, visual search and sequencing were below percentile (pc) 10 [18]. A deviant score was found on the Stroop Colour-Word test indicated disruption of the ability to inhibit a competing and more automatic response set [19]. Frontal planning and conceptual organisation of goal-oriented cognitive strategies was distorted as well. The patient did not succeed to complete any category on the Wisconsin Card Sorting Test (WCST) within 128 trials (pc $<1$ ) [20]. A strong tendency to perseverate as well as impaired cognitive flexibility and self-monitoring was confirmed by a defective score on the Frontal Assessment Battery and the Meander [21, 22]. A defective score on the Middelheim Frontality

**Fig. 1** CT scan showing an acute right cerebellar haemorrhage, secondary hydrocephalus and bilateral calcifications in the globus pallidus (a–b). Quantified Tc-99m-ECD SPECT studies reveal a significant decrease and aggravation of perfusional deficits bilaterally distributed in the prefrontal brain regions during follow-up (c–d). MRI axial FLAIR slices 6 months poststroke show complete resorption of the cerebellar haemorrhage, atrophy of the right cerebellum (e) and restoration of the intraventricular volumes (f)



Scale confirmed frontal-like disinhibited behavioural abnormalities [23].

Repeat CT showed no changes but quantified Tc-99m-ECD SPECT revealed perfusional deficits bilaterally distributed in the medial (right  $-2.67$  SD; left  $-3.37$  SD) and lateral (right  $-3.27$  SD; left  $-2.22$  SD) prefrontal regions, the right inferior frontal region ( $-2.38$  SD) and the right cerebellar hemisphere ( $-2.63$  SD) (Fig. 1c). During the course of remission of apathetic syndrome, reversion to a previously learnt German accent and abusive and foul language became increasingly outspoken, as well as sexual disinhibition, hypersexuality, verbal and physical aggression which required neuroleptic treatment. Analysis of a 2-min video-taped sample of conversational speech revealed

that 8 of the 24 sentences (33.3 %) produced by the patient were echo-answers (4 immediate, 4 mitigated echo-answers). However, in sharp contrast to prior findings, speech production was marked by the use of foreign words and a foreign accent (German). Indeed, 39 out of the 146 (26.7 %) words produced by the patient were German and 24 (16.4 %) Dutch words were pronounced with a clear German accent. Repeat neuropsychological assessments at 6 months poststroke confirmed aggravation of executive and behavioural dysfunctions as reflected by a decrease of test results on verbal fluency tasks, WCST, Stroop, Meander, TMT, MFS and FAB. By contrast, no psychometric evidence was found in favour of a further general cognitive

**Table 1** Neurocognitive test results 1 and 6 months poststroke

Neurocognitive tests	1 month poststroke (SS) SD	6 months poststroke (SS) SD	Mean	±1SD
Mini mental state examination	22/30	21/30	29	1.67
Full-Scale Intelligence Quotient (FSIQ)	(62) -2.5	(70) -2.0	(100)	15.0
Verbal IQ (VIQ)	(69) -2.0	(72) -1.9	(100)	15.0
Information	(6) -1.3	(7) -1.0	(10)	3.0
Comprehension	(3) -2.3	(4) -2.0	(10)	3.0
Digit Span	(6) -1.3	(5) -1.6	(10)	3.0
Arithmetics	(4) -2.0	(4) -2.0	(10)	3.0
Similarities	(6) -1.3	(7) -1.0	(10)	3.0
Vocabulary	(6) -1.3	(7) -1.0	(10)	3.0
Performance IQ (PIQ)	(66) -2.3	(71) -1.9	(100)	15.0
Digit Symbol Substitution	(/)	(/)	(10)	3.0
Picture Completion	(5) -1.6	(7) -1.0	(10)	3.0
Block Design	(5) -1.6	(5) -1.6	(10)	3.0
Picture Arrangement	(6) -1.3	(5) -1.6	(10)	3.0
Symbol Search	(4) -2.0	(7) -1.0	(10)	3.0
Matrix Reasoning	(6) -1.3	(6) -1.3	(10)	3.0
Raven Matrices	(75) -1.6		(100)	15.0
<b>RBANS</b>				
Immediate memory index	(57) -2.9	(58) -2.8	(100)	15.0
Visuo-perceptual skills index	(64) -2.4	(66) -2.3	(100)	15.0
Language index	(57) -2.9	(45) -3.6	(100)	15.0
Attention index	(46) -3.6	(49) -3.4	(100)	15.0
Delayed memory index	(56) -2.9	(60) -2.6	(100)	15.0
Boston Naming Test	48/60 -0.6	49/60 -0.4	51.6	5.87
<b>Verbal fluency</b>				
Semantic categories: total	21 -2.9	9 -3.8	13.27	59.7
Animals, 1 minute	7	4		
Transportation, 1 minute	6	3		
Vegetables, 1 minute	3	0		
Clothing, 1 minute	5	2		
Number of perseverations	6	5		
<b>Wisconsin Card Sorting</b>				
Number of categories completed	0/128 (pc<1)	0/128 (pc<1)		
<b>Stroop Colour-Word Test</b>				
Card I	147" (pc<1)	181" (pc<1)		
Card II	250" (pc<1)	263" (pc<1)		
Card III	320" (pc<1)	interrupted		
Meander	Interrupted; Perseverations	Interrupted; Perseverations		
<b>Trail Making Test</b>				
A	205" (pc<10)	229" (pc<10)	80"	
B	473" (pc<10)	508" (pc<10)	196"	
Middelheim Frontality Scale	6	8	<5	
Frontal Assessment Battery	13/18	17/18	<13	

SS standard score; *Pc* percentile; *SD* standard deviation; *RBANS* Repeatable Battery for the Assessment of Neuropsychological Status

decline as indicated by the WAIS-III and RBANS (Table 1). Repeat Tc-99m-ECD SPECT disclosed significant aggravation

(>1.5 SD) of perfusional deficits in the left medial prefrontal lobe (-5.42 SD), left inferior lateral frontal region (-1.86) and

right motor cortex ( $-2.06$  SD). In addition, perfusional deficits were observed in both cingulate gyri (right  $-1.84$  SD; left  $-2.14$  SD) (Fig. 1d).

After 6 months, the patient was transferred to a specialized neurorehabilitation center but little progression was made: apart from partial recovery of the right hemiparesis (MRC-scale 4+/5) the neurobehavioural and neurocognitive status remained unchanged. MRI of the brain showed reabsorption of the cerebellar haemorrhage with atrophy of the right cerebellum and near restoration of the ventricular volumes (Fig. 1e-f).

## Discussion

After a right cerebellar haemorrhage this Dutch-speaking patient of German descent presented with PFS followed by CCAS and neurogenic FAS. Only four adult stroke patients have been reported with PFS and all of them developed the condition after PF surgery to treat the vascular pathology [6–9]. Since no surgical treatment of the right cerebellar haematoma was performed, this patient seems to be the first stroke patient in whom PFS was not induced by surgical damage. In addition, there have been no reports of patients in whom CCAS coincides with reversion to a previously learnt accent. Furthermore, no patients have been reported in the FAS literature in whom accent reversion was associated with a cerebellar lesion. Because of obstructive hydrocephalus, external drainage was performed two days after onset of the stroke. Since this treatment resulted in a rapid normalization of consciousness and a CT Evan's index  $<0.3$ , the hydrocephalus can be considered as a transient phenomenon without major repercussions on the subsequent clinical and cognitive tableau. Quantified Tc-99m-ECD SPECT follow-up findings identified a consistent pattern of perfusional deficits in the anatomoclinically suspected but structurally intact supratentorial brain regions. Indeed, following remission of post-mutism apathy and echolalia at one month poststroke the development of CCAS was reflected on SPECT by the phenomenon of cerebello-cerebral diaschisis consisting of bilateral perfusional deficits in the medial and lateral prefrontal regions, the right inferior frontal region and the right cerebellum. Clinical evolution from inhibition behaviour to a constellation of disinhibited behavioural and affective symptoms was not only accompanied by a significant aggravation of perfusional deficits in the left medial prefrontal lobe and left inferior lateral frontal region but also by extension of the pattern of perfusional deficits to the right motor cortex and both cingulate gyri. From a pathophysiological point of view, dysregulation of cingulate cortex activity might account for the disruption of the capacity for self-regulatory

control in this patient. Consistent with the anatomoclinical findings in this patient, a number of functional neuroimaging studies has shown that (dis)inhibition behaviour - among which disruption of language dynamics such as mutism and echolalia - not only results from basal ganglia and frontal cortex dysregulation but may also follow alterations in cingulate cortex function [24–26]. In this respect, studies have also shown that suppression of disinhibition behaviour is associated with decreased cingulate cortex activity [27]. Since the prefrontal cortex seems to physiologically regulate cingulate cortex activity within the frontostriatal network it might be hypothesized that in our patient the loss of prefrontal control over cingulate cortex function induced disruption of the capacity for self-regulatory control leading to disinhibited behaviour.

During the past years, the hypothesis of bilateral crossed cerebello-cerebral diaschisis, reflecting the functional impact of cerebellar damage on distant cortical areas has attracted increased attention to explain cognitive and affective disturbances following PF lesions [26, 28]. Our findings confirm that in adult patients vascular damage to the cerebellum may induce remote functional disturbances at the supratentorial level causing PFS, CCAS and neurogenic FAS. Disruption of transmission of excitatory impulses from the lesioned cerebellum to the contralateral prefrontal supratentorial regions indicates that the dentato-rubro-thalamic tract is crucially implicated in the neuronal network subserving cognitive, affective and behavioural processes. Given these crosswise anatomical connections, a bilateral distribution of perfusional deficits at the supratentorial level in this patient is rather unexpected since the left cerebellar hemisphere was structurally unaffected. However, bilateral perfusional deficits following unilateral cerebellar lesions may be related to the phenomenon of 'transcallosal' or 'transhemispheric diaschisis', which is reflected by a hypoperfusion in the cerebral hemisphere opposite to the functionally disrupted region [29, 30]. Possible mechanisms of transcallosal diaschisis include disrupted input from the afferent fibre pathways [31], depressed excitatory transcallosal connection fibres [32], or transcallosal fibre degeneration [33].

The combination of this unique constellation of poststroke neurobehavioural changes reflected on SPECT by bilateral cerebello-cerebral diaschisis provides convergent evidence that a decrease of excitatory impulses from the lesioned cerebellum to the structurally intact supratentorial regions subserving cognitive, behavioural and affective processes constitutes the likely pathophysiological mechanism of PFS and CCAS. In addition, the present case shows that neurogenic FAS and echolalia may result from distant suppression of frontal lobe function.

**Acknowledgements** The authors wish to thank Mrs Inge Bats for preparing the figure and Mrs Ellen Wouters for the editorial assistance.

**Conflict of Interest** The authors of the manuscript Peter Mariën, Lieven Verslegers, Maarten Moens, Guido Dua, Piet Herregods, and Jo Verhoeven explicitly disclose no conflicts of interests.

## References

- Schmahmann JD, Sherman JC. The cerebellar cognitive–affective syndrome. *Brain*. 1998;121:561–79.
- Schmahmann JD. Disorders of the cerebellum: ataxia, dysmetria of thought, and the cognitive affective syndrome. *J Neuropsychiatry Clin Neurosci*. 2004;16:367–78.
- Pollack IF, Polinko P, Albright AL, Towbin R, Fitz C. Mutism and pseudobulbar symptoms after resection of posterior fossa tumors in children: incidence and pathophysiology. *Neurosurgery*. 1995;37:885–93.
- Catsman-Berrevoets CE, Aarsen FK. The spectrum of neurobehavioural deficits in the posterior fossa syndrome in children after cerebellar tumour surgery. *Cortex*. 2010;46:933–46.
- Mariën P, De Smet HJ, Wijgerde E, Verhoeven J, Crols R, De Deyn PP. The posterior fossa syndrome in adults: a new case and comprehensive survey of the literature. *Cortex*. 2013;49:284–300.
- Dunwoody GW, Alsagoff ZS, Yuan SY. Cerebellar mutism with subsequent dysarthria in an adult: case report. *Br J Neurosurg*. 1997;11:161–3.
- Coplin WM, Kim DK, Kliot M, Bird TD. Mutism in an adult following hypertensive cerebellar hemorrhage: nosological discussion and illustrative case. *Brain Lang*. 1997;59:473–93.
- Idiaquez J, Fadic R, Mathias CJ. Transient orthostatic hypertension after partial cerebellar resection. *Clin Auton Res*. 2011;21:57–9.
- De Smet HJ, Mariën P. Posterior fossa syndrome in an adult patient following surgical evacuation of an intracerebellar haematoma. *Cerebellum*. 2012;11:587–92.
- Verhoeven J, Mariën P. Neurogenic foreign accent syndrome: articulatory setting, segments and prosody in a Dutch speaker. *J Neurolinguistics*. 2011;23:599–614.
- Mariën P, Verhoeven J, Engelborghs S, Rooker S, Pickut BA, De Deyn PP. A role for the cerebellum in motor speech planning: evidence from foreign accent syndrome. *Clin Neurol Neurosurg*. 2006;108:518–22.
- Cohen DA, Kurowski K, Steven MS, Blumstein SE, Pascual-Leone A. Paradoxical facilitation: the resolution of foreign accent syndrome after cerebellar stroke. *Neurology*. 2009;73:566–7.
- Folstein MF, Folstein SE, McHugh PR. Mini-mental state: a practical method for grading the cognitive state of patients for the clinician. *J Psychiatr Res*. 1975;12:189–98.
- Wechsler D. Wechsler Adult Intelligence Scale—III (WAIS-III). London: The Psychological Corporation; 1997.
- Randolph C. Repeatable Battery for the Assessment of Neuropsychological Status (RBANS). San Antonio: Psychological Corporation; 1998.
- Raven JC. Progressive Matrices: a perceptual test of intelligence. London: Lewis; 1938.
- Mariën P, Mampaey E, Vervaeke A, Saerens J, De Deyn PP. Normative data for the Boston Naming Test in native Dutch speaking elderly. *Brain Lang*. 1998;65:447–67.
- Reitan RM. Validity of the trail making test as an indicator of organic brain damage. *Percept Mot Skills*. 1958;8:271–6.
- Golden CJ. Stroop Color and Word Test: a manual for clinical and experimental uses. Chicago: Stoelting; 1978.
- Heaton RK, Chelune GJ, Talley JL, Kay GG, Curtiss G. Wisconsin Card Sorting Test: revised and expanded. Lutz: Psychological Assessment Resources; 1993.
- Dubois B, Slachevsky A, Litvan I, Pillon B. The FAB: a frontal assessment battery at bedside. *Neurology*. 2000;55:1621–6.
- Luria AR. Human brain and psychological processes. New York: Harper & Row; 1966.
- De Deyn PP, Engelborghs S, Saerens J, Goeman J, Mariën P, Maertens K, et al. The Middelheim Frontality Score: a behavioural assessment scale that discriminates frontotemporal dementia from Alzheimer’s disease. *Int J Geriatr Psychiatry*. 2005;20:70–9.
- Bohlhalter S, Goldfine A, Matteson S, Garraux G, Hanakawa T, Kansaku K, et al. Neural correlates of tic generation in Tourette syndrome: an event-related functional MRI study. *Brain*. 2006;129:2029–37.
- Müller-Vahl KR, Kaufmann J, Grosskreutz J, Dengler R, Emrich HM, Peschel T. Prefrontal and anterior cingulate cortex abnormalities in Tourette syndrome: evidence from voxel-based morphometry and magnetization transfer imaging. *BMC Neurosci*. 2009;10:47. doi:10.1186/1471-2202-10-47.
- Mariën P, Engelborghs S, Fabbro F, De Deyn PP. The lateralized linguistic cerebellum: a review and new hypothesis. *Brain Lang*. 2001;79:580–600.
- Eidelberg D, Moeller JR, Antonini A, Kazumata K, Dhawan V, Budman C, et al. The metabolic anatomy of Tourette’s syndrome. *Neurology*. 1997;48:927–34.
- Miller NG, Reddick WE, Kocak M, Glass JO, Löbel U, Morris B, et al. Cerebellocerebral diaschisis is the likely mechanism of post-surgical posterior fossa syndrome in pediatric patients with midline cerebellar tumors. *AJNR Am J Neuroradiol*. 2010;31:288–94.
- Lagrèze HL, Levine RL, Pedula KL, Nickles RJ, Sunderland JS, Rowe BR. Contralateral flow reduction in unilateral stroke: evidence for transhemispheric diaschisis. *Stroke*. 1987;18:882–6.
- Andrews RJ. Transhemispheric diaschisis: a review and comment. *Stroke*. 1991;22:943–9.
- Lane R, Krikbride V, Hughes P, Jones B, Costa D. Diagnosis of herpes simplex encephalitis by single photon emission tomography. *Lancet*. 1989;1:778–9.
- Conti F, Manzoni T. The neurotransmitters and postsynaptic actions of callosally projecting neurons. *Behav Brain Res*. 1994;64:37–53.
- Iglesias S, Marchal G, Rioux P, Beaudouin V, Hauttement AJ, de la Sayette V, et al. Do changes in oxygen metabolism in the unaffected cerebral hemisphere underlie early neurological recovery after stroke? A positron emission tomography study. *Stroke*. 1996;27:1192–9.