

CASE REPORT

Isolated thalamic tuberculoma presenting as ataxic hemiparesis

Ritesh Sahu, Tushar B Patil, Prakash Kori, Rakesh Shukla

Department of Neurology,
King George's Medical
University, Lucknow,
Uttar Pradesh, India

Correspondence to
Professor Rakesh Shukla,
rakeshshukla_rakesh@
rediffmail.com

SUMMARY

Lacunar syndrome is a neurodeficit secondary to a deep cerebral lesion, usually because of microatheroma of small arteries. Ataxic hemiparesis (AH) is a lacunar syndrome with unilateral pyramidal weakness and ipsilateral ataxia. Thalamic tuberculoma, as a cause of AH, has not been previously described in the literature. We describe an elderly man who presented with left hemiparesis and ipsilateral ataxia. Clinical examination revealed upper motor neuron left facial paresis and left-sided hemiparesis. The patient had incoordination in left upper and lower limbs. Mantoux test was positive and erythrocyte sedimentation rate was elevated. MRI of brain showed a conglomerated hypointense lesion in the right thalamus with a peripheral hyperintensity on T1-weighted imaging and a hyperintense lesion in T2-weighted imaging with significant perilesional oedema, suggesting a tuberculoma. The patient was treated with antitubercular therapy and was symptomatically better at the 9 months follow-up.

BACKGROUND

Lacunar syndrome is a neurodeficit secondary to a deep cerebral lesion, and now established to be caused by cerebral ischaemia because of microatheroma of deep penetrating arterial branches.¹ Ataxic hemiparesis (AH) is a lacunar syndrome comprising unilateral pyramidal weakness with ipsilateral ataxia. Pontine, capsular, thalamocapsular and striatocapsular lesions have been demonstrated in patients with ataxic hemiparesis.² Lacunar syndrome, not because of lacunar infarction, has been found to occur in 16.6% patients, with the other causes being haemorrhage, cardioembolism, multiple sclerosis or a tumour.³ However, AH because of a thalamic tuberculoma is very unusual. We report an immunocompetent patient with AH secondary to a thalamic tuberculoma.

CASE PRESENTATION

A 65-year-old non-smoker, non-alcoholic man was admitted to the neurology ward complaining of weakness in the left half of the body and deviation of the angle of his mouth towards the right with slurring of the speech for last 7 days. The weakness was acute at onset. The caregivers of patient also noticed clumsiness and incoordination of movements with the right hand and swaying towards the right while walking. On further enquiry, he complained of fever, decreased appetite and loss of weight in the previous 1 month, but did not have any history of cough or haemoptysis. There was no history of sensory complaints, diminution of vision,

vertigo, convulsions, chest pain or palpitations. He had no history of hypertension, heart disease or diabetes mellitus. There was no history of stroke, hypertension or ischaemic heart disease in his family.

Clinical examination revealed a conscious, oriented but restless elderly man with intact higher mental functions. He was afebrile with a heart rate of 76 bpm, blood pressure 126/84 mm Hg and respiratory rate of 22/min. All peripheral pulses were well palpable and there was no carotid bruit. Cardiac and bilateral lung field auscultation did not reveal any abnormality. He had upper motor neuron left facial paresis. Other cranial nerves were found to be normal upon clinical testing. After motor testing, he was found to have Medical Research Council (MRC) grade 3/5 power in left upper and lower limbs and normal power in right upper and lower limbs. His deep tendon reflexes were hyperactive and plantar response was extensor on the left side. The patient had incoordination in the left upper and lower limbs demonstrated by a positive finger–nose and knee–heel–shin test. Tremor was also present both in the distal and proximal regions in the left upper limb indicating the involvement of cerebellar fibres. Dysmetria and dysdiadokinesia were present on the left side suggesting definite ataxia out of proportion to the degree of pyramidal weakness. Sensory examination including proprioception was completely normal and autonomic examination was within normal limits.

INVESTIGATIONS

This patient presented to us with hemiparesis and ipsilateral cerebellar signs. This presentation was consistent with AH secondary to a lacunar stroke. Investigations were started on the lines of a presumed lacunar stroke. The patient's haemoglobin, total and differential leucocyte counts, fasting and postprandial blood sugar, lipid profile, kidney and liver function tests were within the normal limits. Chest x-ray did not reveal any abnormality. Considering a 1-month history of fever and weight loss, Mantoux test was done which showed an induration of 18 mm, erythrocyte sedimentation rate (ESR) was 46 mm at the end of 1 h. MRI of brain with contrast was requested which showed conglomerated hypointense lesion in the right thalamus with peripheral hyperintensity on T1-weighted imaging and hyperintense lesion in T2-weighted imaging with significant perilesional oedema (figure 1A–D). MR spectroscopy revealed increased lipid peak and decreased N-acetyl

To cite: Sahu R, Patil TB, Kori P, et al. *BMJ Case Rep* Published online: [please include Day Month Year] doi:10.1136/bcr-2013-009100

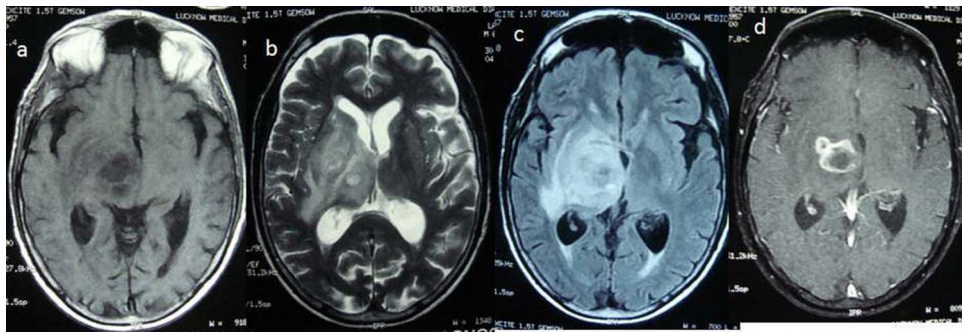


Figure 1 (A–D) MRI of brain showing conglomerated lesion in right thalamus which was hypointense on T1-weighted image (A), and hyperintense with significant perilesional oedema in T2-weighted (B) and flair (C) image. Ring enhancement seen in contrast image (D).

aspartate (NAA) peak. MR angiography was normal. Thus diagnosis of thalamic tuberculoma was made on the basis of these imaging features and corroborative evidence in the form of positive Mantoux test and raised ESR.

TREATMENT

The patient was started on antitubercular treatment with isoniazid (5 mg/kg/day), rifampin (10 mg/kg/day), pyrazinamide (25 mg/kg/day) and ethambutol (20 mg/kg/day) for 2 months followed by isoniazid and rifampin for 7 months. Dexamethasone (4 mg intravenous 6 hourly) was administered for first two 2 weeks followed by oral prednisolone in tapering doses for next 4 weeks. The patient was also given physiotherapy for rehabilitation.

OUTCOME AND FOLLOW-UP

After 9 months of therapy, the patient had significant improvement in power and ataxic symptoms. He was able to walk without support and perform activities of daily living independently. No side-effects of antitubercular therapy were seen. A repeat MRI brain scan was performed at 9 months which showed a marked reduction in the size of the right thalamic tuberculoma, along with complete resolution of perilesional oedema (figure 2A–D).

DISCUSSION

On the basis of pathological studies, Fisher has defined lacunae as small deep cerebral infarct resulting from occlusion of intracranial penetrating arterioles, caused by hypertension.^{4 5} Various lacunar syndromes include pure motor hemiparesis, pure sensory stroke, sensorimotor stroke, ataxic hemiparesis and dysarthria-clumsy hand syndrome. Further studies have shown

that lacunar syndrome can occur because of embolism from the heart⁶ or carotid artery occlusion.⁷ Arboix *et al* found that 16.6% of lacunar syndromes do not occur because of lacunar infarction. They observed that these cases are attributable to spontaneous subdural haematoma, primary intracerebral haemorrhage, atherothrombotic infarction and cardioembolic infarction.³ Anzalone *et al* observed that non-ischaemic causes like primary intracerebral haemorrhage, ruptured mycotic aneurysm, multiple sclerosis, cerebral abscess, subdural haematoma and glioblastoma also contribute to lacunar syndrome.⁸

AH is a lacunar syndrome involving homolateral ataxia with corticospinal tract impairment. AH accounts for about 10% lacunar syndromes.⁹ It was first described by Fisher and Cole, and was thought to be because of cerebrovascular lesion in the posterior-superior part of the internal capsule. In several subsequent reports, however, lesions have been found in the upper pons, posterior limb of the internal capsule, corona radiata, midbrain and parietal lobe.⁹ Later on, a few cases were reported to be caused by a thalamic lesion.^{10 11} Most of the reported cases were accompanied by sensory disturbances. However, in our case despite a large lesion, sensory examination was normal. To the best of our knowledge, AH because of a thalamic tuberculoma has not been previously described.

Dentatorubrothalamic tract carries fibres from contralateral cerebellum, is located in ventrolateral nucleus of thalamus. Cerebellar signs in this case may be because of involvement of dentatorubrothalamic tract or interruption of the corticopontocerebellar fibres located in the posterior limb of internal capsule. Perilesional oedema compressing over posterior limb of internal capsule is probably responsible for hemiparesis. Absence of sensory disturbance may be because of sparing of ventral posteromedial and posterolateral nuclei.

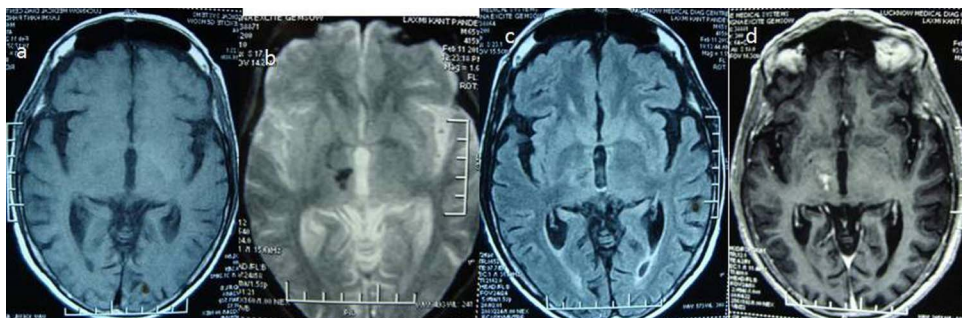


Figure 2 (A–D) Follow-up MRI of brain after 9 months depicting significant decrease in the size of the right thalamic lesion with resolution of perilesional oedema. Gradient recoil echo image (B) showing calcification and small enhancement in contrast image (D).

Learning points

- ▶ Non-vascular aetiology should also be considered in a patient presenting with lacunar syndrome.
- ▶ Tuberculoma is a potentially treatable cause of a focal lesion mimicking a lacunar stroke.
- ▶ MRI brain is the best modality for investigation in a patient with lacunar syndrome.

Competing interests None.

Patient consent Obtained.

Provenance and peer review Not commissioned; externally peer reviewed.

REFERENCES

- 1 Adria Arboix J, Martí-Vilalta L. New concepts in lacunar stroke etiology: the constellation of small-vessel arterial disease. *Cerebrovasc Dis* 2004;17:58–62.
- 2 Gorman MJ, Dafer R, Levine SR. Ataxic hemiparesis: critical appraisal of a lacunar syndrome. *Stroke* 1998;29:2549–55.
- 3 Arboix A, Massons J, García-Eroles L, et al. Clinical predictors of lacunar syndrome not due to lacunar infarction. *BMC Neurol* 2010;10:31.
- 4 Fisher CM. Lacunes: small deep cerebral infarcts. *Neurology* 1965;15:775–84.
- 5 Fisher CM. Capsular infarcts: the underlying vascular lesions. *Arch Neurol* 1979;36:65–73.
- 6 Santamaria J, Graus F, Rubio F, et al. Cerebral infarction of the basal ganglia due to embolism from the heart. *Stroke* 1983;14:911–14.
- 7 Aleksic SN, George AE. Pure motor hemiplegia with occlusion of the extracranial carotid artery. *J Neurol Sci* 1973;19:331–9.
- 8 Anzalone N, Landi G. Non ischaemic causes of lacunar syndromes: prevalence and clinical findings. *J Neurol Neurosurg Psychiatry* 1989;52:1188–90.
- 9 Moulin T, Bogousslavsky J, Chopard JL, et al. Vascular ataxic hemiparesis: a re-evaluation. *J Neurol Neurosurg Psychiatry* 1995;58:422–7.
- 10 Emori T, Kuriyama Y, Imakita S, et al. Ataxic hemiparesis following thalamic lacunar infarction. *Intern Med* 1992;31:889–92.
- 11 Boiten J, Lodder J. Ataxic hemiparesis following thalamic infarction. *Stroke* 1990;2:339–40.

Copyright 2013 BMJ Publishing Group. All rights reserved. For permission to reuse any of this content visit <http://group.bmj.com/group/rights-licensing/permissions>.

BMJ Case Report Fellows may re-use this article for personal use and teaching without any further permission.

Become a Fellow of BMJ Case Reports today and you can:

- ▶ Submit as many cases as you like
- ▶ Enjoy fast sympathetic peer review and rapid publication of accepted articles
- ▶ Access all the published articles
- ▶ Re-use any of the published material for personal use and teaching without further permission

For information on Institutional Fellowships contact consortiasales@bmjgroup.com

Visit casereports.bmj.com for more articles like this and to become a Fellow