

Journal of Child Neurology

<http://jcn.sagepub.com/>

Association Between Infantile Spasms and Nonaccidental Head Injury

Ala Birca, Guy D'Anjou and Lionel Carmant
J Child Neurol published online 11 April 2013
DOI: 10.1177/0883073813483901

The online version of this article can be found at:
<http://jcn.sagepub.com/content/early/2013/04/10/0883073813483901>

Published by:



<http://www.sagepublications.com>

Additional services and information for *Journal of Child Neurology* can be found at:

Email Alerts: <http://jcn.sagepub.com/cgi/alerts>

Subscriptions: <http://jcn.sagepub.com/subscriptions>


Reprints: <http://www.sagepub.com/journalsReprints.nav>

Permissions: <http://www.sagepub.com/journalsPermissions.nav>

>> [OnlineFirst Version of Record](#) - Apr 11, 2013

[What is This?](#)

Association Between Infantile Spasms and Nonaccidental Head Injury

Journal of Child Neurology
00(0) 1-3
© The Author(s) 2013
Reprints and permission:
sagepub.com/journalsPermissions.nav
DOI: 10.1177/0883073813483901
jcn.sagepub.com


Ala Birca, MD, PhD¹, Guy D'Anjou, MD¹, and
Lionel Carmant, MD¹

Abstract

Infantile spasms constitute a severe epileptic encephalopathy of infancy with poor long-term developmental outcome. Many diverse etiologies have been associated with infantile spasms, but the pathophysiological process is still not fully understood. We describe 2 cases of previously healthy 1- and 3-month-old infants who suffered a nonaccidental head injury with extensive cerebral lesions. Both presented with acute focal seizures rapidly controlled with phenobarbital. Nevertheless, they developed infantile spasms after a latency period of 3-4 months. Spasms were rapidly controlled with vigabatrin. Both children manifested with developmental delay, either exacerbated (case 1) or elicited (case 2) by infantile spasms. Our report highlights nonaccidental head injury as a risk factor for developing infantile spasms following a seizure-free latency period. A better understanding of the pathophysiology linking accidental brain trauma with infantile spasms could lead to more effective neuroprotective strategies. In the meantime, increased awareness and follow-up are warranted.

Keywords

infantile spasms, pathophysiology, epilepsy, nonaccidental head injury, West syndrome

Received February 21, 2013. Received revised March 2, 2013. Accepted for publication March 3, 2013.

Infantile spasms constitute a severe epileptic encephalopathy of infancy with poor long-term developmental outcome. The pathophysiology of infantile spasms is still not fully understood. A variety of underlying pathologies and risk factors have been associated with infantile spasms,¹ although all these patients manifest with similar clinical seizures and electroencephalographic patterns. Although animal models have improved our understanding, they have not yet been able to adequately reproduce certain aspects of the disorder.^{2,3} A study of infants with acquired brain injuries and infantile spasms that are well characterized may therefore provide further insights into the pathophysiological processes involved and lead to the development of new models to study the disorder. In this report, we describe 2 cases of previously normal infants who presented with nonaccidental head injury and, after several seizure-free months, developed infantile spasms and associated developmental delay. We further highlight nonaccidental head injury as a risk factor for infantile spasms development, increasing the need for neurological and cognitive follow-up.

at the emergency department with an altered level of consciousness, multifocal seizures, and bilateral retinal hemorrhages. The electroencephalogram (EEG) showed multifocal ictal discharges. Brain imaging demonstrated multiple subdural hematomas, small areas of parenchymal contusions, and a subarachnoid hemorrhage (Figure 1). The skeletal survey and infectious and metabolic work-up were negative. A diagnosis of nonaccidental head injury was established based on clinical and imaging findings. Phenobarbital was started to control the seizures. Repeat brain magnetic resonance imaging (MRI) on day 8 showed ventriculomegaly and diffuse brain atrophy more pronounced over the parieto-occipital regions. After 1 month with no seizure recurrence, drug therapy was discontinued. At 5 months, the child was mildly developmentally delayed. A severe head circumference growth deceleration was noted, passing from the 50th percentile (40 cm) on initial admission at 3 months of age to the 15th percentile (41 cm) 2 months later. On the contrary, body growth (weight and height) continued to

Case Reports

Case 1

A previously normal baby boy 3 months of age, who was the product of an uncomplicated pregnancy and delivery, arrived

¹Department of Neurology, Sainte Justine Hospital (CHU Sainte-Justine), University of Montreal, Montreal, Quebec, Canada

Corresponding Author:

Lionel Carmant, Sainte Justine Hospital Research Center, University of Montreal, 3175 Côte Sainte-Catherine, Montreal, QC, H3T 1C5, Canada.
Email: lionel.carmant@umontreal.ca

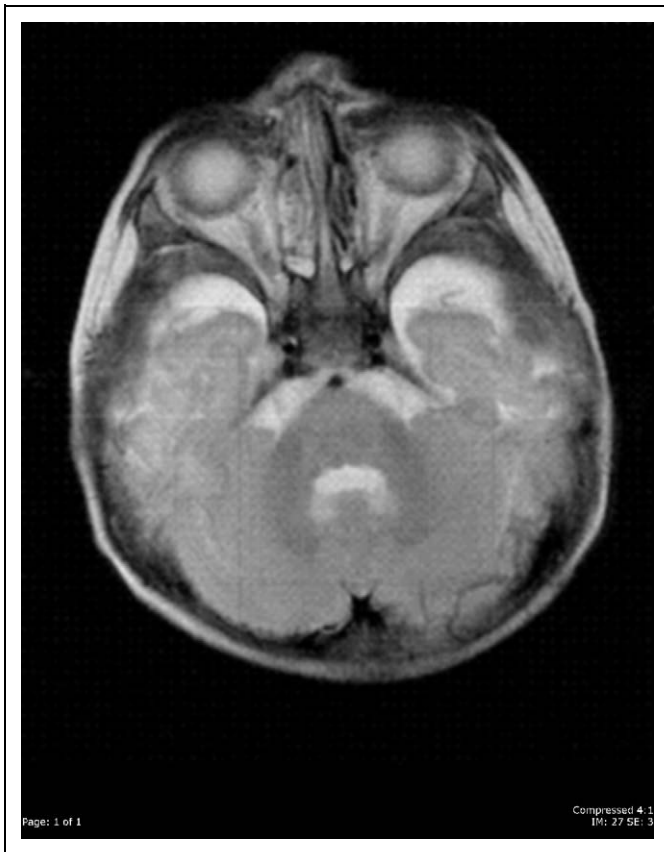


Figure 1. Case 1. Axial T2-weighted magnetic resonance imaging on day 3 of admission to the emergency department. Image shows subacute subdural hematomas at the level of posterior fossa and temporal poles.

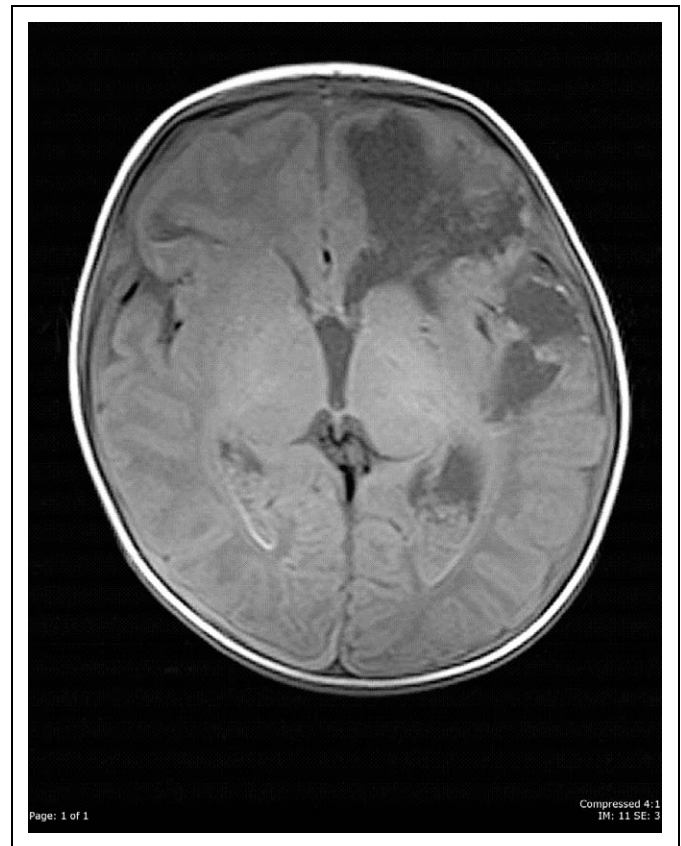


Figure 2. Case 2. Axial T1-weighted magnetic resonance imaging on day 2 of admission to the emergency department. Image shows pan-hemispheric bilateral subdural hematomas and extensive encephaloclastic lesions at the level of the frontal and temporal regions.

follow the 50th percentile. Routine EEG showed no epileptic discharges.

Infantile spasms were first observed at the age of 6 months. Within 2 weeks of their onset, the child lost all previous interest in environmental stimuli, which led to medical attention. EEG confirmed the presence of hypsarrhythmia. Vigabatrin was able to arrest the spasms within 3 days of treatment. Control EEG 2 weeks later showed persistent interictal discharges but no hypsarrhythmia. Currently at the age of 5 years, the child remains microcephalic (45.5 cm, far below the 2nd percentile), with body growth roughly following the 15th-25th percentiles, but now with severe developmental delay, poor eye contact, and mild spasticity. He is able to walk with help and speak in 2-3 word sentences. He is seizure-free but remains on clobazam due to the presence of focal epileptiform discharges on EEG and the parent's refusal to wean medication.

Case 2

A previously normal baby boy 1 month of age, who was the product of an uncomplicated pregnancy and delivery, presented to the emergency department with irritability, repeated right-sided partial seizures and, on examination, left retinal hemorrhaging. The EEG showed multifocal epileptic activity. Brain

MRI demonstrated multiple subdural hematomas, subarachnoid and intraventricular hemorrhage, an occipital bone fracture and areas of encephalomalacia in the left frontal and temporal regions (Figure 2). No abnormalities were detected on the skeletal survey, cardiac and abdominal ultrasounds, or infectious and metabolic work-up. The coagulation profile was normal. A diagnosis of nonaccidental head injury was made and seizures controlled with phenobarbital. At age 4 months, phenobarbital was discontinued. No further seizures were noted, but as the EEG still recorded very active multifocal epileptic discharges, the infant was started on clobazam. The infant was still achieving developmental milestones according to chronological age. Head circumference growth remained stable over this 3-month period, going from 40 cm (98th percentile) on initial presentation to 45.2 cm (99th percentile), accompanied by a slight acceleration of body growth from the 60th to the 85th percentile for height and 50th to 97th percentile for weight. No clinical signs or symptoms of intracranial hypertension were noted. Follow-up MRI showed enlargement of subarachnoid spaces and ventriculomegaly.

Infantile spasms with hypsarrhythmia on EEG was first noted at the age of 5 months. Vigabatrin administration achieved rapid control of spasms and was tapered after 6 months of use. Subsequent EEGs showed no hypsarrhythmia

but persistent multifocal epileptic discharges. At last follow-up, the child was 14 months old with no seizure recurrence on clobazam. Head circumference was continuing to follow the 99th percentile, with normal body growth around the 85th percentile for both weight and height. He was mildly developmentally delayed, able to crawl and babble, but unable to bear weight on his legs.

Discussion

Chronic epilepsy occurs in about 20% of nonaccidental head injury survivors.⁴ The incidence of infantile spasms in that population is not really known. Many prenatally or perinatally acquired brain lesions have been associated with the development of infantile spasms, but none have been shown to directly precipitate them. In our 2 patients, infantile spasms manifested within 3-4 months of a cerebral insult, in previously healthy infants with no other identifiable risk factor and despite well controlled focal seizures. This time frame was in line with the one found by Guggenheim et al, which ranged from 6 weeks to 11 months.⁵ Like neonatal hypoxic-ischemic encephalopathy, infantile spasms seemed to manifest only after a latency period during which neuronal network changes accumulate. Although our data did not allow us to establish a definite mechanism, they did support a role for traumatic brain injury in the development of symptomatic infantile spasms. They also demonstrated their responsiveness to vigabatrin, as described in the symptomatic model of infantile spasms.^{6,7}

Studies have described both structural and functional cortical abnormalities in patients with infantile spasms, suggesting a predilection for posterior brain areas.^{8,9} However, though our 2 patients had extensive cerebral lesions, case 2 showed no posterior predominance. According to the developmental desynchronization model,³ an unbalanced maturational pattern occurring within a critical developmental window could result in dysfunctional interactions between abnormal cortical areas and subcortical structures, regardless of lesion location, thus precipitating infantile spasms. Our data are consistent with this hypothesis.

A better understanding of the pathophysiology underlying infantile spasms development in nonaccidental head injury could lead to advances in neuroprotective or preventative strategies. This report highlights nonaccidental head injury as a risk factor for developing infantile spasms following a seizure-free latency period. Although no significant delay to diagnosis (< 1 month) was observed in our patients, health care professionals should heighten awareness in caregivers of the risk for young children with nonaccidental head injury for developing a form of epilepsy as severe as infantile spasms, with cognitive sequelae. Furthermore, increased neurological follow-up despite cessation of focal seizures is warranted in nonaccidental head injury.

Acknowledgements

The authors are grateful to Danielle Buch, medical writer/editor at the Applied Clinical Research Unit of the Sainte-Justine Research Center, for critical revision of the manuscript as well as editing.

Author Contributions

AB reviewed the patients' charts and wrote the first draft of the manuscript. GD reviewed the patients' charts. LC assisted with the interpretation of the patient data and revised and approved the final manuscript.

Declaration of Conflicting Interests

The author(s) declared no potential conflicts of interest with respect to the research, authorship, and/or publication of this article.

Funding

The author(s) received no financial support for the research, authorship, and/or publication of this article.

Ethical Approval

The review of all charts was approved by our institutional review board.

References

1. Carmant L. Infantile spasms: West syndrome. *Arch Neurol*. 2002; 59(2):317-318.
2. Brunson KL, Eghbal-Ahmadi M, Baram TZ. How do the many etiologies of West syndrome lead to excitability and seizures? The corticotropin releasing hormone excess hypothesis. *Brain Dev*. 2001;23(7):533-538.
3. Frost JD Jr, Hrachovy RA. Pathogenesis of infantile spasms: a model based on developmental desynchronization. *J Clin Neurophysiol*. 2005;22(1):25-36.
4. Bourgeois M, Di Rocco F, Garnett M, et al. Epilepsy associated with shaken baby syndrome. *Childs Nerv Syst*. 2008;24(2): 169-172.
5. Guggenheim MA, Frost JD Jr, Hrachovy RA. Time interval from a brain insult to the onset of infantile spasms. *Pediatr Neurol*. 2008; 38(1):34-37.
6. Scantlebury MH, Galanopoulou AS, Chudomelova L, et al. A model of symptomatic infantile spasms syndrome. *Neurobiol Dis*. 2010;37(3):604-612.
7. Carmant L. Vigabatrin therapy for infantile spasms: review of major trials in Europe, Canada, and the United States; and recommendations for dosing. *Acta Neurol Scand Suppl*. 2011;(192): 36-47.
8. Chugani HT, Shewmon DA, Shields WD, et al. Surgery for intractable infantile spasms: neuroimaging perspectives. *Epilepsia*. 1993; 34(4):764-771.
9. Hamano S, Tanaka M, Kawasaki S, et al. Regional specificity of localized cortical lesions in West syndrome. *Pediatr Neurol*. 2000;23(3):219-224.