

# Dystextia

## Acute Stroke in the Modern Age

**A** HEALTHY 25-YEAR-old right-handed pregnant woman, gravida 1, para 0 at 11 weeks' gestational age, was brought to the emergency department after sending her husband a series of confusing text messages regarding their baby's due date (**Figure, A**). At the time, she had just concluded a routine visit to her obstetrician's office, where she was retrospectively noted to have difficulty accurately completing her intake form. She additionally recalled an episode of acute weakness of her right arm and leg earlier in the morning that had lasted for a few minutes before resolving and for which she did not seek medical attention.

On neurologic examination, she was mildly disoriented and inattentive and had mild right hemiparesis in an upper motor neuron pattern, a mild right hemisensory loss, and a right extensor plantar response. Her language was notable for a fluent dysphasia with frequent semantic and phonemic paraphasic errors and difficulty following complex commands, with naming and repetition relatively intact. Her speech was hypophonic because of a recent upper respiratory illness.

Brain magnetic resonance imaging and 3-dimensional time-of-flight magnetic resonance angiography demonstrated reduced diffusivity in the left insula (**Figure, B**) and a filling defect in the inferior division of the left middle cerebral artery (**Figure, C**). A stroke workup revealed an atrial septal defect with

intracardiac shunting, but no deep venous thromboses, and a mildly elevated anticardiolipin IgM antibody (19 MPL units; reference range, 0-15 MPL units).

Her language deficits rapidly improved, and after consultation with her obstetricians, she was discharged taking 81 mg of aspirin daily as well as low-molecular-weight heparin for deep venous thrombosis prophylaxis. She had no recurrence of her symptoms, her repeated antiphospholipid antibody testing results were negative, and there was no evidence of fetal harm.

### COMMENT

Aphasia is a common manifestation of stroke, occurring in 21% to 38% of acute stroke patients.<sup>1</sup> To our knowledge, this is the first report of aberrant text messaging being the presenting sign of acute ischemic stroke. Alterations in texting ability, or "dystextia," have been previously observed in the context of a combined aphasia/apraxia during a complex migraine<sup>2</sup> as well as secondary to left hemiparesis following ischemic stroke.<sup>3</sup> As the accessibility of electronic communication continues to advance, the growing digital record will likely become an increasingly important means of identifying neurologic disease, particularly in patient populations that rely more heavily on written rather than spoken communication. In this case, the availability of texting may have been particularly valuable, because the patient's hypo-

phonia likely prevented earlier detection of her dysphasia.

Arvind Ravi, PhD  
Vikram R. Rao, MD, PhD  
Joshua P. Klein, MD, PhD

**Published Online:** December 24, 2012. doi:10.1001/jamaneuro.2013.604

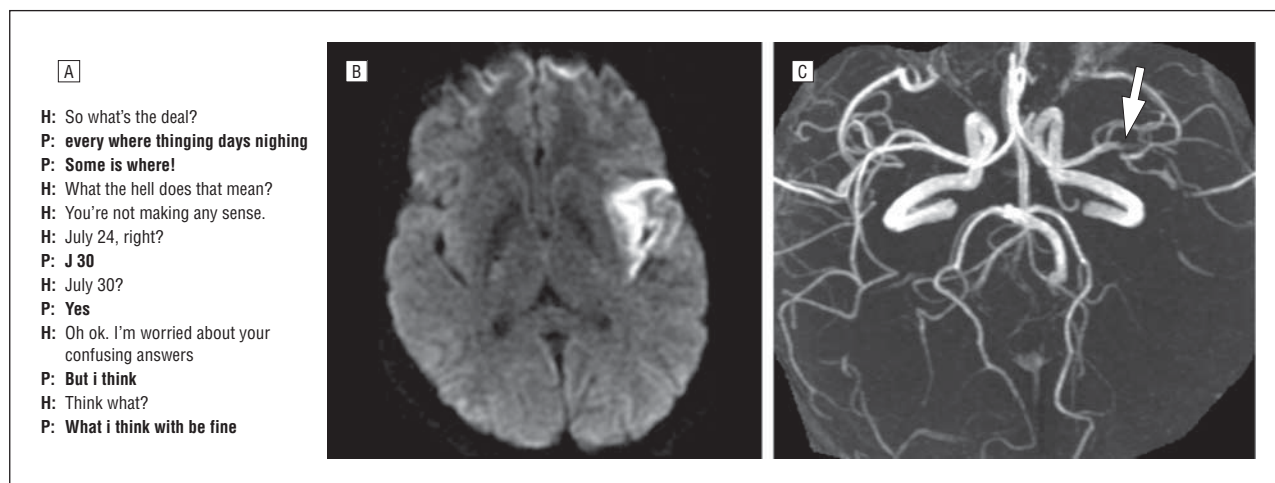
**Author Affiliations:** Harvard Medical School Health, Sciences, Technology Program (Dr Ravi), and Departments of Neurology (Drs Rao and Klein) and Radiology (Dr Klein), Brigham and Women's Hospital and Harvard Medical School, Boston, Massachusetts.

**Correspondence:** Dr Klein, Department of Neurology, Brigham and Women's Hospital, 75 Francis St, Boston, MA 02115 (jpklein@partners.org).

**Author Contributions:** Study concept and design: Ravi, Rao, and Klein. Acquisition of data: Ravi, Rao, and Klein. Analysis and interpretation of data: Ravi, Rao, and Klein. Drafting of the manuscript: Ravi. Critical revision of the manuscript for important intellectual content: Rao and Klein. Administrative, technical, and material support: Klein. Study supervision: Klein. **Conflict of Interest Disclosures:** None reported.

### REFERENCES

- Berthier ML. Poststroke aphasia: epidemiology, pathophysiology and treatment. *Drugs Aging*. 2005; 22(2):163-182.
- Whitfield P, Jayathissa S. Evolving neurological terminology in the 21st century: 'dystextia' associated with complex migraine. *Intern Med J*. 2011; 41(8):646.
- Cawood TJ, King T, Sreenan S. Dystextia: a sign of the times? *Ir Med J*. 2006;99(5):157.



**Figure.** Reproduced transcript and neuroimaging correlates of texting dysphasia. A, Transcript of text message conversation between the patient (P) and her husband (H). Patient's replies are notable for use of high-frequency words, social phrases, and neologisms. Spelling autocorrection function had been previously disabled on her mobile device. B, Axial diffusion-weighted magnetic resonance imaging shows reduced diffusivity in the left insula. Apparent diffusion coefficient maps (not shown) revealed corresponding hypointensity, confirming acute ischemic infarction. C, Maximal-intensity projection 3-dimensional time-of-flight magnetic resonance angiography shows a filling defect in the inferior division of the left middle cerebral artery (arrow). A relative paucity of vascular markings are noted throughout the distal left middle cerebral artery territory.