

Multimodal Imaging-Monitored Progression of Stroke-Like Episodes in a Case of MELAS Syndrome

Izzie Jacques Namer, MD, PhD,*§ Valérie Wolff, MD,† Jean-Louis Dietemann, MD,‡§
and Christian Marescaux, MD†

Abstract: We report imaging findings during, between, and after 2 stroke-like episodes in a 45-year-old woman with mitochondrial myopathy, encephalopathy, lactic acidosis, and stroke-like episodes (MELAS) syndrome with an A32243G mitochondrial mutation 6 years before. In November 2010, for a first episode, she showed mixed aphasia with logorrhea, disinhibition, agitation, euphoria, and a large left temporoparietal lesion. Symptomatology progressively regressed under L-arginine treatment. She was readmitted in June 2011 for a second episode with great anxiety, disorientation, impaired face recognition, worsening mixed aphasia, and a new right temporal lesion. After additional L-carnitine treatment, she remained without relapse for 14 months.

Key Words: MELAS, neuroimaging, FDG PET, SPECT, MRI, MRS

(*Clin Nucl Med* 2014;39: e239–e240)

Received for publication September 6, 2012; and revision accepted December 29, 2012.

From the *Service de Biophysique et Médecine Nucléaire, †Unité de Neurovasculaire, and ‡Service de Radiologie, Hôpital de Haute-pierre, Hôpitaux Universitaires de Strasbourg, Strasbourg; and §Université de Strasbourg/CNRS, UMR 7237, Strasbourg, France.

Conflicts of interest and sources of funding: none declared.

Reprints: Izzie Jacques Namer, MD, PhD, Service de Biophysique et de Médecine Nucléaire, Hôpitaux Universitaires de Strasbourg, Hôpital de Haute-pierre, 1, avenue Molière, 67098 Strasbourg Cedex 09, France. E-mail: Izzie.Jacques.NAMER@chru-strasbourg.fr.

Copyright © 2013 by Lippincott Williams & Wilkins
ISSN: 0363-9762/14/3903–e239

REFERENCES

- Iizuka T, Sakai F. Pathogenesis of stroke-like episodes in MELAS: analysis of neurovascular cellular mechanisms. *Curr Neurovasc Res.* 2005;2:29–45.
- Koga Y, Povalko N, Nishioka J, et al. MELAS and L-arginine therapy: pathophysiology of stroke-like episodes. *Ann NY Acad Sci.* 2010;1201:104–110.
- Ito H, Mori K, Kagami S. Neuroimaging of stroke-like episodes in MELAS. *Brain Dev.* 2011;33:283–288.
- Miyamoto A, Oki J, Takahashi S, et al. Serial imaging in MELAS. *Neuroradiology.* 1997;39:427–430.
- Nariai T, Ohno K, Ohta Y, et al. Discordance between cerebral oxygen and glucose metabolism, and hemodynamics in a mitochondrial encephalopathy, lactic acidosis, and stroke-like episode patient. *J Neuroimaging.* 2001;11:325–329.
- Shelly MJ, Kelly P, O'Connell MJ. FDG-PET imaging in the investigation of homonymous hemianopia in a patient with MELAS syndrome. *Clin Nucl Med.* 2007;32:479–480.
- Nishioka J, Akita Y, Yatsuga S, et al. Inappropriate intracranial hemodynamics in natural course of MELAS. *Brain Dev.* 2008;30:100–105.
- Wei CY, Hsiao HL, Chen SC, et al. Ictal and interictal 99mTc-HMPAO brain SPECT of a MELAS case presented with epilepsy-like visual hallucination. *Clin Nucl Med.* 2012;37:876–877.
- Tsujikawa T, Yoneda M, Shimizu Y, et al. Pathophysiologic evaluation of MELAS strokes by serially quantified MRS and CASL perfusion images. *Brain Dev.* 2010;32:143–149.
- Hsu CC, Chuang YH, Tsai JL, et al. CPEO and carnitine deficiency overlapping in MELAS syndrome. *Acta Neurol Scand.* 1995;92:252–255.

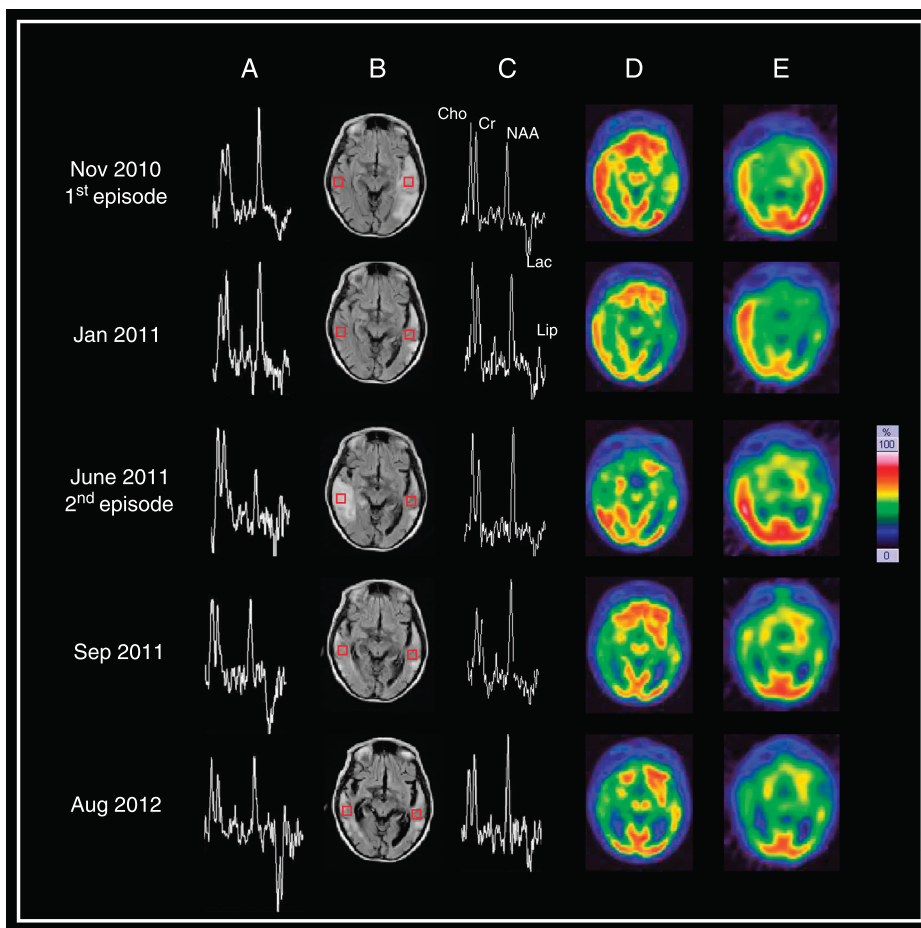


FIGURE 1. Matched temporal level transverse slices showing multimodal brain imaging during (November 2010 and June 2011) and after stroke-like episodes in MELAS syndrome: ^1H magnetic resonance spectroscopy (MRS) (A, C), fluid-attenuated inversion recovery magnetic resonance imaging (FLAIR MRI) (B), ^{18}F -FDG PET (D), and $^{99\text{m}}\text{Tc}$ -HMPAO SPECT (E). In both episodes, ^{18}F -FDG PET and $^{99\text{m}}\text{Tc}$ -HMPAO SPECT were performed the same day, and MRI/MRS were performed within 48 hours. In the acute phase of the first (fifth day) and the second (third day) stroke-like episodes, FLAIR MRI showed a large cortical and subcortical hyperintensity on the left temporal and later right temporal regions, which does not correspond to a vascular territory.¹⁻³ These lesions were characterized by decreased N-acetylaspartate, decreased FDG metabolism, and hyperemia.^{1,4-9} We detected a high level of lactate in all cerebral parenchyma including normal-appearing tissue and in lateral ventricles related to systemic lactic acidosis.^{1-4,9} The hyperemia observed in the acute phase seems to have been caused by vasodilatation due to a passive response to tissue acidosis resulting from impaired oxidative metabolism in mitochondria and differed from luxury perfusion after ischemic stroke.⁵ In the chronic phase, we observed a persistently high level of lactate as well as severe and expanded hypometabolized and hypoperfused areas affecting bilateral temporal regions, despite the decreased FLAIR MRI abnormality and partial recovery of N-acetylaspartate.^{3,9} Note the appearance of generalized brain atrophy in less than 2 years,⁴ despite no relapse for 14 months under L-arginine² and L-carnitine¹⁰ treatment.