

Ischemic Infarction of Cerebral Cortex in a Child with Scorpion Sting Envenomation

Rajniti Prasad · Shipra Suri · Shambhavi ·
Om Prakash Mishra

Received: 3 November 2012 / Accepted: 25 March 2013
© Dr. K C Chaudhuri Foundation 2013

Abstract Ischemic infarction in scorpion sting envenomation is rare and only few cases have been reported in adults. A 3-y-old child is reported who developed recurrent generalized tonic-clonic seizures 2 h after admission and hemiparesis on third day of admission following scorpion sting. Cranial tomography showed infarction in right and left frontoparietal lobes. The child was managed conservatively with prazosin, lorazepam and phenytoin sodium and made a complete recovery.

Keywords Scorpion sting · Envenomation · Ischemic infarction

Introduction

Scorpion sting envenomation is a life-threatening emergency in children of many underdeveloped tropical countries including India [1]. Clinical manifestations depend on body surface area, species and the amount of toxin injected and include local discomfort, pain, paraesthesia, motor hyperkinesia, cranial nerve dysfunction, dysphagia, cold extremities, drooling, fasciculations, neuromuscular hyperactivity, convulsions, wheezing, opisthotonus, hypothermia/hyperthermia, hypotension/hypertension, pulmonary edema, myocardial hypoperfusion and death. The systemic manifestations are due to intracellular influx of Na⁺ and Ca⁺⁺ ions, which results in autonomic storm. The venom is a low molecular weight water soluble mucopolysaccharide, which causes release of histamine and neurotoxins; while coagulins of venom induce intravascular thrombosis [2]. Intracerebral hemorrhage may

be due to sudden increase in blood pressure [3]. Therefore the authors report this case, which had features of scorpion sting envenomation and hemiparesis due to ischemic infarction of the cerebral cortex.

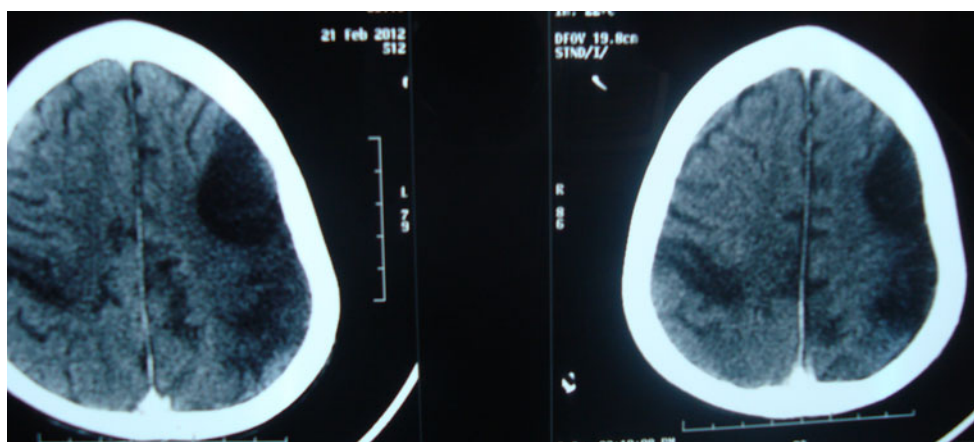
Case Report

A 3-y-old female child was brought to emergency with history of scorpion sting 6 h back, followed by cold extremities, profuse sweating, and fast breathing. She was conscious and tachypneic (58/min). Her pulse rate was 124/min, and blood pressure; systolic was 60 mm of Hg. Her arterial blood gas analysis was normal at admission. Child was initially given one bolus of normal saline (20 mL/kg) followed by normal maintenance fluids, prazosin (at admission, 3 h and then 6 hrly till stabilization of vital signs: 72 h), and dobutamine (10 µg/kg/min). After 2 h of admission patient developed generalized tonic clonic seizure and was managed with intravenous lorazepam and phenytoin sodium. Thereafter patient remained unconscious for 24 h. Patient was monitored in ICU with fluctuating heart rate of 20/min from baseline. On day 3 of admission, she was found to be aphasic and have weakness of right side of the body. Neurological examination revealed spasticity on right upper and lower limb. Power in right upper and lower limb was 1/5 and 2/5 respectively. All deep tendon reflexes on right side were exaggerated with extensor plantar response. Cranial nerves examination was normal.

Her complete blood count, electrolytes, blood glucose, liver and renal function tests were normal. Chest radiograph showed few infiltrates in right lower lung field. Her electrocardiogram showed nonspecific ST-segment elevation. Her platelet count, PT, APTT, FDP and D-dimer were within normal range. Cranial tomographs (done on seventh day) showed infarction in right and left frontoparietal lobes (Fig. 1). Patient was managed conservatively. Residual

R. Prasad (✉) · S. Suri · Shambhavi · O. P. Mishra
Department of Pediatrics, Institute of Medical Sciences,
Banaras Hindu University, Varanasi 221005, India
e-mail: rajnitip@gmail.com

Fig. 1 Cranial tomographs showing infarction in bilateral frontoparietal region



bilateral hemiparesis persisted at discharge with regain of speech. Patient was discharged on oral phenytoin sodium and advice of physiotherapy and there was no residual hemiparesis at 3 mo of follow up. Repeat cranial tomography was not done as patient had no residual paralysis.

Discussion

The bilateral asymmetric watershed cerebral infarcts seen in the present case following scorpion sting envenomation are because of reduced blood flow in the carotid arterial system as a result of severe vasospasm during autonomic storm. The catecholamine excess during autonomic storm also enhances endothelin secretion with resultant severe vasoconstriction [4, 5].

The increased acetyl choline in scorpion envenomation may cause excessive perspiration and vomiting leading to hypotension, which in presence of carotid vasospasm may further aggravate cerebral ischemia resulting in cerebral infarction. Cerebral infarcts, clinically evident 48 h after envenomation in present case, are compatible with low flow infarcts, which may progress over days or weeks [4]. An early treatment with prazosin may prevent cerebrovascular complications of scorpion envenomation [6].

Hypertension, tachycardia, myocardial dysfunction and pulmonary edema are because of alpha receptor stimulation, whereas increased angiotensin I levels facilitates the sympathetic outflow [7]. Myocarditis may occur due to unopposed stimulation of alpha receptor leading to intra-cardiac stasis and hypotension. The abrupt increase in blood pressure due to

sympathetic stimulation may result in rupture of perforating arteries, intra-cerebral hemorrhage, cerebral infarction and central respiratory failure in scorpion envenomation [8].

Conflict of Interest None.

Role of Funding Source None.

References

1. Chippaux JP, Goyffon M. Epidemiology of scorpionism: A global appraisal. *Acta Trop.* 2008;107:71–9.
2. Bawaskar HS, Bawaskar PH. Scorpion sting. *J Assoc Physicians India.* 1998;46:388–92.
3. Rai M, Shukla RC, Varma DN, Bajpai HS, Gupta SK. Intracerebral hemorrhage following scorpion bite. *Neurology.* 1990;40:1801.
4. Weiller C, Ringelstein EB, Reiche W, Buell U. Clinical and hemodynamic aspects of low-flow infarcts. *Stroke.* 1991;22:1117–23.
5. Thacker AK, Lal R, Misra M. Scorpion bite and multiple cerebral infarcts. *Neurol India.* 2002;50:100–2.
6. Biswal N, Bashir RA, Murmu UC, Mathai B, Balachander J, Srinivasan S. Outcome of scorpion sting envenomation after a protocol guided therapy. *Indian J Pediatr.* 2006;73:577–82.
7. Gueron M, Stern J, Cohen W. Severe myocardial damage and heart failure in scorpion sting. Report of five cases. *Am J Cardiol.* 1967;19:719–26.
8. Cody RJ, Haas GJ, Binkley PF, Capers Q, Kelley R. Plasma endothelin correlates with the extent of pulmonary hypertension in patients with chronic congestive heart failure. *Circulation.* 1992;85:504–9.