

Miseon Kwon, PhD,  
CCC-SLP

Jae-Hong Lee, MD, PhD

Jungsu S. Oh, PhD

Jae Young Koh, MD,  
PhD

## ISOLATED BUCCOFACIAL APRAXIA SUBSEQUENT TO A LEFT VENTRAL PREMOTOR CORTEX INFARCTION

Buccofacial apraxia (BFA, or oral apraxia) is a non-speech skilled movement disorder that involves orofacial structures in the absence of paresis. BFA usually co-occurs with aphasia or apraxia of speech (AOS), and isolated BFA is an extremely rare phenomenon. The brain regions correlated with BFA have been studied in patients with concomitant aphasia or limb apraxia. Therefore, the exact brain regions responsible for BFA remain unclear. We report a patient with pure BFA and discuss the localization of the brain lesion.

**Patient report.** A 63-year-old, right-handed, previously healthy man was admitted to our hospital due to the sudden onset of speech disturbance. He had difficulty speaking when he attempted to explain his destination to a taxi driver. A neurologic examination performed 4 hours after onset showed mild right facial palsy and mumbling speech without any motor/sensory dysfunction of the extremities. Diffusion-weighted MRI performed on the day of onset revealed an infarct in the left frontal cortex.

A thorough speech-language evaluation was administered 3 days after onset. He demonstrated intermittent distortion of articulation without any evidence of AOS or aphasia. The aphasia quotient (93.7/100) determined with the Korean version of the Western Aphasia Battery was within normal range. The score on the Korean version of the Boston Naming Test was above average (53/60, 66th percentile). Interestingly, prominent BFA was detected with the BFA test (1/10). He was only able to protrude his tongue in response to verbal instructions and imitate a lip-licking motion with his tongue after several trials. He showed great difficulties in performing or imitating the rest of the items of the BFA test, including motions such as tongue clicking, kissing a baby, and sucking through a straw. Severe concomitant groping movements of the lips and tongue were observed in response to each commanded gesture. He could not make sequential lip movements for “a-i-u” shapes even immediately after saying /a-i-u/ repeatedly and successfully. However, the automatic movements of the lips and tongue were preserved. He did not have any difficulties with limb apraxia<sup>1</sup> or AOS tests.

Fluid-attenuated inversion recovery MRI taken 4 days after onset was spatially normalized to a standard Montreal Neurological Institute MRI template using SPM2 in MATLAB (Mathworks Inc., Natick, MA). The coordinates of the lesion were then transformed to the standard coordinates of the Talairach brain atlas. We reconstructed the lesioned area, Brodmann area (BA) 6, and cortical surface in 3D using surface rendering in yellow, green, and triangular meshes, respectively. The results showed that the lesioned area was the left premotor cortex, which is the lateral part of BA 6. The lesion was restricted to the ventral portion of the premotor cortex (figure).

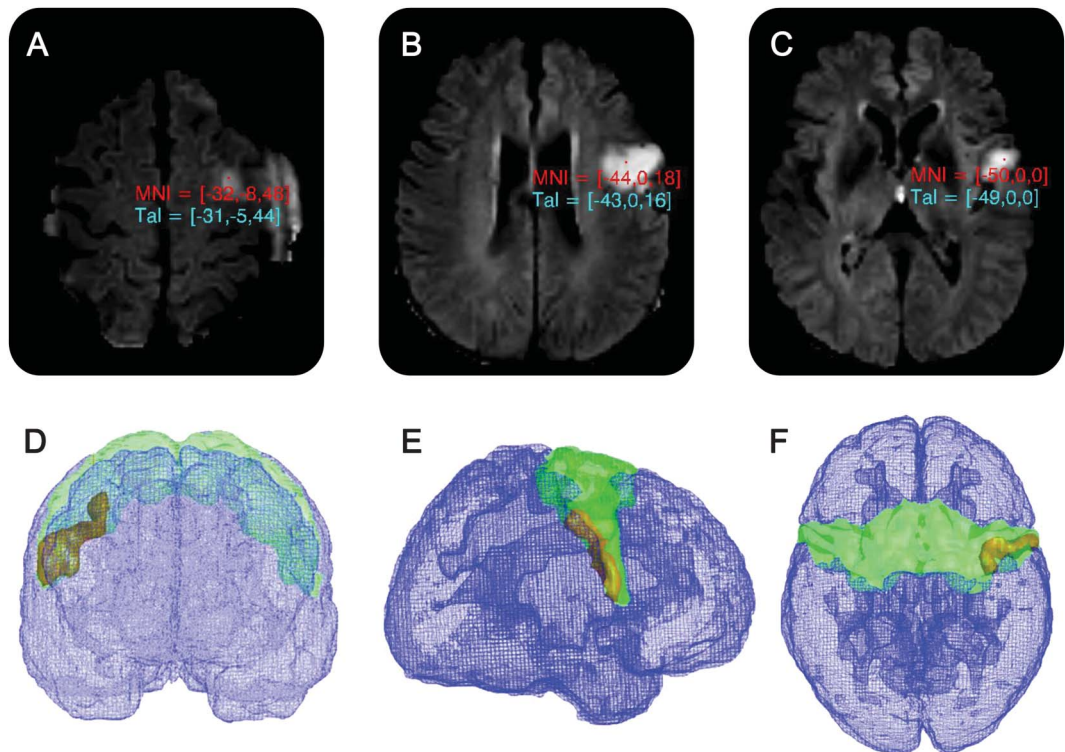
**Discussion.** We report a patient with pure BFA without aphasia, AOS, or any other forms of apraxia due to a left ventral premotor cortex infarction. The intermittent distortion of speech was likely due to tongue weakness of a corticobulbar origin rather than to AOS.

BFA lesions are thought to be located in the central operculum, the anterior insula, a part of the first temporal convolution, and the basal ganglia of the left hemisphere.<sup>1-3</sup> However, the presumed importance of these areas is based on the results from patients with concomitant aphasia or limb apraxia. Furthermore, some of these areas may be responsible for AOS.<sup>3</sup> Our patient only had BFA and his lesion was restricted to the ventral-posterior part of the left premotor cortex (figure).

The premotor cortex, which is located anterior to the primary motor cortex, comprises the lateral part of BA 6. The mesial part of BA 6 includes the supplementary motor area (SMA).<sup>3</sup> It has been suggested that the SMA is closely related to the preparation and execution of skilled motor sequences of the limbs (ideomotor praxis), especially the limb movements in relationship to an instrument (transitive movement), but does not influence nonspeech oral motor movements (BFA).<sup>3,4</sup> Sparing of this area seems to explain the absence of limb apraxia in our patient.

The premotor cortex can be subdivided into the dorsal (dPMC) and ventral part (vPMC).<sup>5</sup> According to previous intracortical microstimulation experiments using monkeys, stimulation of dPMC elicited movements of limbs, upper trunk, and face, whereas the vPMC was associated with the forelimb and orofacial

**Figure** Fluid-attenuated inversion recovery MRI



Fluid-attenuated inversion recovery MRI shows the upper (A), middle (B), and lower (C) extension of an infarct involving the left premotor cortex, and 3D reconstructed lesion (shown in yellow) is mapped to Brodmann area 6 (shown in green) in anterior (D), lateral (E), and superior (F) view. MNI = Montreal Neurological Institute coordinates; Tal = Talairach coordinates.

movements.<sup>6</sup> Furthermore, functional MRI study of human subjects showed that dPMC is activated during hand movement.<sup>7</sup> Therefore, there may be somatotopic functional segregation in the premotor area similar to the primary motor cortex. Our patient presented a lesion that was restricted to the vPMC and isolated BFA. The results provide further evidence supporting the argument.

*From Asan Medical Center, University of Ulsan College of Medicine, Seoul, Korea.*

*Author contributions: Mison Kwon: drafting/ revising the manuscript for content, including medical writing for content, study concept and design, analysis and interpretation of data, supervision and coordination of study, obtained funding. Jae-Hong Lee: drafting/ revising the content (including the medical terminology) of the manuscript, study concept and design, analysis and interpretation of data. Jungsu S. Oh: drafting/ revising the content (including the medical terminology) of the manuscript, analysis and interpretation of data (including analysis of brain images). Jae Young Kob: drafting/ revising the content (including the medical terminology) of the manuscript, study concept and design, contribution of vital patient.*

*Study funding: Supported by a grant from the Basic Science Research Program through the National Research Foundation of Korea (NRF) funded by the Ministry of Education, Science and Technology (no. 2010-0024353).*

*Disclosure: The authors report no disclosures relevant to the manuscript. Go to Neurology.org for full disclosures.*

*Received October 4, 2012. Accepted in final form February 19, 2013.*

*Correspondence to Dr. Kwon: mskwon@amc.seoul.kr*

© 2013 American Academy of Neurology

1. Raade AS, Rothi LJ, Heilman KM. The relationship between buccofacial apraxia and limb apraxia. *Brain Cogn* 1991;16:130–146.
2. Tognola G, Vignolo LA. Brain lesions associated with oral apraxia in stroke patients: a clinico-neuroradiological investigation with the CT scan. *Neuropsychologia* 1980; 18:257–272.
3. Square PA, Roy EA, Martin RE. Apraxia of speech: another form of praxis disruption. In: Rothi LJ, Heilman KM, eds. *Apraxia: The Neuropsychology of Action*. New York: Psychology Press; 1997:173–206.
4. Watson RT, Fleet WS, Rothi LG, Heilman KM. Apraxia and the supplementary motor area. *Arch Neurol* 1986;43: 787–792.
5. Mayka MA, Corcos DM, Leurgans SE, Vaillancourt DE. Three-dimensional locations and boundaries of motor and premotor cortices as defined by functional brain imaging: a meta-analysis. *Neuroimage* 2006;31:1453–1474.
6. Preuss TM, Stepniewska I, Kaas JH. Movement representation in the dorsal and ventral premotor areas of owl monkeys: a microstimulation study. *J Comp Neurol* 1996;371: 649–676.
7. Hlustick P, Solodkin A, Gullapalli RP, Noll DC, Small SL. Functional lateralization of the human premotor cortex during sequential movements. *Brain Cogn* 2002;49:54–62.

# Neurology<sup>®</sup>

## Isolated buccofacial apraxia subsequent to a left ventral premotor cortex infarction

Miseon Kwon, Jae-Hong Lee, Jungsu S. Oh, et al.

*Neurology* 2013;80:2166-2167 Published Online before print May 8, 2013

DOI 10.1212/WNL.0b013e318295d6e3

### This information is current as of May 8, 2013

<b>Updated Information &amp; Services</b>	including high resolution figures, can be found at: <a href="http://www.neurology.org/content/80/23/2166.full.html">http://www.neurology.org/content/80/23/2166.full.html</a>
<b>References</b>	This article cites 6 articles, 0 of which you can access for free at: <a href="http://www.neurology.org/content/80/23/2166.full.html##ref-list-1">http://www.neurology.org/content/80/23/2166.full.html##ref-list-1</a>
<b>Citations</b>	This article has been cited by 1 HighWire-hosted articles: <a href="http://www.neurology.org/content/80/23/2166.full.html##otherarticles">http://www.neurology.org/content/80/23/2166.full.html##otherarticles</a>
<b>Subspecialty Collections</b>	This article, along with others on similar topics, appears in the following collection(s): <b>All Cerebrovascular disease/Stroke</b> <a href="http://www.neurology.org/cgi/collection/all_cerebrovascular_disease_stroke">http://www.neurology.org/cgi/collection/all_cerebrovascular_disease_stroke</a> <b>Apraxia</b> <a href="http://www.neurology.org/cgi/collection/apraxia">http://www.neurology.org/cgi/collection/apraxia</a> <b>MRI</b> <a href="http://www.neurology.org/cgi/collection/mri">http://www.neurology.org/cgi/collection/mri</a>
<b>Permissions &amp; Licensing</b>	Information about reproducing this article in parts (figures, tables) or in its entirety can be found online at: <a href="http://www.neurology.org/misc/about.xhtml#permissions">http://www.neurology.org/misc/about.xhtml#permissions</a>
<b>Reprints</b>	Information about ordering reprints can be found online: <a href="http://www.neurology.org/misc/addir.xhtml#reprintsus">http://www.neurology.org/misc/addir.xhtml#reprintsus</a>

*Neurology*® is the official journal of the American Academy of Neurology. Published continuously since 1951, it is now a weekly with 48 issues per year. Copyright © 2013 American Academy of Neurology. All rights reserved. Print ISSN: 0028-3878. Online ISSN: 1526-632X.

