

ORIGINAL ARTICLE

## Surgical embolectomy for large vessel occlusion of anterior circulation

Tomohiro Inoue<sup>1</sup>, Akira Tamura<sup>1</sup>, Kazuo Tsutsumi<sup>2</sup>, Isamu Saito<sup>1</sup> & Nobuhito Saito<sup>3</sup>

<sup>1</sup>Department of Neurosurgery, Fuji Brain Institute and Hospital, Shizuoka, Japan, <sup>2</sup>Department of Neurosurgery, Showa General Hospital, Tokyo, Japan, and <sup>3</sup>Department of Neurosurgery, University of Tokyo, Tokyo, Japan

### Abstract

**Object.** The aim of this study was to assess the technical details and the efficacy and safety of surgical embolectomy for occlusion of large vessels in the anterior circulation. **Methods.** Twenty-three consecutive patients with acute ischemic stroke attributed to embolic occlusion of large arteries of the anterior circulation who underwent treatment with surgical embolectomy were retrospectively reviewed. Twenty patients were treated based on data from magnetic resonance angiography (MRA)–diffusion weighted imaging (DWI) mismatch, while three other patients had contraindications to magnetic resonance imaging (MRI) and were treated based on computed tomography (CT) and digital subtraction angiography (DSA) findings. Clinical outcomes, including recanalization rate, recanalization time, complications, modified Rankin Scale (mRS) at 3 months, and National Institute of Health Stroke Scale (NIHSS) score improvement at 1 month, were evaluated. **Results.** Among the 23 patients (median age, 80 years; median presenting NIHSS score, 21 points), the occlusion site was the internal carotid artery (ICA) terminus in six patients, the M1 segment of the middle cerebral artery (MCA) in 10 patients, and the M2 division of the MCA in seven patients. Final recanalization status was thrombolysis in myocardial infarction (TIMI) 3 in 21 patients (91%). Median recanalization time from symptom onset and from start of surgery was 282 min and 70 min, respectively. One patient (4.3%) had symptomatic haemorrhage. Three patients (13%) had brain oedema due to massive infarction of affected vessel area; two of these patients had undergone embolectomy based on CT findings and had successful recanalization, while one patient underwent embolectomy based on MRI findings and did not have successful recanalization. All 18 patients who underwent embolectomy based on MRA–DWI mismatch and had successful recanalization did not develop additional confluent ischaemic lesion on postoperative DWI. At 3 months, seven patients (30%) had a mRS score of 0–2, eight patients (35%) had a mRS score of 3, and none of the patients had died. Sixteen patients (70%) demonstrated NIHSS score improvement

of more than eight points at 1 month. **Conclusion.** Surgical embolectomy for occlusion of large vessels in the anterior circulation resulted in a high complete recanalization rate with an acceptable safety profile. Use of MRA–DWI mismatch as an indication for surgical embolectomy was associated with a reduced complication rate.

**Keywords:** carotid terminus; DWI; embolectomy; middle cerebral artery; MRA

**Abbreviations:** CT, computed tomography; DSA, digital subtraction angiography; DWI, diffusion-weighted imaging; ECASS, European Cooperative Acute Stroke Study; ICA, internal carotid artery; MCA, middle cerebral artery; MERCI, mechanical embolus removal in cerebral ischaemia; MRA, magnetic resonance angiography; MRI, magnetic resonance imaging; mRS, modified Rankin Scale; NIHSS, National Institute of Health Stroke Scale; PH, parenchymal haematoma; STA, superficial temporal artery; TIMI, thrombolysis in myocardial infarction; tPA, tissue plasminogen activator; T2WI, T2-weighted imaging

### Introduction

Proximal intracranial arterial occlusion is independently associated with poor functional outcomes and high mortality rates,<sup>1–3</sup> and final revascularization is the strongest predictor of good outcome.<sup>4,5</sup> However, the rate of intravenous tissue plasminogen activator (tPA)-induced revascularization for occlusions of large intracranial vessel in patients with acute ischemic stroke may be as low as 6% for occlusion of the internal carotid artery (ICA) terminus and 30% for occlusion of the proximal middle cerebral artery (MCA). Further, nonresponse to intravenous tPA is associated with poor clinical outcomes.<sup>4,6</sup> The multi-mechanical embolus removal in cerebral ischemia trial achieved recanalization in 70% of patients.<sup>7</sup> Although encouraging, a substantial number of patients still experience unsuccessful vessel recanalization with the currently approved endovascular technique.

Practically, endovascular approach using mechanical embolus removal in cerebral ischaemia (MERCI) devices necessitates diagnostic evaluation and treatment in stroke centres equipped with an interventional neuroradiological service on a 24-h basis, but there is no such centre available in many areas in Japan including our geographic district (eastern half of Shizuoka Prefecture). Ultimately, our service (Department of Neurosurgery, Fuji Brain Institute and Hospital), which is staffed with a neurosurgical service that can perform microsurgery but cannot perform endovascular surgery on a 24-h basis, will serve as a referral centre for severe stroke patients in this district of approximately 500 000 inhabitants.

Our institution has adopted surgical embolectomy as a second-line treatment for occlusions of large intracranial vessels of the anterior circulation but not as an adjunct to intravenous tPA infusion treatment.

During the study period of the present case series (2008–2011), intravenous tPA infusion therapy was limited to only 3 h since symptom onset in Japan. Most patients who underwent surgical embolectomy presented beyond 3 h in the present series, although some patients who presented within 3 h were included into surgical embolectomy when IV tPA is contraindicated or relative contraindicated in Japanese guideline. Although several series describing surgical embolectomy for occlusions of the MCA have been published, experience with surgical embolectomy for occlusions of the ICA terminus is relatively scarce.<sup>8–10</sup> Most case series have selected patients for embolectomy based on computed tomography (CT) and digital subtraction angiography (DSA) findings,<sup>8,9</sup> and little is known as to whether selecting patients based on magnetic resonance imaging (MRI) is associated with safe and effective surgical embolectomy.<sup>10</sup>

Magnetic resonance angiography (MRA) and diffusion-weighted imaging (DWI) mismatch is a proposed model to identify patients who are likely to benefit from intravenous tPA therapy in the 3- to 6-h time window.<sup>11</sup> The MRI pattern observed in these patients consists of a relatively small DWI lesion in combination with MRA evidence of occlusion of a large intracranial vessel. This model might be useful to identify patients who would benefit from surgical embolectomy.

Thus, the goal of this study was to characterize the technical details and efficacy of surgical embolectomy for acute embolic occlusions of large intracranial arteries of the anterior circulation, including the ICA terminus, with particular regard to the recanalization rate. Further, this study analysed whether patient inclusion based on MRI findings could reduce complications and extend the therapeutic window when compared with inclusion based on CT and DSA findings.

## Methods

### Patient selection

The medical records of 23 consecutive patients who underwent surgical embolectomy for acute ischaemic stroke attributed to embolic occlusion of the intracranial ICA and MCA (M1 segment, M2 division) at Fuji Brain Institute and Hospital between 2008 and 2011 were reviewed (Table I). Demographic, clinical, MRI, CT, DSA and follow-up data were analysed. The National Institute of Health Stroke Scale (NIHSS) score upon initial presentation was determined by the treating physician (neurosurgical residents), and CT imaging was performed in all patients. Three patients had an implanted pacemaker and could not undergo MRI studies, but the remaining 20 patients underwent MRA and DWI

Table I. Clinical summary of 23 consecutive patients treated with surgical embolectomy for large vessel occlusions of anterior circulation.

Patient	Age/Sex	Presenting NIHSS	Occluded artery/side	Onset to recanali (min)	Ope to recanali (min)	TIMI final	NIHSS 1 month	mRS 3months	Last MRA f/u (months)	Number of arteriotomy
1	85/m	20	M1/lr	510	275	3	4	3	2	2
2	61/m	9	M2/lr	150	52	3	0	1	23	1
3	85/m	17	M1/rt	426	120	3	9	3	27	3
4	80/f	23	ICA/lr	319	97	3	4	3	31	1
5	58/m	21	M2/lr	257	47	3	1	1	22	1
6	74/m	30	M1/lr	247	57	3	12	3	19	2
7	82/m	17	M2/lr	271	56	3	3	3	9	1
8	87/m	23	M1/rt	240	60	3	10	5	2	2
9	61/m	5	M2/lr	445	70	3	2	1	9	1
10	84/m	24	ICA/rt	NA	NA	0	21	5	NA	1
11	72/f	20	M1/rt	330	78	3	9	4	0.5	1
12	79/m	12	M1/rt	302	47	3	2	2	14	1
13	91/f	12	ICA/rt	450	75	3	13	5	NA	2
14*	81/f	28	M1/rt	292	74	3	27	5	NA	1
15	69/m	14	M2//lr	724	91	3	6	3	0.5	3
16*	64/f	25	ICA//lr	235	55	3	19	4	NA	2
17	64/m	23	ICA/rt	240	80	3	4	1	7	1
18	82/m	18	M1/rt	282	67	3	6	2	5	1
19	73/f	21	M2/lr	NA	NA	0	16	4	NA	2
20	85/f	24	M1/rt	184	44	3	4	3	4	1
21	93/f	30	M1/rt	265	73	3	26	5	0.5	2
22	36/f	23	ICA/rt	435	92	3	0	0	3	1
23*	86/f	29	M2/lr	256	48	3	5	3**	0.5	2

NIHSS, National Institute of Health Stroke Scale; Onset (Ope) to recanali, time from onset of symptom (start of operation) to recanalization; TIMI, Thrombolysis In Myocardial Infarction; mRS, modified Rankin Scale; MRA, magnetic resonance angiography; f/u, follow-up; M1, M1 segment of middle cerebral artery; M2, M2 division of middle cerebral artery; ICA, internal cerebral artery; NA, not applicable

\*Inclusion based on CT due to contraindication to MRI

\*\*mRS at 1 month

to identify occluded arteries as well as to evaluate the extent of the ischaemic lesion. In these 20 patients, the so-called MRA-DWI mismatch, representing occlusion of a large artery in the anterior circulation on MRA with minimal ischaemic lesion (less than one-third of the MCA territory) on DWI, was confirmed. The presence of proximal intracranial arterial occlusion was assessed mainly using MRA and was classified as follows: occlusion of the ICA terminus, occlusion of the M1 segment of the MCA and occlusion of the M2 division of the MCA. In addition, in 10 cases, DSA was also performed between MRI and surgery to confirm the configuration of the occluded site, to elucidate whether that occlusion was embolic in origin (indicated by a characteristic 'fish mouse figure'), and to assess collateral status. In the three patients with pacemakers (Patients 14, 16 and 23), DSA was used to identify the occluded artery. The decision to conduct surgical embolectomy was based on a clinical diagnosis of acute embolic occlusion of the proximal intracranial anterior circulation with NIHSS  $\geq 15$  or a dense focal deficit, such as severe hemiparesis and severe aphasia, and the absence of acute hyperintensity on DWI (hypodensity or early ischaemic sign on CT when contraindications to MRI were present) involving more than one-third of the MCA territory. Hyperintensity area was assessed by visual inspection by the treating physician and was supervised by a staff neurosurgeon (TI). Nine patients presented within 3 h. Three of these nine patients had contraindications to intravenous tPA therapy (concomitant small cerebellar haemorrhage,  $n = 1$ ; recent intracranial surgery,  $n = 1$ ; recent stroke,  $n = 1$ ), and the other six patients had relative contraindications to intravenous tPA therapy (NIHSS  $\geq 23$ ,  $n = 6$ ; older age,  $n = 3$ ; warfarin therapy,  $n = 1$ ; coma,  $n = 3$ ). Patients with modified Rankin Scale (mRS) score  $\geq 3$  were not excluded. None of the patients underwent intravenous tPA infusion or intra-arterial thrombolytic therapy before surgical embolectomy. Informed consent to undergo surgical embolectomy was obtained from the patients' families in all cases.

### Surgical embolectomy

Under general anaesthesia, a frontotemporal craniotomy was utilized for a trans-Sylvian approach. Under microscopy, the Sylvian fissure was opened to expose the occluded artery. The location of the embolus was identified by visualizing the bluish discoloration of the occluded artery. Temporary clips were applied to distal vessels (and proximal to the occlusion when needed) to prevent distal migration of the embolus. Transverse arteriotomy was made near the distal end of the embolus, and the embolus was removed. If the embolus was segmented or large, another transverse arteriotomy was made as needed. After confirming anterograde flow as well as retrograde flow, the arteriotomy was repaired with intermittent stitches using 9-0 nylon. Recanalization status was confirmed by microvascular Doppler after restoration of flow followed by intravenous administration of 2000–3000 U of heparin. In the event of acute re-occlusion, the arteriotomy distal to the re-occlusion was reopened, residual local debris was flushed and the arteriotomy was repaired in the same manner. Good anterograde flow of all the branches

distal to the occluded portion, as confirmed by microvascular Doppler, was regarded as Thrombolysis In Myocardial Infarction (TIMI) 3 flow.<sup>12</sup> If one of the distal branches did not show stable anterograde flow, it was regarded as TIMI 2 flow. Time of final recanalization was recorded to determine recanalization time from symptom onset and from start of the operation. The retrieved thrombus was examined using histopathological techniques when possible. Continuous intravenous heparin 10 000 unit/day infusion was started on postoperative day 1 and was continued until warfarinization to an international normalization ratio of 1.6 to 2.6 was obtained.

### Postoperative evaluation and follow-up

CT was performed several times during the acute period, including immediately postoperatively and on postoperative day 1, to assess for haemorrhagic complications or new ischaemic lesions. Follow-up MRI studies, including MRA and DWI, were performed on day 0 (0–12 h after surgery) in eight patients and on day 1 (12–24 h after surgery) in 12 patients to determine the recanalization status of the initially occluded artery and to assess for any new ischaemic lesions. In 20 patients who underwent surgical embolectomy based on MRA-DWI mismatch, final recanalization status was assessed based on follow-up MRA according to TIMI system (0, complete occlusion; 1, penetration without perfusion; 2, partial perfusion; and 3, complete perfusion).<sup>12,13</sup> In the three patients with pacemakers, final TIMI scores were determined based on intraoperative microvascular Doppler (Patient 14) or postoperative DSA (Patients 16 and 23). Progression of ischaemic lesion(s) on DWI was also evaluated when available. Haemorrhagic complications were categorized as haemorrhagic infarction Type 1 or 2 (HI-1 or HI-2) or parenchymal haematoma Type 1 or 2 (PH-1 or PH-2) according to the classification system of the European Cooperative Acute Stroke Study (ECASS) trial.<sup>14,15</sup> Symptomatic haemorrhage was defined as neurological worsening  $\geq 4$  points on NIHSS that was attributed to the presence of the clot, with no other CT findings other than haemorrhage that might have been responsible for this deterioration. When the neurological deterioration was due to massive progression of infarct and ischaemic brain oedema of the affected arterial territory with coincidental minimal bleed within the surgical field, it was regarded as brain oedema and not as symptomatic haemorrhage. The timing of evaluation for functional outcomes varied from patient to patient because of the retrospective nature of this study; therefore, outcome scores were obtained at approximately 1 month (NIHSS score) and at approximately 3 months (mRS score) via a review of medical records by a staff neurosurgeon (TI). In addition to usual functional outcome measures (mRS score, 0–2), the incidence of NIHSS score improvement greater than 8 points at 1 month was assessed. This was done because the patient population contained those with high NIHSS scores upon presentation, older patients, and patients with mRS score  $\geq 3$ . Mid- to long-term patency of the embolectomy site was also examined using MRA when possible.

Table II. Recanalization rate and time.

	ICA occlusion (n = 6)	M1 occlusion (n = 10)	M2 occlusion (n = 7)	Total (n = 23)
TIMI 3 recanalization	5 (83%)	10 (100%)	6 (86%)	21 (91%)
TIMI 0	1* (17%)	0 (0%)	1** (14%)	2 (9%)
Median recanalization time***	80 (Range 55-97) min; n = 5	70 (Range 44-275) min; n = 10	54 (Range 47-91) min; n = 6	70 (Range 44-275) min; n = 21

ICA, internal cerebral artery terminus; M1, M1 segment of MCA; M2, M2 division of MCA; TIMI, thrombolysis in myocardial infarction; min, minutes.

\*No recanalization due to persistent carotid siphon occlusion by large embolus (Patient 10).

\*\*No recanalization due to atherosclerotic occlusion rather than embolic occlusion (Patient 19).

\*\*\*Recanalization time from start of surgery.

## Results

The 23 patients included 13 men and 10 women with a median age of 80 years (range, 36–93 years). The median presenting NIHSS score was 21 points (range, 5–30). All patients had a cardiac history suggestive of cardiac embolism. Atrial fibrillation was noted in 18 patients. One patient had an implanted artificial mechanical aortic valve and was on warfarin. Three patients had an implanted pacemaker, and these patients had a past history of embolic phenomena, hypertrophic cardiomyopathy and tachycardia with pacemaker malfunction, respectively. One patient had cardiomegaly without atrial fibrillation, and a preoperative diagnosis of cardiac embolism was established based on observation of a 'fish mouse figure' in the occluded portion.

The occlusion occurred at the ICA terminus in six patients, the M1 segment of the MCA in 10 patients, and the M2 division of the MCA in seven patients. The occlusion was on the right-hand side in 12 patients and on the left-hand side in 11 patients. Final recanalization status was TIMI 3 flow in 21 patients (91%; Table II). Intraoperative microvascular Doppler and postoperative MRA demonstrated TIMI 3 flow in 17 patients. In one patient, intraoperative microvascular Doppler showed TIMI 2 flow, but postoperative MRA demonstrated TIMI 3 flow. In the three patients with pacemakers, TIMI 3 flow was confirmed by intraoperative microvascular Doppler in one patient and by postoperative DSA in two patients. The last four patients were regarded as TIMI 3 in final recanalization status. Two patients resulted in TIMI 0 flow. In Patient 10, even after the removal of embolus from the C2 portion of the ICA, antegrade flow was not restored, possibly due to large residual embolus burden at the carotid siphon. In Patient 19, with a sudden onset of atrial fibrillation, intraoperative findings revealed that the aetiology of occlusion was in situ thrombus engrafted on severe atherosclerotic lesions within the superior M2 division. Recanalization by embolectomy was unsuccessful due to the underlying atherosclerotic lesion. Of the 21 patients who obtained recanalization, median recanalization time from symptom onset was 282 min (range, 150–724 min). Recanalization time from symptom onset was more than 4 h in 18 patients and was more than 6 h in six patients. Of the 18 patients who recanalized later than 4 h, 16 patients (including all six patients that recanalized later than 6 h) underwent surgical embolectomy based on MRA-DWI mismatch. Notably, of these 16 patients, no patient had a substantial increase in ischaemic lesions on postoperative DWI when compared with preoperative DWI, and only one patient (Patient 12) developed symptomatic haemorrhagic complications. Median recanalization time

from the start of surgery was 70 min (range, 44–275 min; n = 21). Patients with more distal occlusion tended to achieve recanalization more quickly (Table II).

There were four instances of major complications (17.3%): one patient experienced symptomatic intracerebral haemorrhage (4.3%), and three patients developed brain oedema (13%) caused by cerebral infarction of the affected vessel area (Table III).

The incidence of clinically significant symptomatic haemorrhage in this study was 4.3%. This was associated with PH-1, possibly due to hyperperfusion followed by generalized convulsions (Patient 12). No patient developed PH-2. Eleven patients (48%) experienced asymptomatic intracranial bleeding, all of which were minor subarachnoid haemorrhage or sub-pial contusion in the medial surface of the frontal and temporal opercula. These were likely related to pial injury by surgical manipulation rather than to rebleed from the arteriotomy site.

Three patients (13%) experienced clinical deterioration due to brain oedema generated from the confluent infarction of the initially occluded vessel area. All three patients underwent internal decompression surgery with craniotomy and partial frontotemporal lobectomy by removing necrotic brain tissue. Of note, two of these three patients (Patients 14 and 16) underwent surgical embolectomy based on CT and DSA findings; MRI was contraindicated in these two patients because of the presence of a pacemaker. In these two patients, immediate postoperative CT revealed completed stroke in the affected vessel territory despite successful recanalization; this suggests that pre-existing early ischaemic change may have been present that was not detected on CT. One patient (Patient 10) underwent embolectomy based on MRI findings and did not have successful recanalization. In contrast, of the 18 patients who underwent surgical embolectomy based on MRA-DWI mismatch and had successful recanalization, none developed significant additional confluent ischaemic lesions on postoperative DWI.

At 3 months, seven patients (30%) had a mRS score of 0–2, eight patients (35%) had a mRS score of 3, and there was no mortality. However, Patient 23 was only followed up for 1 month, and the mRS at 1 month was used as the value for the

Table III. Complication.

	MRI based (n = 20)	CT based (n = 3)	Total (n = 23)
Symptomatic ICH	1 (5%)	0 (0%)	1 (4.3%)
Brain oedema	1* (5%)	2 (66.7%)	3 (13%)

ICH, intracerebral haemorrhage; brain oedema, cytotoxic brain oedema caused by cerebral infarction of initially affected vessel area.

\*Due to no recanalization of ICA occlusion (Patient 10).

mRS at 3 months in this patient. Eight patients remained at a mRS score of 3 at 3 months despite marked recovery in motor function. Of these eight patients, the median age was 83.5 years (range, 69–86 years), and the reason for dependency was aphasia in five patients and mild dementia in three patients. Sixteen patients (70%) demonstrated an NIHSS score improvement of > 8 points at 1 month.

Retrieved clots from 14 patients underwent histological examination, revealing organizing mixed thrombus of probable cardiac origin in 13 patients. In one patient (patient 19), tiny organized thrombus with some component of the arterial wall suggested an atherosclerotic occlusion rather than a cardiac embolism.

The number of arteriotomy sites was one in 13 patients, two in eight patients and three in two patients. In 18 of 23 patients, mid- to long-term patency of the arteriotomy site was confirmed using MRA (median, 6 months; range, 0.5–31 months). No patient developed significant stenosis at the embolectomy site during this period.

## Case illustration

### Patient 4

An 80-year-old female with a premorbid mRS score of 3 (slight dementia) experienced a sudden onset of disturbance of consciousness and right hemiplegia. Her presenting NIHSS score was 23. Electrocardiogram showed atrial fibrillation. MRA showed left ICA occlusion, but no ischaemic lesions were found on DWI. Considering the possibility of high clot burden combined with high NIHSS score and advanced age, surgical embolectomy was elected. Arteriotomy was made in the proximal M1 just distal to the ICA bifurcation (Fig. 1a, b). Recanalization was obtained at 319 min after symptom onset and at 97 min after the start of surgery. Postoperative MRA showed TIMI 3 recanalization, and DWI demonstrated a minimal spotty ischaemic lesion in the medial temporal lobe. The patient's level of consciousness and motor deficits improved significantly. Her NIHSS score at 1 month was 4. At 3 months, her mRS score was 3 due to general weakness and slight dementia. The most recent follow-up MRA at 31 months demonstrated a patent left ICA and MCA.

### Patient 22

A 36-year-old woman presented with a sudden onset of disturbance of consciousness, left hemiplegia, and right-sided conjugated deviation of her gaze. Her presenting NIHSS score was 23. Although electrocardiogram did not show atrial fibrillation, the family related that the patient had been complaining of irregular heartbeat for the preceding several days. Initial CT showed a hyperdense sign from the right ICA to MCA. MRA demonstrated a right ICA occlusion. DWI showed an ischaemic lesion in the right insular cortex and basal ganglia (Fig. 2a). Surgical embolectomy was performed (Fig. 2b). Arteriotomy was made in the proximal M1 just distal to the ICA bifurcation. Recanalization was obtained at 435 min after symptom onset and at 92 min after the start of surgery, respectively. Postoperative MRA demonstrated TIMI 3 recanalization. There were no additional ischaemic lesions on DWI (Fig. 2c). Paroxysmal atrial fibrillation was

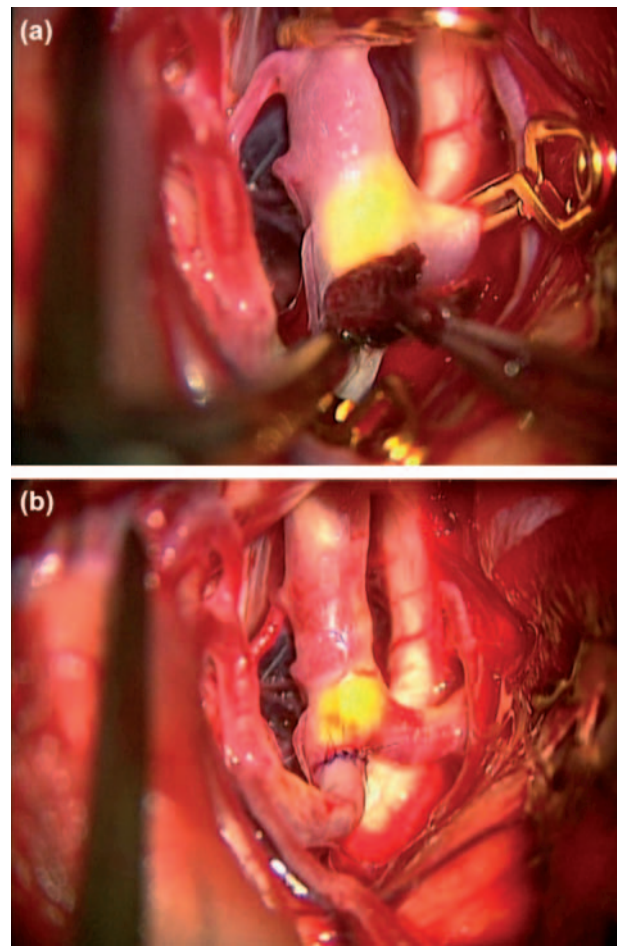


Fig. 1. Intraoperative photograph (a, b), showing an embolus being extracted via the arteriotomy site in the proximal M1 just distal to the left ICA bifurcation.

confirmed during the postoperative course. The patient experienced a marked neurologic recovery, with a mRS score of 0 and regained her previous job at 3 months.

## Discussion

This study showed that surgical embolectomy was associated with a high TIMI 3 recanalization rate (91%). Final revascularization is the strongest predictor of good outcome,<sup>4,5</sup> and in most of the endovascular studies using recanalization status as outcome surrogate, both TIMI 2 and TIMI 3 flows are considered to represent successful recanalization. However, among most of these series, there was still a substantial percentage of patients with TIMI 2 flow, and the rate of complete recanalization rate (i.e. TIMI 3 flow) was only approximately 40–50%.<sup>16</sup> In this study, because of the nature of procedure itself (in which there was an immediate distal clip application before embolus removal rather than clot disruption with proximal revascularization and distal embolization), all cases of successful recanalization comprised TIMI 3 recanalization.

Among all cases of occlusion of large vessels, acute ischaemic stroke attributed to occlusion at the ICA terminus is associated with a high rate of mortality and poor functional outcome. Due to high clot burden, pharmacological

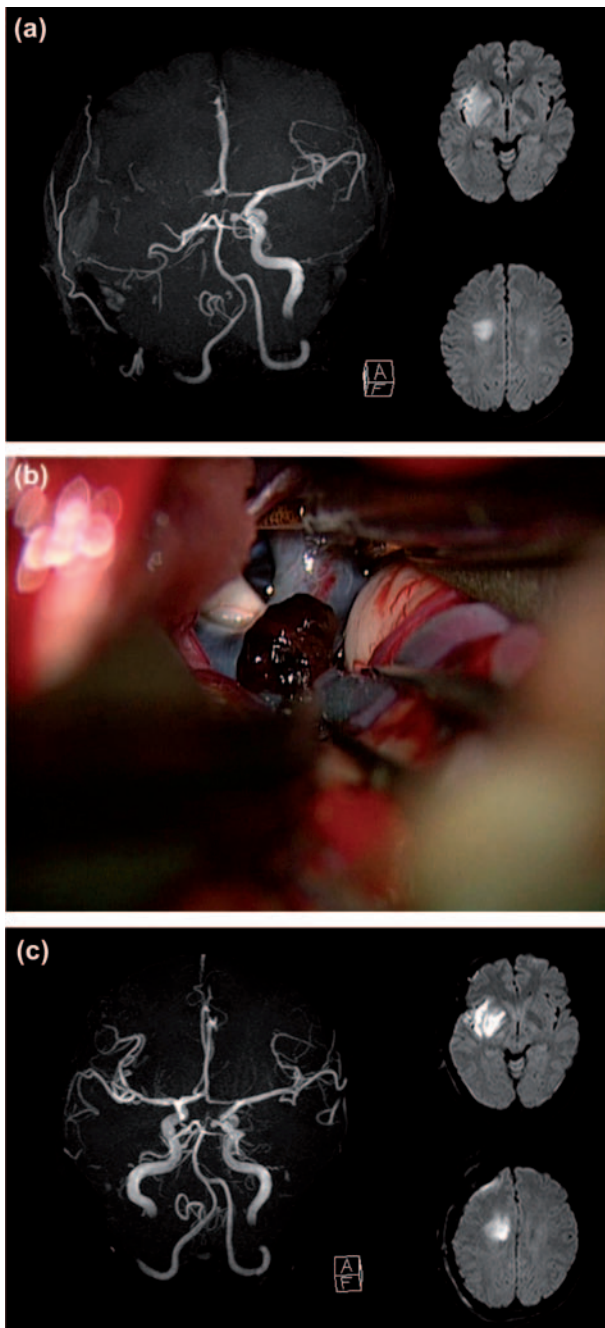


Fig. 2. Preoperative MRA and DWI (a) of a 36-year-old woman showing right ICA occlusion and an ischaemic lesion in the right insular cortex and basal ganglia. Intraoperative photograph (b) showing bluish discoloration of the occluded right ICA terminus, A1 and M1 and embolus being extracted via the arteriotomy site at the proximal M1 just distal to the ICA bifurcation. Postoperative MRA and DWI (c) demonstrating complete recanalization of the right ICA and no additional ischaemic lesions.

treatment using intravenous and intra-arterial thrombolysis has been associated with low recanalization rates (approximately 20%). MERCI embolectomy alone achieved around 45%, and MERCI embolectomy combined with intra-arterial thrombolytics was associated up to 85% TIMI 2–3 recanalization rates, even though TIMI 3 revascularization comprised only 33% of these cases and was accompanied by a relatively high rate (7.5%) of PH-2 haemorrhage.<sup>17</sup> In the present series, there was an 83% TIMI 3 recanalization rate (five of six

patients) for those with ICA terminus occlusion, and PH-2 haemorrhage did not occur. Given the high clot burdens that can occur in the context of occlusion of the ICA terminus or proximal M1, surgical embolectomy might provide an advantage over an endovascular embolectomy device for revascularization of these segments.

This study also showed that surgical embolectomy for occlusion of large vessels of the anterior circulation can be performed with a safety profile that is similar to that observed for other endovascular methods. The rates of symptomatic intracranial bleeding with surgical embolectomy in our series did not exceed those (6.2–10%) associated with existing treatments for acute ischaemic stroke,<sup>1,2,5,7</sup> and only one (4.3%) patient in the present study developed haemorrhage that was associated with a neurologic deficit. By contrast, minor asymptomatic subarachnoid haemorrhage and sub-pial contusion in the medial surface of the frontal and temporal opercula were far more common (48%) due to invasive nature of the trans-Sylvian approach in the setting of acute ischaemia. These minor postoperative bleeds might be partially due to the postoperative use of anticoagulants, such as heparin and warfarin. However, early anticoagulation also reduces the incidence of recurrent emboli; in fact, none of the present patients experienced further embolic/thrombotic episodes over the three-month follow-up period. The spectrum of haemorrhagic transformation differs widely and may include some trivial haemorrhagic petechiae as well as PH with space-occupying effect. Among those haemorrhagic transformations, PH-2 is associated with a distinct radiologic profile (dense homogeneous haematoma occupying >30% of the ischaemic lesion volume with a significant space-occupying effect) and is independently associated with clinical deterioration and worse prognosis.<sup>18</sup> In the present series, PH-2 did not occur, which may be related to the fact that thrombolytic drugs were not utilized. Three (13%) cases developed brain oedema secondary to massive and progressive infarction of the affected vessel area and required decompressive surgery on postoperative day 1. These cases comprised one patient who underwent surgical embolectomy based on MRA–DWI mismatch and who experienced unsuccessful recanalization, and two patients with pacemakers who underwent successful surgical embolectomy based on CT findings. Notably, in the 18 patients who underwent surgical embolectomy based on MRA–DWI mismatch and had successful recanalization, no significant additional confluent ischaemic lesions were found on postoperative DWI. Of these 18 patients, time to recanalization after symptom onset was 4–6 h in 10 patients and was later than 6 h in six patients. These data suggest that patient selection for surgical embolectomy based on MRA–DWI mismatch is associated with a reduced rate of complications and a longer therapeutic time window.

Endovascular methods have selected advantages over surgical embolectomy. First, surgical embolectomy, due to its open invasive nature, might have disadvantage to provide alternative and synergistic method for flow restoration when intravenous thrombolysis fails. Further study is required to determine whether surgical embolectomy can be pursued as an adjunct to intravenous thrombolysis.

Second, time to reperfusion is longer for surgical embolectomy when compared with endovascular methods. This is because endovascular methods can achieve recanalization essentially within the same procedure and immediately following diagnostic DSA, while surgical embolectomy requires transfer of the patient from the radiology suite to the operating room. To minimize time loss (especially in the 10 more recent cases within our 20 consecutive patients who were candidates for MRI-based imaging), we made a direct effort to transport patients directly from the MRI suite to the operating room. Standard frontotemporal craniotomy with minimal haemostasis required about 20 min, and we were able to accomplish recanalization in an average of 70 min after initiation of the operation, which may compare favourably with the time to recanalization associated with endovascular methods.

With regard to technical aspects, several series investigating surgical embolectomy have adopted the use of longitudinal arteriotomy.<sup>8–10</sup> The present study utilized a transverse arteriotomy for several reasons. First, many patients have underlying atherosclerosis at the preferred site for arteriotomy during surgical embolectomy; with a transverse arteriotomy, use of intermittent sutures with thick bites can prevent dissection of the plaque and enable creation of an arteriotomy repair with sufficient radius (albeit with slight curving and shortening). In fact, mid- to long-term follow-up of the arteriotomy site by MRA (mean, 6 months; range, 0.5–31 months; n = 18) did not show significant stenosis in our series. In addition, longitudinal arteriotomy resulted in significantly greater stenosis when compared with transverse arteriotomy in dogs.<sup>19</sup> Second, with transverse arteriotomy, multiple tandem arteriotomies can be performed to extract long and/or fragmented clot. In fact, we utilized two arteriotomies in eight patients and three arteriotomies in two patients. The incidence of stenosis secondary to tandem arteriotomy is apparently lower when using transverse arteriotomy than with longitudinal arteriotomy. Third, when sludging results in re-occlusion of the embolectomy site, it is easier to reopen/reclose a transverse arteriotomy than to do so with a longitudinal arteriotomy. In the present study, three cases required reopening of the arteriotomy, flushing of sludge by anterograde and retrograde flow, and resuturing with larger bites. Further, all three cases had good mid- to long-term patency.

The retrospective nature of data acquisition represents the major limitation of this study. The TIMI recanalization outcomes as well as the NIHSS scores and mRS scores might have been overestimated because the surgeon and treating physician determined those scores. However, it is conceivable that very low flow may not be detectable using an MRA despite an open vessel. This may theoretically lead to an underestimation of TIMI flow grade when compared with that estimated by DSA.<sup>13</sup> Thus, we believe that the possibility of overestimating final recanalization status was very low in the present study, as the majority of final recanalization statuses was determined using MRA.

The major determinant of NIHSS score improvement of more than 8 points is motor function improvement, which is relatively easy and straightforward to assess. Thus, it is

unlikely that functional measurements were biased in this study. The traditional, dichotomized, primary functional outcomes used in acute stroke trials may not capture clinically meaningful improvements that fall short of the defined outcomes.<sup>20</sup> Our patients had higher age (median, 80 years) and a higher presenting NIHSS score (median, 21 points) when compared with those in populations from published series. Both variables are associated with a worse outcome, and these variables may have played a role in the relatively low rate of good mRS score (0–2) at 3 months (30%). Considering the high baseline stroke severity, we also evaluated the rate of mRS score of 3 at 3 months (35%) and NIHSS score improvement more than 8 points at 1 month (70%) to elucidate the therapeutic effect.

## Conclusions

Surgical embolectomy for embolic occlusion of large vessels in the anterior circulation was associated with a high complete recanalization rate and an acceptable safety profile. Patient selection based on MRA–DWI mismatch was associated with a reduced complication rate and a longer therapeutic time window. Surgical embolectomy may be better than endovascular embolectomy device in achieving complete recanalization of large vascular segments, particularly those with high clot burdens, such as at the ICA terminus. Although this approach is associated with a relatively high risk of minimal to moderate postoperative bleed around the manipulated Sylvian fissure, the dismal natural history of this disease when not recanalized may warrant this aggressive approach.

**Declaration of interest:** The authors report no conflict of interest. The authors alone are responsible for the content and writing of the paper.

## References

1. Furlan A, Higashida R, Wechsler L, *et al.* Intra-arterial prourokinase for acute ischemic stroke. The PROACT II study: a randomized controlled trial. PROlyse in Acute Cerebral Thromboembolism. *JAMA* 1999;282:2003–11.
2. Ogawa A, Mori E, Minematsu K, *et al.* Randomized trial of intraarterial infusion of urokinase within 6 hours of middle cerebral artery stroke: the Middle Cerebral Artery Embolism Local Fibrinolytic Intervention Trial (MELT) Japan. *Stroke* 2007;38:2633–9.
3. Smith WS, Lev MH, English JD, *et al.* Significance of large vessel intracranial occlusion causing acute ischemic stroke and TIA. *Stroke* 2009;40:3834–40.
4. Bhatia R, Hill MD, Shobha N, *et al.* Low rates of acute recanalization with intravenous recombinant tissue plasminogen activator in ischemic stroke. Real-world experience and a call for action. *Stroke* 2010;41:2254–8.
5. Shi ZS, Loh Y, Walker G, Duckwiler GR; MERCI and Multi-MERCI Investigators. Clinical outcome in middle cerebral artery trunk occlusions versus secondary division occlusions after Mechanical Thrombectomy. Pooled analysis of the Mechanical Embolus Removal in Cerebral Ischemia (MERCI) and Multi MERCI trials. *Stroke* 2010;41:953–60.
6. Saqqur M, Uchino K, Demchuk AM, *et al.* Site of arterial occlusion identified by transcranial Doppler predicts the response to intravenous thrombolysis for stroke. *Stroke* 2007;38:948–54.
7. Smith WS, Sung G, Saver J, *et al.* Mechanical thrombectomy for acute ischemic stroke: final result of the Multi MERCI trial. *Stroke* 2008;39:1205–12.

8. Horiuchi T, Nitta J, Sakai K, Tanaka Y, Hongo K. Emergency embolectomy for treatment of acute middle cerebral artery occlusion. *J Neurosurg* 2007;106:257-62.
9. Meyer FB, Piepgras DG, Sundt TM, Yanagihara T. Emergency embolectomy for acute occlusion of the middle cerebral artery. *J Neurosurg* 1985;62:639-47.
10. Park J, Hwang YH, Kim Y. Extended superciliary approach for middle cerebral artery embolectomy after unsuccessful endovascular recanalization therapy: technical note. *Neurosurgery* 2009;65:1191-4.
11. Lansberg MG, Thijs VN, Bammer R, et al. The MRA-DWI mismatch identifies patients with stroke who are likely to benefit from reperfusion. *Stroke* 2008;39:2491-6.
12. TIMI Study Group. The Thrombolysis in Myocardial Infarction (TIMI) trial. Phase I findings. *N Engl J Med* 1985;312:932-6.
13. Neumann-Haefelin T, de Rochemont M, Fiebich JB, et al.; Kompetenznetz Schlaganfall Study Group. Effect of incomplete (spontaneous and postthrombolytic) recanalization after middle cerebral artery occlusion. A magnetic resonance imaging study. *Stroke* 2004;35:109-15.
14. Hacke W, Kaste M, Fieschi C, et al. Randomized double-blind placebo-controlled trial of thrombolytic therapy with intravenous alteplase in acute ischaemic stroke (ECASS II). *Lancet* 1998;352:1245-51.
15. Larrue V, von Kummer R, Müller A, et al. Risk factor for severe hemorrhagic transformation in ischemic stroke patients treated with recombinant tissue plasminogen activator. A secondary analysis of the European-Australasian Acute Stroke Study (ECASS II). *Stroke* 2001;32:438-41.
16. Abou-Chebl A. Endovascular treatment of acute ischemic stroke may be safely performed with no time window limit in appropriately selected patients. *Stroke* 2010;41:1996-2000.
17. Lin R, Vora N, Zaidi S, et al. Mechanical approaches combined with intraarterial pharmacological therapy are associated with higher recanalization rates than either intervention alone in revascularization of acute carotid terminus occlusion. *Stroke* 2009;40:2092-7.
18. Berger C, Fiorelli M, Steiner T, et al. Hemorrhagic Transformation of ischemic brain tissue. Asymptomatic or Symptomatic? *Stroke* 2001;32:1330-5.
19. Dickson CS, Magovern JA. Transverse versus longitudinal arteriotomy: an experimental study in dogs. *J Vasc Surg* 1991;14:181-3.
20. Bruno A, Saha C, Williams LS. Using change in the National Institute of Health Stroke Scale to measure treatment effect in acute stroke trials. *Stroke* 2006;37:920-1.



Copyright of British Journal of Neurosurgery is the property of Taylor & Francis Ltd and its content may not be copied or emailed to multiple sites or posted to a listserv without the copyright holder's express written permission. However, users may print, download, or email articles for individual use.