

Treatment of a carotid cavernous fistula via direct transovale cavernous sinus puncture

Technical note

ALBERTO GIL, M.D.,¹ LUIS LÓPEZ-IBOR, M.D.,¹ GERARDO LOPEZ-FLORES, M.D., PH.D.,²
HUGO CUELLAR, M.D.,³ EDUARDO MURIAS, M.D., PH.D.,⁴
AND GREGORIO RODRÍGUEZ-BOTO, M.D., PH.D.⁵

¹Interventional Neuroradiology Unit and ⁵Neurosurgery Service, Hospital Clínico San Carlos; ²Neurosurgery Service, Hospital San Francisco Asís, Madrid; ⁴Interventional Neuroradiology Unit, Hospital Universitario Central de Asturias, Oviedo, Spain; and ³Interventional Neuroradiology Section, Departments of Neurosurgery and Radiology, LSU Health Sciences Center, Shreveport, Louisiana

Endovascular treatment is the treatment of choice for indirect carotid cavernous fistulas (CCFs). Direct surgical obliteration of CCFs is recommended in highly symptomatic patients or in those with an aggressive pattern of venous drainage. However, this is a technically challenging approach associated with significant procedural morbidity. The authors present a case in which they decided to attempt a novel access to the cavernous sinus through the foramen ovale before recommending surgery for an otherwise untreatable dural CCF.

This 52-year-old man with an indirect CCF and neurological deficit had undergone several attempts to embolize the shunt by means of the standard approaches. Ultimately direct cavernous sinus access was obtained through the foramen ovale, resulting in complete obliteration of the shunt. The occlusion was radiographically stable at the 6-month follow-up evaluation, and the patient has remained asymptomatic. Percutaneous transovale puncture of a CCF is a feasible alternative to accessing the cavernous sinus when traditional transvenous catheterization or direct superior ophthalmic vein approach is not possible.

(<http://thejns.org/doi/abs/10.3171/2013.4.JNS121504>)

KEY WORDS • carotid cavernous fistula • direct puncture • embolization •
foramen ovale • cavernous sinus • vascular disorders

ENDOVASCULAR treatment is the treatment of choice for indirect carotid cavernous fistulas (CCFs). Usually, the pathological cavernous sinus is occluded through the inferior petrosal sinus. In cases of failure of the transvenous approach, alternatives include percutaneous puncture of accessible veins, such as the superior ophthalmic vein. However, when these structures are not patent, direct surgical exposure of the cavernous sinus is required, especially in highly symptomatic patients or in those with an aggressive pattern of venous drainage. In one such patient, prior to undertaking an open surgical

approach we attempted a novel access to the cavernous sinus through the foramen ovale. The procedure was carried out using simultaneous biplanar fluoroscopic guidance, and occlusion of the fistula was achieved. We discuss this new percutaneous technique as an alternative to direct surgery for the treatment of indirect CCF when the endovascular or percutaneous approaches fail.

Illustrative Case

This 52-year-old man was referred to our institution for a chronic symptomatic right dural CCF. The lesion was treated unsuccessfully several times at another institution. At admission, he was being treated with 600 mg per day

Abbreviations used in this paper: AP = anteroposterior; CCF = carotid cavernous fistula; ICA = internal carotid artery.

of carbamazepine, due to left temporal lobe seizures associated with the abnormal cortical venous drainage of the fistula. A cerebral angiogram revealed a dural right CCF filling from the dural branches of the right external and internal carotid arteries and draining to the contralateral basal vein of Rosenthal through the basilar plexus (Fig. 1). Although the inferior petrosal sinus did not appear patent on the angiogram, our first attempt to occlude the fistula was made through this route. The procedure was unsuccessful, and radiosurgery was performed after discharge. There was no radiological or symptomatic improvement at 2-year follow-up. A percutaneous puncture of the foramen ovale was attempted due to failure of all other nonsurgical methods (Fig. 2).

Technique

After induction of general anesthesia, the patient's head was secured to the angiography table. A 6-Fr guiding catheter was inserted in the right ICA through a right femoral artery approach for angiographic guidance and to navigate a temporary occlusion balloon along the cavernous segment of the ICA. A percutaneous puncture of the foramen ovale was performed according to the Mullan-Lichter technique¹⁷ with a 14-gauge needle (Fig. 3). The needle was slowly advanced through the right foramen ovale under simultaneous biplanar fluoroscopic guidance. The lateral fluoroscopic image was used to determine the depth of the needle. After the stylet was retrieved, a 20-gauge spinal

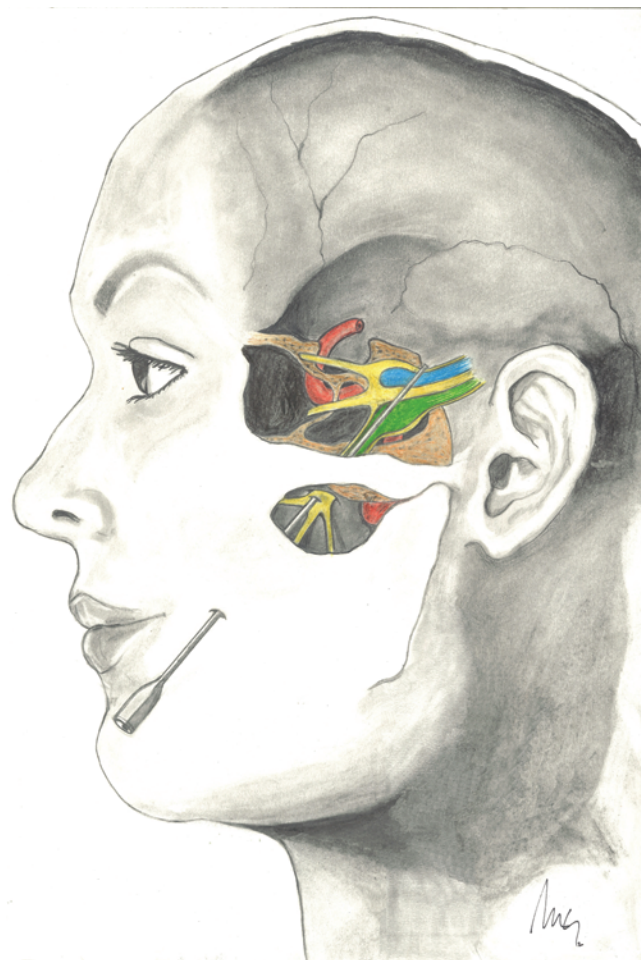

FIG. 2. Artist's illustration of the direct transovale cavernous sinus puncture. Printed with permission of Marcos Gil.

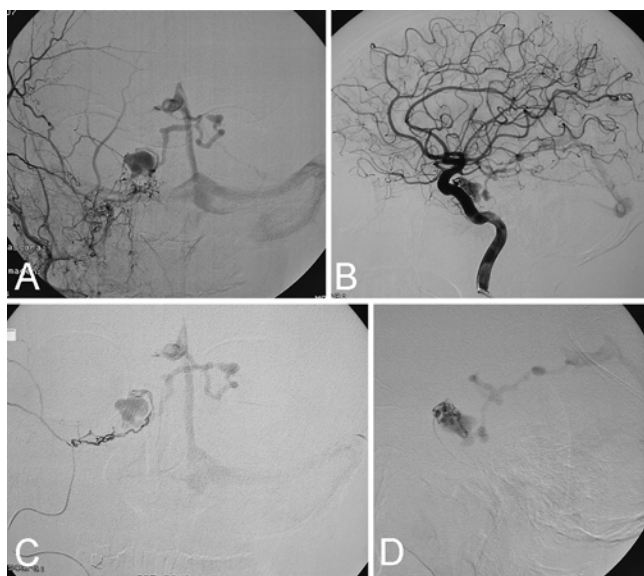


FIG. 1. **A:** Right external carotid artery angiogram, AP view, showing a right dural CCF filling from distal branches of the internal maxillary artery and draining to the left basal vein of Rosenthal. **B:** Right ICA angiogram, lateral view, showing small dural branches supplying the fistula. **C:** Superselective left middle meningeal artery angiogram, AP view, showing the contralateral venous drainage. Due to the small size of the distal branches, a more distal position of the microcatheter could not be achieved. **D:** Superselective left meningohypophysial trunk angiogram, lateral view, showing exclusive venous drainage of the fistula into the deep venous system. Embolization from this point was not considered because of the potential risk of reflux of embolic agents into the ICA and intracranial circulation.

needle, preshaped with a 15° curve in its distal portion, was inserted through the trocar to perforate the external dural layer of the cavernous sinus (Fig. 3). The direction of the tip of the needle was controlled under simultaneous biplanar fluoroscopy. When the pathological cavernous sinus was reached, the stylet was removed from the spinal needle and a 0.012-inch nitinol guidewire was advanced into the cavernous sinus (Fig. 4) with the objective of introducing a

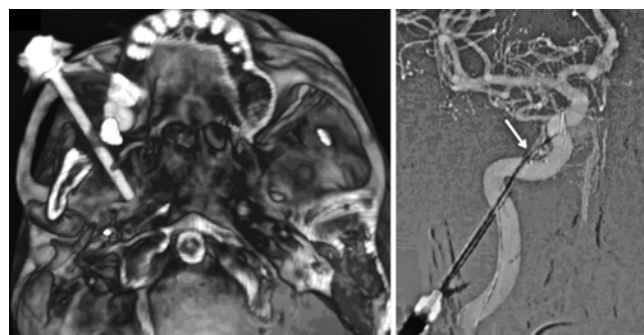


FIG. 3. **Left:** Detail of the 3D volume rendering reconstruction of the access through the foramen ovale, during the procedure. **Right:** Right ICA roadmap image, AP view, showing the preshaped 20-gauge spinal needle (arrow) inside the 14-gauge trocar.

Direct transovale cavernous sinus puncture

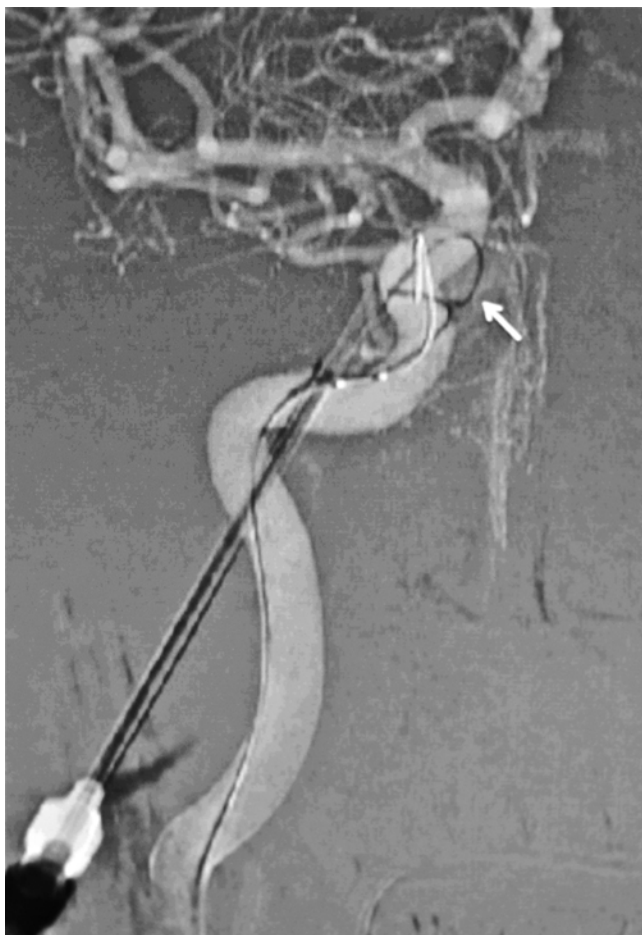

FIG. 4. Right ICA roadmap image showing the 0.012-inch guidewire inside the fistula (arrow).

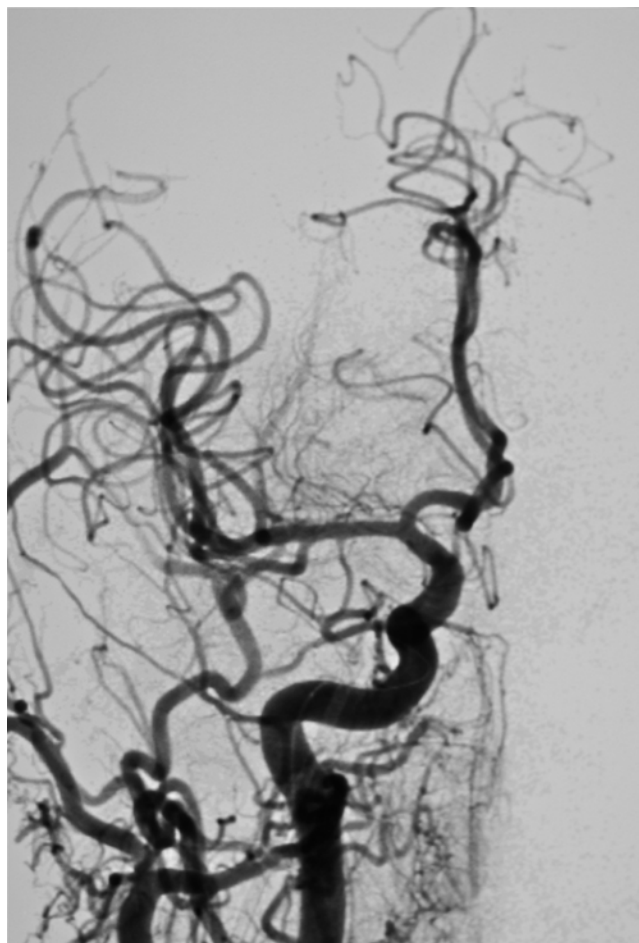


FIG. 5. Right common carotid artery angiogram showing occlusion of the fistula.

microcatheter. During these maneuvers, a right ICA angiogram was performed to confirm the position of the guidewire. The angiogram revealed a complete occlusion of the fistula (Fig. 5). With evidence of occlusion of the CCF, we terminated the procedure and removed the spinal needle and trocar carefully. An intraoperative CT scan was performed to rule out complications. The postoperative course was uneventful. The patient was transferred to the intensive care unit for 24 hours and then to the ward to be discharged a week after the procedure. A 6-month follow-up cerebral angiogram showed persistent occlusion of the fistula.

Discussion

Endovascular treatment of indirect CCFs is usually efficient and safe. The venous access to the cavernous sinus, first described by Debrun et al.⁵ is the treatment of choice. Indirect CCFs are frequently associated with numerous small-caliber meningeal branches, making the arterial approach much less effective. In a majority of cases, the fistula can be treated by occluding the pathological cavernous sinus through a transvenous embolization via the inferior petrosal sinus. This can be done even in cases of local thrombosis.^{8,9} However, in some occasions, the inferior petrosal sinus cannot be catheterized; alternative

venous routes have been described, including the contralateral inferior petrosal sinus, the superior petrosal sinus, and the transverse or facial veins.¹⁶

If these venous approaches fail, other minimally invasive alternatives may be used. Direct puncture of the facial, angular, and superior ophthalmic veins can be performed. These approaches are particularly useful if the veins are angiographically patent and wide enough, but they are not viable options when the veins are too tortuous,¹⁴ stenotic, or thrombosed.^{11,15,19} In our patient, the inferior petrosal sinus was thrombosed, and the alternative veins were not visualized angiographically. Surgical exposure of the superior ophthalmic vein to perform direct puncture has also been described and can be particularly useful if the facial and angular vein are not visualized or prove to be too tortuous, but again the presence of a wide superior ophthalmic vein is needed.^{7,20} When these techniques fail, a transorbital puncture of the cavernous sinus can obviate the need for a craniotomy. Although its use in the treatment of CCF has been described,¹ this technique can be complicated by severe intraorbital hemorrhage.^{6,24} Other potential risks of this procedure include nerve damage, globe puncture, infection, and laceration of the ICA resulting in direct CCF.⁷

When the endovascular or percutaneous options fail,

and especially in those patients with rapid deterioration of ocular symptoms or in patients with an increased risk of bleeding related to venous reflux into cortical or deep veins,³ as in our patient, a direct surgical approach may be the only option. However, this is a technically challenging approach and is associated with significant procedural morbidity.^{4,10}

The foramen ovale is a well-described route of percutaneous access to perform minimally invasive procedures in the trigeminal cistern^{2,23} for the treatment of trigeminal neuralgia.^{2,12,18,22} It has also been used to access the middle cranial fossa to place electrodes in patients with temporal lobe epilepsy.^{13,22} Exploiting its close anatomical relationship with the lateral wall of the cavernous segment of the ICA, biopsy of cavernous sinus tumors via the foramen ovale has also been reported.^{21,25}

However, to access the cavernous sinus through the foramen ovale, it is necessary to modify the Mullan-Lichter technique. First, a longer 20-gauge spinal needle is used inside the trocar to reach the cavernous sinus. Since the direction along the foramen ovale does not allow direct access to the cavernous sinus, a change in the direction of the distal aspect of the spinal needle is necessary. Preshaping the distal aspect of the spinal needle with a 15° curve allows one to enter the ipsilateral cavernous sinus, which lies medial to the foramen ovale. Finally, an endovascular occlusion balloon is positioned in the cavernous ICA, as ICA injury has been reported as a complication of foramen ovale puncture. In our case, spontaneous occlusion of the shunt was probably due to cavernous sinus thrombosis. Although no hematoma was seen on posttreatment CT of the head, compression due to a small intradural hematoma could also be responsible for the occluded shunt. The occlusion was stable radiographically at the 6-month follow-up examination despite the fact that no embolic material was used. Clinically, the patient remains asymptomatic. We will continue to follow the patient with periodic clinical examinations and imaging studies.

Conclusions

Percutaneous transfacial puncture of a CCF via the foramen ovale is a feasible alternative to accessing the cavernous sinus when traditional transvenous catheterization or a direct superior ophthalmic vein approach is not possible. Spontaneous obliteration of a CCF by sinus thrombosis may result from cavernous sinus catheterization. Further studies are needed to understand the complex arterial and venous relationships that exist at the internal aspect of the foramen ovale in patients with CCFs. An elucidation of these relationships may allow safe and easy implementation of a percutaneous transovale approach to the cavernous sinus.

Disclosure

The authors report no conflict of interest concerning the materials or methods used in this study or the findings specified in this paper.

Author contributions to the study and manuscript preparation

include the following. Conception and design: Gil, López-Ibor, Murias, Lopez-Flores. Acquisition of data: Gil, López-Ibor, Murias. Analysis and interpretation of data: Gil, Rodríguez-Boto. Drafting the article: Gil, Cuellar. Critically revising the article: all authors. Reviewed submitted version of manuscript: all authors. Approved the final version of the manuscript on behalf of all authors: Gil. Administrative/technical/material support: Gil. Study supervision: Gil.

References

1. Benndorf G, Bender A, Campi A, Menneking H, Lanksch WR: Treatment of a cavernous sinus dural arteriovenous fistula by deep orbital puncture of the superior ophthalmic vein. **Neuroradiology** **43**:499–502, 2001
2. Bowsher D: Trigeminal neuralgia: an anatomically oriented review. **Clin Anat** **10**:409–415, 1997
3. Cognard C, Gobin YP, Pierot L, Bailly AL, Houdart E, Casasco A, et al: Cerebral dural arteriovenous fistulas: clinical and angiographic correlation with a revised classification of venous drainage. **Radiology** **194**:671–680, 1995
4. Day JD, Fukushima T: Direct microsurgery of dural arteriovenous malformation type carotid-cavernous sinus fistulas: indications, technique, and results. **Neurosurgery** **41**:1119–1126, 1997
5. Debrun G, Lacour P, Vinuela F, Fox A, Drake CG, Caron JP: Treatment of 54 traumatic carotid-cavernous fistulas. **J Neurosurg** **55**:678–692, 1981
6. Elhammady MS, Peterson EC, Aziz-Sultan MA: Onyx embolization of a carotid cavernous fistula via direct transorbital puncture. Case report. **J Neurosurg** **114**:129–132, 2011
7. Goldberg RA, Goldey SH, Duckwiler G, Vinuela F: Management of cavernous sinus-dural fistulas. Indications and techniques for primary embolization via the superior ophthalmic vein. **Arch Ophthalmol** **114**:707–714, 1996
8. Halbach VV, Higashida RT, Hieshima GB, Hardin CW, Priram H: Transvenous embolization of dural fistulas involving the cavernous sinus. **AJNR Am J Neuroradiol** **10**:377–383, 1989
9. Halbach VV, Higashida RT, Hieshima GB, Hardin CW, Yang PJ: Transvenous embolization of direct carotid cavernous fistulas. **AJNR Am J Neuroradiol** **9**:741–747, 1988
10. Hamby WB, Dohn DF: Carotid-cavernous fistulas: report of thirty-six cases and discussion of their management. **Clin Neurosurg** **11**:150–170, 1964
11. Jahan R, Gobin YP, Glenn B, Duckwiler GR, Viñuela F: Transvenous embolization of a dural arteriovenous fistula of the cavernous sinus through the contralateral pterygoid plexus. **Neuroradiology** **40**:189–193, 1998
12. Jho HD, Lunsford LD: Percutaneous retrogasserian glycerol rhizotomy. Current technique and results. **Neurosurg Clin N Am** **8**:63–74, 1997
13. Kim OJ, Ahn JY, Lee BI: Analysis of electrical discharges made with the foramen ovale electrode recording technique in mesial temporal lobe epilepsy patients. **J Clin Neurophysiol** **21**:391–398, 2004
14. Kurata A, Suzuki S, Iwamoto K, Miyazaki T, Inukai M, Abe K, et al: Direct-puncture approach to the extraconal portion of the superior ophthalmic vein for carotid cavernous fistulae. **Neuroradiology** **51**:755–759, 2009
15. Lewis AI, Tomsick TA, Tew JM Jr: Management of 100 consecutive direct carotid-cavernous fistulas: results of treatment with detachable balloons. **Neurosurgery** **36**:239–245, 1995
16. Mounayer C, Piotin M, Spelle L, Moret J: Superior petrosal sinus catheterization for transvenous embolization of a dural carotid cavernous sinus fistula. **AJNR Am J Neuroradiol** **23**:1153–1155, 2002
17. Mullan S, Lichtor T: Percutaneous microcompression of the trigeminal ganglion for trigeminal neuralgia. **J Neurosurg** **59**:1007–1012, 1983

Direct transovale cavernous sinus puncture

18. Nugent GR: Radiofrequency treatment of trigeminal neuralgia using a cordotomy-type electrode. A method. **Neurosurg Clin N Am** **8**:41–52, 1997
19. Quiñones D, Duckwiler G, Gobin PY, Goldberg RA, Viñuela F: Embolization of dural cavernous fistulas via superior ophthalmic vein approach. **AJNR Am J Neuroradiol** **18**:921–928, 1997
20. Reis CV, Gonzalez FL, Zabramski JM, Hassan A, Deshmukh P, Albuquerque FC, et al: Anatomy of the superior ophthalmic vein approach for direct endovascular access to vascular lesions of the orbit and cavernous sinus. **Neurosurgery** **64** (5 Suppl 2):318–323, 2009
21. Sindou M, Chavez JM, Saint Pierre G, Jouvét A: Percutaneous biopsy of cavernous sinus tumors through the foramen ovale. **Neurosurgery** **40**:106–111, 1997
22. Sweet WH: Faciocephalic pain, in Apuzzo MLJ (ed): **Brain Surgery Complication Avoidance and Management**. New York: Churchill Livingstone, 1993, pp 2053–2083
23. Taha JM, Tew JM Jr: Treatment of trigeminal neuralgia by percutaneous radiofrequency rhizotomy. **Neurosurg Clin N Am** **8**:31–39, 1997
24. White JB, Layton KF, Evans AJ, Tong FC, Jensen ME, Kallmes DF, et al: Transorbital puncture for the treatment of cavernous sinus dural arteriovenous fistulas. **AJNR Am J Neuroradiol** **28**:1415–1417, 2007
25. Yi W, Ohman K, Brännström T, Bergenheim AT: Percutaneous biopsy of cavernous sinus tumour via the foramen ovale. **Acta Neurochir (Wien)** **151**:401–407, 2009

Manuscript submitted August 8, 2012.

Accepted April 11, 2013.

Please include this information when citing this paper: published online May 10, 2013; DOI: 10.3171/2013.4.JNS121504.

Address correspondence to: Alberto Gil, M.D., Interventional Neuroradiology, Hospital Clinico San Carlos, Calle de Profesor Martín Lagos, S/N, Madrid 28040, Spain. email: agil_garcia@yahoo.com.