

Use of Electroconvulsive Therapy in the Presence of Arachnoid Cyst

A Case Report and Review of Existing Literature

Sandeep Grover, MD, Jitender Aneja, MD, Aakansha Singh, MBBS, and Neha Singla, MBBS

Abstract: A caution is advised for the use of electroconvulsive therapy (ECT) in patients with space-occupying intracranial lesions. The use of ECT in the presence of arachnoid cyst has been reported only in 10 cases in the literature. Here, we report a case of severe depression with psychotic symptoms who was found to have an arachnoid cyst of 3.4×1.6 cm in the left temporal region. The patient received a course of 12 ECT treatments without any complications and had significant improvement in symptoms. Magnetic resonance imaging after completion of ECT did not reveal any change in size of the arachnoid cyst.

Key Words: ECT, arachnoid cyst

(*J ECT* 2013;29:e38–e39)

Dear Sir:

Arachnoid cysts are space-occupying intracranial lesions that are formed because of the separation of the 2 layers of arachnoid membrane due to abnormal embryonic development and usually consist of a collection of cerebrospinal fluid. Usually, arachnoid cysts are asymptomatic, but at times, these may enlarge to cause mild symptoms such as headache or severe complications due to localized pressure effects such as hemiparesis or seizures.^{1,2}

There are limited data with regard to the use of electroconvulsive therapy (ECT) in patients with arachnoid cyst with data limited to only 10 cases reported in 5 publications.^{1–5} Here, we present a case in which ECT was used successfully to treat a patient with severe depression with psychotic symptoms and review the existing literature.

CASE REPORT

Mrs. V, a 57-year-old illiterate widow presented to the inpatient unit with an illness of 6 months duration characterized by sadness of mood, irritability, anhedonia, poor interaction, reduced sleep in the form of difficulty in falling asleep and early morning awakening, ideas of worthlessness, hopelessness, death wish, suicidal ideations, 2 suicidal attempts, visual and auditory hallucinations, delusions of persecution, poverty, nihilism and hypochondriasis, psychomotor retardation, marked weight loss, and refusal to eat. She had attempted suicide for the second time just before hospitalization. Treatment history revealed that she was treated with escitalopram 10 mg/d with no much improvement.

From the Department of Psychiatry, Postgraduate Institute of Medical Education and Research, Chandigarh, India.

Received for publication January 27, 2013; accepted February 1, 2013.

Reprints: Sandeep Grover, MD, Department of Psychiatry, Postgraduate

Institute of Medical Education and Research, Chandigarh 160012,

India (e-mail: drsandeepg2002@yahoo.com).

The authors have no conflicts of interest or financial disclosures to report.

Copyright © 2013 by Lippincott Williams & Wilkins

DOI: 10.1097/YCT.0b013e31828b3546

Medical history revealed hypertension. On mental state examination, she was found to have marked psychomotor retardation, sad mood, delusion of poverty, guilt, and negation of body organs. She was diagnosed with severe depression with psychotic symptoms. A 2-dimensional echocardiography did not reveal any abnormality. Examination of fundus by an ophthalmologist did not reveal any evidence of raised intracranial pressure. Her hemogram, serum electrolytes, renal function test, liver function test, chest x-ray (posterior-anterior view), and computed tomography of the brain did not reveal any abnormality. On Hamilton Depression Rating Scale, she scored 31 at the time of admission.

In view of severe depression, suicidal attempts, marked psychomotor retardation, and refusal to eat, ECT was considered. Family members received explanation about the need of ECT, and they provided written proxy informed consent for giving ECT. Opinions of the cardiologist and neurologist were taken who opined that the patient can be safely treated with modified ECT.

She was given bilateral modified ECT with the use of glycopyrolate as premedication, thiopentone as an inducing agent, and suxamethonium as muscle relaxant. After 24 hours of first ECT treatment, the patient developed an episode of fluctuating sensorium lasting for approximately 3 hours after which a magnetic resonance imaging (MRI) scan of the brain was done, which revealed an arachnoid cyst in the left temporal region measuring 3.4×1.6 cm (Fig. 1). A neurologist and a neurosurgeon opined that ECT can be continued with proper monitoring. The family received an explanation about the clinical situation and a high risk, informed consent was taken, and ECT was continued. Over the period of 4 weeks, she received a total of 12 ECT treatments with no further complications and achieved remission (the Hamilton Depression Rating Scale was reduced to 4) with regard to her depressive symptoms. She was discharged from the inpatient unit after a week of achieving remission. She continued to maintain remission during the follow-up duration of 6 months without any further complications, and assessment of cognitive functions at 3 months after ECT revealed the presence of moderate deficits on immediate and delayed recall. Repeat brain MRI at 6 months after ECT did not show any change in the dimensions of the arachnoid cyst.

DISCUSSION

Data with respect to use of ECT in patients with arachnoid cyst are limited to just 10 cases.^{1–5} In one of the first case reports, Escalona et al¹ reported the use of ECT in a patient with bipolar depression with arachnoid cyst in the area of left sylvian fissure. The patient received 11 ECT treatments without any complications and showed clinical improvement in symptoms, and post-ECT neuroimaging did not reveal any change in the size of the cyst. A case report highlighted the use of 9 ECT treatments in a patient with psychosis not responding to pharmacotherapy who was found to have a colloid cyst in the third

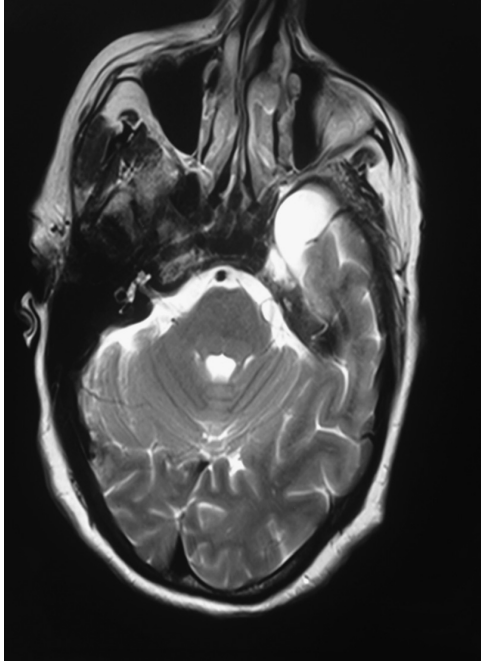


FIGURE 1. Magnetic resonance imaging scan showing the arachnoid cyst in the left anterior temporal region.

ventricle without raised intracranial pressure.² Another report documented the use of ECT in the presence of a 2.5×2.5 -cm arachnoid cyst in the anterior portion of the right temporal lobe. The patient was treated with 6 bilateral ECT treatments for her bipolar depression without any complication and showed improvement in her depressive symptoms.³ Perry et al⁴ reported 6 cases in which ECT was used in the presence of arachnoid cysts of different sizes at different locations in the brain. These patients received 1 to 21 ECT treatments without complications, but 1 patient refused ECT after only 1 ECT treatment, and 1

patient did not show improvement with ECT. In the most recent case report, 7 bilateral ECT treatments were administered to a patient of recurrent depressive disorder without any complications.⁵ Our case adds to the limited existing data and suggests that ECT can be safely administered in presence of arachnoid cyst, which was detected accidentally after an episode of altered sensorium after first ECT treatment.

It is to be remembered that some of the arachnoid cysts may be communicating with the surrounding cerebrospinal fluid, and hence, there is always a possibility of enlargement of the cyst during the rise in intracranial pressure during the course of ECT treatments. Hence, it is recommended that a close liaison with neurology and neurosurgery must be maintained while administering ECT. In the present case, there was 1 episode of altered sensorium after first ECT, which can be theoretically attributed to raised intracranial pressure. However, subsequent ECT treatments were not associated with any further complications. In 8 of the previous 10 reported cases, post-ECT MRI scan was not done. In the index case, an MRI scan 6 months after ECT did not reveal any increase in size of arachnoid cyst, which suggests that the use of ECT has no adverse effect on the size of arachnoid cyst.

REFERENCES

1. Escalona PR, Coffey CE, Maus-Feldman J. Electroconvulsive therapy in a depressed patient with an intracranial arachnoid cyst: a brain magnetic resonance imaging study. *Convuls Ther.* 1991;7:133–138.
2. Restifo S, Paterson R. Brief case report: uneventful electroconvulsive therapy in a patient with psychosis and coincidental colloid cyst of the third ventricle. *Aust N Z J Psychiatry.* 1999;33:603.
3. Hanretta AT, Akra I, Malek-Ahmadi P. Electroconvulsive therapy and arachnoid cysts. *J ECT.* 2007;23:126–127.
4. Perry CL, Lindell EP, Rasmussen KG. ECT in patients with arachnoid cysts. *J ECT.* 2007;23:36–37.
5. Desseilles M, Thiry JC, Monville JF, et al. Electroconvulsive Therapy for Depression in a patient with an intracranial arachnoid cyst. *J ECT.* 2009;25:64–66.