

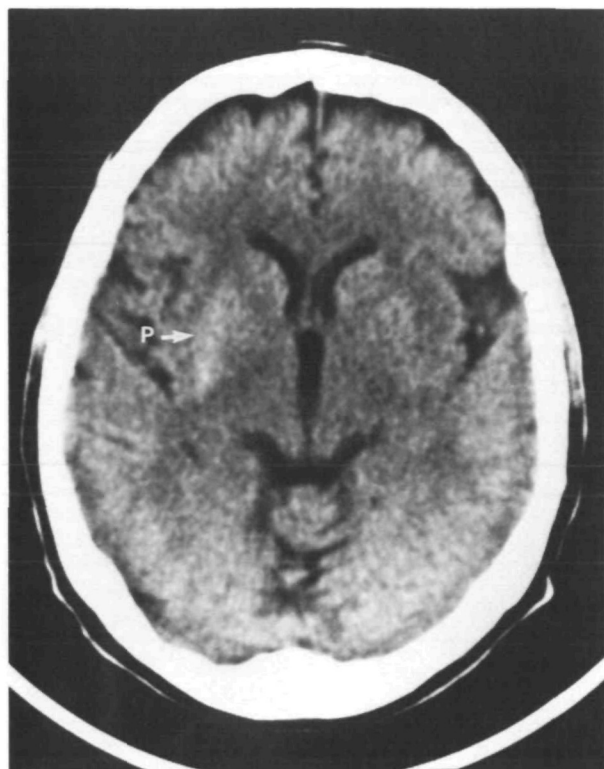

FIGURE 1. Unenhanced admission axial computed tomography through the basal ganglia.

Putaminal Hemorrhage Accompanied by Hemichorea-Hemiballism

To the Editor:

Hemichorea-hemiballism is a relatively rare syndrome described most often with lesions in the contralateral subthalamic nucleus and, less frequently, at other sites.¹ Hemichorea has also been reported as a rare manifestation of nonketotic hyperglycemia.² We report a case of acute hemichorea produced by a small hemorrhage or hemorrhagic infarct in the contralateral putamen. This case is noteworthy because hemorrhagic putaminal lesions infrequently produce hemichorea³ and because dyskinesia was associated with nonketotic hyperglycemia.

A 67-year-old right-handed male with insulin-dependent diabetes, hypertension, and past alcohol abuse noted the abrupt onset of involuntary movements involving the left arm and leg 4 days prior to admission. General examination was unremarkable with a blood pressure of 120/70 mm Hg. There was mild left supranuclear facial nerve weakness. Strength of extremities was normal. Constant choreiform movements involving the distal left arm and leg were seen with occasional ballistic components involving the proximal musculature. These movements disappeared during sleep. Except for mild symmetric distal loss of vibration, the neurologic examination was normal.

On admission, blood glucose was 610 mg/dl and calculated serum osmolality was 315 milliosmoles/l. The hyperglycemia resolved after administration of insulin and the remainder of the laboratory evaluation was normal.

Initial computerized tomography without contrast (Figure 1) showed slightly increased attenuation in the right putamen representing acute hemorrhage. Two weeks later, T1-weighted coronal magnetic resonance imaging (Figure 2) demonstrated increased signal in the right putamen, representing methemoglobin.

The abnormal movements resolved over the next 2 weeks following administration of 2 mg haloperidol three times a day and

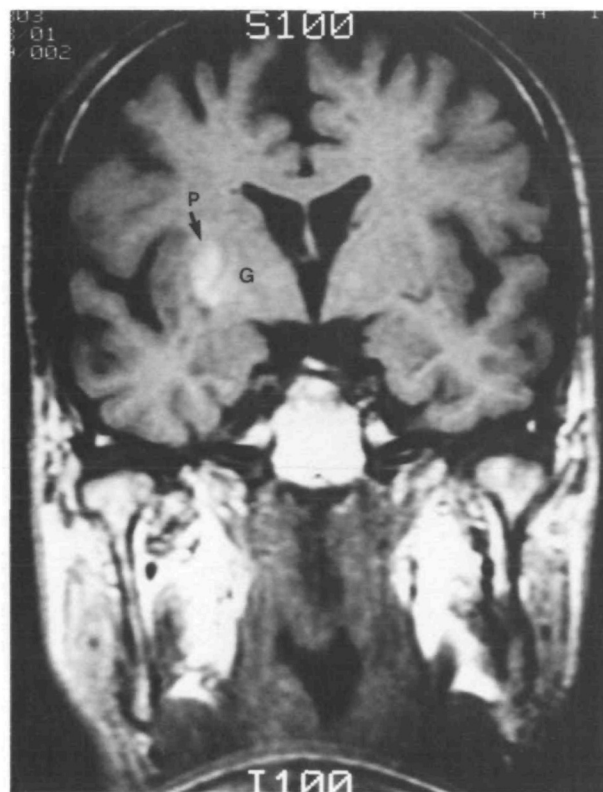


FIGURE 2. T1-weighted coronal magnetic resonance imaging scan through the basal ganglia 3 weeks after the acute event.

50 mg benadryl once a day. However, 3 weeks after initial presentation, this patient experienced abrupt recurrence of left hemichorea. Blood glucose was 597 mg/dl with no ketones in the serum. The next morning blood glucose was 235 mg/dl, and choreiform movements had resolved.

The majority of patients with hemichorea-hemiballism have vascular lesions, due usually to ischemia rather than hemorrhage or hemorrhagic infarct.⁴ Despite the high incidence of lacunar infarcts and hypertensive intracerebral hemorrhage in the basal ganglia, hemichorea-hemiballism is a rare presentation, probably because accompanying weakness masks manifestation of the abnormal movements.

Hemichorea-hemiballism has been described with lesions in the subthalamic nucleus, striatum, cerebral cortex, thalamus, diencephalon, and brain stem.¹ Based on a series of experiments in the monkey, in which stereotaxic lesions were placed in the subthalamic nucleus, Carpenter et al⁵ concluded that development of "choreoid-hyperkinesia" required an intact globus pallidus. Reviewing human cases of hemichorea, Martin inferred that choreic movements resulted when the globus pallidus was released from the inhibitory influence of the subthalamic nucleus.⁶ Results of an acute putaminal lesion suggest that the putamen similarly inhibits the globus pallidus and that removal of this inhibition leads to hemichorea,⁷ as demonstrated in the present case.

Interestingly, this patient had nonketotic hyperglycemia on both occasions that he presented with hemichorea. Both ketoacidosis and nonketotic hyperglycemia depress the Krebs cycle so that brain energy requirements must be met by alternate metabolic pathways such as increased rate of utilization of GABA to succinic acid via the GABA shunt.⁸ Depletion of striatal GABA in nonketotic hyperglycemia, either as a result of increased metabolic

consumption or secondary to local ischemia, may allow increased pallidal activity with resultant dyskinesia.

Irfan Altafullah, MD

Alvaro Pascual-Leone, MD

Kathy Duvall, MD

David C. Anderson, MD

Department of Neurology

Saul Taylor, MD

Department of Radiology

Hennepin County Medical Center

Minneapolis, Minnesota

References

1. Schwarz G, Barrows L: Hemiballism without involvement of Luys body. *Arch Neurol* 1960;2:420-434

2. Rector W, Herlong F, Moses H: Nonketotic hyperglycemia appearing as choreoathetosis or ballism. *Arch Intern Med* 1982; 142:154-155
3. Jones R Jr, Baker R, Kott S: Hypertensive putaminal hemorrhage presenting with hemichorea. *Stroke* 1985;16:130-131
4. Dewey R, Jankovic J Jr: Hemiballism-hemichorea: Clinical and pharmacologic findings in 21 patients. *Arch Neurol* 1989;46: 862-867
5. Carpenter M, Whittier J, Mettler F: Analysis of choreoid hyperkinesia in the rhesus monkey; surgical and pharmacological analyses of hyperkinesia resulting from lesions in the subthalamic nucleus of Luys. *J Comp Neurol* 1950;92:293-331
6. Martin J: Hemichorea (hemiballismus) without lesions of the corpus Luysii. *Brain* 1957;80:1-10
7. Crossman A, Sambrook M, Jackson A: Experimental hemichorea/hemiballismus in the monkey. *Brain* 1984;107:579-596
8. Guisado R, Arieff A: Neurologic manifestations of diabetic comas: Correlation with biochemical alterations in the brain. *Metabolism* 1975;24:655-679