

# Vascular dementia with left thalamic infarction: Neuropsychological and behavioral implications suggested by involvement of the thalamic nucleus and the remote effect on cerebral cortex. The Osaki–Tajiri project

Kenichi Meguro\*, Kyoko Akanuma, Yoshitaka Ouchi, Mitsue Meguro, Kei Nakamura, Satoshi Yamaguchi

Department of Geriatric Behavioral Neurology, Tohoku University Graduate School of Medicine, Sendai, Japan

## ARTICLE INFO

### Article history:

Received 5 August 2011

Received in revised form

16 November 2012

Accepted 19 December 2012

### Keywords:

Vascular dementia

Thalamus

Word fluency

Depressive state

Single photon emission computed tomography (SPECT)

Three-Dimensional Stereotaxic Surface Projection (3D-SSP)

## ABSTRACT

Vascular dementia (VaD) is a condition whereby decreased cerebral perfusion causes cognitive deterioration. We hypothesized that lesions of the anterior nucleus (AN) including the mammillo-thalamic tract cause a decline in the recollection of past episodes/events, and that the left thalamic infarction can cause frontal dysfunction through the “diaschisis.” We investigated 18 VaD cases with only left thalamic infarction.  $^{99m}\text{Tc}$ -ECD single photon emission computed tomography (SPECT) was used to assess regional cerebral blood flow (CBF). To test the first hypothesis, the scores on the Cognitive Abilities Screening Instrument (CASI) domain Recent memory or the rating on the Clinical Dementia Rating (CDR) domain Memory were analyzed. To test the second hypothesis, we selected the six regions of interest that correlated with the two measures, i.e., word fluency and/or depressive state, as assessed with the Geriatric Depression Scale (GDS). We found that all patients had amnesia, especially in the AN group, six of the eight patients had scores of 1+ on the CDR Memory scale, and all but one disclosed the CASI domain *Recent memory* impairment. There were significant correlations between the left anterior cingulate CBF and word fluency scores, and between the right rectal gyrus CBF and GDS scores. We suggest that these observations are due to a remote effect of the thalamic lesion.

© 2013 Elsevier Ireland Ltd. All rights reserved.

## 1. Introduction

Vascular dementia (VaD) is a condition in which decreased cerebral perfusion causes cognitive deterioration that interferes with daily life. Three major subtypes of VaD have been proposed: (1) a large infarction that causes deterioration of at least two cognitive domains and subsequently meets the criteria for VaD; (2) multiple infarctions that cause dementia, including cases referred to as multi-infarct dementia (Hachinski et al., 1974), as well as those with white matter lesions that cause executive dysfunction and memory impairment (referred to as subcortical VaD) (Erkinjuntti et al., 2000); and (3) infarctions in “strategic” areas such as the thalamus or caudate head that cause cognitive dysfunction (Szimai et al., 2002).

Among the “strategic” areas, the thalamus and associated neural networks have been investigated extensively with regard to memory impairment (Aggleton et al., 2011; Carlesimo et al., 2011). There are two major thalamic nuclei: the anterior nucleus (AN) of the

thalamus including the mammillo-thalamic tract (MTT), which is supplied mainly by the tuberothalamic artery, linked to the mammillary body and hippocampus, and the mediodorsal nucleus (MD), which is supplied mainly by the paramedian artery, linked to the perirhinal cortex. Lesions of the AN and/or MMT are considered to be marked by a selective decline in the recollection of past episodes/events, whereas MD lesions are not.

Furthermore, VaD patients frequently exhibit “extra-memory” symptoms such as depression. Thus the third type, which we refer to as “strategic VaD,” is thought to be a good model for analysis of the neuronal network, since symptoms observed in this condition, such as memory or language dysfunction, cannot be attributed simply to the function of small “strategic” areas, but can be viewed as the expression of dysfunction of cortical/subcortical networks.

Diaschisis, a well-known neuroimaging and pathophysiological finding in which thalamic or basal ganglia infarctions cause hypoperfusion in the ipsilateral or contralateral cerebral cortex, was originally proposed as a basis of functional impairment in remote areas. In early studies, Baron et al. (1986, 1992) investigated the relationship between cortical energy metabolism and neuropsychological impairment linked to unilateral thalamic lesions caused by stroke or thalamotomy. Such impairment was reflected in the depression of synaptic activity in both the

\* Corresponding author. Department of Geriatric Behavioral Neurology, Tohoku University Graduate School of Medicine, 2-1, Seiryō-machi, Aoba-ku, 980-8575 Sendai, Japan. Tel.: +81 22 717 7359.

E-mail address: k-meg@umin.ac.jp (K. Meguro).

overlying and contralateral cerebral cortices. In particular, thalamic infarctions could lead to word-finding difficulty, with word finding difficulty, aphasia, or amnesia, which could be due to remote effects on other cortical areas. Functional neuroimaging using single photon emission computed tomography (SPECT) or positron emission tomography (PET) may be appropriate to study these effects.

Previously *Levasseur et al. (1992)* examined seven consecutive patients with bilateral thalamic infarcts who manifested with persistent amnesia and frontal lobe signs. They exhibited diffuse cortical hypometabolism, suggestive of the areas of cortical diaschisis following thalamic infarction. Regarding the laterality, a left side lesion was considered to be more responsible for cognitive deterioration. *Shim et al. (2008)* described four patients with acute stroke in the left thalamus who exhibited severe amnesia and decreased word fluency, as well as executive dysfunction. SPECT findings indicated that the amnesia observed in the patients was caused by a combination of the left thalamic nucleus and cortical areas. *Stenset et al. (2007)* reported a case of a 67-year-old right-handed patient with a left thalamic lesion who had an amnesic syndrome with preserved general intellectual function. PET with fluorodeoxyglucose (FDG) showed decreased uptake showed decreased uptake in the frontal, parietal and temporal lobes of the left hemisphere. These results support the importance of the network influencing the activity in areas of the cortex that are responsible for memory.

Systematic studies of “strategic” VaD with left thalamic infarction, especially those focusing on the remote effect in association with neuropsychological findings, have not been performed comprehensively. We used SPECT to examine consecutive outpatients with “strategic” VaD who exhibited infarction only on the left side, and using SPECT and investigated whether the remote effect was associated with cognitive dysfunction.

We hypothesized that (1) lesions of the AN, including the MMT, would be marked by a selective decline in the recollection of past episodes/events, and that (2) left thalamic infarction could cause cognitive deterioration, especially in frontal lobe function, through “diaschisis.” These mechanisms may be used to explain the clinical observations.

## 2. Methods

### 2.1. Participants

This was a prospective study of data collected on all patients seen in the clinic at the Osaki–Tajiri SKIP Center. The study investigated 120 consecutive outpatients with dementia. The entry criteria were as follows: (1) right-handed; (2) presence of cerebrovascular disease (CVD) only in the thalamus, as shown by magnetic resonance imaging (MRI) (see below); (3) meeting NINDS-AIREN criteria for VaD; (4) Clinical Dementia Rating (CDR) (*Hughes et al., 1982; Morris et al., 2001*) scores of 0.5 or greater; (5) Mini-Mental State Examination (MMSE) (*Folstein et al., 1975*) scores  $\geq 9$  to ensure verbal communication during neuropsychological testing, and (6) MMSE scores below the cutoff scores regarding dementia according to each educational year, i.e., a score below 24 (educational level of 10 years or more), a score below 21 (8 years of education), and a score below 17 (6 years of education). The exclusion criteria were as follows: (1) drug treatment that could affect cerebral metabolism, such as anti-depressants and cholinesterase inhibitors; and (2) systemic conditions that might affect cognitive functions, such as vitamin B<sub>1</sub>, B<sub>6</sub>, B<sub>12</sub> deficiency, hypothyroidism, or diabetes mellitus, as shown by blood sampling.

The NINDS-AIREN criteria include the presence of CVD, dementia, and a relationship between the two, supported by a temporal relationship between CVD and onset of dementia within 3 months. All patients developed dementia after CVD within 3 months, from 2 weeks to 3 months after the stroke with an average time of 1.52 months. A total of 44 patients with VaD met all the study entry criteria, of whom 20 had bilateral thalamic infarctions with several lacunar infarctions in the deep white matter, accompanying moderate to severe white matter lesions, 18 had a single CVD only in the left thalamus, and six had a single CVD only in the right thalamus. Therefore, the effect of a left thalamic infarction was assessed in 18 patients. No infarctions were detected in any areas except for the left thalamus.

**Table 1**

Demographics of 18 VaD patients with left thalamic infarction.

ID	Age/sex	Education (years)	Recent stroke (months ago)	Nucleus	Artery
1	71 F	12	1	AN	Tubelothalamic
2	84 M	12	0.5	AN	Tubelothalamic
3	88 M	8	1.5	AN	Tubelothalamic
4	83 F	8	0.5	AN	Tubelothalamic
5	70 F	8	2.8	AN	Tubelothalamic
6	87 M	8	2	AN	Tubelothalamic
7	83 F	8	1	AN	Tubelothalamic
8	82 F	6	0.8	AN	Tubelothalamic
9	83 F	10	3	MD	Paramedian
10	77 M	12	1	MD	Paramedian
11	76 M	12	2.5	MD	Paramedian
12	82 M	10	3	MD	Paramedian
13	84 F	10	0.5	MD	Paramedian
14	72 M	10	2.5	MD	Paramedian
15	70 M	8	0.5	MD	Paramedian
16	88 M	8	3	MD	Paramedian
17	87 M	8	0.8	MD	Paramedian
18	82 F	8	0.5	MD	Paramedian

ID #1 and #3 cases are reported in the text. VaD, vascular dementia; M, male; F, female; AN, anterior nucleus; MD, mediodorsal nucleus.

The demographics of the 18 patients are shown in Table 1. Eight patients exhibited infarction in the AN including MTT, supplied mainly by the tuberothalamic artery, whereas the remaining 10 had infarction in the MD, supplied mainly by the paramedian artery. The MD lesions were all in the anterior and/or medial portions. Thus, the remote effect of the medial frontal lobe (not dorsolateral) was analyzed (see below).

Written informed consent was obtained from the patients and their families. The study was approved by the ethics review committees of the Osaki-Tajiri SKIP Center and Tohoku University Graduate School of Medicine.

### 2.2. CDR assessment

For the CDR assessment, a clinical team consisting of medical doctors (board-certified neurologists and a psychiatrist) and public health nurses determined the CDR independent of the neuropsychological assessment in the following manner: (1) Before participants were interviewed by the medical doctors, a research nurse specialist or public health nurses visited their homes to evaluate their daily activities. (2) Family members observed the participants' daily activities, and a research nurse specialist or public health nurse visited frequently to evaluate their daily lives. (3) The participants were interviewed by medical doctors to assess episodic memory, orientation, judgment, etc. (4) Finally, referring to the information provided by the family members, the CDRs for all participants were determined at a joint meeting of the medical doctors and a research nurse specialist or public health nurses. A reliable Japanese version of the CDR scales had previously been established (*Meguro, 2004*).

The CDR is a dementia staging instrument used to rate cognitive function over five levels of impairment from none to maximal (rated as 0, 0.5, 1, 2, or 3) in each of six domains: Memory (M), Orientation (O), Judgment and Problem Solving (JPS), Community Affairs (CA), Home and Hobbies (HH), and Personal Care (PC). Only impairment caused by cognitive dysfunction is rated. Domain-M scores are based on the subjects' episodic memories; domain-O rates according to their time and place orientation. Domain-JPS examines social judgment abilities; domain-CA and domain-HH assess instrumental activities of daily living that are relevant to the individual. Domain-PC represents basic activities of daily living that are common to almost all individuals. Based on the collateral source and participant interviews, a global CDR score is derived from individual ratings in each domain; CDR 0 indicates healthy, and CDR 0.5, 1, 2, and 3 represent questionable, mild, moderate, and severe dementia, respectively.

### 2.3. Neuropsychological and behavioral assessments

The assessments were administered by trained neuropsychologists, without knowledge of the diagnosis and SPECT findings. The MMSE was used to assess general cognitive function, a word fluency test was performed to evaluate frontal lobe function, and the Geriatric Depression Scale (GDS) (*Sutcliffe, 2000*) was used to assess depressive state.

The Cognitive Abilities Screening Instrument (CASI) (*Teng et al., 1994*), total score of 100 and comprising the following subscores, was also performed: *Remote memory* (10 points): personal semantic memory (place and date of birth of the patient) and general semantic memory (direction of sunset, number of minutes in an hour); *Recent memory* (12 points): immediate and delayed (10 min) recall of

three words (from different categories, e.g., shoes, black, modesty) and immediate recall of five objects presented visually; *Attention* (8 points): repeating three words and two sentences; *Mental manipulation & concentration* (10 points): repeating digit span backwards and serial subtraction of 3 from 100; *Orientation* (18 points): age, temporal and spatial orientation; *Figure copying* (10 points): copying two intersecting pentagons; *Abstraction & judgment* (12 points): abstracting similarities between pairs of items, judgment; *List-generating fluency* (10 points): generating names of four-legged animals; *Language* (10 points): executing a simple written command, writing a simple dictated sentence, following a three-step oral command, naming five body parts and five common objects.

#### 2.4. Magnetic resonance imaging (MRI)

A 1.5 Tesla MRI instrument was used (Toshiba, Japan). Three kinds of axial scans were performed to acquire T<sub>1</sub>-weighted images (TR: 564, TE: 11, FA: 80), T<sub>2</sub>-weighted images (TR: 4450, TE: 80, FA: 180), and FLAIR images (TR: 8000, TE: 82, FA: 150, TI: 2400). Using the axial and coronal images, a board-certified neuroradiologist independent of this study evaluated the location of thalamic infarction, especially the AN or MD.

#### 2.5. SPECT

An intravenous (i.v.) line was established before SPECT was performed. An i.v. injection of 600 MBq of <sup>99m</sup>Tc-ethyl cysteinyl dimer (<sup>99m</sup>Tc-ECD) was administered with the patient lying in a supine position with eyes closed in a dimly lit, quiet room. Ten minutes after the injection of <sup>99m</sup>Tc-ECD, SPECT was performed using triple-headed rotating  $\gamma$ -cameras (Multispect, Siemens Medical Systems, Inc.) equipped with high-resolution fanbeam collimators. For each camera, projection data were obtained in a 128 × 128 format for 24 angles at 50 s per angle. A Shepp and Logan Hanning filter was used for image reconstruction at 0.7 cycle/cm, with attenuation correction using Chang's method.

#### 2.6. Image analysis

The original SPECT data were analyzed using the iSSP program (SSP; Nihon Mediphysics) modified with NEUROSTAT (Dr. Minoshima, Department of Radiology & Bioengineering, University of Washington, Seattle, WA, USA). After rotation and centering of the data set, the original data were realigned to the bicommissural line (AC-PC) and transformed into stereotaxic standard Talairach space. The cortical peak activity was projected onto the brain surface, and the peak value was projected back and assigned to the originating surface pixel. The extracted data sets were displayed from eight different angles, including the lateral, medial, superior, inferior, anterior, and posterior views. The Three-Dimensional Stereotaxic Surface Projection (3D-SSP) programs (Minoshima et al., 1994, 1995) in NEUROSTAT were used to normalize the pixel values over the whole brain, thalamus, pons, and cerebellum (Nihashi et al., 2007).

The pixel values for each patient were compared with a normal database of normal elderly CDR 0 residents in the Osaka-Tajiri Project ( $n=18$ ). Stereotaxic Extraction Estimation (SEE) software (Mizumura et al., 2003) was used for the region of interest (ROI) analysis. This method gives a z-score and pixel-by-pixel cerebral blood flow (CBF) values using the Talairach Daemon (Lancaster et al., 1997, 2000). The relative regional CBF (rCBF) was normalized to the global CBF for analysis.

#### 2.7. Hypotheses and analyses

As described above, we hypothesized that (1) lesions of the AN including MTT would be marked by a selective decline in the recollection of past episodes/events, and (2) left thalamic infarction could cause cognitive deterioration, especially frontal lobe function, through "diaschisis."

To test the first hypothesis, the scores on the CASI-domain Recent memory or the rating on the CDR domain Memory were analyzed, since the former evaluates recent memory functions and the latter is based on episodic memories of everyday life.

Thus we analyzed the number of patients with a CDR Memory rating of 1+, or those with CASI domain scores below the previously reported normal range (Meguro et al., 2004).

To test the second hypothesis, we only set six ROIs in the bilateral frontal lobes: medial frontal, anterior cingulate, and rectal gyrus. The MD lesions were all anterior and/or medial portions; thus the remote effect of the medial frontal lobe (not dorsolateral) was analyzed. We set the six ROIs, possibly correlating with the two measures, i.e., word fluency and/or depressive state. Statistical significance was set at 0.0125 (0.05/6/2). Non-parametric Spearman's correlations were used to analyze the relationships between rCBFs and the neurobehavioral measures.

### 3. Results

#### 3.1. Cognitive profiles

Clinically all patients had amnesia based on their families' reports. In the AN group, six of the eight patients had a CDR Memory scale core of 1+, and all but one showed Recent memory impairment in the CASI domain. By contrast, in the MD group, only one patient had a CDR Memory scale score of 1+, and all but two patients had normal findings for the CASI domain Recent memory.

Ten patients had exhibited difficulties finding words. Six of them had mild difficulties, in which they used pronouns in less than 50% of their conversations with their families (+ in Table 2, mild difficulties).

**Table 2**  
Cognitive profiles of 18 VaD patients with left thalamic infarction.

ID	MMSE	Three-word delayed recall	Amnesia		Word fluency (number/min)	Word finding difficulty	GDS (Max. 15)	Depression
			CDR-Memory	CASI-Recent memory				
1	23	0	1	Impaired	3	++	6	+
2	21	1	1	Impaired	5	+	5	+
3	19	1	1	Impaired	7	–	3	–
4	18	0	1	Impaired	8	–	2	–
5	17	1	0.5	Normal	6	++	11	+
6	16	0	1	Impaired	6	–	1	–
7	15	0	0.5	Impaired	2	++	3	–
8	15	0	1	Impaired	9	–	2	–
9	23	2	0.5	Normal	4	+	3	–
10	23	1	0.5	Normal	10	–	2	–
11	23	2	0.5	Normal	10	–	0	–
12	22	1	0.5	Normal	8	+	10	+
13	22	1	1	Impaired	5	+	3	–
14	21	1	0.5	Normal	7	–	3	–
15	20	1	0.5	Normal	9	–	1	–
16	18	1	0.5	Normal	3	+	13	++
17	16	1	0.5	Impaired	4	+	14	++
18	16	1	0.5	Normal	2	++	2	–

ID #1 and #3 cases are reported in the text. Mean age and MMSE scores were 80.5 and 19.7, respectively. VaD, vascular dementia; MMSE, Mini-Mental State Examination; CDR, Clinical Dementia Rating; CASI, Cognitive Abilities Screening Instrument; GDS, Geriatric Depression Scale; +, mild; ++, moderate or severe, – , absent.

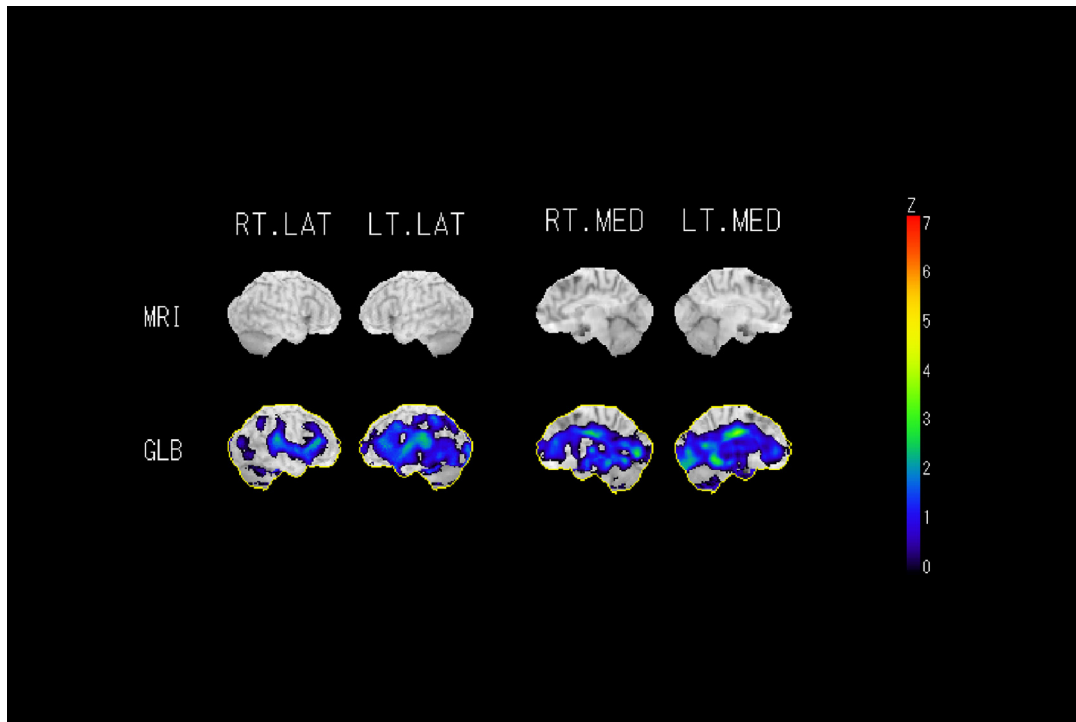


Fig. 1. See the text. RT, right; Lat, Lateral; Lt, left; MED, medial; MRI, magnetic resonance imaging; and GLB, global.

**Table 3**  
Correlations between rCBF and depressive state and word fluency in VaD patients with left thalamic infarctions.

	Medial frontal		Anterior cingulate		Rectal gyrus		
	Lt	Rt	Lt	Rt	Lt	Rt	
ROI							
GDS	rs	0.148	0.000	0.741	0.741	0.704	0.815
	p	0.751	1.000	0.057	0.057	0.077	0.012*
Word fluency	rs	-0.708	-0.220	-0.878	-0.732	-0.732	0.037
	p	0.049	0.601	0.004*	0.039	0.039	0.931

ROI images are shown using the SEE software, with only significant ( $p < 0.05$ ) side being colored. Multiple comparisons disclosed two correlations (\*) remained significant ( $0.05/6/2=0.0125$ ). rCBF, regional cerebral blood flow; VaD, vascular dementia; Lt, left; Rt, right; ROI, region of interest; GDS, Geriatric Depression Scale.

Four of these patients exhibited moderate or severe difficulties ( $> 50\%$ , ++ in Table 2, severe difficulties).

Six of the patients exhibited a depressive state. Two of them had major depression (++ in Table 2, severe state), while the remaining four exhibited a depressive state, as assessed by the GDS (+ in Table 2, mild state). The mean age and MMSE score were 80.5 years and 19.7, respectively.

For the control subjects (18 CDR 0 subjects), the mean age, MMSE, word fluency, and GDS scores were 79.5 years, 24, 10, and 2, respectively: all measures except for age were significantly different from those of the affected patients ( $p < 0.01$ ,  $t$  tests). Clinically these CDR 0 subjects exhibited no amnesia or depressive state.

### 3.2. SPECT findings

Regions showing decreased uptake in the subjects compared with the normal controls are shown in Fig. 1. Both the left and

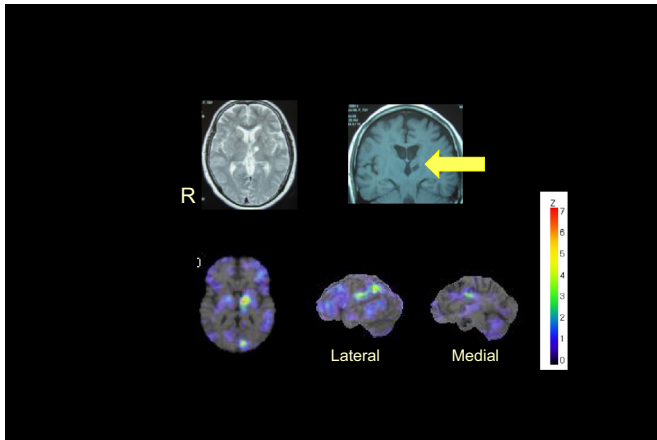
right hemispheres showed decreased CBF, the left side demonstrating more marked hypoperfusion.

Regional CBF correlated significantly (a biologically meaningful direction) with the depressive state (i.e., lower CBF and higher scores) and word fluency (lower CBF and decreased scores) (Table 3), but not with MMSE scores. In Table 3, the ROI images have been presented using SEE software, with the significant side being colored. Multiple comparisons revealed two correlations that remained significant after Bonferroni correction. Correlations were observed for rCBF in the left anterior cingulate vs. word fluency scores, and for rCBF in the right rectal gyrus vs. GDS scores. There was no relationship between global CBF in the left hemisphere and the delay since the last stroke. There was also no relationship between the word fluency and GDS scores.

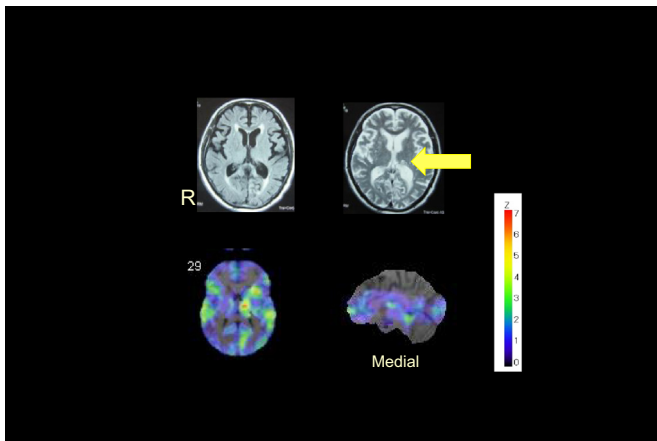
### 3.3. Case reports

Two typical cases with AN and MD lesions were reported.





**Fig. 2.** Case with lesion of the anterior nucleus of the thalamus (see text for detailed description). R, right; MRI, magnetic resonance imaging; and SPECT, single photon emission computed tomography.



**Fig. 3.** Case with lesion of the mediodorsal nucleus of the thalamus (see text for detailed description). R, right; MRI, magnetic resonance imaging; and SPECT, single photon emission computed tomography.

### 3.3.1. Case #1 with AN lesion

The patient was a 71-year-old right-handed woman with 12 years of education. She was originally scrupulous in her performance of domestic chores. She had no marked vascular risk factors. She suddenly developed difficulty finding words and used many pronouns in her communication. She exhibited apathy and did her housework in a careless manner. Amnesia was also noted. Her MMSE score was 23 (three-word recall was 0). She could not recall episodic memory of her daily life, with a CDR Memory scale of 1. However, her remote memory was not impaired.

Neurologically, she exhibited very slight right hemiparesis that did not interfere with her daily activities. MRI showed infarction in the left AN of the thalamus, and SPECT revealed decreased CBF in the bilateral frontal lobes and anterior cingulate (Fig. 2). The precuneus and parietotemporal areas were intact.

### 3.3.2. Case #12 with MD lesion

The patient was an 82-year-old right-handed man with 16 years of education. He had been active and enjoyed his hobbies (golf for the elderly) almost every day. He had suffered from hypertension and angina pectoris as vascular risk factors for 10 years. He suddenly developed difficulty finding words. This problem remitted after 2 weeks, but he gradually exhibited

amnesia and apathy, and he did not enjoy his hobbies anymore. His MMSE score was 22 (three-word recall was 1) and his GDS score was 14 (depressive state). He could remember episodic memory of his daily life, with a CDR Memory scale of 0.5. However, his remote memory was impaired.

Neurologically, he exhibited slight right hemiparesis that did not interfere with his daily activities. MRI showed infarction in the left MD of the thalamus, and SPECT revealed decreased CBF in the bilateral (especially left) frontal lobes and anterior cingulate (Fig. 3). The precuneus and parietotemporal areas, which are characteristic of Alzheimer disease, were intact.

## 4. Discussion

### 4.1. Summary of the results

We tested our hypothesis that (1) lesions of the AN are marked by a selective decline in the recollection of past episodes/events, and (2) that left thalamic infarction can cause cognitive deterioration, especially in frontal lobe function, through “diaschisis.” We discuss these results based on the function of the thalamus and the functional neural network.

### 4.2. Diaschisis of thalamic infarction

The imaging study clarified the remote effect of thalamic infarction on the cortical blood flow with functional impairment, i.e., diaschisis. As described previously, the relationship between cortical energy metabolism and neuropsychological impairment was linked to unilateral thalamic lesions. This was reflected in the depression of synaptic activity in both the other overlying and contralateral cerebral cortices (Baron et al., 1986, 1992). The neuropsychological impairments caused by unilateral thalamic infarction were considered to be due to remote effects on other cortical areas.

### 4.3. Amnesia

In this study, all 18 patients had amnesia, six of them were moderate or severe, as supported by three-word delayed recall scores of 0 or 1 on the MMSE. The medial dorsal and anterior nuclei of the thalamus play important roles in memory, and unilateral lesions of either thalamus can cause impairment of recent memory (von Cramon et al., 1985; Schmahmann, 2003). The impairments occur because these nuclei mediate the acquisition of new information and project to afferent pathways from the temporal lobe to the frontal lobe (Schmahmann, 2003; Edelstyn et al., 2006). Two neuronal networks are relevant for learning and memory: (1) the mamillothalamic tract, which connects the anterior thalamic nucleus with the hippocampus via the fornix, with lesions or deficits in these systems resulting in encoding deficits of memory that are similar to the effects of hippocampal lesions; and (2) the ventral amygdalofugal pathway, which links the amygdala to the medial dorsal nucleus of the thalamus and prefrontal cortex. Memory data brought to the hippocampus are subsequently stored in the neocortex, including the frontal or temporal lobe, in the form of long-term memory; and the thalamic nuclei appear to be situated in this pathway (von Cramon et al., 1985).

The thalamus and associated neural networks have been investigated extensively (Aggleton et al., 2011; Carlesimo et al., 2011). Lesions of the AN, including the MTT, are considered to be marked by a selective decline in the recollection of past episodes/events, whereas this does not occur with MD lesions. Although the number of patients was small, this hypothesis was supported

by the finding that scores on the CASI Recent memory domain or the rating on the CDR domain Memory were impaired in the AN group.

#### 4.4. Difficulties finding words and depressive state

Ten patients had difficulties finding words in this study. The remote effect of the thalamic lesion has recently been considered in relation to language function. The left side effect is thought to be associated with separation of concurrent sounds, contributing to smooth verbal communication in everyday settings (Alain et al., 2005), or syntactic integration of lexical elements in grammatical structure (Dominey et al., 2009). Several studies have also reported the relationship between thalamic lesion and decreased word fluency (Kuljic-Obradovic et al., 2007) or mental flexibility (Swartz et al., 2008).

Six patients exhibited depression in this study. Several studies have also reported a relationship between thalamic lesions and a depressive state (Kim and Choi-Kwon, 2000; Levy-Cooperman et al., 2008; Santos et al., 2009). All previous studies have discussed a possible functional network between the thalamus and the cerebral cortex, especially the frontal lobe.

#### 4.5. Left anterior cingulate and right orbitofrontal cortex

The atrophy rate of the left anterior cingulate, as assessed by MRI has been associated with semantic fluency in mild cognitive impairment (McDonald et al., 2012). PET studies have shown that this area is activated after a verbal fluency task in normal adults and in patients with depression (Ravnkilde et al., 2002; Videbech et al., 2003). Gray matter reduction in the right orbitofrontal cortex has been reported in patients with depression (Gilbert et al., 2010). PET studies have also shown that cerebral glucose metabolism in this area correlated negatively with depressive scores in patients with chronic kidney disease (Song et al., 2008) and was increased in patients with chronic spontaneous pain (Chen et al., 2008).

#### 4.6. Limitations of the study

There are several limitations to this study. First, the subjects were all outpatients at a memory clinic targeting dementia, and thus all patients had dementia. Although we could use “negative” control subjects (CDR 0) from the Tajiri Project for SPECT analysis, “positive” control subjects with thalamic infarction but not dementia were not available, since our center is focused on dementia patients, and not on acute stroke patients. Second, a more detailed neuropsychological examination was not always performed for all patients; thus, we were only able to analyze the dataset of the MMSE, the word fluency test, and the GDS. Despite these limitations, we believe that our results provide a better understanding of the neurological background of VaD patients.

The effects of right, left and bilateral thalamic CVDs should be analyzed. In this study, the bilateral CVD group exhibited lacunar infarctions in the deep white matter, together with severe white matter lesions, but the number of patients in the right CVD group was small. We will further investigate the laterality effect using a larger sample of “pure” patients.

#### Acknowledgments

We are grateful to the staff at the Osaki-Tajiri SKIP Center, and to Ms. Yuriko Kato and Megumi Nakai for their clinical assistance.

#### References

- Aggleton, J.P., Dumont, J.R., Warburton, E.C., 2011. Unraveling the contributions of the diencephalon to recognition memory: a review. *Learning & Memory* 18, 384–400.
- Alain, C., Reinke, K., McDonald, K.L., Chau, W., Tam, F., Pacurar, A., Graham, S., 2005. Left thalamo-cortical network implicated in successful speech separation and identification. *NeuroImage* 26, 592–599.
- Baron, J.C., D'Antona, R., Pantano, P., Serdaru, M., Samson, Y., Bousser, M.G., 1986. Effects of thalamic stroke on energy metabolism of the cerebral cortex. A positron emission tomography in man. *Brain* 109, 1243–1259.
- Baron, J.C., Levasseur, M., Mazoyer, B., Legault-Demare, F., Mauguire, F., Pappata, S., Jedynak, P., Derome, P., Cambier, J., Tran-Dinh, S., 1992. Thalamocortical diaschisis: positron emission tomography in humans. *Journal of Neurology, Neurosurgery, and Psychiatry* 55 (10), 935–942.
- Carlesimo, G.A., Lombardi, M.G., Caltagirone, C., 2011. Vascular thalamic amnesia: a reappraisal. *Neuropsychologia* 49, 777–789.
- Chen, F.Y., Tao, W., Cheng, X., Wang, H.Y., Hu, Y.S., Zhang, X.H., Li, Y.J., 2008. Brain glucose metabolic changes associated with chronic spontaneous pain due to brachial plexus avulsion: a preliminary positron emission tomography study. *Chinese Medical Journal* 121 (12), 1096–1100.
- Dominey, P.F., Inui, T., Hoen, M., 2009. Neural network processing of natural language: II. Towards a unified model of corticostriatal function in learning sentence comprehension and non-linguistic sequencing. *Brain and Language* 109, 80–92.
- Edelstyn, N.M., Hunter, B., Ellis, S.J., 2006. Bilateral dorsolateral thalamic lesions disrupts conscious recollection. *Neuropsychologia* 44, 931–938.
- Erkinjuntti, T., Inzitari, D., Pantoni, L., Wallin, A., Scheltens, P., Rockwood, K., Roman, G.C., Chui, H., Desmond, D.W., 2000. Research criteria for subcortical vascular dementia in clinical trials. *Journal of Neural Transmission* 59, 23–30.
- Folstein, M.F., Folstein, S.E., McHugh, P.R., 1975. Mini-Mental State. A practical method for grading the cognitive state of patients for the clinician. *Journal of Psychiatric Research* 12, 189–198.
- Gilbert, A.M., Prasad, K., Goradia, D., Nutche, J., Keshavan, M., Frank, E., 2010. Grey matter volume reduction in the emotion network of patients with depression and coronary artery disease. *Psychiatry Research: Neuroimaging* 181 (1), 9–14.
- Hachinski, V.C., Lassen, N.A., Marshall, J., 1974. Multi-infarct dementia. A cause of mental deterioration in the elderly. *Lancet* 2 (7874), 207–210.
- Hughes, C.P., Berg, L., Danziger, W.L., Coben, L.A., Martin, R.L., 1982. A new clinical scale for the staging of dementia. *British Journal of Psychiatry* 140, 566–572.
- Kim, J.S., Choi-Kwon, S., 2000. Poststroke depression and emotional incontinence: correlation with lesion location. *Neurology* 54 (9), 1805–1810.
- Kuljic-Obradovic, D., Labudovic, G., Basurovic, N., Savic, M., 2007. Neuropsychological deficits after bilateral hemorrhages. *Journal of Neurological Sciences* 257 (1–2), 174–176.
- Lancaster, J.L., Rainey, L.H., Summerlin, J.L., Freitas, C.S., Fox, P.T., Evans, A.F., Toga, A.W., Mazziotta, J.C., 1997. Automated labeling of the human brain: a preliminary report on development and evaluation of a forward-transform method. *Human Brain Mapping* 5, 238–242.
- Lancaster, J.L., Woldorff, M.G., Parsons, L.M., Liotti, M., Freitas, C.S., Rainey, L., Kochunov, P.V., Nickerson, D., Mikiten, S.A., Fox, P.T., 2000. Automated Talairach atlas labels for functional brain mapping. *Human Brain Mapping* 10, 120–131.
- Levasseur, M., Baron, J.C., Sette, G., 1992. Brain energy metabolism in bilateral paramedian thalamic infarcts: a positron emission tomography study. *Brain* 115, 795–807.
- Levy-Cooperman, N., Burhan, A.M., Rafi-Tari, S., Kusano, M., Ramirez, J., Caldwell, C., Lee, E., Tanaka, Y., Kasuya, M., Sekita, Y., 2004. Prevalence and cognitive performances of clinical dementia rating 0.5 and mild cognitive impairment in Japan: the Tajiri Project. *Alzheimer's Disease and Associated Disorders* 18 (1), 3–10.
- Minoshima, S., Frey, K.A., Koeppe, R.A., Foster, N.L., Kuhl, D.E., 1995. A diagnostic approach for Alzheimer's disease using three-dimensional stereotaxic surface projections of fluorine-18-FDG-PET. *Journal of Nuclear Medicine* 36, 1238–1248.
- Minoshima, S., Koeppe, R.A., Frey, K.A., Ishihara, M., Kuhl, D.E., 1994. Stereotaxic PET atlas of the human brain: aid for visual interpretation of functional brain images. *Journal of Nuclear Medicine* 35, 949–954.
- Mizumura, S., Kumita, S., Cho, K., Ishihara, M., Nakajo, H., Toba, M., Kumizaki, T., 2003. Development of quantitative analysis method for stereotaxic brain image: assessment of reduced accumulation in extent and severity using anatomical segmentation. *Annals of Nuclear Medicine* 17 (4), 289–295.
- Morris, J.C., Strandt, M., Miller, J.P., McKeel, D.W., Price, J.L., Rubin, E.H., Berg, L., 2001. Mild cognitive impairment represents early stage Alzheimer's disease. *Archives of Neurology* 58, 397–405.
- Nihashi, T., Yatsuya, H., Hayasaka, K., Kato, R., Kawatsu, S., Arahata, Y., Iwai, K., Takeda, A., Washimi, Y., Yoshimura, K., Mizuno, K., Kato, T., Naganawa, S., Ito, K., 2007. Direct comparison study between FDG-PET and IMP-SPECT for

- diagnosing Alzheimer's disease using 3D-SSP analysis in the same patients. *Radiation Medicine* 25, 255–262.
- Ravnikle, B., Videbeck, P., Rosenberg, R., Gjedde, A., Gade, A., 2002. Putative tests of frontal lobe function: a PET-study of brain activation during Stroop's Test and verbal fluency. *Journal of Clinical and Experimental Neuropsychology* 24 (4), 534–547.
- Santos, M., Gold, G., Kövari, E., Herrmann, F.R., Bozikas, V.P., Bouras, C., Giannakopoulos, P., 2009. Differential impact of lacunes and microvascular lesions on poststroke depression. *Stroke* 40 (11), 3557–3562. (Epub August 20 2009).
- Schmahmann, J.D., 2003. Vascular syndromes of the thalamus. *Stroke* 24, 2264–2278.
- Shim, Y.S., Kim, J.S., Shon, Y.M., Chung, Y.A., Ahn, K.J., Yang, D.W., 2008. A serial study of regional cerebral blood flow deficits in patients with left anterior thalamic infarction: an anatomical and neuropsychological correlates. *Journal of Neurological Sciences* 266, 84–91.
- Song, S.H., Kim, I.J., Kim, S.J., Kwak, I.S., Kim, Y.K., 2008. Cerebral glucose metabolism abnormalities in patients with major depressive symptoms in pre-dialytic chronic kidney disease: statistical parametric mapping analysis of F-18-FDG PET, a preliminary study. *Psychiatry and Clinical Neurosciences* 62 (5), 554–561.
- Stenset, V., Grambaite, R., Reinvang, I., Hessen, E., Cappelen, T., Bjørnerud, A., Gjerstad, L., Fladby, T., 2007. Diaschisis after thalamic stroke: a comparison of metabolic and structural changes in a patient with amnesic syndrome. *Acta Neurologica Scandinavica*, Supplement 187, 68–71.
- Sutcliffe, C., 2000. A new version of the Geriatric Depression Scale (Residential) (GDS-12R). *International Psychogeriatrics* 12, 173–181.
- Swartz, R.H., Stuss, D.T., Gao, F., Black, S.E., 2008. Independent cognitive effects of atrophy and diffuse subcortical and thalamico-cortical cerebrovascular disease in dementia. *Stroke* 39 (3), 822–830.
- Szimai, I., Vastagh, I., Szobathelyi, E., Kamondi, A., 2002. Strategic infarcts of the thalamus in vascular dementia. *Journal of Neurological Sciences* 203–204, 91–97.
- Teng, E.L., Hasegawa, K., Homma, A., Imai, Y., Larson, E., Graves, A., Sugimoto, K., Yamaguchi, T., Sasaki, H., Chiu, D., 1994. The cognitive abilities screening instrument (CASI): a practical test for cross-cultural epidemiological studies of dementia. *International Psychogeriatrics* 6 (1), 45–58.
- Videbeck, P., Ravnikle, B., Kristensen, S., Egander, A., Clemmensen, K., Rasmussen, N.A., Gjedde, A., Rosenberg, R., 2003. The Danish PET/depression project: poor verbal fluency performance despite normal prefrontal activation in patients with major depression. *Psychiatry Research: Neuroimaging* 123 (1), 49–63.
- von Cramon, D.Y., Hebel, N., Schuri, U., 1985. A contribution to the anatomical basis of thalamic amnesia. *Brain* 108, 993–1008.