

Ketamine for Medically Refractory Status Epilepticus After Elective Aneurysm Clipping

F. A. Zeiler · A. M. Kaufmann · L. M. Gillman ·
M. West · J. Silvaggio

Published online: 24 May 2013

© Springer Science+Business Media New York 2013

Abstract

Background Medically refractory status epilepticus, without an identifiable cause, post elective aneurysm clipping is a rare event.

Objective To describe the two cases of refractory status epilepticus post elective aneurysm clipping, without an identifiable cause, and discuss the potential role for early consideration of ketamine.

Methods Retrospectively reviewed two patients at our institution who developed refractory status epilepticus post elective aneurysm clipping, without a defined cause.

Results Two patients who underwent elective aneurysm clipping developed medically refractory status epilepticus post-craniotomy. No structural, vascular, infectious, or metabolic cause was identified. Seizure control failed with multiple medications and intravenous sedatives over the period of weeks in both. Ketamine was instituted at 20 and 40 mg/kg/min in these patients. Within hours of starting ketamine, burst suppression was obtained in both.

Medications were all tapered over the next month, and both the patients recovered to be cognitively normal, with mild residual morbidity secondary to critical care polyneuropathy.

Conclusions Refractory status epilepticus, in the absence of an identifiable etiology, in elective aneurysm clipping is a rare event. Consideration should be given for the early use of ketamine in refractory status epilepticus.

Keywords Refractory seizure · Ketamine · Aneurysm clipping · Elective clipping · Status epilepticus

Introduction

Status epilepticus in post-neurosurgery patients is poorly defined in the literature. The incidence is unknown, and its management is based on protocols designed for status epilepticus in nonsurgical settings.

Of the literature that exists surrounding refractory status epilepticus post skull base surgery [1], what we do know is it seems to be a rare experience, difficult to treat, and seems to resolve without major neurological morbidity.

In the setting of elective aneurysm clipping, we know from the existing literature that the incidence of post-operative seizures is variable [2–6], with unknown benefit of anti-epileptic drugs (AED) prophylaxis [4]. Status epilepticus rates are undefined in this operative population. Medically refractory cases, in the absence of an underlying etiology, of post elective aneurysm clipping status epilepticus have yet to be described in the literature, to the best of our knowledge.

Within this study, we describe two new cases of refractory status epilepticus post elective aneurysm clipping. No underlying etiology has been identified. Individual case description and discussion around the effectiveness of ketamine and its potential early consideration are found within.

Methods

We retrospectively reviewed the charts of two patients at our institution who underwent elective aneurysm clipping and developed post-operative medically refractory status

F. A. Zeiler (✉) · A. M. Kaufmann · M. West · J. Silvaggio
Section of Neurosurgery, Department of Surgery,
University of Manitoba, Winnipeg, MB, Canada
e-mail: umzeiler@cc.umanitoba.ca

L. M. Gillman
Section of Critical Care Medicine, Department of Internal
Medicine, University of Manitoba, Winnipeg, MB, Canada

epilepticus without an identifiable etiology. Demographics, pre- and peri-operative medications, imaging, and outcomes were recorded.

Results

Case 1: A 66-year-old female, with a past medical history of Crohn's disease, hypertension, and migraines, was admitted for the elective clipping of a right middle cerebral artery (MCA) aneurysm. Home medications consisted of amitriptyline, amlodipine, citalopram, propranolol, and betahistine. She had a left sided unruptured MCA aneurysm clipped 1 year previously that was uncomplicated.

The surgery for the right MCA aneurysm was uncomplicated and her initial post-operative course was unremarkable, with discharge home on post-operative day 3. The anesthetic for the procedure consisted of midazolam and succinylcholine for intubation, followed by propofol and remifentanyl infusions as maintenance. No adverse events were recorded by intra-operative electroencephalogram (EEG) or anesthesia throughout the entirety of the procedure.

She subsequently presented to her local hospital on post-operative day 5, after a generalized tonic–clonic seizure, with persistent decreased level of consciousness. She was transferred to our institution after administration of a 1-gm load of phenytoin. Clinically upon arrival, she displayed repetitive blinking, coughing, and yawning. She underwent endotracheal intubation and admission to the intensive care unit (ICU) and propofol administered at 5 mg/kg/h. Right frontal discharges and generalized spike wave activity were noted on EEG, and midazolam was then added at 10 mg/h with goal of burst suppression. The next day, EEG failed to demonstrate burst suppression and Keppra 1,000 mg twice daily was added, and midazolam was increased to 20 mg/h. Magnetic resonance imaging (MRI), magnetic resonance angiography (MRA), and CT angiography (CTA) of the brain showed no structural or vascular etiology of the seizures. Vasculitis workup was negative. Investigation for an infectious and metabolic cause was conducted and failed to identify an etiology for the ongoing seizure activity.

Over the next 3 days, midazolam was weaned with EEG evidence of medium to high-amplitude theta and delta activity dispersed in the hemispheres bilaterally which subsequently transitioned into a rhythmic pattern consistent with nonconvulsive status epilepticus. As a result, she received a Phenobarbital load of 20 mg/kg with maintenance of 90 mg three times daily, an increase in Keppra dose to 1,500 mg twice daily, and the addition of clobazam titrated up to 40 mg twice daily with each subsequent failure of cessation of intravenous sedation, resulting in electrographic seizures.

On post-operative day 14, 9 days after seizure onset, intravenous sedatives were weaned, and EEG evidence of recurrent status epilepticus was documented, valproic acid was added. An elevation in liver enzymes and concern for progressive medication mediated hepatocellular injury prompted discontinuation of valproate on post-operative day 17 and the addition of topiramate at 100 mg twice daily. Ketamine infusion was then started at 10 mg/kg/min after EEG evidence of ongoing seizure activity. With repeat, EEG failing to display burst suppression, the ketamine dose was increased to 20 mg/kg/min.

On post-operative day 18, after the increase in ketamine infusion, the patient displayed burst suppression on EEG after weaning of the propofol. Ketamine was continued for 3 days, while both midazolam and propofol were completely discontinued, with EEG evidence of no seizures. The patient had a tracheostomy and percutaneous feeding tube placed.

The oral AED were tapered starting with topiramate and Phenobarbital. During the next 20 days, the patient remained unresponsive, with repeat EEG indicating no ongoing seizures. On post-operative day 40, the patient began to open her eyes, however, no spontaneous or stimulus induced movement was apparent. Concerns for ICU polyneuropathy were raised.

Over the period of the next 2 months, she gradually recovered, function was decannulated and the gastric feeding tube was removed. On post-operative day 92, she was transferred to our stroke rehabilitation service for 2 months on inpatient rehabilitation. Upon clinic follow-up, 6 months out from her second elective clipping, she was off all AED and neurologically/cognitively normal, with the exception of mild residual right leg weakness.

Case 2: A 57-year-old male with a past medical history of hypertension, type 2 diabetes, and hypercholesterolemia was admitted for elective clipping of an anterior communicating artery (AComm) aneurysm. The procedure underwent without complication, with only a small amount of the left gyrus rectus being resected during the exposure. The patient was loaded with 1 gm of phenytoin intraoperatively during the closure as prophylaxis. His anesthetic consisted of rocuronium and midazolam for intubation, followed by propofol and remifentanyl infusions for maintenance. No adverse intraoperative events were recorded by intra-operative EEG monitoring or anesthesia.

In the recovery room, he was noted to have a generalized tonic–clonic seizure. He received a repeat 500 mg bolus of phenytoin, and two 2 mg doses of midazolam that failed to control his seizures. He was subsequently reintubated and transferred to the ICU for intravenous sedation. Diffuse sharp spike wave activity in both hemispheres was documented on EEG. Propofol infusion at 5 mg/kg/h and midazolam at 10 mg/h was started. MRI,

MRA, and CTA of the brain failed to demonstrate a vascular or structural cause. A vasculitis workup was conducted and was negative. All the infectious and metabolic work-up was negative for a cause.

On post-operative day 2, EEG and clinical evidence of generalized tonic–clonic seizures was recorded upon weaning of intravenous sedation. Profound hypertension and bradycardia were noted during the seizure. Sedation with reinstated and Valproic acid was started. Repeat EEG failed to display burst suppression and Keppra 1,000 mg twice daily was added. On post-operative day 4 concerns of elevated lactate levels and propofol infusion syndrome were raised. As a result, propofol was reduced to 1 mg/kg/h and ketamine infusion at 40 mg/kg/min was started. EEG displayed burst suppression within 30 min of starting the ketamine infusion. A repeat CT of the head was ordered that displayed right small parietal hemorrhages, thought to be related to hypertension (Fig. 1). Repeat MRI of the brain with diffusion weighted sequencing displayed a small area of restricted diffusion, without significant surrounding edema, in area of CT defined hemorrhage (Fig. 1).

The ketamine was continued until post-operative day 9, allowing for weaning of the propofol and midazolam, with EEG confirming the absence of seizure activity. During weaning of the ketamine infusion, EEG displayed active seizures, and Phenobarbital load of 20 mg/kg was administered and the maintenance of 60 mg twice daily added. The patient received a tracheostomy and percutaneous gastric feeding tube on post-operative day 15. Ketamine was successfully weaned without EEG evidence of seizures on post-operative day 16.

On post-operative day 23, the patient began to wake and obey simple commands weakly. Concerns over ICU polyneuropathy were raised. His AED were tapered over the course of the next 20 days. The patient was decannulated and transferred to local hospital. Upon the last assessment, he was cognitively normal and ambulating independently, though has residual gait difficulty secondary to critical care neuropathy.

Discussion

Seizures post-craniotomy have been widely reported, with ranges from 8 to 50 % [2]. Post-operative seizure episodes are well described in aneurysm surgery [2–4]. Ruptured aneurysm patients have displayed varying degrees of seizure activity post-operatively, with rates ranging from 1 to 27 % [3–6]. Rates of status epilepticus in patient's post-operative from aneurysm clipping are poorly defined.

However, for unruptured intracranial aneurysms, seizure activity post elective clipping has yet to be well-defined in the literature, with few studies to date. Rabinowicz et al.

[2] reported a 15.7 % incidence of seizures post elective clipping in 19 patients whom were previously seizure free. Temporal lobe retraction was thought to be the underlying cause in that study. All patients had AED tapered before 12 months post-operatively. Similar, Raper et al. [4] described the incidence of seizures post elective aneurysm clipping at 3 % early after surgery, and 5 % late onset. Interestingly, that study demonstrated an increased incidence of post-operative seizures in those patients given AED prophylaxis, bringing the role of AED prophylaxis in aneurysm surgery into question.

The incidence of medically refractory status epilepticus post-craniotomy is rarely described within the literature. Al-Mefty et al. [1] described a case series of skull base surgery patients displayed delayed post-operative decline in consciousness. These patients presented with nonconvulsive status epilepticus on average 3 days post-craniotomy, that was medically refractory, and without any structural, metabolic, vascular, or infectious etiology defined. All of these individuals awoke spontaneously within a few days after EEG normalization. This case series raised concerns revolving around the potential effect of anesthetic agents or medication combinations as the cause of these epileptic episodes, though the underlying source was never identified.

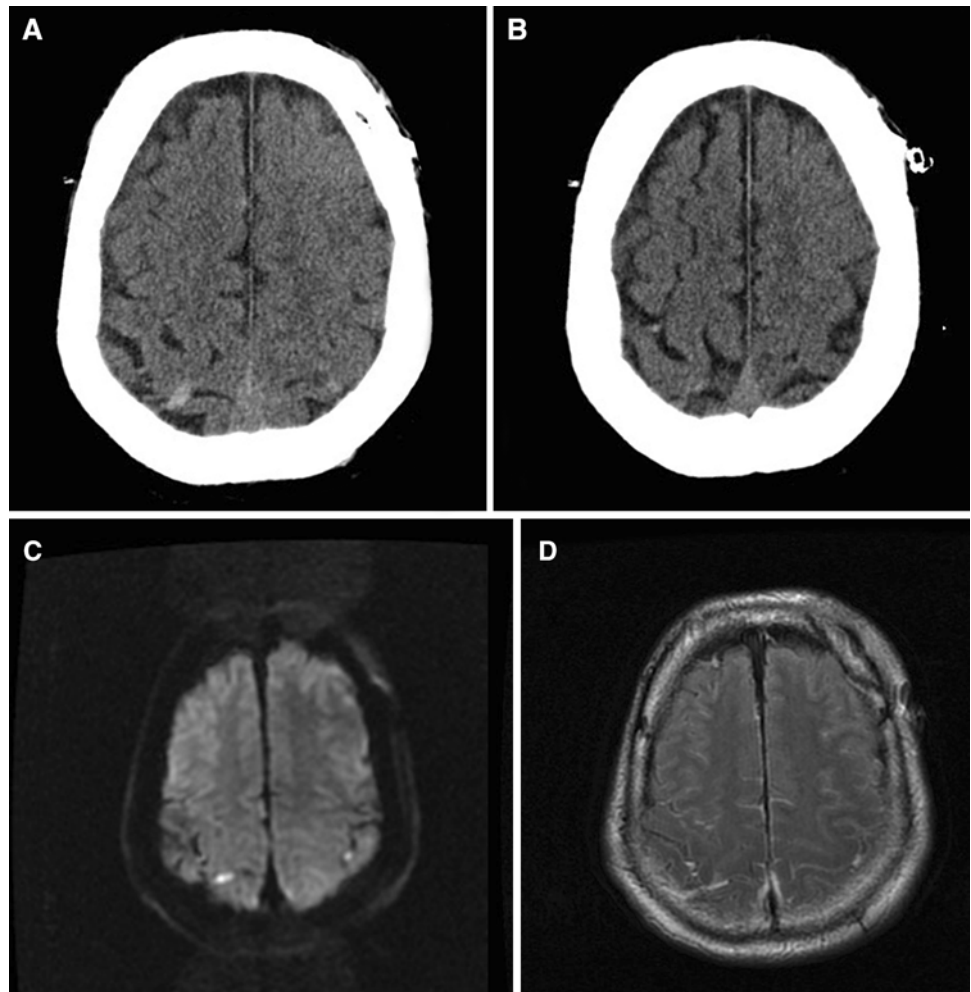
The presence of refractory status epilepticus post elective aneurysm clipping, in the absence of an identifiable underlying cause, has never been described in the literature, to the best of our knowledge.

Our report of two new cases of refractory status epilepticus, in the absence of a defined etiology, post elective aneurysm clipping is of interest for a variety of reasons.

First, it seems to be a novel description in the literature, to the best of our knowledge. Our hope is the above case descriptions will encourage others to publish similar results on these confusing clinical scenarios, with the goal of potentially understanding precipitating factors, treatment regimens, and preventative strategies.

Second, the underlying etiology of the seizure activity was never defined. This is similar to those cases described by Al-Mefty et al. [1], with the absence of an identifiable vascular, structural, metabolic, or infectious cause. There is a slight difference, in that our two cases are very different from the literature [1] and from one another. For example, different aneurysm locations between the patients, and the surgery being different from the skull base approach cases described in the literature. In addition, the neurosurgery literature describes only nonconvulsive status epilepticus to date [1] in the presence of no underlying etiology, where our series has one with convulsive and one with nonconvulsive status epilepticus. Thus, it is hard to make a direct comparison to the related literature and our case series. Despite this, it is unnerving to be left without an answer as to etiology of such refractory seizures. We had conducted

Fig. 1 Case 2 CT and MRI 8of post seizure parietal hemorrhages. *CT* computed tomography, *MRI* magnetic resonance imaging. **a, b** Post-operative day 3 CT brain. **c, d** Post-operative day 4 MRI brain. **a, b** Uninfused CT of head demonstrating right parietal hyperdensity. **c** Diffusion weighted imaging of brain indicating restricted diffusion (apparent diffusion coefficient maps confirmed) in area of right parietal hemorrhage on CT. **d** Fluid attenuated inversion recovery (FLAIR) imaging at same level as **c** indicating lack of significant edema



thorough imaging (MRI/MRA/CTA), vasculitis, metabolic, and infectious workup for a potential source of the seizures that came back negative. One of our patients did display some focal hemorrhages, as described, which may relate to vasoconstriction or hypertension. Both patients were of advanced age, and have vascular risks factors, thus, making it difficult to completely rule out the occult vascular pathology contributing to the seizure focus. In addition, perhaps an undefined genetic predisposition is a contributing factor to these patients epileptogenicity.

Third, the concept of anesthetic and/or medication interactions leading to the seizure activity was postulated in Al-Mefty's [1] paper. We had questioned this as well, however, given the intra-operative EEG and anesthetic notes failing to identify any remarkable intraoperative events, it remains unknown. The use of enflurane, etomidate, and sevoflurane are well-known to precipitate the seizure activity [7]. Yet looking at our cases, the maintenance infusions of remifentanyl and propofol intraoperatively, in the absence of inhaled volatile anesthetic agents, it's hard to attribute this to the precipitation of seizure activity. However, some literature exists pointing to lower seizure stimulus amplitudes and

longer seizures during electroconvulsive therapy in patients on modest doses of mu-opioids, in particular remifentanyl, and propofol in combination [7–9]. Thus, the combination of mu-opioids, propofol, and mild mechanical stimulus intraoperatively may explain the inciting cause of seizure in our patients. However, prolonged refractory seizure activity even after discontinuation of remifentanyl immediately post-operatively, is still difficult to explain.

Fourth, the use of ketamine, as a nonconventional AED in our series displays the drugs ability to suppress refractory seizure activity. Given our success with this medication, one must question its role in the control of refractory status epilepticus and timing of administration. The choice of first and second line intravenous sedative agents in status epilepticus typically rests on propofol and midazolam [10–12]. When seizures are refractory to these initial intravenous medications, controversy exists as to what it the next best choice. Ketamine is of interest in the setting of refractory seizures as its *N*-methyl-D-aspartate (NMDA) receptor antagonism is potentially advantageous, since upregulation of NMDA receptors occurs as status epilepticus continues [12, 13]. Activation of NMDA receptors, during status epilepticus,

increases intracellular calcium which can contribute seizure activity [14]. Furthermore, the refractory nature of status epilepticus to the conventional intravenous sedative agents can be explained in part due to the changes in gamma-aminobutyric acid (GABA_A) receptor function [15]. This leaves GABAergic drugs poorly suited in the ongoing treatment [13, 15, 16], thus, implementing nonconventional drugs such as ketamine as a potential next line. In addition, the sympathomimetic nature of ketamine avoids the risk of hypotension commonly associated with other intravenous sedative agents used for seizure control. Animal models have demonstrated the efficacy of ketamine in abolishing refractory status epilepticus in rats [15, 17]. In humans, the use of ketamine in the management of refractory status epilepticus is limited to case reports and small case series [14, 18]. Our series of patients adds to this limited literature on the effectiveness of ketamine.

Timing of initiation of such nonconventional AED is controversial. Our initial experience in Case 1 prompted early initiation of ketamine in Case 2, whereas without this prior success, we may have waited longer to start such a nonconventional therapy.

Despite the encouraging results with ketamine in our cases, caution must be taken as the potential side effect profile can have serious consequences. Profound hypertension can be seen due to the sympathomimetic nature of the drug. Other side effects include, but not limited to confusion, hallucinations, tachycardia, delusions, and dizziness. Drug interaction has been described with opiates, benzodiazepine, barbituates, and a variety of anesthetics. Some contraindications to ketamine use include uncontrolled hypertension, and elevated intracranial pressure, which in the neurologically ill patient may preclude its use as an antiepileptic drug.

Finally, the presence of critical care neuropathy in both of our patients is concerning. The underlying cause, we suspect, is multifaceted. We attribute patient age, multiple high-dose intravenous sedative infusions, prolonged ICU stays, and immobility for at least 3 weeks to the cause of significant neuropathy in our cases. It is encouraging that both patients, despite significant initial limitations, have recovered almost completely. Avoidance of this complication is difficult due to the refractory nature of their epilepsy, requiring prolonged medication administration and an extended period in a medication induced altered state.

Overall, it's difficult to understand what occurred during our two cases. The limitation of the study is the retrospective nature, and the fact we have two cases to date. This makes the treatment and outcomes difficult to generalize to all the patients with refractory status epilepticus post elective clipping, or even post-craniotomy. Despite the limitations, the discussion on anesthetic drug combinations, utility of a nonconventional AED in ketamine, and the positive patient outcome despite prolonged periods of

poorly controlled epilepsy are of interest. The hope is that more cases will become available in the literature, so as to better understand the possible inciting events, treatment, and prognosis with such a rare phenomenon in elective aneurysm surgery, and neurosurgery in general.

Conclusions

Medically refractory status epilepticus in the setting of elective aneurysm clipping, without an identifiable etiology, is a rare occurrence with our series of two patients being the first described. Consideration should be given for early implementation of nonconventional AED, such as ketamine, when faced with refractory status epilepticus.

References

- Al-Mefty O, Wrubel D, Haddad N. Postoperative nonconvulsive encephalopathic status: identification of a syndrome responsible for delayed progressive deterioration of neurological status after skull base surgery. *J Neurosurg.* 2009;111:1062–8.
- Rabinowicz AL, Ginsburg DL, DeGiorgio CM, Gott PS, Giannotta SL. Unruptured intracranial aneurysms: seizures and antiepileptic drug treatment following surgery. *J Neurosurg.* 1991;75:371–3.
- Lin CL, Dumont AS, Lieu AS, Yen CP, Hwang SL, Kwan AL, Kassell NF, Howng SL. Characterization of perioperative seizures and epilepsy following aneurysmal subarachnoid hemorrhage. *J Neurosurg.* 2003;99:978–85.
- Raper DMS, Kokabi N, McGee-Collett M. The efficacy of anti-epileptic drug prophylaxis in the prevention of early and late seizures following repair of intracranial aneurysms. *J Clin Neurosci.* 2011;18:1174–9.
- Wong JM, Ziewacz JE, Ho AL, Panchmatia JR, Kim AH, Bader AM, Thompson BG, Du R, Gawande AA. Patterns in neurosurgical adverse events; open cerebrovascular neurosurgery. *Neurosurg Focus.* 2012;33(5):E15.
- Hoh BL, Nathoo S, Chi YY, Barker FG. Incidence of seizures of epilepsy after clipping or coiling of ruptured and unruptured cerebral aneurysms in the nationwide inpatient sample database: 2002–2007. *Neurosurgery.* 2011;69(3):644–50.
- Voss LJ, Sleight JW, Barnard JPM, Kirsch HE. The howling cortex: seizures and general anesthetic drugs. *Anesth Analg.* 2008;107(5):1689–703.
- Recart A, Rawal S, White PF, Byerly S, Thornton L. The effect of remifentanyl on seizure duration and acute hemodynamic responses to electroconvulsive therapy. *Anesth Analg.* 2003;96:1047–50.
- Vishne T, Aronov S, Amiaz R, Etchin A, Grunhaus L. Remifentanyl supplementation of propofol during electroconvulsive therapy: effect on seizure duration and cardiovascular stability. *J ECT.* 2005;21:235–8.
- Claassen J, Hirsch LJ, Emerson RG, Mayer SA. Treatment of refractory status epilepticus with pentobarbital, propofol, or midazolam: a systematic review. *Epilepsia.* 2002;43:146–53.
- Claassen J, Hirsch LJ, Mayer SA. Treatment of status epilepticus: a survey of neurologists. *J Neurol Sci.* 2003;211:37–41.
- Smith M. Anesthetic agents and status epilepticus. *Epilepsia.* 2011;52(Suppl. 8):42–4.
- Pruss H, Holtkamp M. Ketamine successfully terminates malignant status epilepticus. *Epilepsy Res.* 2008;82:219–22.

14. Kramer AH. Early ketamine to treat refractory status epilepticus. *Neurocrit Care*. 2012;16:299–305.
15. Mazarati AM, Wasterlain CG. N-methyl-d-aspartate receptor antagonists abolish the maintenance phase of self-sustaining status epilepticus in rat. *Neurosci Lett*. 1999;265:187–90.
16. Kapur J, Coulter DA. Experimental status epilepticus alters GABAA receptor function in CA1 pyramidal neurons. *Ann Neurol*. 1995;38:893–900.
17. Borris DJ, Bertram EH, Kapur J. Ketamine controls prolonged status epilepticus. *Epilepsy Res*. 2000;42:117–22.
18. Yeh PS, Shen HN, Chen TY. Oral ketamine controlled refractory nonconvulsive status epilepticus in an elderly patient. *Seizure*. 2011;20:723–6.