

Hyperintensity in the subarachnoid space on contrast-enhanced fluid-attenuated inversion-recovery magnetic resonance imaging after central venous catheter removal

Kyusik Kang · Sehoon Lee

© Springer Science+Business Media New York 2013

Abstract Cerebral air embolism is a rare complication of central venous catheterization. A 61-year-old man developed a left-sided hemiparesis immediately after his right jugular venous catheter removal. A diffusion-weighted magnetic resonance imaging (MRI) obtained 2 h after the symptom onset was normal. However, postgadolinium cerebral spinal fluid enhancement was seen on fluid-attenuated inversion-recovery MRI. A repeat diffusion-weighted MRI, 18 h later, showed restricted diffusion in the bilateral hemispheres. Disruption of the blood–brain barrier caused by the air bubbles might lead to accumulation of gadolinium in the subarachnoid space. Postgadolinium cerebral spinal fluid enhancement may be an early, sensitive predictor of blood–brain barrier disruption and impending cerebral infarct after air embolism.

Keywords Cerebral embolism · Cerebral infarction · Fluid-attenuated inversion-recovery magnetic resonance imaging · Venous catheter

Introduction

Cerebral air embolism leading to neurologic illness is a potentially serious, though rare, complication of central venous catheterization [1]. Symptoms are nonspecific and include headache, altered consciousness, seizures, and focal neurologic deficits such as hemiparesis, hemianopsia, and pupil asymmetry [2, 3]; precontrast brain computed

tomography (CT) or magnetic resonance imaging (MRI) is frequently normal [1, 4, 5]. Therefore, the diagnosis is often clinical [2]. We report a case of cerebral air embolism evaluated acutely using brain CT, diffusion-weighted, perfusion-weighted, and postcontrast fluid-attenuated inversion-recovery (FLAIR) MRI, and magnetic resonance angiography.

Case report

A 61-year-old male patient was admitted because of acute renal failure and central venous catheter was inserted through his right jugular vein. On the 8th hospital day, central venous catheter was removed. Five minutes later, he developed dyspnea and left hemiparesis and the oxygen saturation transiently decreased to 62 %. One hour later, his blood pressure transiently dropped to levels of 85/50 mmHg, but a brain CT was normal. Therefore, he was treated with intravenous tissue plasminogen activator. One hour later, diffusion-weighted and perfusion-weighted MRI (Fig. 1a) and brain and cervical magnetic resonance angiogram were normal. However, high signal was seen in the subarachnoid space over the bilateral convexities on contrast-enhanced FLAIR MRI (Fig. 1b). A repeat diffusion-weighted MRI, 18 h later, showed restricted diffusion in the right frontal lobe and bilaterally in the parietal lobes (Fig. 1c, d). An electrocardiogram and an echocardiogram were normal. His neurological status improved to baseline over 3 days.

Discussion

Our patient developed hemiparesis in temporal association with the procedure that carry a risk of air embolism. Air entering the venous circulation travels to the right heart and

K. Kang (✉) · S. Lee
Department of Neurology, Eulji General Hospital,
Eulji University, 14 Hangeulbiseok-gil, Nowon-gu,
Seoul 139-711, Republic of Korea
e-mail: cobnut1@gmail.com

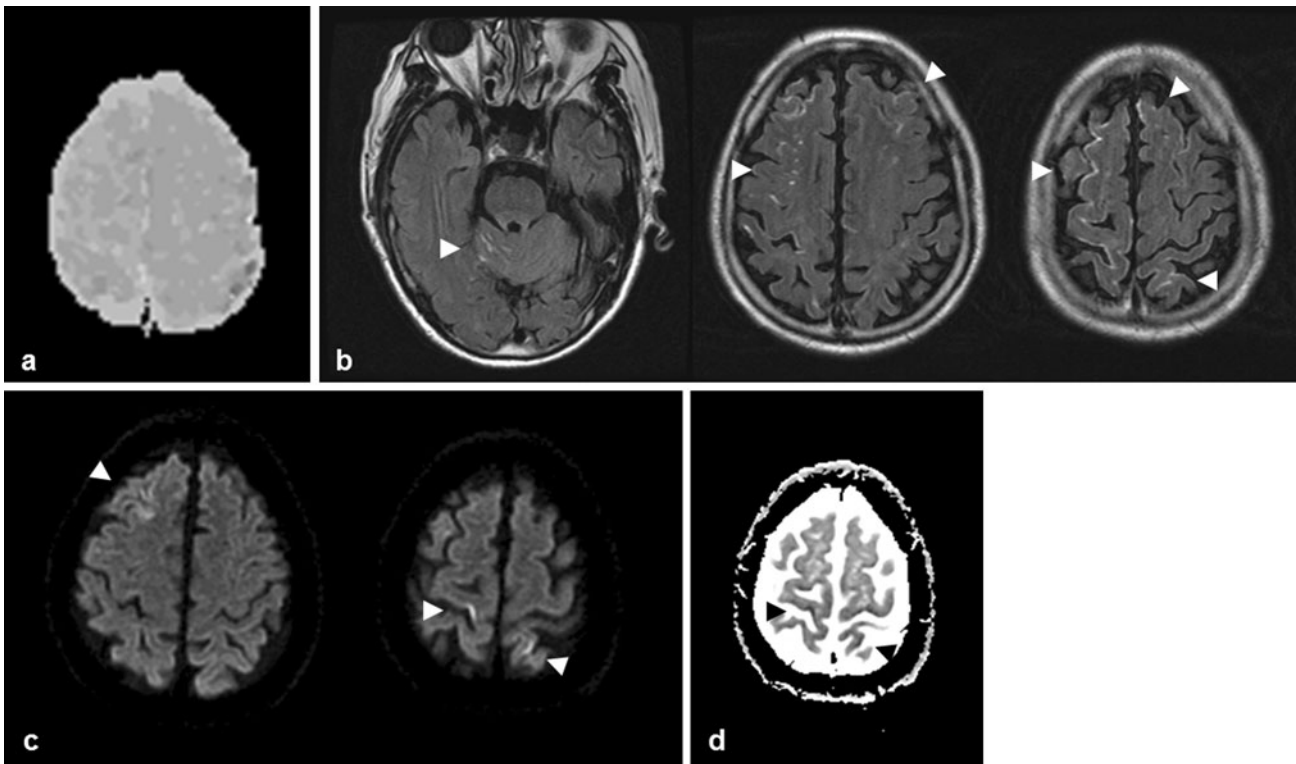


Fig. 1 Brain MRI of the patient. **a** The time-to-minimum-perfusion map demonstrates no perfusion deficit. **b** FLAIR images obtained 2 h after symptom onset show postgadolinium CSF enhancement.

c-d Diffusion-weighted and apparent diffusion coefficient images obtained 18 h later show multiple areas of restricted diffusion affecting cortical areas in the bilateral hemispheres

pulmonary arterial tree, and may produce cardiac and pulmonary compromise [4]. Clinically this manifests as transient hypotension and hypoxia, as seen in our patient [3]. Air can enter the arterial circulation through an intracardiac shunt or by directly crossing the pulmonary capillary bed [1, 3]. Although brain CT or diffusion-weighted MRI may show air embolism, they are not sensitive [1, 4, 5]. In our patient, these imaging modalities showed no intracranial air, cerebral ischemia or edema, despite the presence of neurologic deficits at the times of imaging. Arterial air emboli can irritate the arterial endothelium mechanically or act as a foreign body, promoting inflammation and endothelial damage [3, 4]. Under normal conditions, gadolinium-containing compounds do not cross the blood–brain barrier (BBB) [6]. Extravasation of the gadolinium-containing compounds into cerebral spinal fluid (CSF) results in a shortening of T1, poor fluid signal suppression on FLAIR MRI, and hyperintensity of the CSF space [6]. This case illustrates that air embolism can disrupt BBB and cause neurologic deficits in the absence of radiologic evidence of vascular occlusion, reduced cerebral perfusion, and infarction in the hyperacute stage. Postgadolinium CSF enhancement may be an early, sensitive predictor of BBB disruption and impending infarction after air embolism.

Acknowledgments This study was supported by a grant of the Korea Healthcare Technology R&D Project, Ministry of Health and Welfare, Republic of Korea (A102065).

Conflict of interest The authors declare that they have no conflict of interest.

References

1. Brockmeyer J, Simon T, Seery J, Johnson E, Armstrong P (2009) Cerebral air embolism following removal of central venous catheter. *Mil Med* 174:878–881
2. Murphy A, Torres C, Lum C, Hogan M, Bussiere M (2011) Whole brain CT Perfusion after cerebral air embolism. *Can J Neurol Sci* 38:522–525
3. Muth CM, Shank ES (2000) Gas embolism. *N Engl J Med* 342:476–482
4. van Hulst RA, Klein J, Lachmann B (2003) Gas embolism: pathophysiology and treatment. *Clin Physiol Funct Imaging* 23: 237–246
5. Droghetti L, Giganti M, Memmo A, Zatelli R (2002) Air embolism: diagnosis with single-photon emission tomography and successful hyperbaric oxygen therapy. *Br J Anaesth* 89:775–778
6. Latour LL, Kang DW, Ezzeddine MA, Chalela JA, Warach S (2004) Early blood–brain barrier disruption in human focal brain ischemia. *Ann Neurol* 56:468–477