

## Case report

## Multiple endocrine neoplasia type I presenting as recurrent stroke like episodes

Praveen Kesav<sup>a</sup>, Dheeraj Khurana<sup>a,\*</sup>, Sanjay Bhadada<sup>b</sup>, Ritambhara Nada<sup>c</sup>, Ashim Das<sup>c</sup>, Vivek Lal<sup>a</sup><sup>a</sup> Department of Neurology, Post Graduate Institute of Medical Education and Research (PGIMER), Chandigarh 160012, India<sup>b</sup> Department of Endocrinology, Post Graduate Institute of Medical Education and Research (PGIMER), Chandigarh 160012, India<sup>c</sup> Department of Histopathology, Post Graduate Institute of Medical Education and Research (PGIMER), Chandigarh 160012, India

## ARTICLE INFO

## Article history:

Received 21 March 2013

Accepted 17 May 2013

Available online 5 June 2013

## Keywords:

Metabolic disorders

Cerebrovascular diseases

Neuroimaging

Neurointensive care

Seizures

## 1. Introduction

Multiple endocrine neoplasia type I (MEN-I) is an uncommon disease affecting 1 in 30,000 individuals worldwide [1]. Both sporadic and familial forms have been described. Sporadic forms present with two of the three principal MEN-I related endocrine tumours (pituitary, pancreatic and/or parathyroid) while the familial form consists of a MEN-I case with at least one first degree relative showing one of the endocrine characterising tumours. Primary hyperparathyroidism (PHPT) is the most common and usually the presenting manifestation of MEN-I affecting more than 95% of all patients.

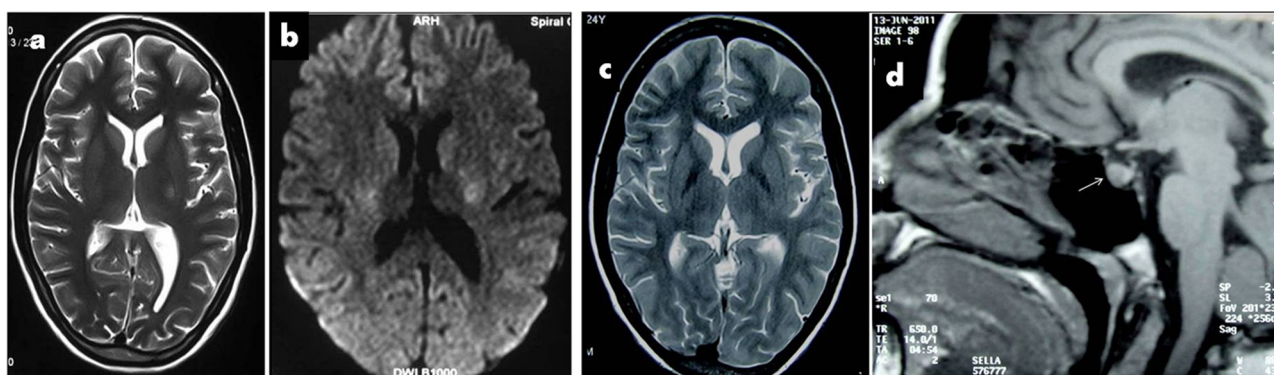
## 2. Case report

A 23 year old female presented with right sided weakness and progressive altered sensorium with recurrent generalised seizures of 72 h duration. Previously she had three episodes of self-remitting right sided hemiplegia in the last two years. She

had history of migraine without aura and recurrent renal stones for which she underwent percutaneous nephrolithotomy. Family history was unremarkable. On examination, she was comatose with generalised spasticity and hyperreflexia without focal neurological deficits. Investigations revealed normal hemogram and serum biochemistry. Cerebrospinal fluid (CSF) analysis was normal; CSF/serum lactate was 0.21. Surface 16 channel electroencephalogram (EEG) revealed diffuse theta range background slowing without epileptiform discharges. Electrocardiogram (ECG) showed a corrected QTc interval of 0.32 s (normal: 0.36–0.44 s). Serum calcium, phosphorous and magnesium were 14.6 mg/dl (normal: 8.6–10.2 mg/dl), 1.1 mg/dl (normal: 2.5–4.5 mg/dl) and 1.89 mg/dl (normal: 1.6–2.6 mg/dl) respectively. 24 h urinary calcium was 438 mg/day (normal: 100–300 mg/day). Intact parathyroid hormone (iPTH) was 167.8 pg/ml (15–45 pg/ml). Abdominal ultrasonography (USG) revealed bilateral nephrolithiasis and USG neck revealed well defined 10 mm × 6 mm lobulated hypoechoic lesion posterior to inferior pole of right thyroid lobe and a 22 mm × 12 mm lesion posterior to the superior pole of left thyroid lobe suggestive of right inferior and left superior parathyroid adenoma. A 99m Technetium Sestamibi scan showed hypermetabolic lesions in right inferior and left superior parathyroid glands suggestive of parathyroid adenoma. Cranial MRI revealed nonenhancing T2 hyperintensities in bilateral posterior limb of internal capsule, corona radiata, centrum semiovale, anterior aspect of pons with

\* Corresponding author. Tel.: +91 172 2756695.

E-mail addresses: [pkesav@ymail.com](mailto:pkesav@ymail.com) (P. Kesav), [dherajk@yahoo.com](mailto:dherajk@yahoo.com) (D. Khurana), [bhadadask@rediffmail.com](mailto:bhadadask@rediffmail.com) (S. Bhadada), [ritamduseja@hotmail.com](mailto:ritamduseja@hotmail.com) (R. Nada), [ashim126@gmail.com](mailto:ashim126@gmail.com) (A. Das), [vivekl44@yahoo.com](mailto:vivekl44@yahoo.com) (V. Lal).



**Fig. 1.** Baseline cranial MRI showing (a) T2 hyperintensities in posterior limb of internal capsule and (b) restricted diffusion in posterior limb of internal capsule bilaterally on DWI. (c) One month follow up cranial MRI revealing resolution of T2 hyperintensities in posterior limb of internal capsule. (d) Three months follow up Gadolinium enhanced cranial MRI showing sellar mass involving the pituitary with patchy enhancement without pressure effects.

diffusion restriction (Fig. 1a and b). MR angiography of neck and intracranial vessels was normal. Prothrombotic work up (Factor V Leiden mutation, protein C, S, anti thrombin III deficiency, serum homocysteine levels and anti phospholipid antibody levels) was negative. A diagnosis of primary hyperparathyroidism associated hypercalcemia induced encephalopathy was considered. Hypercalcemia was treated with hydration, diuretics and bisphosphonates.

Following parathyroid adenectomy, histopathology revealed features suggestive of parathyroid adenoma (Fig. 2a). At discharge she was conscious, oriented with normal biochemistry (serum calcium: 9.6 mg/dl, serum phosphorous: 4.2 mg/dl, iPTH: 27.9 pg/ml) with parallel improvement in neuroimaging findings (Fig. 1c). She was treated with oral calcium and calcitriol. Three months later, she was readmitted with acute onset altered sensorium without associated deficits or seizures. Her blood glucose was 36 mg/dl. She regained consciousness on administration of 100 ml 25% dextrose. Her fasting insulin and C peptide levels were 6.17  $\mu$ u/ml (normal: 2.6–24.9) and 1.7 ng/ml (normal: 1.1–4.4) respectively with a corresponding fasting plasma glucose of 25 mg/dl (normal: 70–100). Serum gastrin levels were 19.80 pg/ml (normal: 13.0–115). USG abdomen revealed a hypoechoic lesion in the head of pancreas. Biphasic contrast CT abdomen revealed a hyper-vascular lesion in the pancreatic head. Endoscopic USG of the abdomen revealed a well defined 1.5 cm  $\times$  1.4 cm lesion in the head of pancreas. She underwent laparotomy with enucleation of two lesions; one in head and uncinata process (intrapancreatic) and other in tail of pancreas. Histopathology revealed insulinoma in head (Fig. 2(b) and (c)) and adenoma in tail of the pancreas. Follow up neuroimaging revealed patchy enhancing sellar mass involving the pituitary without significant pressure on the surrounding tissues (Fig. 1d). Hormonal analysis revealed a non functioning pituitary tumour. The patient is being periodically checked for visual fields and hormonal analysis. She has had no further episodes of hypoglycemia or altered sensorium. The constellation of parathyroid adenoma, pancreatic adenoma and pituitary lesion prompted testing for MEN-I mutation (RT PCR of MEN I mRNA with genome sequencing), which was positive (Fig. 2(d) and (e)).

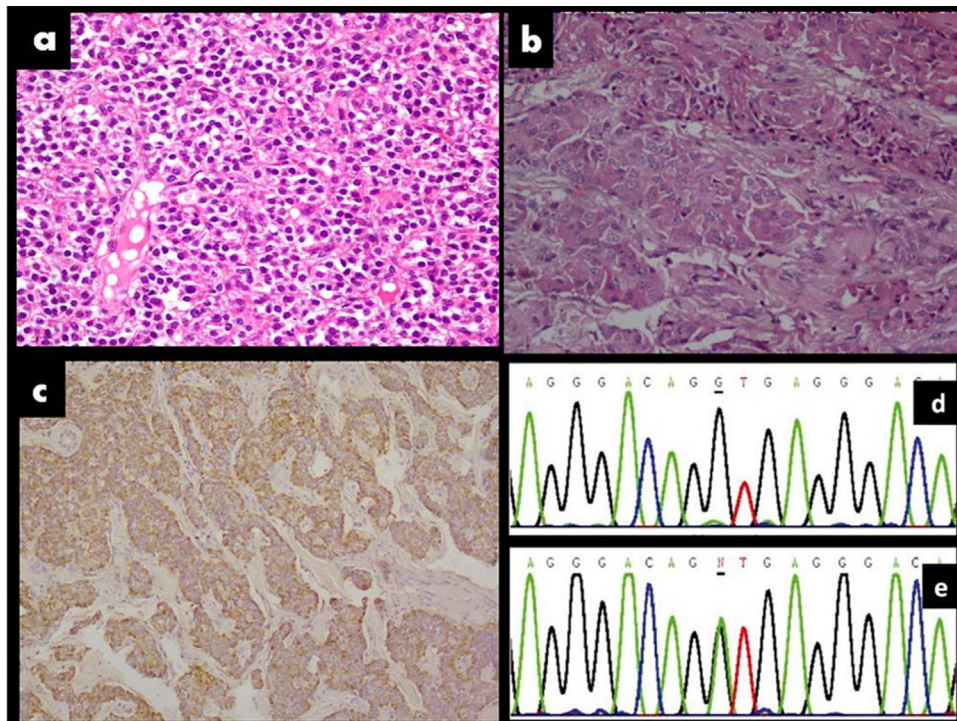
### 3. Discussion

Multiple endocrine neoplasia type I (MEN-I) or Wermer's syndrome is characterised by co-occurrence of tumours of parathyroids, pancreas and anterior pituitary gland [1]. The causative mutation involves the putative tumour suppressor gene,

MEN-I gene encoding menin protein located on chromosome 11q13 [2]. Primary hyperparathyroidism is the most common feature of MEN-I occurring in more than 95% patients, age of onset being 20–25 years [3]. Clinical manifestations of hypercalcemia due to MEN-I associated PHPT include neurological (altered mentation, depression, seizures and rarely focal neurological deficits), gastrointestinal (anorexia, constipation, nausea and vomiting), renal (polyuria, nocturia, nephrolithiasis), skeletal (increased fracture risk) and cardiovascular (hypertension, shortened QTc interval). Reversible focal neurological deficits in hypercalcemia are attributed to possible brain parenchymal changes secondary to hypercalcemia induced reversible cerebral vasoconstriction syndrome [4]. Parathyroidectomy (total/subtotal) is the effective treatment modality of symptomatic hypercalcemic MEN-I patients as was observed in our patient with complete and sustained resolution of metabolic parameters following subtotal parathyroidectomy. The reversible neuroimaging abnormalities observed in our patient temporally correlated with hypercalcemia, with complete resolution associated with normalisation of clinical and biochemical parameters on correction of hypercalcemia, probably due to hypercalcemia induced cytotoxicity [5] (Fig. 1 (a)–(c)).

Pancreatic tumours occur in about 30–80% of MEN-I patients, the most common functional tumours being gastrinomas and insulinomas. About one-third of pancreatic tumours are non functional. Combination of endoscopic ultrasonography (EUS) and octreoscan scintigraphy increases the pancreatic tumour detection rate to 90%. Our patient had inappropriately elevated fasting C peptide levels in the setting of hypoglycaemia, with EUS revealing a pancreatic lesion, which was duly resected and on histopathological evaluation turned out to be insulinoma.

Incidence of pituitary adenomas in MEN-I varies from 15% to 90%. They manifest either on account of the effects of hormones secreted by them or pressure effects on neighbouring structures (visual field defects, headache and/or blurred vision). Approximately 60% of pituitary tumours secrete prolactin, 25% secrete growth hormone and 3% secrete adrenocorticotrophin (ACTH) and the remaining seems to be non functional [1]. Our patient had an incidentally detected non functioning pituitary tumour on follow up neuroimaging, for which she is on conservative management on account of lack of pressure effects. The other associated tumours in MEN-I include adrenal neoplasms (up to 20–40%), thyroid neoplasms (up to 25%), carcinoid tumours (up to 10% involving bronchi, gastrointestinal tract, pancreas, thymus), facial angiofibroma,



**Fig. 2.** (a) Histopathology (H & E stain) of right inferior parathyroid showing monomorphic tumour cells with moderate amount of eosinophilic cytoplasm, large nucleus and inconspicuous nucleoli without mitoses or dysplasia, suggestive of parathyroid adenoma. (b) Histopathology section (H & E stain) from head of pancreas showing tumour cells arranged in sheets and nests with moderate nuclear pleomorphism, stippled chromatin, prominent nucleoli and moderate amount of granular eosinophilic cytoplasm. (c) Immunohistochemistry for insulin is positive (brown colour). (d) Genome sequence analysis of MEN 1 gene located on chromosome 11q13 in healthy control with normal sequence at exon 9 (G). (e) Genome sequence analysis of MEN 1 gene of patient showing reduced expression at position exon 9 (N). (For interpretation of the references to colour in this figure legend, the reader is referred to the web version of the article.)

collagenoma, lipoma and meningioma. Early detection and prompt treatment of the potential malignant neuroendocrine tumours in MEN-I reduces the morbidity and mortality associated with MEN-I syndrome.

#### 4. Conclusion

MEN-I, a relatively rare syndrome may present in myriad forms, recurrent stroke like episodes being one of them. To the best of our knowledge, this novel mode of presentation of MEN.I syndrome has not been reported in the world literature before. Hence it is prudent to consider metabolic etiologies like hypercalcemia for unexplained recurrent focal neurological deficits.

#### Conflict of interest

None.

#### Source of funding

None.

#### References

- [1] Pannett AAJ, Thakker RV. Multiple endocrine neoplasia type I. *Endocrine-Related Cancer* 1999;6:449–73.
- [2] Chandrasekharappa SC, Guru SC, Manickam P, Olufemi SE, Collins FS, Emmert-Buck MR, et al. Positional cloning of the gene for multiple endocrine neoplasia-type 1. *Science* 1997;276:404–7.
- [3] Trump D, Farren B, Wooding C, Pang JT, Besser GM, Buchanan KD, et al. Clinical studies of multiple endocrine neoplasia type 1 (MEN1) in 220 patients. *Quarterly Journal of Medicine* 1996;89:653–69.
- [4] Yarnell PR, Caplan LR. Basilar artery narrowing and hyperparathyroidism: illustrative case. *Stroke* 1986;17:1022–4.
- [5] Patten BM, Pages M. Severe neurological disease associated with hyperparathyroidism. *Annals of Neurology* 1984;15:453–6.