

Efficacy of lacosamide on seizures and myoclonus in a patient with *epilepsia partialis continua*

Maddalena Spalletti¹, Angela Comanducci¹,
Alessandro Vagaggini², Luca Bucciardini³,
Antonello Grippo¹, Aldo Amantini¹

¹ Unit of Clinical Neurophysiology

² Unit of Neurosurgery 1

³ Neurointensive Care Unit, DAI of Neurosciences, Azienda Ospedaliero-Universitaria Careggi, Florence, Italy

Received October 30, 2012; Accepted February 17, 2013

ABSTRACT – A 39-year-old male with *epilepsia partialis continua*, refractory to first- and second-line antiepileptic drugs, is described. Lacosamide produced a progressive antiepileptic effect on Jacksonian motor seizures and subsequently on positive myoclonus, which developed into negative myoclonus before complete resolution. Our report confirms the efficacy of lacosamide on focal motor refractory status epilepticus and documents a unique effect of lacosamide on seizure semiology.

Key words: lacosamide, refractory status epilepticus, *epilepsia partialis continua*, myoclonus, negative myoclonus

Lacosamide (LCM) is approved in the US and Europe as add-on treatment for partial seizures with or without secondary generalisation. Its efficacy in focal refractory status epilepticus (RSE) has been described in previous case reports (Tilz *et al.*, 2010) and retrospective studies (Höfler *et al.*, 2011; Kellinghaus *et al.*, 2011; Cherry *et al.*, 2012).

We describe a case of RSE with *epilepsia partialis continua* (EPC) presenting as both focal myoclonus and focal motor seizures. Intravenous administration of LCM provided resolution of status epilepticus (SE) through a peculiar and grad-

ual change of semiology. In particular, continuous irregular myoclonic jerks associated with Jacksonian motor seizures became exclusively myoclonic jerks, which eventually developed into negative myoclonus, followed by complete resolution.

Case study

A 39-year-old male patient without any previous relevant medical history was admitted to the hospital complaining of left hemiparaesthesia. A chronic subdural haematoma in the right hemisphere was found and the patient underwent surgical

Correspondence:

Aldo Amantini
Unit of Clinical Neurophysiology,
DAI Neurosciences,
Azienda Ospedaliero-Universitaria
Careggi,
Largo Brambilla,
3-50134 Florence, Italy
<amantini@unifi.it>

evacuation. It was later determined that a few months before hospital admission, the patient had suffered mild non-physical head trauma for which he did not seek medical attention. Shortly after surgery, the patient was discharged without neurological signs or symptoms. Eight days post-surgery, left arm motor focal seizures began to occur. Recurrence of a right hemispheric subdural haematoma was diagnosed by CT. Oral levetiracetam (LEV; 500 mg twice daily [bid] was administered). Two days later, seizures became clustered and frequent, resulting in focal SE. Seizures were only partially attenuated by repeated intravenous administration of diazepam boluses (10+10+5 mg). Surgery was performed a second time on the recurrent subdural haematoma, however, upon regaining consciousness post-surgery, the patient still suffered with frequent seizures and a continuous irregular myoclonus of the left wrist and finger extensor (ECD; *extensor communis digitorum*) muscles. Intravenous LEV (1,500 mg bolus, then 1,000 mg bid) and subsequent administration of phenytoin (15 mg/kg bolus, then 150 mg three times daily) were ineffective against both seizures and myoclonus. The patient was then transferred to a neurological intensive care unit (ICU). Seizures were partially attenuated with midazolam (MDZ; 5 mg), thus continuous intravenous low-dose MDZ (0.05 mg/kg/h) was administered without any requirement of respiratory assistance.

The following morning, SE was still present and manifested as continuous focal myoclonus and frequent left arm motor seizures. During a 30-minute standard EEG, two seizures were recorded. Ictal focal epileptiform discharges arising from right central areas were associated with Jacksonian motor spread of the seizure to the upper left limb (*figure 1A*). Contralateral spreading of ictal discharges was variable, but associated with brief impairment of consciousness. Between seizures, right central periodic lateralised epileptiform discharges (PLEDs) were observed on the EEG, which were myoclonus-related (cortical myoclonus, lasting for 100-120 ms; *figure 1B*). Immediately before the seizures, PLEDs were more abundant and enriched with fast activity (PLEDs-plus; *figure 1C*). Plasma levels of phenytoin were found to be within the therapeutic range (13 µg/mL), thus a third AED was added.

Intravenous LCM (200 mg, then 200 mg bid) caused the motor seizures to stop within one hour. Focal clonic seizures were absent, but continuous positive myoclonus of the left wrist and finger extensors persisted for 48 hours. LEV and MDZ were gradually discontinued. On the third day following administration of LCM, positive myoclonus ceased and negative myoclonus of the same muscles developed. A video-polygraphic EEG showed that negative myoclonus (duration of 80-110 ms) was associated

with low-amplitude PLEDs (cortical epileptic negative myoclonus [ENM], *figure 1D*). The day after ENM was resolved, the patient was seizure-free, fully conscious, and able to regain complete use of his left arm.

The patient was discharged with oral LCM therapy (200 mg bid), and phenytoin was progressively discontinued. An EEG after one month showed normal background rhythm and absence of PLEDs. After six months, the patient was both seizure and myoclonus-free with LCM monotherapy.

Discussion

Efficacy of LCM for the treatment of focal RSE has been reported by several studies in the last few years. Seizure control has been described in 44-80% of patients and appears to correlate with the timing of administration (Höfler *et al.*, 2011; Kellinghaus *et al.*, 2011). Despite focal motor SE refractory to benzodiazepines and two AEDs, the described case showed a clear response to intravenous administration of LCM, leading to complete resolution. The observed gradual changes in epileptic semiology after administration of LCM were particularly unusual. In particular, Jacksonian motor seizures ceased within an hour and positive myoclonus persisted for two days, eventually developing into ENM which ceased within 24 hours. EEG patterns showed a similar evolution, beginning with the cessation of seizure-related, high-frequency, spike discharges. While separate, periodic, paroxysmal potentials persisted, amplitude reduction was observed when myoclonus changed from positive to negative. This effect on EEG is consistent with previous reports on experimental models of focal SE, in which LCM initially decreased spike frequency and interrupted seizures, although individual spike activity persisted for many hours (Beyreuther *et al.*, 2007).

Some AEDs, such as carbamazepine, oxcarbazepine, and phenytoin, have been shown to potentially induce seizure worsening and ENM in benign childhood epilepsy with centrotemporal spikes (BECTS) (Parmeggiani *et al.*, 2004). Recently, a case of LCM-induced ENM was reported when LCM was combined with carbamazepine (Belcastro *et al.*, 2011). In the described case study, negative myoclonus was unlikely to have been related to worsening of epilepsy or a genuine collateral effect, since it appeared after progressive clinical improvement. Similarly, EEG improved with initial cessation of focal ictal discharges, followed by progressive reduction of amplitude and then cessation of PLEDs, resulting in complete resolution of SE. This differs significantly from the increased frequency of seizures and paroxysmal activity that has been observed in BECTS. Furthermore, when ENM is attributed to tapering of GABAergic AEDs,

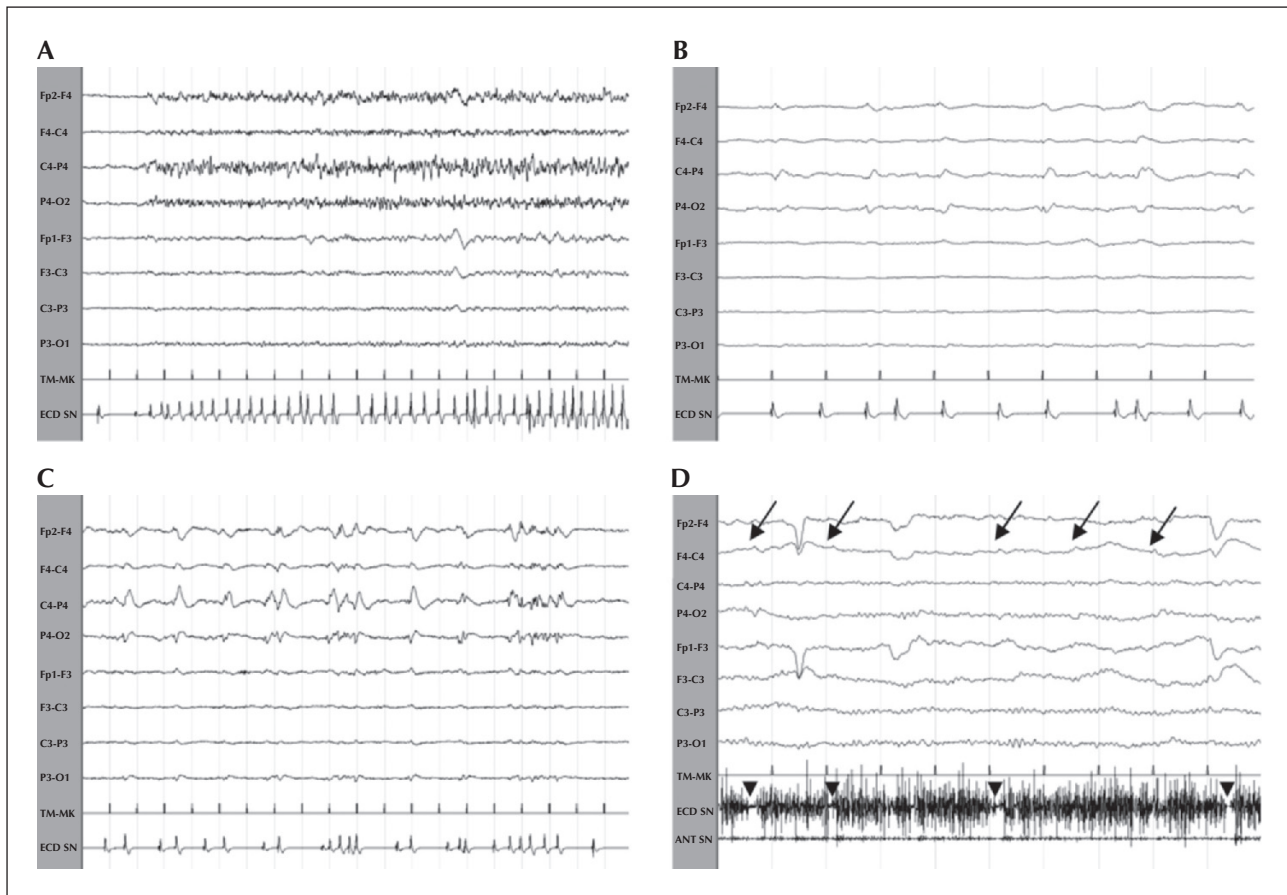


Figure 1. Evolution of polygraphic EEG pattern.

EEG was recorded in the ICU before LCM treatment (A-C) and three days after the beginning of LCM treatment (D). (A) Right fronto-central ictal discharge associated with a Jacksonian motor seizure involving the left arm. (B) Right central PLEDs related to left wrist/finger extensor ECD positive myoclonus. (C) Right central PLEDs-plus associated with ECD myoclonus, preceding the Jacksonian seizure. (D) Residual, right-sided PLEDs of very low amplitude (arrows), inconstantly associated with very brief drops of tonic ECD electromyographic activity, while hands remained outstretched (negative myoclonus; arrowheads).

an overall worsening of seizures is usually reported (Gambardella *et al.*, 1997). Therefore, we postulate that ENM with a decreased diffusion of epileptic activity may constitute an antiepileptic effect of LCM, rather than a “paradoxical effect” of decreased GABAergic inhibition due to cessation of LEV and MDZ. Interestingly, in our case, amplitude reduction of PLEDs coincided with the conversion from positive to negative myoclonus. This is consistent with evidence showing that intracranial electrical stimulation of the sensorimotor cortex in humans can induce positive or negative phenomena depending on high or low intensity of electrical stimuli. Alternatively, a minor diffusion of epileptic activity may restrict ictal discharge to motor areas most capable of producing negative motor phenomena (Rubboli *et al.*, 2006). In line with this, efficacy of LCM in inhibiting the seizure spread and ictal

activity has been reported in several animal models (Beyreuther *et al.*, 2007).

Treatment guidelines for generalised tonic-clonic SE are widely accepted and available. More debatable are the treatment protocols for focal SE, which is not considered immediately life-threatening and therefore the use of non-sedative agents for the first 24-36 hours is commonly recommended, such that the risk of ICU complications does not outweigh the benefit of rapid seizure control (Rossetti and Lowenstein, 2011). In this way, availability of different AEDs for focal RSE is of particular importance because it increases treatment choices and avoids the necessity to proceed with sedative and anaesthetic drugs in the ICU. □

Disclosures.

None of the authors has any conflict of interest to disclose.

References

Belcastro V, Arnaboldi M, Taborelli A, Prontera P. Induction of epileptic negative myoclonus by addition of lacosamide to carbamazepine. *Epilepsy Behav* 2011; 20: 589-90.

Beyreuther BK, Freitag J, Heers C, Krebsfänger N, Scharfenecker U, Stöhr T. Lacosamide: a review of preclinical properties. *CNS Drug Rev* 2007; 13: 21-42.

Cherry S, Judd L, Muniz JC, Elzawahry H, Laroche S. Safety and efficacy of lacosamide in the intensive care unit. *Neurocrit Care* 2012; 16: 294-8.

Gambardella A, Aguglia U, Oliveri RL, Russo C, Zappia M, Quattrone A. Negative myoclonic status due to antiepileptic drug tapering: report of three cases. *Epilepsia* 1997; 38: 819-23.

Höfler J, Unterberger I, Dobesberger J, Kuchukhidze G, Walser G, Trinka E. Intravenous lacosamide in status epilepticus and seizure clusters. *Epilepsia* 2011; 52: e148-52.

Kellinghaus C, Berning S, Immisch I, et al. Intravenous lacosamide for treatment of status epilepticus. *Acta Neurol Scand* 2011; 123: 137-41.

Parmeggiani L, Seri S, Bonanni P, Guerrini R. Electrophysiological characterization of spontaneous and carbamazepine-induced epileptic negative myoclonus in benign childhood epilepsy with centro-temporal spikes. *Clin Neurophysiol* 2004; 115: 50-8.

Rossetti AO, Lowenstein DH. Management of refractory status epilepticus in adults: still more questions than answers. *Lancet Neurol* 2011; 10: 922-30.

Rubboli G, Mai R, Meletti S, et al. Negative myoclonus induced by cortical electrical stimulation in epileptic patients. *Brain* 2006; 129: 65-81.

Tilz C, Resch R, Hofer T, Eggers C. Successful treatment for refractory convulsive status epilepticus by non-parenteral lacosamide. *Epilepsia* 2010; 51: 316-7.