

Acute Encephalopathy with Unilateral Cortical-Subcortical Lesions in Two Unrelated Kindreds Treated with Glucocorticoids Prenatally for Congenital Adrenal Hyperplasia due to 21-Hydroxylase Deficiency: Established Facts and Novel Insight

Sebastian Grunt^a Maja Steinlin^a Christian Weisstanner^b Martin Schöning^d
Primus E. Mullis^c Christa E. Flück^c

^aDepartment of Pediatrics, Division of Neuropediatrics, Development and Rehabilitation, University Children's Hospital, University Hospital Inselspital, ^bInstitute of Diagnostic and Interventional Neuroradiology, University Hospital Inselspital, and ^cDepartment of Pediatrics, Division of Endocrinology, Diabetology and Metabolics, University Children's Hospital, Bern, Switzerland, and ^dDepartment of Child Neurology, University Children's Hospital, Tübingen, Germany

Established Facts

- Prenatal dexamethasone treatment of female fetuses suffering from 21-hydroxylase deficiency may prevent virilization of the external genitalia and androgenization of the brain.
- However, prenatal dexamethasone therapy remains controversial because of possible adverse effects on programming of the fetal hypothalamus-pituitary-adrenal axis, on the cardiovascular system and on structure, development and neuroendocrine function of the brain.

Novel Insights

- Acute encephalopathy in children with 21-hydroxylase deficiency may be associated with diffuse white matter lesions and focal cortical-subcortical lesions.
- Two unrelated congenital adrenal hyperplasia patients who were treated with dexamethasone in utero presented with acute encephalopathy and multifocal cortical-subcortical lesions.
- Is there a predisposition for cerebral lesions with prenatal glucocorticoid treatment and/or congenital adrenal hyperplasia?

Key Words

Acute encephalopathy · Congenital adrenal hyperplasia · Prenatal treatment · 21-Hydroxylase deficiency · Dexamethasone · Hypoglycemia

Abstract

Background: Prenatal glucocorticoid (GC) treatment of the female fetus with 21-hydroxylase deficiency (21-OHD) may prevent genital virilization and androgen effects on the brain, but prenatal GC therapy is controversial because of possible adverse effects on fetal programming, the cardiovascular system and the brain. **Case Reports:** We report 2 patients with congenital adrenal hyperplasia (CAH) due to 21-OHD who were treated prenatally with dexamethasone, suffered from an acute encephalopathy and showed focal and multifocal cortical and subcortical diffusion restrictions in early MRI and signs of permanent alterations in the follow-up neuroimaging studies. Both patients recovered from the acute episode. Whereas the first patient recovered without neurological sequelae the second patient showed hemianopsia and spastic hemiplegia in the neurological follow-up examination. **Conclusion:** These are 2 children with CAH, both treated prenatally with high doses of dexamethasone to prevent virilization. The question arises whether prenatal high-dose GC treatment in patients with CAH might represent a risk factor for brain lesions in later life. Adverse effects/events should be reported systematically in patients undergoing prenatal GC treatment and long-term follow-up studies involving risk factors for cerebrovascular disease should be performed.

Copyright © 2013 S. Karger AG, Basel

Introduction

Congenital adrenal hyperplasia (CAH) affects approximately 1 in 10,000–20,000 subjects in Western European countries [1, 2]. Patients with the classic form of CAH present typically in the second week of life with lethargy and vomiting due to salt loss because of mineralo- and glucocorticoid deficiency [1]. In addition, 46,XX patients with CAH present with variable degrees of virilization of the external genitalia which often need surgical correction in later life, and virilization of the brain which both may impact normal psychosexual development. Genetic mutations in the CYP21A2 gene are identified in about 9/10 patients manifesting with CAH. CYP21A2 mutations causing a loss or severe decrease of 21-hydroxylase activity (<5%) are associated with the classic form of salt-losing

or simple virilizing CAH, whereas milder forms may manifest as late-onset CAH. Thus there is good genotype-phenotype correlation for 21-hydroxylase deficiency (21-OHD), making this genetic disorder an excellent candidate for genetic counseling and prenatal treatment.

Loss of 21-hydroxylase activity in the human adrenal cortex affects steroidogenesis severely as both mineralo- and glucocorticoid production depend on this enzyme and blockade will lead to an accumulation of 17 α -hydroxyprogesterone and an increase in the production of adrenal C19 steroids (DHEA/-S, androstenedione) through central feedback mechanisms involving CRH and ACTH of the hypothalamus and pituitary gland [1–3]. Neonatal screening programs measuring serum 17 α -hydroxyprogesterone levels 3–4 days after birth have been established in most Western European countries to diagnose and treat CAH before affected newborns present with life-threatening Addison's crises. To avoid possible virilization of the female external genitalia, early prenatal treatment of siblings of CAH patients with synthetic steroids (mostly dexamethasone) has been suggested and pursued for more than 25 years [4, 5]. However, although prenatal treatment was shown to prevent or grossly minimize virilization of the external genitalia in CAH girls [6–8], this therapy remains controversial for several reasons [9–16]: First, mothers who are treated with dexamethasone may suffer from side effects such as excessive weight gain, hypertension, edema, and diabetes. Second, as CAH is an autosomal recessive disorder, to prevent virilization in 1 CAH girl, 7 out of 8 fetuses will be exposed to dexamethasone treatment unnecessarily from around 6–12 weeks' gestation until fetal sexing reveals male sex or diagnosis is established. Third, even for affected female fetuses that will benefit from treatment in terms of virilization, it is thought that exposure to high doses of dexamethasone during fetal life might adversely affect the brain and the programming of the hypothalamus-pituitary-adrenal (HPA) axis resulting in a higher risk for metabolic and cardiovascular disorders, immunosuppression, and alterations in behavior and cognitive function in later life [13–19]. Therefore, experts in the field advise to treat within controlled clinical studies or, at least, report possible side effects of prenatal treatment [2].

Here we present the detailed medical history of 2 unrelated CAH patients who were both treated with glucocorticoids prenatally and suffered from focal brain lesions in their first decade of life. We discuss the association between prenatal glucocorticoid exposure and the brain lesions as well as possible pathophysiological mechanisms.

Case Reports

Patient 1

This Swiss girl was the second child of a mother who gave prior birth to a boy diagnosed with CAH due to 21-OHD through newborn screening. Genetic analysis revealed compound heterozygosity for a splicing mutation in intron 2 (c.656A>G) (known to cause loss of 21-hydroxylase activity from functional assays [20]), and the missense mutation I172N in exon 4 (2–4% activity) of the CYP21A2 gene; thus, prenatal diagnosis and treatment was offered as an option for further pregnancies to prevent virilization of a female fetus after detailed information of both parents. Five weeks into the second pregnancy, dexamethasone treatment (0.5 mg tid) was started after obtaining allowance for compassionate use by Swiss Medic and informed consent by parents. However, the patient was not enrolled in a specific (follow-up) study. Diagnostic evaluation at 12 weeks' gestation revealed a 46,XX fetus carrying CYP21A2 mutations on both alleles. Therefore, to prevent virilization of the female external genitalia, dexamethasone treatment was continued throughout pregnancy. During this second pregnancy the mother gained 20 kg of weight and intrauterine fetal growth was noted to be attenuated. At 37⁴/₇ weeks' gestation the child was born by cesarean section with a weight of 1,930 g (–3.2 SDS), length of 45.5 cm (–1.8 SDS), and head circumference of 33.5 cm (–1.6 SDS). Her external genitalia were normal female without any signs of virilization (Prader 1). Ultrasound showed a normal uterus and adrenals and genitogram revealed a normal vagina and a perfectly separated female urethra. Because of postnatal lethargy and hypoglycemia she was treated with stress dose hydrocortisone and antibiotics for 5 days. Thereafter, she was put on fludrocortisone and hydrocortisone replacement treatment and discharged from hospital at day 25 of life. During an upper respiratory tract infection at age 13 months and gastroenteritis at age 4 years, the girl was hospitalized for 2 days for intravenous fluid and hormonal replacement therapy. Otherwise follow-up visits in our outpatient clinic at 3-month intervals revealed good metabolic control on treatment with 12–18 mg/m²/day hydrocortisone given in three doses and 75 µg/day fludrocortisone given in two doses. Growth and psychomotor development were normal.

At 5³/₁₂ years of age the girl was brought to our emergency department unconscious, with a blood glucose of 3.8 mmol/l and a mean arterial blood pressure of 80/30 mm Hg (normal range for age and height: 90/55 mm Hg) without any signs for ongoing infection. By history, she was brought to bed in good health and had her normal steroid replacement the day before, but did not wake up the following morning. Physical examination revealed a Glasgow Coma Scale of 6, pupils were reactive and isocor but intermittent eye deviation to the left was noted. No signs of hemiplegia were observed on neurological examination. CT scan of the brain showed a cortical focal edema left temporal-occipital, no hemorrhage and no thrombosis of the venous sinus. Electroencephalogram (EEG) revealed a normal background activity with decreased amplitude of left hemispheric activity. Initial treatment consisted of 50 mg hydrocortisone and a bolus of glucose and volume, but arterial hypotension was only controlled by additional treatment with 2.5 µg/kg/min dobutamine for the initial 18 h. The patient regained consciousness over the next 12 h and thereafter was normal on neurological examination including symmetric, normal-reactive reflexes and negative Babinski sign. MRI scan

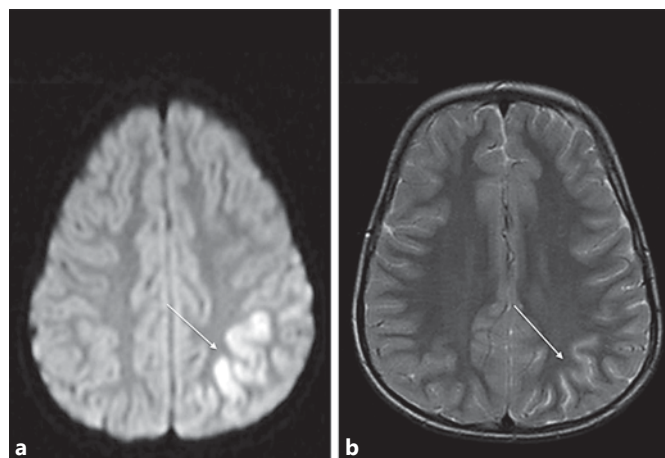


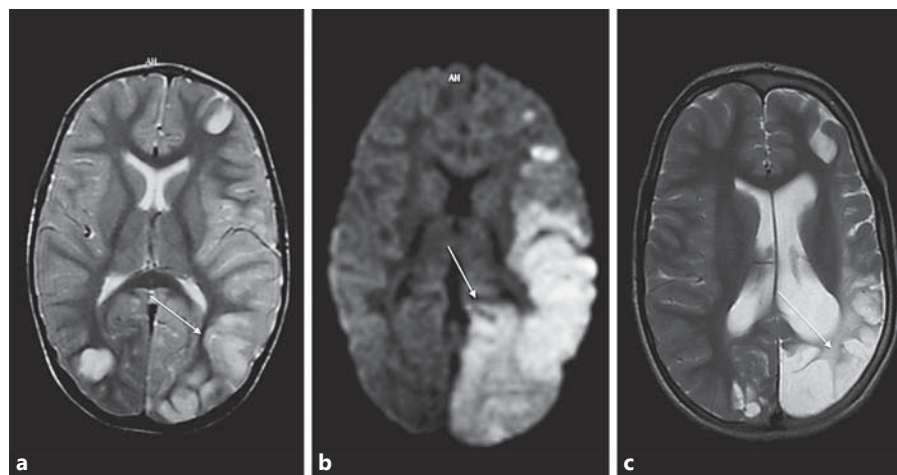
Fig. 1. Brain imaging studies of patient 1. **a** Cortical diffusion restriction in diffusion-weighted imaging in the left parietal lobe (arrow). **b** Follow-up 3 months later. Cortical hyperintensity in T2-weighted imaging in the same area with volume loss (arrow).

with diffusion-weighted images on day 5 showed focal diffusion restriction of the left parietal cortex (fig. 1a), these areas were also slightly hyperintense in T2-weighted imaging (not shown). A control MRI 3 months later revealed residual findings with thinning of cortex and hyperintensity in T2-weighted imaging (fig. 1b). Biochemical work-up for thrombotic risk factors including clotting factors and metabolic disorders revealed no abnormalities. Five months after the stroke, neuropsychological testing showed a normal IQ of 93 but minor deficits in visual-constructive function. At age 5¹⁰/₁₂ years the patient suffered from two focal seizures. EEG showed focal activity on the left parietal side. She was started on antiepileptic therapy with valproate. Meanwhile she is 13 years old, seizure-free without antiepileptic drugs, hormonally well controlled and developing normally.

Patient 2

This German boy was the second child to a mother who gave prior birth to a boy with 21-hydroxylase CAH. The first child was diagnosed at the age of 4¹/₂ years for accelerated growth and incomplete precocious puberty (pubic hair and penis enlargement only due to adrenal androgen overproduction). Genetic analysis of the CYP21A2 gene showed a common deletion on one allele and the I172N missense mutation on the other allele explaining late-onset CAH. With genetic counseling the possibility of prenatal dexamethasone treatment was explained. Five weeks into the second pregnancy the mother opted for prenatal dexamethasone treatment after giving informed consent. From week 5 to 12 of gestation she was given 1 mg dexamethasone daily until genetic analysis on chorionic villous biopsy material revealed a 46,XY fetus who was found to be compound heterozygote for both CYP21A2 mutations. Although the fetus was diagnosed with CAH, dexamethasone treatment was omitted because of male sex. No adverse effects of the treatment were noted in the mother, pregnancy was carried out to 39²/₇ weeks' gestation when the child was delivered spontaneously with a weight of 2,700 g (–2.4 SDS) and length of

Fig. 2. Brain imaging studies of patient 2. **a** Hyperintensity in T2-weighted imaging in the cortex of the left frontal, temporal and occipital lobe (arrow). There is also a focal hyperintense spot within the right occipital cortex. **b** Diffusion restriction mainly in the cortex of the left frontal, temporal and occipital lobe (arrow). Subcortical white matter in the temporo-occipital lobe is also involved. **c** Follow-up 5 years later. Volume loss with hyperintense cortex and subcortical white matter mainly in the left temporo-occipital lobe (arrow).



48 cm (−1.6 SDS). As the affected brother had non-salt-losing CAH, the baby was not immediately started on steroid replacement treatment but at day 16 of life he was admitted to hospital for vomiting, hyponatremia and hyperkalemia. No hyperpigmentation of the genital area was found but the serum 17-hydroxyprogesterone was grossly elevated to 54,690 ng/dl (normal range for birth to 5 days of age <420 ng/dl). Thus replacement therapy with fludrocortisone and hydrocortisone was started.

On treatment he did well until the age of 1¹⁰/₁₂ years when he was admitted to the emergency department unconscious with a history of falling from a trampoline 2 days earlier but without any symptoms within the first 24 h of the event. Irritability, vomiting, fever, diarrhea and hypoglycemia (0.9 mmol/l) developed within 24 h prior to admission. Glasgow Coma Scale was 5 at admission. Pupils were symmetrical but minimally reactive to light; abnormal eye deviations to the left and papillary edema were found. The child required intensive care treatment including artificial ventilation for 9 days and seizure therapy. Neurological examination 1 month after the event was abnormal for right-sided hemiparesis. An early MRI scan on day 2 after admission revealed extensive diffusion restriction on diffusion-weighted imaging (fig. 2b) and already hyperintensity in the T2-weighted sequence (fig. 2a) in the left parieto-occipital lobe, involving the cortex and medulla and to a lesser degree in the left middle and inferior frontal gyrus and in the right occipital lobe. Follow-up MRI 5 years later showed marked left-sided cortical and subcortical atrophy in the temporo-occipital lobe and smaller defects in the left frontal and right occipital lobe (fig. 2c). Fortunately, on clinical follow-up the neurological abnormalities were improving.

At age 8 years the boy was a second grader of a special school requiring no other medication than fludrocortisone and hydrocortisone replacement. His physical examination revealed a weight of 23 kg (−1.4 SDS) and height of 116.8 cm (−2.7 SDS). Head circumference was 50 cm (−2.3 SDS). By neurological examination, right hemianopsia, mild right-sided hemiparesis especially of the right arm, and generalized hyperactive reflexes on the right side of the body were noted.

Discussion

The patients we present in this report were both suffering from a sudden encephalopathic crisis and showed focal or multifocal cortical or subcortical diffusion restrictions in the early MRI and residual cortically predominant lesions on follow-up neuroimaging. Both patients suffered from CAH and had received prenatal glucocorticoid treatment and both did not have any history of known risk factors for cerebrovascular disease. Therefore, we hypothesized whether there might be a link between the encephalopathic crisis, the focal brain lesions and CAH and/or prenatal glucocorticoid treatment.

Publications regarding MRI abnormalities on neuroimaging in patients with CAH are scarce. A study which evaluated 22 patients with CAH without history of neurological symptoms during young adulthood found MRI abnormalities in as many as 45% of the cases involving diffuse and focal white matter abnormalities [21]. There was no correlation between abnormalities in neuroimaging and clinical features such as sex, phenotype, simple virilizing subtype, salt-wasting subtype, late-onset form, duration of disease and time of treatment. Furthermore, the etiology of the brain lesions in patients with CAH remained unknown and details with respect to prenatal treatment were not provided [21]. However, it may be concluded that patients with CAH seem to have an increased susceptibility for brain lesions, even without neurological manifestation. Another study described 3 patients with CAH who suffered from an acute encephalopathic crisis and presented different types of lesions in MRI [22]. Whereas 2 of the patients

exhibited diffuse white matter lesions, in the third patient diffusion-weighted imaging revealed cortical-subcortical focal high-intensity lesions in the right frontal lobe [22], which were very similar to those described in the presented cases.

Different pathophysiologic mechanisms might explain the cerebral lesions in patients with CAH presenting with acute encephalopathy as described in the presented cases. An acute arterial ischemic stroke (AIS) resulting from a focal interruption of the cerebral blood supply caused by vascular pathology or embolism may lead to focal lesions in the brain. In children, AIS is seen in 2–5/100,000 children per year with a boy to girl ratio of 2:1 [23–25]. Known risk factors include infectious, parainfectious reactions, vasculopathies, systemic disorders, heart defects and hereditary coagulopathies [26]. Investigations for risk factors in pediatric stroke patients revealed that more than half of the affected patients had more than one risk factor and only 11% had none [25]. Searching the current literature, we found a case of AIS in a 60-year-old untreated patient with CAH [27]. We did not find any other case description of AIS – neither in patients with CAH nor in patients who received prenatal steroid therapy. Thus, when discussing our 2 CAH patients who were treated prenatally with glucocorticoids and then presented with an ischemic lesion in preschool age, we suggest considering three possible scenarios: (1) there is no link between the three entities, (2) patients with CAH have a higher risk for AIS, and (3) exposure to glucocorticoids prenatally (or after birth) makes the brain susceptible for ischemic lesions in later life.

In the cases presented, the involved brain regions are not consistent with distinct vascular territories and therefore other mechanisms should be discussed. Whereas in patient 2 hypoglycemia was documented at admission, the serum glucose level was within the normal range in patient 1. A recent study described MRI findings in a series of 17 patients presenting with hypoglycemic encephalopathy [28]. Although unilateral diffusion restriction in the centrum semiovale has been described in 1 patient, all other patients showed bilateral symmetrical lesions, which involved the cortex, the deep gray matter and the white matter [28]. Another study performed in patients suffering from hypoglycemic encephalopathy confirmed that MRI lesions are mainly bilateral and symmetrical [29]. Patient 2 showed arterial hypotension at manifestation and arterial hypotension might have led to an interruption of the cerebral blood supply and consecutively to watershed infarcts. Possibly vascular pathologies in the

terminal vascular beds may have led to an increased susceptibility for ischemic lesions after a second hit (hypoglycemia and/or hypotension).

CAH or prenatal glucocorticoid treatment has not been reported as a risk factor for cerebrovascular disease in children [24–26]. Similarly, no CAH patient suffering from cerebrovascular events has been reported so far. In addition, we found no data suggesting that mineralo- and glucocorticoid deficiency and/or androgen excess may result in AIS. A direct association between AIS and CAH has also not been described in either children or adults. Falhammar et al. [30] compared 61 women with CAH with 61 age-matched controls with respect to body composition and cardiovascular risk factors, and did not find clear evidence of unfavorable risk for cardiovascular disease in women with CAH [30]. In contrast, it has been shown that adult women with classic CAH may show an increased diastolic blood pressure and that metabolic abnormalities such as obesity, hypercholesterolemia and insulin resistance may occur more frequently in this population [31]. Furthermore, Sartorato et al. [32] studied the glucose metabolism and measured the intima media thickness of the common carotids, carotic bulbs and common femoral arteries in adult patients with CAH. They found a reduced insulin sensitivity as well as an increased intima medial thickness in patients diagnosed with CAH [32]. Bearing in mind that an increased intima medial thickness is associated with an increased risk for cardiovascular events or stroke [33], this may put patients with CAH at risk. Nevertheless, although data gives suspicion of a higher cardiovascular risk for women with CAH, no definitive increased risk for AIS in patients with CAH may be deduced.

Prenatal glucocorticoid treatment is suspected to have many potential side effects through alteration of the programming of the fetal HPA axis [2, 14–16, 19]. Until recently, the fetal adrenal was thought to start biosynthesis of glucocorticoids only shortly before birth, predominantly for final maturation of the lungs [34]. However, even the need of glucocorticoids for final lung maturation was recently challenged by the remarkable case of an infant with a homozygote null mutation in the glucocorticoid receptor who presented with normal pulmonary development [35]. Thus the normal fetus was thought to live in a low glucocorticoid environment, and both maternal stress and treatment with synthetic glucocorticoids were blamed to adversely affect the HPA axis. However, Goto et al. [36] showed that early cortisol biosynthesis at around 8–9 weeks postconception is necessary to safeguard the female sexual development by de-

creasing adrenal androgen production through negative central feedback via ACTH, thereby explaining elegantly for the first time how prenatal dexamethasone treatment might work. One could therefore argue that prenatal exposure to glucocorticoids at around this time should not harm the fetus. However the typical dose of dexamethasone (20 µg/kg maternal weight) that is generally administered for the prevention of fetal virilization in CAH is about 3–6 times supraphysiological for the mother, and an affected fetus will be exposed to about 60 times higher cortisol concentrations than a normal fetus assuming that synthetic glucocorticoids cross the placenta freely and that fetal cortisol concentrations are about one tenth that of maternal concentrations in mid-pregnancy [37]. Most evidence for possible adverse effects of prenatal glucocorticoid treatment on the cardiovascular and/or central nervous system comes from animal studies. In sheep, antenatal dexamethasone administration was found to cause dysfunctions in the microvascular system [38] and alter cardiovascular hemodynamics and the baroreceptor-heart rate reflex [39]. Furthermore, reduced cerebral blood flow and decreased oxygen delivery were reported [40]. In animals, prenatal dexamethasone has also been shown to alter central nervous system programming through reduction of corticosteroid re-

ceptors in the hippocampus, thereby attenuating HPA axis feedback sensitivity [14]. The effect of prenatal glucocorticoid therapy on the human brain is also manifold [14–16, 19]. Higher levels of intrauterine cortisol concentrations seem to alter the programming of the HPA axis for later life promoting metabolic, cardiovascular and behavioral disorders. The long-term impact on brain structure and development, particularly in the hippocampus, has been demonstrated. Thus it would not be astonishing when further studies would show that prenatal dexamethasone treatment accounts for a risk factor for cerebrovascular lesions.

In summary, we report 2 patients with classic salt-wasting CAH who were treated with glucocorticoids in utero and suffered from an acute encephalopathic crisis in their preschool age and showed focal or multifocal cortical-subcortical lesions on MRI of the brain. To our knowledge this is the first report of this association. Further reports and multicenter follow-up studies of prenatal dexamethasone treatment are needed to answer the question whether CAH, hypoglycemia and/or prenatal glucocorticoid therapy might belong to the list of risk factors for cerebrovascular disease in children and adults.

References

- Speiser PW, White PC: Congenital adrenal hyperplasia. *N Engl J Med* 2003;349:776–788.
- Speiser PW, Azziz R, Baskin LS, Ghizzoni L, Hensle TW, Merke DP, Meyer-Bahlburg HF, Miller WL, Montori VM, Oberfield SE, Ritzen M, White PC: Congenital adrenal hyperplasia due to steroid 21-hydroxylase deficiency: an Endocrine Society clinical practice guideline. *J Clin Endocrinol Metab* 2010;95:4133–4160.
- Flück CE, Achermann JC, Miller WL: The adrenal cortex and its disorders; in Sperling MA (ed): *Pediatric Endocrinology*, ed 3. Philadelphia, Saunders, 2008, pp 444–511.
- David M, Forest MG: Prenatal treatment of congenital adrenal hyperplasia resulting from 21-hydroxylase deficiency. *J Pediatr* 1984;105:799–803.
- Chrousos GP, Evans MI, Loriaux DL, McCluskey J, Fletcher JC, Schulman JD: Prenatal therapy in congenital adrenal hyperplasia. Attempted prevention of abnormal external genital masculinization by pharmacologic suppression of the fetal adrenal gland in utero. *Ann NY Acad Sci* 1985;458:156–164.
- Forest MG, Betuel H, David M: Prenatal treatment in congenital adrenal hyperplasia due to 21-hydroxylase deficiency: update 88 of the French multicentric study. *Endocr Res* 1989;15:277–301.
- Carlson AD, Obeid JS, Kanellopoulou N, Wilson RC, New MI: Congenital adrenal hyperplasia: update on prenatal diagnosis and treatment. *J Steroid Biochem Mol Biol* 1999;69:19–29.
- New MI, Carlson A, Obeid J, Marshall I, Cabrera MS, Gosoco A, Lin-Su K, Putnam AS, Wei JQ, Wilson RC: Prenatal diagnosis for congenital adrenal hyperplasia in 532 pregnancies. *J Clin Endocrinol Metab* 2001;86:5651–5657.
- Ritzen EM: Prenatal dexamethasone treatment of fetuses at risk for congenital adrenal hyperplasia: benefits and concerns. *Semin Neonatol* 2001;6:357–362.
- Lajic S, Wedell A, Bui TH, Ritzen EM, Holst M: Long-term somatic follow-up of prenatally treated children with congenital adrenal hyperplasia. *J Clin Endocrinol Metab* 1998;83:3872–3880.
- Miller WL: Prenatal treatment of congenital adrenal hyperplasia: a promising experimental therapy of unproven safety. *Trends Endocrinol Metab* 1998;9:290–293.
- Seckl JR, Miller WL: How safe is long-term prenatal glucocorticoid treatment? *JAMA* 1997;277:1077–1079.
- Brook CG: Antenatal treatment of a mother bearing a fetus with congenital adrenal hyperplasia. *Arch Dis Child Fetal Neonatal Ed* 2000;82:F176–F181.
- Seckl J: Prenatal glucocorticoids and long-term programming. *Eur J Endocrinol* 2004;151:U49–U62.
- Reynolds RM, Seckl JR: Antenatal glucocorticoid treatment: are we doing harm to term babies? *J Clin Endocrinol Metab* 2012;97:3457–3459.
- Miller WL, Feldman Witchel S: Prenatal treatment of congenital adrenal hyperplasia: risks outweigh benefits. *Am J Obstet Gynecol* 2013;208:354–359.
- Heine VM, Rowitch DH: Hedgehog signaling has a protective effect in glucocorticoid-induced mouse neonatal brain injury through an 11β-HSD2-dependent mechanism. *J Clin Invest* 2009;119:267–277.
- Lajic S, Nordenstrom A, Hirvikoski T: Long-term outcome of prenatal treatment of congenital adrenal hyperplasia. *Endocr Dev* 2008;13:82–98.

- 19 Kapoor A, Dunn E, Kostaki A, Andrews MH, Matthews SG: Fetal programming of hypothalamic-pituitary-adrenal function: prenatal stress and glucocorticoids. *J Physiol* 2006;572:31–44.
- 20 Krone N, Braun A, Roscher AA, Knorr D, Schwarz HP: Predicting phenotype in steroid 21-hydroxylase deficiency? Comprehensive genotyping in 155 unrelated, well-defined patients from southern Germany. *J Clin Endocrinol Metab* 2000;85:1059–1065.
- 21 Bergamaschi R, Livieri C, Uggetti C, Candeloro E, Egitto MG, Pichiecchio A, Cosi V, Bastianello S: Brain white matter impairment in congenital adrenal hyperplasia. *Arch Neurol* 2006;63:413–416.
- 22 Lee S, Sanefuji M, Watanabe K, Uematsu A, Torisu H, Baba H, Kira R, Takada Y, Ishizaki Y, Toyoshima M, Aragaki F, Hata D, Hara T: Clinical and MRI characteristics of acute encephalopathy in congenital adrenal hyperplasia. *J Neurol Sci* 2011;306:91–93.
- 23 Barnes C, Newall F, Furmedge J, Mackay M, Monagle P: Arterial ischaemic stroke in children. *J Paediatr Child Health* 2004;40:384–387.
- 24 Steinlin M: A clinical approach to arterial ischemic childhood stroke: increasing knowledge over the last decade. *Neuropediatrics* 2012;43:1–9.
- 25 Steinlin M, Pfister I, Pavlovic J, Everts R, Boltshauser E, Capone MA, Gubser MD, Hanggeli CA, Keller E, Luetsch J, Maroz J, Ramelli GP, Roulet PE, Schmitt-Mechelke T, Weissert M: The first three years of the Swiss Neuroepidemiologic Stroke Registry (SNPSR): a population-based study of incidence, symptoms and risk factors. *Neuropediatrics* 2005;36:90–97.
- 26 Mallick AA, O'Callaghan FJ: Risk factors and treatment outcomes of childhood stroke. *Expert Rev Neurother* 2010;10:1331–1346.
- 27 Verma S, Lewis D, Warne G, Grossmann M: An X-traordinary stroke. *Lancet* 2011;377:1288.
- 28 Ma JH, Kim YJ, Yoo WJ, Ihn YK, Kim JY, Song HH, Kim BS: MR imaging of hypoglycemic encephalopathy: lesion distribution and prognosis prediction by diffusion-weighted imaging. *Neuroradiology* 2009;51:641–649.
- 29 Kang EG, Jeon SJ, Choi SS, Song CJ, Yu IK: Diffusion MR imaging of hypoglycemic encephalopathy. *AJNR Am J Neuroradiol* 2010;31:559–564.
- 30 Falhammar H, Filipsson H, Holmdahl G, Jansson PO, Nordenskjold A, Hagenfeldt K, Thoren M: Metabolic profile and body composition in adult women with congenital adrenal hyperplasia due to 21-hydroxylase deficiency. *J Clin Endocrinol Metab* 2007;92:110–116.
- 31 Arlt W, Willis DS, Wild SH, Krone N, Doherty EJ, Hahner S, Han TS, Carroll PV, Conway GS, Rees DA, Stimson RH, Walker BR, Connell JM, Ross RJ: Health status of adults with congenital adrenal hyperplasia: a cohort study of 203 patients. *J Clin Endocrinol Metab* 2010;95:5110–5121.
- 32 Sartorato P, Zulian E, Benedini S, Mariniello B, Schiavi F, Bilora F, Pozzan G, Greggio N, Pagnan A, Mantero F, Scaroni C: Cardiovascular risk factors and ultrasound evaluation of intima-media thickness at common carotids, carotid bulbs, and femoral and abdominal aorta arteries in patients with classic congenital adrenal hyperplasia due to 21-hydroxylase deficiency. *J Clin Endocrinol Metab* 2007;92:1015–1018.
- 33 Ali YS, Rembold KE, Weaver B, Wills MB, Tatar S, Ayers CR, Rembold CM: Prediction of major adverse cardiovascular events by age-normalized carotid intimal medial thickness. *Atherosclerosis* 2006;187:186–190.
- 34 Liggins GC: The role of the hypothalamic-pituitary-adrenal axis in preparing the fetus for birth. *Am J Obstet Gynecol* 2000;182:475–477.
- 35 McMahon SK, Pretorius CJ, Ungerer JJP, Salmon NJ, Conwell LS, Pearen MA, Batch JA: Neonatal complete generalized glucocorticoid resistance and growth hormone deficiency caused by a novel homozygous mutation in helix 12 of the ligand binding domain of the glucocorticoid receptor gene (NR3C1). *J Clin Endocrinol Metab* 2010;95:297–302.
- 36 Goto M, Piper HK, Marcos J, Wood PJ, Wright S, Postle AD, Cameron IT, Mason JI, Wilson DI, Hanley NA: In humans, early cortisol biosynthesis provides a mechanism to safeguard female sexual development. *J Clin Invest* 2006;116:953–960.
- 37 Dardis A, Miller WL: Dexamethasone does not exert direct intracellular feedback on steroidogenesis in human adrenal NCI-H295A cells. *J Endocrinol* 2003;179:131–142.
- 38 Molnar J, Nijland MJ, Howe DC, Nathanielsz PW: Evidence for microvascular dysfunction after prenatal dexamethasone at 0.7, 0.75, and 0.8 gestation in sheep. *Am J Physiol Regul Integr Comp Physiol* 2002;283:R561–R567.
- 39 Dodic M, Peers A, Coghlan JP, May CN, Lumbers E, Yu Z, Wintour EM: Altered cardiovascular haemodynamics and baroreceptor-heart rate reflex in adult sheep after prenatal exposure to dexamethasone. *Clin Sci (Lond)* 1999;97:103–109.
- 40 Schwab M, Roedel M, Anwar MA, Muller T, Schubert H, Buchwalder LF, Walter B, Nathanielsz W: Effects of betamethasone administration to the fetal sheep in late gestation on fetal cerebral blood flow. *J Physiol* 2000;528:619–632.