

Successful Intra-arterial Thrombolysis in a Patient with an Intracranial Meningioma

Robson F. Baiense, MD,*† Agessandro Abrahão, MD,† Irapuá F. Ricarte, MD,†
Thiago G. Fukuda, MD,† Ricardo A. Oliveira, MD,† Gisele S. Silva, MD, PhD,†
Maristela Costa, MD,* and Manoel J. Teixeira, MD, PhD*

Alteplase (recombinant tissue plasminogen activator [rt-PA]) label approval by the Food and Drug Administration remarks the contraindication of its use with known intracranial neoplasm because of potential bleeding complications. Despite this concern, the real risk of intracerebral bleeding in patients with intracranial neoplasms treated with rt-PA is unknown, and there are few reports of thrombolysis in patients with brain tumors. We report a case of a 78-year-old man who was seen in our emergency department within 2 hours from sudden onset of aphasia, right-sided hemiplegia, hypoesthesia, and homonymous hemianopsia. The National Institutes of Health Stroke Scale (NIHSS) score at admission was 20. Intra-arterial thrombolysis was performed with administration of .3 mg/kg of alteplase combined with mechanical thrombectomy. At discharge, his NIHSS score was 1, and after 90 days, his modified Rankin score was 1. To our knowledge, this is the first report of intra-arterial thrombolysis in a patient with acute ischemic stroke with an intracranial tumor. **Key Words:** Intra-arterial thrombolysis—meningioma—intracranial neoplasm—acute ischemic stroke—mechanical thrombectomy—intracranial hemorrhage.

© 2013 by National Stroke Association

Introduction

Thrombolytic therapy with recombinant tissue plasminogen activator (rt-PA) is a well-established therapeutic option for acute ischemic stroke.¹ Alteplase (rt-PA) label approval by the Food and Drug Administration remarks

the contraindication of its use with known intracranial neoplasm because of potential bleeding complications.²

Despite this concern, the real risk of intracerebral bleeding in patients with intracranial neoplasms treated with rt-PA is unknown, and there are few reports of thrombolysis in patients with brain tumors. We describe a successful intra-arterial thrombolysis in a patient with acute ischemic stroke and an intracranial meningioma.

Case

A 78-year-old man was seen in our emergency department within 2 hours from sudden onset of aphasia, right-sided hemiplegia, hypoesthesia, and homonymous hemianopsia. The National Institutes of Health Stroke Scale (NIHSS) score at admission was 20. His medical history was remarkable for hypertension, heart failure, a cardiac pacemaker, and an intracranial meningioma.

From the *Hospital do Coração, São Paulo; and †Department of Neurology and Neurosurgery, Universidade Federal de São Paulo, São Paulo, Brazil.

Received April 24, 2013; accepted May 8, 2013.

Address correspondence to Irapuá F. Ricarte, MD, Departamento de Neurologia e Neurocirurgia, Universidade Federal de São Paulo, Rua Pedro de Toledo, 650, CEP 04039-000, São Paulo, Brazil. E-mail: irapuaferreir@hotmail.com.

1052-3057/\$ - see front matter

© 2013 by National Stroke Association

<http://dx.doi.org/10.1016/j.jstrokecerebrovasdis.2013.05.009>

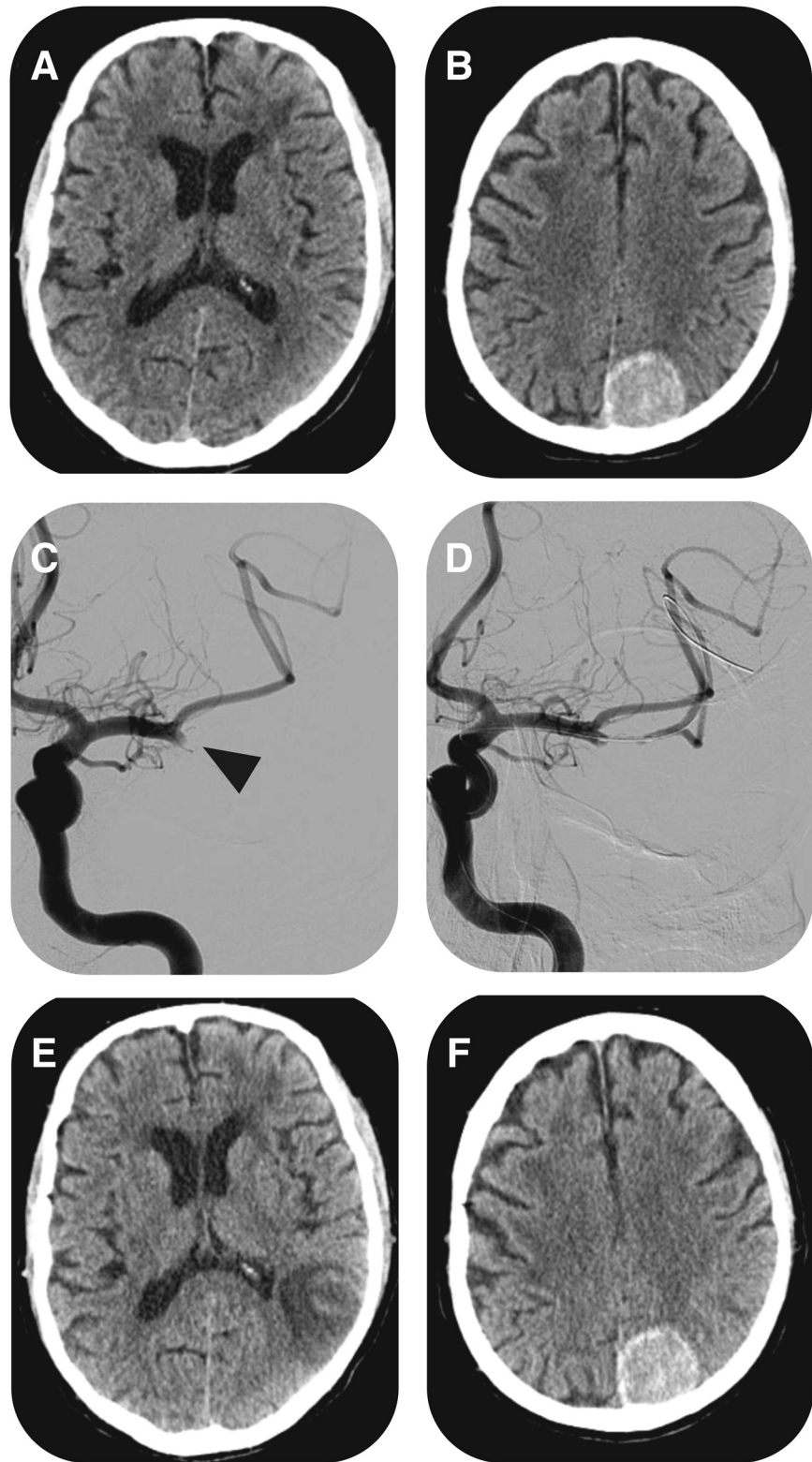


Figure 1. The first computed tomography (CT) scan (1 hour 40 minutes after onset) showed a calcified left occipitoparietal meningioma and no acute abnormalities (A and B). The cerebral angiogram showed occlusion of the inferior division of the left middle cerebral artery (C). Intra-arterial administration of .3 mg/kg of recombinant tissue plasminogen activator combined with mechanical thrombolysis resulted in partial recanalization (D). The CT scan 24 hours after the procedure showed a parietal ischemic area and no bleeding complications (E and F).

A brain computed tomography (CT) scan showed a left parieto-occipital meningioma and no acute ischemic abnormalities (Fig 1, A,B). Intravenous thrombolysis was withheld because of the intracranial neoplasm. Cerebral angiography showed a left, middle cerebral artery M2

branch occlusion (Fig 1, C). Intra-arterial thrombolysis was performed with administration of .3 mg/kg of alteplase (total of 18 mg) combined with mechanical thrombectomy (Catch device). Partial recanalization (TIMI 2) was obtained (Fig 1, D). A head CT scan 24 hours after

the procedure showed a small ischemic area and no hemorrhagic complications (Fig 1, E,F). At discharge, his National Institutes of Health Stroke Scale score was 1, and after 90 days, his modified Rankin score was 1.

Discussion

Cerebral hemorrhage is the most feared complication of intra-arterial or intravenous thrombolysis after ischemic stroke. Although intracranial hemorrhage is an acknowledged risk, the incidence of intracranial hemorrhage from intracranial tumors after thrombolytic therapy is not well characterized because patients with intracranial tumors were specifically excluded from thrombolysis trials and continue not to be treated in general practice.¹ The decision to use off-label thrombolysis for ischemic stroke should be individualized according to existing protocols, individual patient situation, and family consent.³ The reporting of such patients is necessary because uncommon clinical situations cannot be studied in randomized clinical trials as a result of their low prevalence. Our report demonstrates a successful intra-arterial thrombolysis in a patient with an intracranial meningioma. To our knowledge, this is the first report of intra-arterial thrombolysis in a patient with acute ischemic stroke with an intracranial tumor.

Only 5 cases of intravenous thrombolysis in patients with acute ischemic stroke and intracranial neoplasms were previously reported,⁴ being 2 of them, meningiomas.^{4,7} Another 5 patients treated with thrombolysis for nonstroke indications were formerly described: 3 of them received intravenous thrombolysis for acute myocardial infarction (2 with a meningioma and 1 with a pituitary adenoma),^{8,9} 1 patient with a glioblastoma received alteplase for a massive pulmonary embolism,¹⁰ and a fifth patient had a meningioma and was treated with local thrombolysis for deep venous thrombosis.¹¹ None of the patients with meningiomas treated with Intravenous Thrombolysis (IVT) had intracranial hemorrhagic complications.

In a previous report, a patient with a glioblastoma multiforme not seen on the initial head CT and treated with intravenous thrombolysis had a major intracranial hemorrhage and clinical deterioration.⁶ Although the presence of any intracranial tumor is currently considered

an exclusion criterion for thrombolysis, the different risks for bleeding between intra-axial and extra-axial tumors and between different histological subtypes of neoplasm should be considered.

Previous case reports suggest a low risk of bleeding in patients with meningiomas treated with IVT. Despite a theoretical increased risk of hemorrhagic transformation because of the presence of an intracranial neoplasm, the benefit of thrombolysis may outweigh the bleeding risk in some patients.⁷ After a careful evaluation and discussion of the potential risks and benefits, intra-arterial thrombolysis might be a feasible option in patients with intracranial meningiomas and acute ischemic stroke.

References

1. The National Institute of Neurological Disorders and Stroke rt-PA Stroke Study Group. Tissue plasminogen activator for acute ischemic stroke. *N Engl J Med* 1995; 333:1581-1587.
2. Activase (Alteplase7056206) Package Insert Manufactured by LB0974. GENENTECH, INC, South San Francisco, CA. (4800512).
3. Aleu A, Mellado P, Lichy C, et al. Hemorrhagic complications after off-label thrombolysis for ischemic stroke. *Stroke* 2007;38:417-422.
4. Neil W, Ovbiagele B. Intravenous thrombolysis in ischemic stroke patients with intracranial neoplasms: two cases and a literature review. *Case Rep Med* 2011;2011. <http://dx.doi.org/10.1155/2011/503758> (in press).
5. Garcia AM, Egado JA, Garcia ME, et al. Thrombolysis for ischaemic stroke and glioblastoma multiforme: a case report. *BMJ Case Rep* 2009;2009. <http://dx.doi.org/10.1136/bcr.06.2008.0268> (in press).
6. Grimm SA, DeAngelis LM. Intratumoral hemorrhage after thrombolysis in a patient with glioblastoma multiforme. *Neurology* 2007;69:936.
7. Hsieh HC, Chen CH. Tissue plasminogen activator use in a patient with acute ischemic stroke coexisting with meningioma. *Clin Neurol Neurosurgery* 2009;111:562-563.
8. Jaffe R, Reichman JM, Weiss AT, et al. Thrombolysis presence of an intracranial meningioma. *Chest* 1997;111:258.
9. Rubinshtein R, Jaffe R, Flugelman MY, et al. Thrombolysis in patients with a brain tumour. *Heart* 2004;90:1476.
10. Han S, Chaya C, Hoo GWS. Thrombolytic therapy for massive pulmonary embolism in a patient with a known intracranial tumor. *J Intensive Care* 2006;21:240-245.
11. Sakai K, Ochiai H, Katayama N, et al. Catheter interventional therapy in an elderly patient with deep vein thrombosis and a brain tumor. *Jpn Heart J* 2004;45:709-713.