

Brief Communications

Central Nervous System Venulitis Presenting as Migraine

Serena L. Orr, MD; Marlise P. dos Santos, MD, MSc; Roman Jurencak, MD; Jean Michaud, MD, FRCPC;
Elka Miller, MD; Asif Doja, MD, FRCPC

Objective.—To describe a case of pediatric central nervous system (CNS) venulitis.

Background.—Primary angiitis of the CNS is a rare but increasingly well-recognized cause of morbidity in children. It primarily involves the arteries and arterioles of the CNS, with only 1 published case of a pediatric patient found to have isolated CNS venulitis on brain biopsy.

Case Report.—A 17-year-old female with a 4-year history of migraines presented with increasingly frequent migraines and right-sided hemiplegia. Infectious, hematologic, and rheumatologic work-ups were negative. Brain magnetic resonance imaging showed multiple rim-enhancing lesions consistent with calcifications affecting the deep left white matter. On brain biopsy, there was evidence of an inflammatory process involving small veins and venules. The patient displayed clinical improvement with a course of high-dose steroids and 6 monthly cyclophosphamide infusions followed by maintenance therapy with mycophenolate mofetil.

Discussion.—We describe a case of pediatric CNS venulitis presenting with migraine.

Key words: pediatric, migraine, central nervous system vasculitis, central nervous system venulitis, headache, primary angiitis of the central nervous system

Abbreviations: CNS central nervous system, MRI magnetic resonance imaging, PACNS primary angiitis of the central nervous system

(*Headache* 2014;54:541-544)

BACKGROUND

Primary angiitis of the central nervous system (PACNS) is a rare but increasingly well-recognized cause of neurological injury in children. Pediatric PACNS is commonly characterized by a lymphocytic, non-granulomatous inflammation of central nervous system (CNS) vessels.¹ The primary targets of inflammation in PACNS are the arteries and arterioles of

the CNS, and only rarely have the veins and venules been found to display inflammatory changes.² We describe a case of a teenaged female presenting with migraine who was found to have inflammation predominantly involving CNS venules on brain biopsy.

CASE REPORT

A 13-year-old female presented with migraines with aura. Her episodes lasted between 3 and 24 hours in duration. Typically, 5-25 minutes prior to her migraine, she would experience a visual aura consisting of flashes of color in her right eye and blurred vision. She would then feel an intense throbbing pain

From the Children's Hospital of Eastern Ontario, ON, Canada (S.L. Orr, R. Jurencak, J. Michaud, E. Miller, A. Doja); University of Ottawa, ON, Canada (S.L. Orr, M.P. dos Santos, R. Jurencak, J. Michaud, E. Miller, A. Doja); The Ottawa General Hospital, ON, Canada (M.P. dos Santos).

Address all correspondence to Serena Orr, MD, Children's Hospital of Eastern Ontario, Ottawa, Canada ON K1H 8L1.

Accepted for publication June 4, 2013.

Conflict of Interest: The authors report no conflict of interest.

Funding: This case report has no sponsors, industry or otherwise.

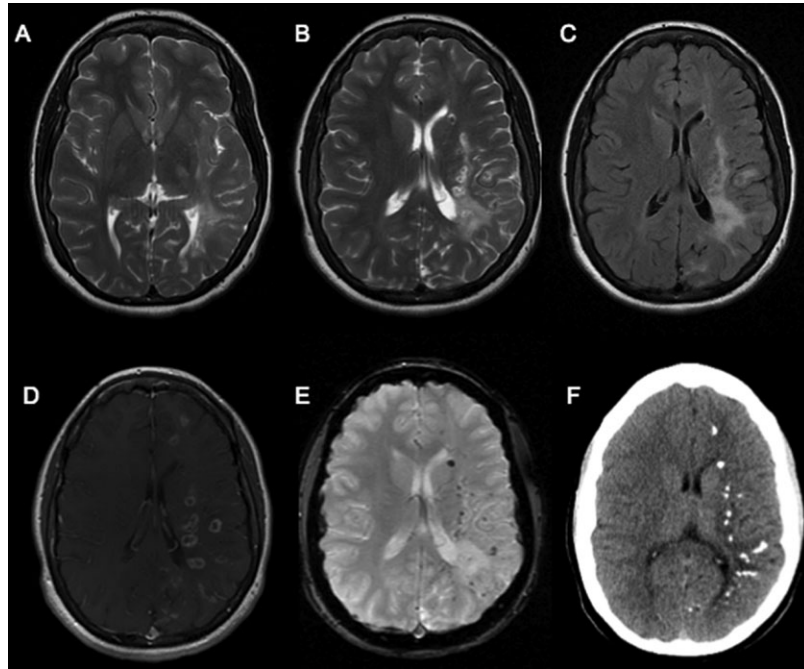


Fig 1.—Findings on magnetic resonance imaging (MRI) and computed tomography (CT) of the brain at second presentation. MRI brain showing increased T2 (A, B) and fluid attenuated inversion recovery sequence (FLAIR) signal intensity lesions (C) in the deep white matter of the left hemisphere and in the subcortical white matter of the left temporal region. Enhancing calcifications are seen in the deep white matter of the left hemisphere on post-gadolinium T1 (D) and high-resolution T2 gradient echo (E), as well as on CT scan (F).

in her cranium, which was worst on the left side, and accompanied by photophobia, phonophobia, as well as nausea and vomiting. Her symptomatology progressed to the point where her level of consciousness varied between unresponsive staring and a normal level of interaction with her environment. Investigations included a brain magnetic resonance imaging (MRI) that demonstrated increased signal intensity in the deep white matter of the left cerebral hemisphere posteriorly. A conventional angiogram was normal. She was diagnosed with migraines and was tried on several prophylactic medications. Her headaches remained stable, occurring at a frequency of approximately 6 episodes per year. She was subsequently lost to follow-up for 4 years. In the interim, her headaches became more frequent and severe, and were now accompanied by right-sided hemiplegia, which persisted for several hours after the headache. At the age of 17, she was admitted to hospital for an episode that was followed by persistent right-sided hemiplegia.

On exam, there was decreased power on the right, with hyperactive deep tendon reflexes and an

extensor plantar response on the right. She had decreased sensation to pinprick in her right upper and right lower extremities. She demonstrated difficulty with both rapid alternating movements and finger-to-nose testing on the right. Gait was intact.

Screening bloodwork, including erythrocyte sedimentation rate (ESR), C-reactive protein (CRP), thyroid, and parathyroid function, was normal. Extensive rheumatologic, hematologic, and infectious work-ups were negative. Cerebrospinal fluid (CSF) studies showed normal glucose and protein, with 17×10^6 white blood cells/L, 734×10^6 red blood cells/L, and an elevated proportion of neutrophils and lymphocytes. Oligoclonal bands were negative.

Computed tomography head showed calcifications in the periventricular and subcortical white matter of the left hemisphere. MRI brain showed multiple rim-enhancing lesions with central areas of blooming artifact in the gradient echo sequence in keeping with calcifications affecting the deep left white matter (see Fig. 1). Magnetic resonance (MR) angiography and venography were within normal

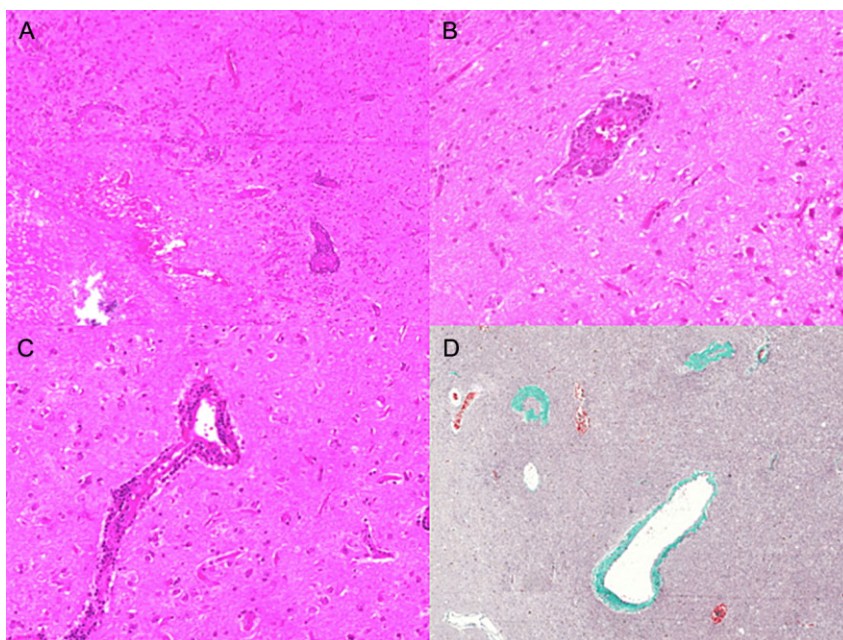


Fig 2.—Findings on biopsy of the brain at second presentation. Brain biopsy from the left occipital lobe showing: subcortical white matter necrosis (left lower corner) and several small veins and venules with inflammation in and around their walls. (A) The inflammatory infiltrate was mostly composed of histiocytes (B) or lymphocytes. (C) Sclerotic, frequently dilated, non-inflamed vessels were seen throughout the sample (D) (A: Hematoxylin phloxine saffron [HPS] 17 \times ; B: HPS 70 \times ; C: HPS 70 \times ; D: Masson trichrome 40 \times).

limits. A conventional angiogram showed normal arteries, with no arteriovenous shunting, but the venous structures of the brain were significantly stenosed. A brain biopsy of the left occipital lobe was consistent with an inflammatory process involving small veins and venules, with focal subcortical white matter necrosis along with several non-inflamed sclerotic vessels (see Fig. 2).

Treatment included a course of high-dose steroids and monthly cyclophosphamide infusions for 6 months, followed by maintenance therapy with oral mycophenolate mofetil. She has shown both radiological and clinical improvement, with a significant reduction in the frequency of her headaches.

DISCUSSION

PACNS is an increasingly well-recognized cause of morbidity in children that can be divided into 2 broad categories: angiography-positive PACNS, which affects large- and medium-sized vessels, and angiography-negative PACNS, which affects small caliber vessels. Angiography-positive PACNS most often presents with stroke-like symptoms, whereas

angiography-negative PACNS can present with headaches, focal neurological deficits, neurocognitive changes, behavior disruption, seizures, as well as systemic symptoms. Angiography-positive PACNS can be further subdivided into progressive and non-progressive forms. Progressive angiography-positive PACNS is a chronic inflammatory disease characterized by the appearance of new areas of stenosis on angiography after 3 months in untreated patients. On the other hand, non-progressive angiography-positive PACNS is a monophasic illness often involving unilateral inflammation of the proximal middle and/or anterior cerebral arteries, and distal internal carotid arteries, with stable angiography findings after 3 months in untreated patients.³

Pediatric PACNS most commonly involves a lymphocytic, non-granulomatous inflammation of CNS vessels.¹ PACNS is thought to primarily affect the arteries and arterioles of the CNS and has only rarely been found to also involve the veins and venules.² Beyond the case presented earlier, there is only 1 other case in the literature describing a pediatric patient, presenting with symptoms of PACNS, where

biopsy results showed inflammation restricted to CNS venules.⁴

The treatment approach differs for each PACNS subtype. Progressive angiography-positive PACNS is treated in phases, beginning with 6 months of induction therapy with monthly intravenous cyclophosphamide, followed by 18 months of maintenance therapy with either mycophenolate mofetil or azathioprine. For children with non-progressive, angiography-positive PACNS, treatment with heparin, followed by an antiplatelet agent, is indicated. These children are sometimes also treated with an adjuvant steroid, but this remains controversial. Finally, children with angiography-negative PACNS are treated with 6 months of induction therapy with monthly intravenous cyclophosphamide, followed by 18 months of maintenance therapy with mycophenolate mofetil. In addition, these children receive adjuvant steroids in the form of high-dose prednisone, which is then tapered over a period exceeding 12 months.⁵ Our patient was treated successfully with high-dose steroids and monthly cyclophosphamide infusions for 6 months, followed by maintenance therapy with oral mycophenolate mofetil, and did well on this regimen.

It is unclear whether CNS venulitis represents a novel form of CNS inflammation, where the target of the inflammatory response is the venule or whether it is a previously undescribed variant of PACNS. Our patient did have a clinical picture similar to cases of angiography-negative PACNS. Further study of cases of CNS venulitis will be necessary before drawing conclusions as to whether this represents a distinct disease entity or whether it can be considered a subtype of PACNS.

STATEMENT OF AUTHORSHIP

Category 1

(a) Conception and Design

Not applicable – case report

(b) Acquisition of Data

Serena Orr, Asif Doja, Roman Jurencak, Elka Miller, Marlise dos Santos, Roman Jurencak

(c) Analysis and Interpretation of Data

Serena Orr, Asif Doja, Roman Jurencak, Elka Miller, Marlise dos Santos, Roman Jurencak

Category 2

(a) Drafting the Manuscript

Serena Orr

(b) Revising It for Intellectual Content

Serena Orr, Asif Doja, Roman Jurencak, Elka Miller, Marlise dos Santos, Roman Jurencak

Category 3

(a) Final Approval of the Completed Manuscript

Serena Orr, Asif Doja, Roman Jurencak, Elka Miller, Marlise dos Santos, Roman Jurencak

REFERENCES

1. Hajj-Ali RA, Singhal AB, Benseler S, et al. Primary angiitis of the CNS. *Lancet Neurol.* 2010;10:561-572.
2. Lie JT. Classification and histopathologic spectrum of central nervous system vasculitis. *Neurol Clin.* 1997;15:805-819.
3. Cellucci C, Benseler SM. Central nervous system vasculitis in children. *Curr Opin Rheumatol.* 2010;22:590-597.
4. Elbers J, Halliday W, Hawkins C, et al. Brain biopsy in children with primary small-vessel central nervous system vasculitis. *Ann Neurol.* 2010;68:602-610.
5. Cellucci T, Benseler SM. Diagnosing central nervous system vasculitis in children. *Pediatr Rev.* 2010;22:731-738.