

CASE REPORT

Multimodal physical therapy management of a 48-year-old female with post-stroke complex regional pain syndrome

Sudarshan Anandkumar, MSc PT, BPT, C-OMPT, MIAP, MMTF¹, and Murugavel Manivasagam, BPT, DYT, CSMT, MIAP²

¹Coventry University, International School of Physiotherapy, Gokula Education Foundation, Bangalore, India and ²Rehabilitation Department, Jerudong Park Medical Centre, Brunei Darussalam

Abstract

This case report describes a 48-year-old female who presented with complaints of right shoulder pain, hyperesthesias and swelling of the hand along with added symptoms of pain centralization following a cerebrovascular accident. On clinical evaluation, the patient satisfied the Budapest diagnostic criteria for Complex Regional Pain Syndrome (CRPS) type-1. Physical therapy management (1st three sessions) was initially focused on pain neurophysiology education with an aim to reduce kinesiophobia and reconceptualise her pain perception. The patient had an immediate significant improvement in her pain and functional status. Following this, pain modulation in the form of transcutaneous electrical nerve stimulation, kinesio tape application, "pain exposure" physical therapy and exercise therapy was carried out for a period of 7 weeks. The patient had complete resolution of her symptoms which was maintained at a six-month follow-up.

Keywords

Complex regional pain syndrome type 1, kinesio taping, pain exposure physical therapy, pain neurophysiology education, physical therapy, shoulder hand syndrome

History

Received 21 October 2012
Revised 21 March 2013
Accepted 15 April 2013
Published online 23 July 2013

Background

Stroke is defined as a focal or global disturbance of cerebral function resulting in neurological deficits due to interruption in blood supply to the brain which lasts for more than 24 hours or until death if within 24 hours (Lakshminarayan et al, 2009). Occurrence of hemiplegic shoulder pain is common after stroke. Factors predisposing a patient to shoulder pain include flaccidity, proprioceptive impairment, hemineglect and spasticity (Murie-Fernández et al, 2012). Various causes for shoulder pain following hemiplegia are adhesive capsulitis, injury to the rotator cuff muscles, impingement syndrome, glenohumeral subluxation or dislocation and Complex Regional Pain Syndrome (CRPS) (Kalichman and Ratmansky, 2011).

CRPS is a neuropathic pain disorder which encompasses a range of motor, autonomic and sensory features present in the extremities that are disproportionate to the inciting event (Goebel, 2011). CRPS is classified into type-1 and type-2. CRPS-1 occurs following an injury without any overt nerve damage (accounting for 90% of the cases) whereas CRPS-2 occurs after a distinct nerve injury (Marinus et al, 2011).

CRPS-1 seen in hemiplegia is also known as shoulder hand syndrome. The incidence of CRPS-1 is highly variable and reportedly ranges from 1.5% (McLean, 2004) to 48.8% (Kocabas, Levendoglu, Ozerbil, and Yuruten, 2007). This high statistical variability occurs due to a lack of consensus on the diagnostic criteria for CRPS with researcher's using varied criteria's (Daly and Bialocerkowski, 2009). Diagnostic criteria available for CRPS are: Veldman's criteria (Veldman, Reynen, Arntz, and Goris, 1993); International Association for the Study of Pain

(IASP) criteria (Merskey and Bogduk, 1994); Bruehl's criteria (Bruehl et al, 1999); and Budapest criteria (Harden et al, 2010) (Appendix 1). The Budapest criteria is the only validated criteria to date with a specificity of 0.79. Hence, when the signs and symptoms are positive, it "rules in" CRPS-1.

Glenohumeral subluxation and shoulder complex muscle paresis have been identified as risk factors for CRPS-1 (Braus, Krauss, and Strobel, 1994). The incidence of glenohumeral subluxation in hemiplegia varies from 17% to 66% (Culham, Noce, and Bagg, 1995). Although trauma to the hemiplegic shoulder is associated with the genesis of CRPS-1 (Geurts, Visschers, van Limbeek, and Ribbers, 2000), the exact pathophysiology as to how this leads to the observed clinical manifestations remain unknown. It is believed that trauma leads to a state of sympathetically maintained pain where the provoked activity of the sympathetic neurons also excites the primary afferents (Niehof et al, 2006). However, the observed autonomic features in CRPS-1 can be explained by other non-autonomic mechanisms. For example, increased endothelin-1 (which induces vasoconstriction) and decreased nitric oxide (which causes reduced vasodilatation) can lead to hypoxia and have been found in subjects with chronic CRPS (Groeneweg et al, 2006). The affected limbs of patients with CRPS will show histopathologic evidence of hypoxia or oxidative stress (Koban, Leis, Schultze-Mosgau, and Birklein, 2003). Hypoxia may contribute to atrophy and ulceration due to impaired metabolism of the high energy phosphates in the muscle and decreased capillary oxygenation (Chae, 2010). Hypoxia, caused by sympathetic dysregulation as well as by the above mechanisms, can also cause acidosis (i.e. due to increased lactate levels in the body) and formation of free radicals, provoking the primary afferents and initiating further inflammatory responses (Chae, 2010).

Another non-autonomic cause for the observed autonomic features with inflammatory signs in CRPS-1 could be attributed to the effects of neuropeptides (Kingery, 2010). Neuropeptides (such

Address correspondence to Sudarshan Anandkumar, Coventry University, International School of Physiotherapy, Gokula Education Foundation, M.S.R Nagar, MSRIT Post, Bangalore 54, Karnataka, India. E-mail: anandkumar.sudarshan@gmail.com

as calcitonin-gene related peptide, substance p and bradykinin) are elevated in patients with CRPS and mediate neurogenic inflammation (Schinkel et al, 2006). Elevated levels of tumour necrosis factor alpha, nerve growth factors and interleukin-6 are also exhibited in patients with CRPS (Heijmans-Antonissen et al, 2006). They sensitize the primary afferents and cause amplification along with upregulation of neurogenic inflammation.

Dysfunction of the somatic nervous system can also play a role in the pathogenesis of CRPS-1. Reduced axonal density (Oaklander et al, 2006) and loss of C and A-delta fibres (Albrecht et al, 2006) have been found in the peripheral somatic sensory system. Continuous pain or nociceptive input can cause reduced stimulation threshold and increased excitability of the spinal neurons leading to sensitization (Woolf and Salter, 2000; Woolf, 2011). This can manifest as allodynia, hyperalgesia and hyperesthesia. Physical therapy approaches like sensory desensitization techniques could be utilized to counter these clinical manifestations, and pain neurophysiology education about central sensitization of pain (Nijs et al, 2011) can be used to reconceptualise the patient's perception of their pain. Pain can also cause disuse of the affected limb, leading to impairments such as decreased range of motion, weakness or tightness of the surrounding soft tissue structures and reduced blood supply over a period of time (Chae, 2010). This forms the basis for intervening with pain modalities (i.e. Transcutaneous Electrical Nerve Stimulation (TENS), heat, cold and spinal cord stimulation for pain modulation); exercise therapy (i.e. range of motion exercises and stretching); and massage therapy to increase blood supply.

In addition to the peripheral and spinal structures, supraspinal involvement also occurs in CRPS. Supraspinal changes noted in CRPS include: altered thalamic perfusion (Fukumoto et al, 1999); altered ipsilateral central sensorimotor processing (Juottonen et al, 2002); reduced representation of the affected hand (Maihöfner, Handwerker, Neundörfer, and Birklein, 2003); overlapping of cortical finger representation (Pleger et al, 2004); and reduced thresholds for two point discrimination (Pleger et al, 2006). Pain intensity and mechanical hyperalgesia have a direct correlation with the extent of cortical reorganisation (Maihöfner, Handwerker, Neundörfer, and Birklein, 2003) and resolution of clinical symptoms have been found with its reversal (Pleger et al, 2005). This provides the rationale for utilizing graded motor imagery and mirror therapy to intervene at the cortical level, thus reconciling sensory feedback and motor output (Cacchio et al, 2009a; Moseley, 2006).

Other influences on CRPS-1 are from the domain of biopsychosocial factors. Stress, anxiety and depression are a predictor for pain intensity in CRPS (Feldman, Downey, and Schaffer-Neitz, 1999). Psychological distress can cause stress induced release of catecholamines and decreased activation of the opioid anti-nociceptive systems (Chae, 2010). Thus, emotional distress can occur as a consequence of pain and forms a vicious circle by possibly sustaining pain. In response, patient's may show maladaptive coping strategies like fear avoidance behaviour. Thus, "Pain Exposure" Physical Therapy (PEPT) with graded exposure to exercises (involving activity, touch and movement) (van de Meent et al, 2011), biofeedback, relaxation techniques and psychological support could be used to intervene at this level.

In short, determining the management of CRPS-1 in patients with hemiplegia is a challenge due to the diverse mechanisms which interact with one another giving rise to a complex pathophysiology and the various interventions utilized to address them. CRPS-1 has a great impact on patients with hemiplegia, where in addition to motor impairments symptoms like severe pain hamper the recovery processes. For example, even if abnormal synergy patterns following stroke resolve with good motor recovery, disuse of the hand may still persist because of

pain. In short, functioning of the upper extremity in CRPS-1 depends not only on the motor recovery shown by patient's but also on the severity with which CRPS-1 clinically manifests itself and how well it is intervened. This case report describes a successful multimodal physical therapy management of a patient with CRPS-1 consisting of pain neurophysiology education, pain modulation in the form of TENS, kinesio taping and exposure to graded exercises.

Case description

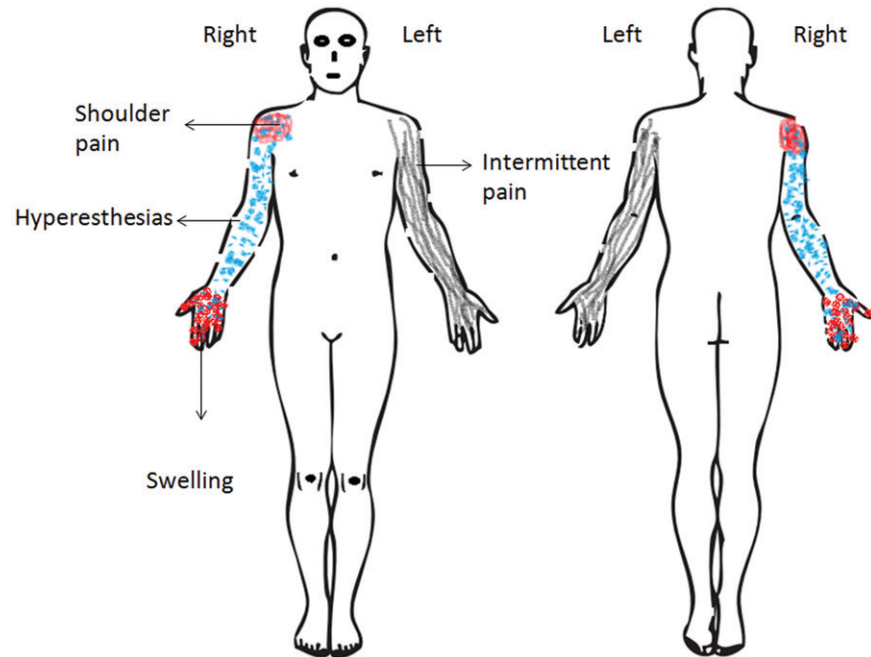
A 48-year-old female who was right hand dominant presented with complaints of difficulty in using her right upper extremity for activities of daily living such as combing hair, showering, eating and dressing for the previous 5 months. The patient had a cerebrovascular accident 6.5 months prior to presenting for this episode of physical therapy care which was revealed by MRI to be a bleed of the basal ganglia. The patient felt a sudden weakness of her right upper and lower extremity (upper > lower) and remained in the intensive care unit for two days. There was no history of a fall or loss of consciousness at the time of this event. She was transferred to an inpatient rehabilitation facility for physical therapy. At the end of the first week after stroke, the patient could ambulate independently at functional speeds and perform functional activities of her upper extremity such as toileting and self-grooming. No cognitive or perceptual deficits were noted. She was advised to have a follow-up in the out-patient physical therapy department and was discharged from the hospital.

The patient continued with her activities of daily living and did not seek the follow-up of physical therapy services. She reported that she had no difficulty in most of her gross motor activities. Even though fine motor functions like buttoning or positioning her hair band were accomplished, she found them to be challenging. Nevertheless, the patient reported that she was getting better day by day with regards to the physical performance of these activities with a near normal "feel" when compared prior to the stroke. However, she noted negligible pain and discomfort in her right shoulder at end ranges of functional activities (like buttoning her bra behind or scrubbing her back while bathing) starting 2 weeks post onset of stroke which she continued to ignore.

After 1.5 months, the patient developed considerable pain in her right shoulder with a gradual onset localised to the right acromion process and humeral head (anterior aspect). The pain started to spread all around the right shoulder and she noticed mild swelling in her right hand with hyperesthesias to touch or temperature variations throughout the right extremity (Figure 1). Swelling and hyperesthesias were intermittent, brought about whenever the pain was aggravated and disappeared when the pain completely relieved. The patient reported that the above-mentioned symptoms were aggravated with household activities like vacuuming or dusting, completely vanishing with rest. However, the discomfort faced in the right shoulder during activities such as scrubbing her back while bathing still persisted.

The symptoms experienced by the patient (i.e. pain, swelling and hyperesthesias) worsened day by day where at times she started to feel her right hand becoming more "colder" or "hotter" than her left hand. The pain became continuous 5 months after the onset of stroke with a "stinging" quality completely limiting her in functional activities. At the same time she also started experiencing tremor in her hands when she attempted doing any household work. Specific aggravating factors for her symptoms were a hot or a cold shower with no relieving factors. The patient felt "weak" about her whole right extremity and said that the swelling in her right hand reached a state of plateau 5.5 months after her stroke.

Figure 1. Symptom distribution marked in the body chart (shoulder pain in pink, swelling in red, hyperesthesias in blue and intermittent pain on the left side in grey).



The patient denied symptoms of sudden weight loss or bowel and bladder disturbances. However, the patient reported severe pain at night completely disturbing her sleep. Further, she complained of intense fatigue with difficulty in concentrating or directing attention to her daily chores. Also, she had been experiencing intermittent pain throughout her left extremity for the past 10 days with no relieving factor (Figure 1). The patient met her family doctor who put her on pain medication (celebrex 200 mg, twice a day; diclofenac sodium 50 mg, three times a day) for seven days. She found no change in her symptoms or in her functional status as a result of the medication. The patient noticed that for the previous three days, even exposure to bright light or listening to loud music was aggravating her symptoms in the right extremity as well as the pain she has been experiencing in her left extremity. At the time of initial physical therapy examination she said that she was stressed out, frustrated and anxious, and constantly ruminating about the progression of her symptoms.

Clinical findings

On observation, mild drooping of the right shoulder along with bilateral prominence of the inferior angle of scapula was noted. The right hand was swollen and appeared to have mild erythema when compared to the left side. Trophic changes (like dryness of skin or loss of hair) were absent throughout the extremity. However, sulcus sign was positive in the right shoulder with a mild flattening of the round contour of the deltoid muscle (Magee, 2006).

On palpating the space between the right acromion and humeral head, a minimal inferior subluxation of grade 1 (according to the three-point scale of thumb palpation for shoulder subluxation developed by Bohannon and Andrews (1990)) was felt by the examiner. Further, on palpating the location of the right humeral head with reference to the acromion, a little more than two-third was translated anteriorly, indicating an anterior instability (Sebastian, 2005). Grade 3 tenderness (Magee, 2006) was obtained on palpating the right humeral head where the patient winced and withdrew the joint. The swelling in the right hand was non-pitting with mild warmth being present.

On sensory examination, the patient complained of severe pain to a pin prick (hyperalgesia) as well as light touch and pressure (allodynia) throughout the right extremity. Both hot pack

(at 37°C) and a cold pack (at 15°C), when touched at random points on the right upper limb, immediately elicited sensations of severe pain throughout the extremity. Similar responses were obtained when vibration (at 256 Hz) was tested at the right and left malleoli in the lower extremity.

Active range of motion examination for the right upper limb was not done due to the severity of the pain and discomfort experienced by the patient. However, range of motion testing for the cervical spine, thoracic spine, lumbar spine and left upper extremity were full and free, provoking no symptoms.

The patient was asked to walk on the treadmill at a comfortable speed of 3 miles per hour for 30 minutes. However, after 10 minutes the patient felt her symptoms of pain being exacerbated throughout the right as well as the left extremity. The treadmill walking was stopped and the patient was allowed to rest. After 20 minutes, the exacerbated symptoms of pain in the left extremity disappeared with the right extremity showing baseline pain severity.

Evaluation and diagnosis

The symptoms being experienced by the patient (continuous pain, hyperesthesia, swelling, tremors) along with signs during the examination (hyperalgesia, allodynia, erythematous skin and right hand swelling) satisfied the Budapest research diagnostic criteria for CRPS -1 (Harden et al, 2010). This criterion has a specificity of 0.79, thus helping to ‘rule in’ the diagnosis of CRPS-1. Range of motion testing for the cervical and thoracic spine did not provoke the patient’s symptoms and helped in ruling them out as the source of dysfunction.

Shoulder subluxation is common after hemiplegia, and it is possible that during the acute phase of stroke in this patient, hypotonicity of the shoulder muscles could have lead to its decreased ability to maintain the humeral head within the glenoid cavity, resulting in subluxation (Murie-Fernández et al, 2012). However, other factors such as improper patient handling or improper sleeping position in bed (Murie-Fernández et al, 2012) have also been implicated to cause subluxation in hypotonic shoulders. The fact that the patient experienced pain and discomfort at the end ranges of shoulder functional activities immediately following stroke suggested that a minor subluxation could have occurred during the acute phase itself.

Shoulder subluxation was confirmed on palpation with a grade 1 inferior subluxation (where 0 = none, 1 = minimal, 2 = substantial) (Bohannon and Andrews, 1990) being identified. This palpatory clinical measure has an agreement rate of 91.7% between two examiners and a weighted kappa score of 0.90 for the ordinal grading (Bohannon and Andrews, 1990). Further, the humeral head was translated forward, indicating an anterior instability. Glenohumeral subluxation along with shoulder complex muscle paresis could have possibly led to the genesis of CRPS-1 in this patient where repeated micro-trauma could have cascaded into the symptom presentation being observed.

In addition to the symptoms of CRPS-1, the patient also gave a clinical picture of added central sensitization. For example, testing of a mechanical stimulus of vibration in a clinically remote site (both the malleoli) elicited severe pain throughout the right upper extremity. Also, exercise is one of the stressors that normally triggers the descending anti-nociceptive mechanisms and increases the pain threshold levels (Koltyn and Arbogast, 1998; Millan, 2002). The patient was made to walk on the treadmill with an aim to assess for these supraspinal anti-nociceptive mechanisms. However, exacerbations of pain in bilateral upper extremities suggested that the supraspinal anti-nociceptive mechanisms were deregulated and impaired, thus unable to respond to an exercise trigger. Further, history of fatigue, sleep disturbances, concentration difficulty, hypersensitivity to hot or cold shower along with symptom provocation as a result of exposure to bright light or noise was suggestive of a superadded central pain (Nijs, Van Houdenhove, and Oostendorp, 2010).

Outcome measures

Outcome measures utilized were: visual analogue scale (VAS) for pain intensity at rest and pain induced by stroking with a paint brush (tactile allodynia); pain-free lateral rotation of the shoulder; figure of eight measurement for size of the hand; disabilities of the arm, shoulder and hand (DASH) for measuring upper limb physical function; and Tampa scale for kinesiophobia (TSK) for measuring kinesiophobia. All the outcome measures were utilized at baseline and at the beginning of each treatment session.

The reliability and validity of the VAS to measure pain intensity has been established (Bijur, Silver, and Gallagher, 2001; Boonstra et al, 2008; Price, McGrath, Rafii, and Buckingham, 1983) where on a 10-cm line, "0" indicates no pain and "10" indicates worst imaginable pain. The minimal clinically important difference is considered to be a difference of more than 12 mm (95% Confidence Interval [CI] 9.15 mm) (Kelly, 2001). The patient rated her pain intensity at rest to be 9.6 cm. The anterior aspect of the shoulder was stroked three times using a paint brush (camlin series 66 synthetic hair brushes) to test for tactile allodynia and was considered present if the pain was provoked. The patient rated her pain on stroking with the paint brush to be 10 cm in the VAS.

Pain-free lateral rotation of the right shoulder was measured by a universal goniometer in supine lying where the shoulder was first abducted to 45 degrees and elbow flexed to 90 degrees with the wrist pronated (Bohannon and Andrews, 1990). The shoulder was laterally rotated by the therapist until the first onset of pain was felt by the patient. The axis of the goniometer was aligned with the olecranon. The immovable arm was kept perpendicular to the ground and the movable arm was aligned along the lateral styloid process. A lateral rotation pain free range of 15 degrees was obtained at baseline.

Figure of eight measurement for size of the hand is a valid and reliable method (Leard et al, 2004) where the tape measurement was done starting from the right ulnar styloid process and taken to

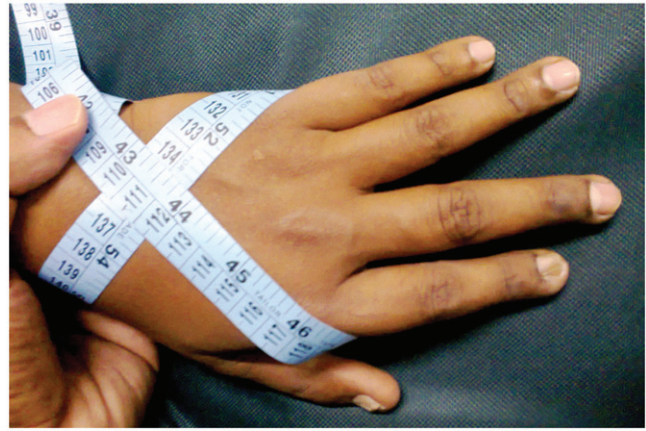

Figure 2. Figure of eight tape measurement for size of the hand.

the radial styloid process anteriorly across the wrist (Figure 2). The tape is taken dorsally to the 5th metacarpal phalangeal joint in a diagonal fashion then brought ventrally across the metacarpal phalangeal joints. The tape is then taken dorsally across the hand to the starting position of the tape measurement. An average of three measurements was taken where baseline values of 48.9 cm and 39.1 cm were obtained for the right hand and left hand respectively.

The DASH is a self-reported questionnaire containing 30 items measuring the physical function and symptoms related to daily activities involving the upper extremity (Beaton, Davis, Hudak, and McConnell, 2001). Scoring is done using an ordinal scale from "1" (without difficulty) to "5" (maximum difficulty) with a total score of 100 being obtained. It is a valid and reliable tool with higher scores indicating greater disability (Roy, MacDermid, and Woodhouse, 2009). The minimal clinically important difference for the DASH is 10.2 points (Roy, MacDermid, and Woodhouse, 2009). A baseline score of 96.6 points was obtained for the right upper extremity.

To measure influence of fear of movement or fear of (re)injury, the TSK was utilized (Mintken, Cleland, Whitman, and George, 2010). A 13-item questionnaire was used instead of the original 17 items, leaving out 4 questions relating to the inversed aspects of kinesiophobia. It is a valid and reliable tool (French et al, 2007) where scoring is done on an ordinal scale ranging from 1 (strongly disagree) to 4 (strongly agree). The total score varies from a minimum of 13 points (indicating no kinesiophobia) to a maximum of 52 points (indicating high kinesiophobia). A baseline value of 46 points was obtained.

Intervention

Based on the above presentation, intervention consisted of: pain neurophysiology explanation; TENS; Kinesio Tape (KT) (manufactured by Nitto Denko) application; PEPT; and exercise therapy. The patient was seen three times a week for a period of 8 weeks. The treatment sequence was as given below.

First two weeks

The first three treatment sessions comprised of pain neurophysiology explanation with the education content based on the book "Explain Pain" (Butler and Moseley, 2003). In the first session which lasted for 40 minutes, the patient was given a brief description about the neurophysiology and origin of pain from the nervous system. It was a one-on-one discussion between the therapist and the patient, carried out in a small seminar hall (inside the physical therapy department) which was sound proof with lighting comfortable for the patient. Visual aid

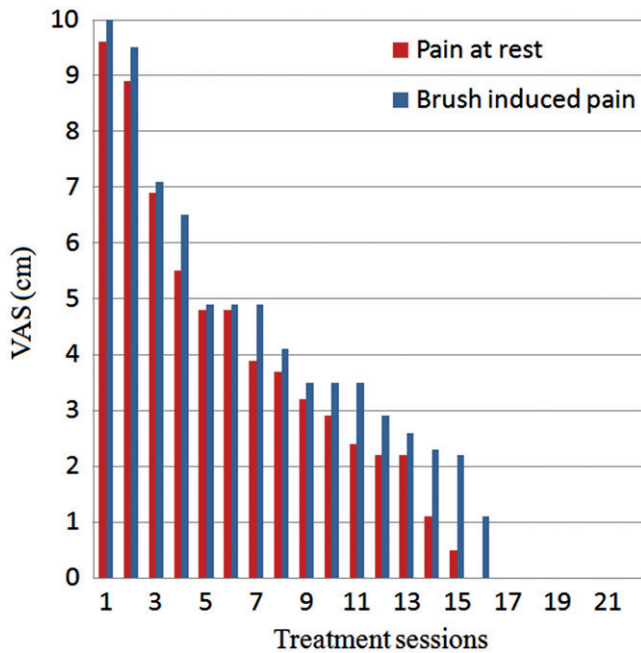


Figure 3. Graph showing progression of VAS scores for pain intensity at rest and pain induced by brush stroking.

(using Windows Microsoft PowerPoint presentation) containing pictures, flow charts and summaries were integrated along with the verbal explanation given by the therapist. A small hand out containing the educational content of the first session was given to the patient and she was asked to read it carefully at home before returning for the second session.

A second educational session was held after two days lasting for 40 minutes and included explanation about acute versus chronic pain, how pain becomes chronic (including central sensitization) and the various sustaining factors of pain (including fear avoidance or stress). A small hand out containing the educational content of the second session was given to the patient. She was also given the patient version of the neurophysiology of pain test (Meeus, Nijs, Elsemans, and De Meirleir, 2010) and was asked to complete the exam the same day prior to the third session.

A third session was held after two days and the patient rated her pain intensity on the VAS at rest and on stroking with a paint brush to be 6.9 cm and 7.1 cm, respectively (Figure 3). Pain-free lateral rotation of the right shoulder increased from 15 degrees to 25 degrees (Figure 4) with the size of the right hand remaining at 48.9 cm. With the DASH and TSK, the scores reduced to 80 points and 13 points, respectively (Figures 5 and 6). The outcome of the pain test revealed that the patient had a good understanding of the educational sessions. Topics related to stress, anxiety and fear avoidance in relation to pain were discussed again and the existing doubts which the patient had were clarified. The patient was willing to pursue strategies for adaptive coping of pain in her daily activities and her consent to undergo PEPT was obtained.

As a part of PEPT, the patient was initially asked to self massage (gentle kneading) her right upper limb for 20 minutes. Followed by this, she was asked to passively and actively mobilize her right upper limb joints (shoulder, elbow, wrist and hand) for 30 repetitions with a break of two to three minutes between each joint which lasted for about 20 minutes. The patient was asked to carry out the same as a home program and was reassured that though increase in pain may occur following PEPT, it is not a sign of further damage or injury. She was discouraged to ruminate about her increase in pain status and was encouraged by the therapist to increase the functional use of her right extremity.

At the fourth treatment session, PEPT was progressed to simple day to day bi-manual activities such as cutting vegetables and scrubbing her body with soap (so as to imitate bathing) and was advised to continue the same at home. This PEPT session lasted for 15 minutes following which she was given TENS to the right shoulder for 30 minutes using a 4 channel output Digitens-104 equipment (manufactured by HMS medical systems). A sensory level stimulation was used with a high frequency of 100 Hz, pulse width of 150 μ s and an intensity so as to elicit a tingling sensation. The patient was comfortable and reported that she liked the tingling sensation.

Following this, KT was applied to the right shoulder and hand based on its principles of application (Kase, Wallis, and Kase, 2003). Two 'I' strips measuring about 15 cm were first utilized. The centre of the first 'I' strip was pulled apart with a 75% tension and applied between the acromioclavicular joint and the humeral head. Following this, the patient's shoulder was passively moved into shoulder flexion (90 degrees) and horizontal adduction after which the posterior tail of the 'I' strip was applied with no tension. Next the patient's shoulder was passively taken into extension and horizontal abduction. In this position the anterior tail of the 'I' strip was applied with no tension. The tape was rubbed with paper to activate the glue. Next, the right shoulder was kept slightly externally rotated in a dependent arm position. The base of the second 'I' strip was placed medial to the anterior tail of the first 'I' strip. The tape was pulled with a 75% tension until the posterior border of the middle deltoid. The patient's shoulder was then passively flexed up to 90 degrees and horizontally adducted following which the remaining tape was applied without tension (Figure 7). A third 'I' strip measuring about 25 cm was next taken and the base was applied 3 inches superior to the acromioclavicular joint. The patient's shoulder was then passively abducted to 90 degrees and the tape was pulled with a 75% tension ending about 3 inches below the right deltoid tuberosity. The tape was rubbed with paper to activate the glue and the shoulder was brought to the anatomical position (Figure 7).

For addressing the swelling in the right hand, another 'I' strip measuring about 25 cm was taken with three holes cut in the centre of the tape and was applied over the index, middle and ring finger. Following this, the wrist was flexed and one end of the tape was applied with a 'paper off' tension over the dorsum of the hand (Figure 8). After this, the wrist was extended and the other end of the 'I' strip was applied with a 'paper off' tension over the volar aspect of the hand (Figure 9). KT is manufactured with about 20% stretch on paper backing and 'paper off' tension means that you apply the KT as it comes out of the paper backing without any added tension. The patient was comfortable after the tape application and was advised to leave it on for 48 hours. If she experienced any discomfort or itching, she was asked to immediately notify the therapist.

At the beginning of the fifth treatment session, her pain intensity in the VAS at rest and on stroking with a paint brush reduced to 4.8 cm and 4.9 cm, respectively. Pain-free lateral rotation of the right shoulder increased to 45 degrees with the size of the right hand reducing to 42.1 cm (Figure 10). The DASH score reduced to 68.3 points and the TSK remained at 13 points, respectively. As the patient was showing good improvement, the same line of management was continued.

3rd and 4th Week

By the seventh session, PEPT was progressed to include graded loading of her daily functions such as washing clothes with hands, cooking and hobbies such as gardening, stitching, painting and literary writing. Also, having a shower with hot or cold water was

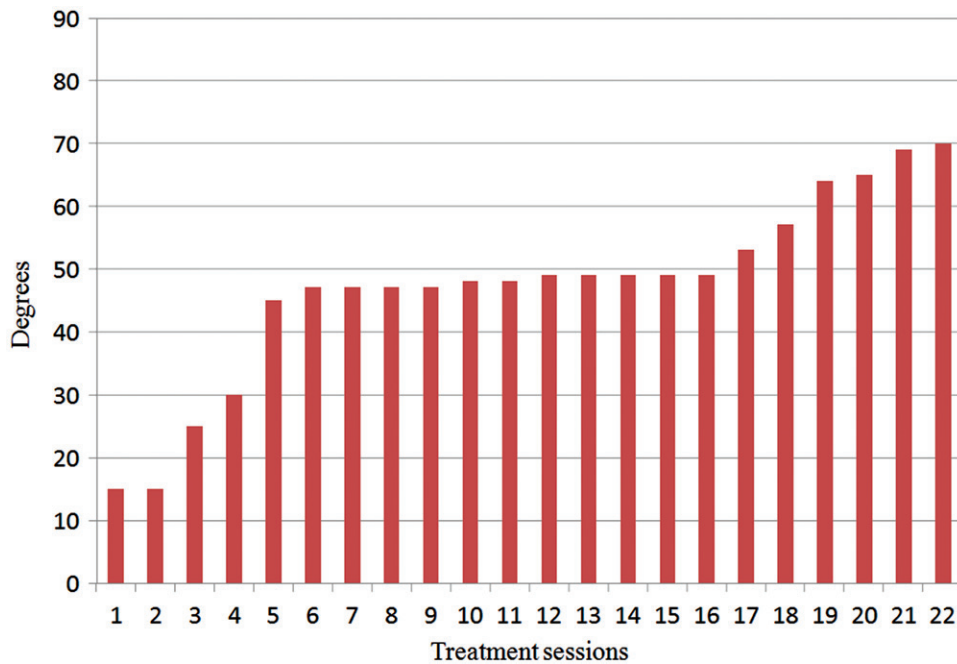


Figure 4. Graph showing improvements in pain free lateral rotation range of motion of the right shoulder.

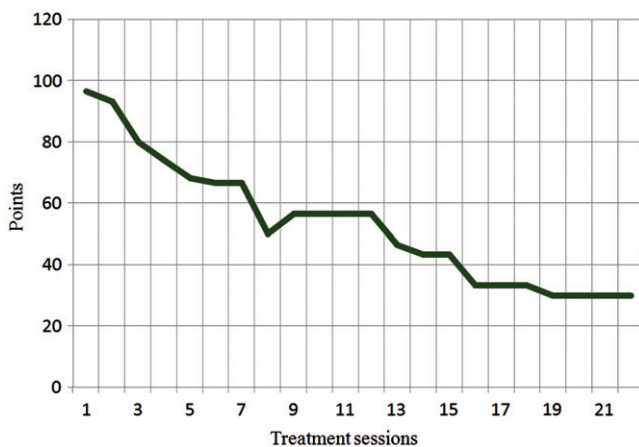


Figure 5. Graph showing progression of DASH scores.

encouraged. The patient reported that bright light or loud noise no longer reproduced her symptoms. By the end of the 4th week, she reported that she had no disturbance in her sleep and that she could concentrate better in her daily chores.

5th and 6th Week

At the beginning of the 13th treatment session, the patient's pain at rest and on stroking with a paint brush reduced to 2.2 cm and 2.6 cm, respectively. Pain-free lateral rotation of the right shoulder increased to 57 degrees with the size of the right hand reducing to 39.9 cm. The DASH score reduced to 46.6 points. No adverse effects were reported during the treatment sessions and the same line of management was carried out. In addition, scapular setting exercises using a Swiss ball (10 times, 3 sets) and rotator cuff strengthening exercises (internal and external rotators) using a Thera-Band[®] latex free resistance band (yellow colour) (10 times, 3 sets) were added as a part of exercise therapy.

By the 16th session, the patient reported that the pain had become intermittent with no temperature or skin colour variations between the right and the left hand. Exercises were progressed to

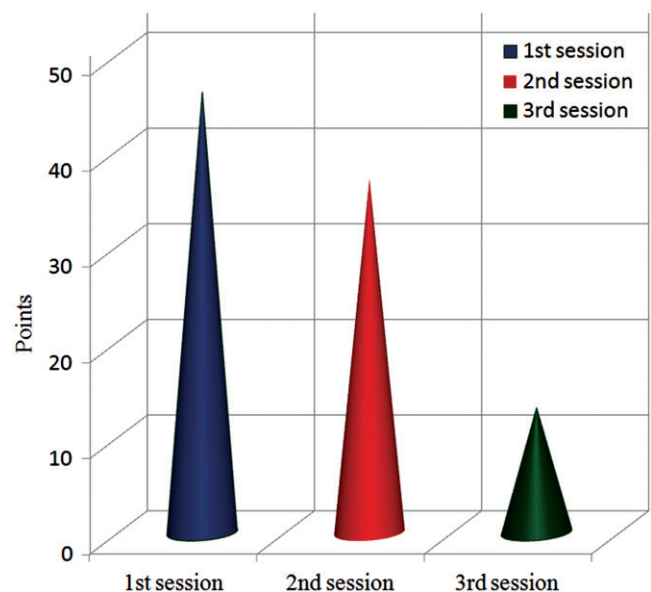


Figure 6. Graph representing immediate reduction in TSK scores following pain neurophysiology education.

scapular weight shifts in the quadruped position (10 times, 3 sets) and proprioceptive neuromuscular facilitation diagonals from D2 extension to D2 flexion (10 times, 3 sets) as a free exercise in standing.

7th and 8th Week

By the beginning of the 7th week, the patient had no pain on stroking with a paint brush. The DASH score reduced to a minimal of 30 points (indicating no disability). However, the patient did complain of intermittent pain in the right shoulder (VAS of 2.1 cm) on days in which she stressed herself excessively with household activities. On palpating the space between the right acromion and the humeral head, no subluxation (Bohannon and Andrews, 1990) was felt. Both TENS and KT application were terminated. No adverse effects as a result of the tape

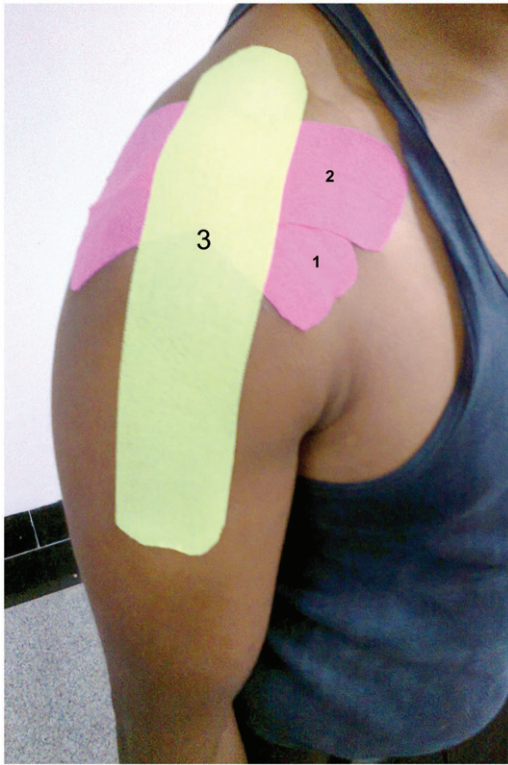


Figure 7. Kinesio taping for the shoulder as shown in a model. Sequences of tape application are numbered as 1, 2 and 3 as applied.



Figure 9. Kinesio tape application for palmar aspect of the hand to reduce swelling as shown in a model.

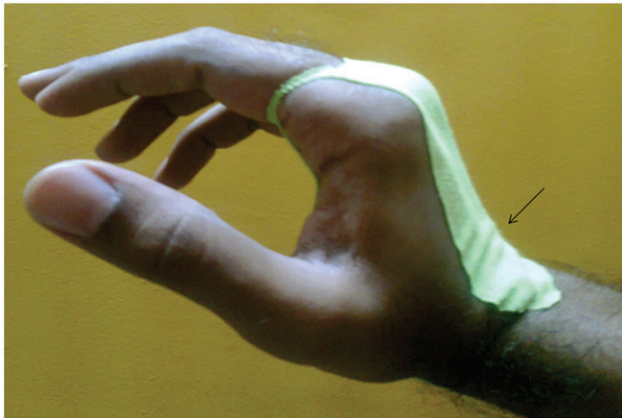

Figure 8. Kinesio tape application for the dorsum of hand as shown in a model. Arrow indicates convolutions created by the tape.

application were reported by the patient during the course of the treatment.

Proprioceptive neuromuscular facilitation diagonals from D2 extension to D2 flexion were progressed using a latex free resistance Thera-Band® (yellow colour) (10 times, 3 sets). By the beginning of the 8th week (22nd treatment session), the patient had complete relief of pain and could perform all her functional activities with no difficulty. Lateral rotation of the right shoulder increased to 70 degrees. It was the maximum available range after which the patient was compensating though she had no pain at the end range. The patient was seen once a week for a period of 1 month and a review after 6 months revealed that the patient was completely pain free and functional.

Discussion

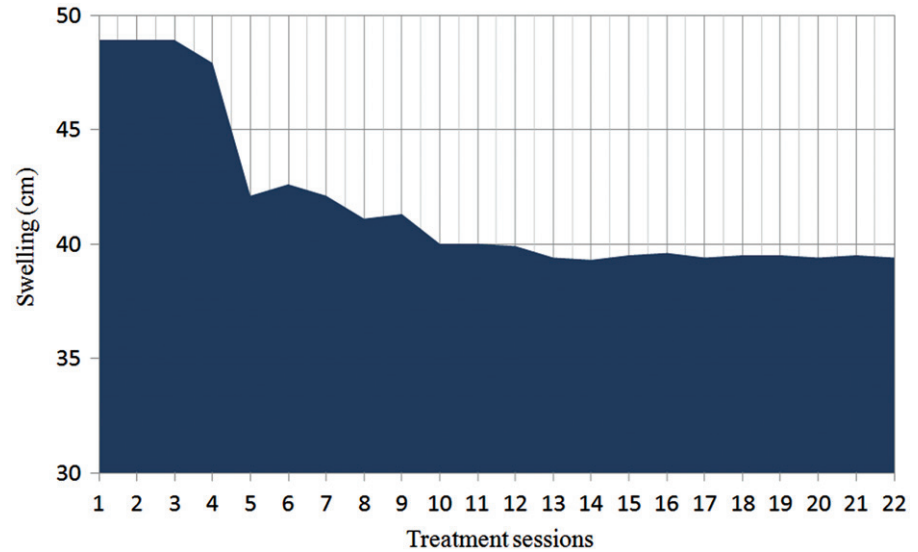
This case report demonstrates the successful multimodal physical therapy management of a patient with CRPS-1. High scores in

TSK obtained at baseline (indicating fear of movement or fear of (re)injury) as well as anxiety, stress, frustration and constant rumination shown by the patient about her pain was suggestive of an affective component contributing to the symptoms. Hence, the first three sessions of pain neurophysiology education was aimed at reconceptualising the perception of her pain and the maladaptive fear avoidance behaviour. There is ample evidence in the literature showing that such educational strategies reduce pain, disability and improve physical performances in patients with chronic musculoskeletal pain (Louw, Diener, Butler, and Puentedura, 2011). Further, these educational classes help in reassuring the patient and prevent pain catastrophizing thoughts. This is crucial because altered beliefs about pain cause lesser pain tolerance with maladaptive coping capabilities (Jackson, Huang, Chen, and Phillips, 2009) and altered motor performance (Nijs et al, 2011). The patient version of the neurophysiology of pain test is a valid and reliable measure in patients with chronic pain (Meeus, Nijs, Elsemans, and De Meirleir, 2010), and the satisfactory test outcome revealed that the patient had an adequate understanding of pain physiology.

The pain education classes also provided a base for discussing the various treatment options available for the patient and the rationale used for administering them. The patient's preferences were taken into account, enabling her compliance in the rehabilitation program extending over a period of 8 weeks. The fact that the minimum clinically important difference for pain intensity was obtained in the VAS along with improvements noted in DASH, TSK and pain-free right shoulder lateral rotation showed that the psychosocial factors and fear avoidance behaviour contributing to the pain were being addressed.

PEPT was started from the end of the third treatment session with an aim to reduce the fear avoidance behaviour related to pain, prevent the disuse of the right upper extremity and increase the patient's self confidence with regards to the capability for performing physical activities (Ek et al, 2009). Desensitization techniques and graded exercises beyond the pain limits were

Figure 10. Graph showing reduction of hand size with figure of eight tape measurement.



carried out in this patient for adaptive coping in response to pain and functional limitations. Functional progressions made by the patient were appreciated by the therapist and the patient was discouraged to ruminate about pain (van de Meent et al, 2011). In this way, the focus was taken away from pain and was centred towards functional capabilities rather than disabilities. Thus, the positive feedback given towards functional progressions further reinforced the behaviour towards the goal of accomplishing the maximum possible level of physical activity. Although graded loading of exercises and desensitization techniques may increase pain following a PEPT session, exacerbations of other CRPS-1 symptoms have not been shown to date (van de Meent et al, 2011). In contrast, significant improvements in pain with full functional recovery have been shown to occur as a result of PEPT (Ek et al, 2009) and are considered to be economical when compared to other treatment options. Other than pain and function, improvements in vasomotor changes, trophic changes and motor functions like grip strength and range of motion have also been shown when an active “stress” loading program had been utilized in subjects with reflex sympathetic dystrophy (Watson and Carlson, 1987). In accordance with previous studies, the patient in this case report showed good functional improvements with significant reduction in pain, making the author continue with PEPT. It must however be noted that PEPT is not indicated and is unlikely to give positive results for patients who do not follow the instructions given by the therapists and doubt the treatment content (van de Meent et al, 2011).

Pain modality in the form of high-frequency TENS was given to the right shoulder with an aim to reduce pain (DeSantana et al, 2008) and thereby help in improving the functional capabilities of the patient. High-frequency TENS activates the δ -opioid receptors (Kalra, Urban, and Sluka, 2001) and produces an opioid-mediated antinociception at the level of the periaqueductal grey to cause analgesia (DeSantana, Da Silva, De Resende, and Sluka, 2009). Increase in the mechanical pain thresholds has been shown in healthy subjects who were given high frequency TENS for 30 minutes (Chesterton et al, 2003). Further, high-frequency TENS is shown to reduce mechanical and thermal allodynia (Gopalkrishnan and Sluka, 2000).

Recently, the use of KT has become popular among physical therapists and is increasingly being applied as an adjunct to other treatment tools that physical therapists utilize (Kaya, Zinnuroglu, and Tugcu, 2011). KT was applied to the shoulder primarily for providing mechanical support and reducing pain (Kase, Wallis, and Kase, 2003). KT produces a tension onto the skin and is

believed to stimulate the mechanoreceptors, thus reducing and modulating pain through the gate control theory (González-Iglesias et al, 2009; Thelen, Dauber, and Stoneman, 2008). Nociception carried by the small diameter nerve fibres is alleviated by the afferent feedback from the large diameter nerve fibres, facilitating pain inhibition mechanisms (González-Iglesias et al, 2009; Thelen, Dauber, and Stoneman, 2008). Further, the tension provided by the tape onto the shoulder provides mechanical support and the sensory stimulation during movement is believed to cause joint repositioning to normalize the tension perceived by the body.

KT was applied to the hand with an aim to reduce swelling (Kase, Wallis, and Kase, 2003). An immediate reduction in swelling after KT application at the beginning of the fifth treatment session showed that it could be due to the convolutions created by the tape (Figure 8). Convolutions are created as a result of the physical properties of KT where due to a “lifting” effect a space is believed to be created under the skin (Kase, Wallis, and Kase, 2003). This causes increased blood flow, lymphatic flow, removal of exudates and reduced chemical receptor irritation (Kase, Wallis, and Kase, 2003). Improvements noted in pain and swelling encouraged the therapist to continue with KT application as an adjunct treatment to TENS and PEPT.

By the fifth week, as the patient had considerable reduction in pain and functional improvement, scapular setting exercises were initiated to increase the scapular muscle stabilization and rotator cuff strengthening exercises were started with an aim to centre the humeral head within the glenoid cavity (Escamilla, Yamashiro, Paulos, and Andrews, 2009). The fact that no subluxation (grade 0) (Bohannon and Andrews, 1990) was found showed that the muscular forces were probably causing a dynamic stabilization of the humeral head within the glenoid (Escamilla, Yamashiro, Paulos, and Andrews, 2009). Exercises were progressed to include proprioceptive neuromuscular facilitation patterns from D2 extension to D2 flexion with an aim to make it more functional for the patient. At the beginning of the 8th week, the patient had complete relief of pain and this report demonstrated that the positive gains achieved through multimodal physical therapy management could be maintained up to a period of 6 months.

Cortical reorganization occurs in CRPS where the represented body part effectively shrinks and the extent of its shift is co-related with pain intensity (Maihöfner, Handwerker, Neundörfer, and Birklein, 2004). Treatment approaches like mirror therapy are utilized to cause a change at the supraspinal level and is found to be effective in patients with CRPS-1

(Cacchio et al, 2009a, 2009b). Further, interventions like constraint induced movement therapy which involves the use of the paretic extremity by having a restraint on the unaffected limb have shown good results in chronic stroke subjects where cortical changes like expansion of the opposite side cortico-motor area have been demonstrated (Azab et al, 2009). In PEPT, sensory desensitization techniques and graded exercises are given to the affected extremity with an aim to reduce kinesiophobia and improve use in daily activities. However, it is unknown if this causes any changes in the representation at the cortical level, forming an implication for future clinical research.

Conclusion

This case report describes the diagnosis and physical therapy management of a patient which included pain neurophysiology education, TENS, KT, PEPT and exercise therapy. PEPT is emerging as an effective treatment option for patient's affected with CRPS-1. It must be noted that the mechanism of pain in CRPS-1 (e.g. sympathetically mediated pain versus nonsympathetically mediated pain) varies between each patient where one mechanism may be more prominent than the other. Hence, after utilizing the recently validated Budapest diagnostic criteria to 'rule in' CRPS-1, therapists must carry out a detailed examination to determine the prominent mechanism of pain and the various contributing factors (e.g. fear avoidance belief). Based on that, physical therapy management must be tailored for each patient's needs.

Declaration of interest

The authors report no declarations of interest.

References

Albrecht PJ, Hines S, Eisenberg E, Pud D, Finlay DR, Connolly MK, Paré M, Davar G, Rice FL 2006 Pathologic alterations of cutaneous innervation and vasculature in affected limbs from patients with complex regional pain syndrome. *Pain* 120: 244–266.

Azab M, Al-Jarrah M, Nazzal M, Maayah M, Sammour MA, Jamous M 2009 Effectiveness of constraint-induced movement therapy (CIMT) as home-based therapy on Barthel Index in patients with chronic stroke. *Topics in Stroke Rehabilitation* 16: 207–211.

Beaton DE, Davis AM, Hudak P, McConnell S 2001 The DASH (Disabilities of the Arm, Shoulder and Hand) outcome measure: What do we know about it now? *British Journal of Hand Therapy* 6: 109–118.

Bijur PE, Silver W, Gallagher EJ 2001 Reliability of the visual analog scale for measurement of acute pain. *Academic Emergency Medicine* 8: 1153–1157.

Bohannon RW, Andrews AW 1990 Shoulder subluxation and pain in stroke patients. *American Journal of Occupational Therapy* 44: 507–509.

Boonstra AM, Schiphorst Preuper HR, Reneman MF, Posthumus JB, Stewart RE 2008 Reliability and validity of the visual analogue scale for disability in patients with chronic musculoskeletal pain. *International Journal of Rehabilitation Research* 31: 162–169.

Braus DF, Krauss JK, Strobel J 1994 The shoulder-hand syndrome after stroke: A prospective clinical trial. *Annals of Neurology* 36: 728–733.

Bruehl S, Harden R, Galer B, Saltz S, Bertram M, Backonja M, Gayles R, Rudin N, Bhugra MK, Stanton-Hicks M 1999 External validation of IASP diagnostic criteria for Complex Regional Pain Syndrome and proposed research diagnostic criteria. *International Association for the Study of Pain*. *Pain* 81: 147–154.

Butler D, Moseley GL 2003 Explain pain. Adelaide, NOI Group Publication.

Cacchio A, De Blasis E, De Blasis V, Santilli V, Spacca G 2009a Mirror therapy in complex regional pain syndrome type 1 of the upper limb in stroke patients. *Neurorehabilitation and Neural Repair* 23: 792–799.

Cacchio A, De Blasis E, Necozone S, di Orto F, Santilli V 2009b Mirror therapy for chronic complex regional pain syndrome type 1 and stroke. *New England Journal of Medicine* 361: 634–636.

Chae J 2010 Poststroke complex regional pain syndrome. *Topics in Stroke Rehabilitation* 17: 151–162.

Chesterton LS, Foster NE, Wright CC, Baxter GD, Barlas P 2003 Effects of TENS frequency, intensity and stimulation site parameter manipulation on pressure pain thresholds in healthy human subjects. *Pain* 106: 73–80.

Culham EG, Noce RR, Bagg SD 1995 Shoulder complex position and glenohumeral subluxation in hemiplegia. *Archives of Physical Medicine and Rehabilitation* 76: 857–864.

Daly AE, Bialocerowski AE 2009 Does evidence support physiotherapy management of adult Complex Regional Pain Syndrome Type One? A systematic review. *European Journal of Pain* 13: 339–353.

DeSantana JM, Da Silva LF, De Resende MA, Sluka KA 2009 Transcutaneous electrical nerve stimulation at both high and low frequencies activates ventrolateral periaqueductal grey to decrease mechanical hyperalgesia in arthritic rats. *Neuroscience* 163: 1233–1241.

DeSantana JM, Walsh DM, Vance C, Rakel BA, Sluka KA 2008 Effectiveness of transcutaneous electrical nerve stimulation for treatment of hyperalgesia and pain. *Current Rheumatology Reports* 10: 492–499.

Ek JW, van Gijn JC, Samwel H, van Egmond J, Klomp FP, van Dongen RT 2009 Pain exposure physical therapy may be a safe and effective treatment for longstanding complex regional pain syndrome type 1: A case series. *Clinical Rehabilitation* 23: 1059–1066.

Escamilla RF, Yamashiro K, Paulos L, Andrews JR 2009 Shoulder muscle activity and function in common shoulder rehabilitation exercises. *Sports Medicine* 39: 663–685.

Feldman SI, Downey G, Schaffer-Neitz R 1999 Pain, negative mood, and perceived support in chronic pain patients: A daily diary study of people with reflex sympathetic dystrophy syndrome. *Journal of Consulting and Clinical Psychology* 67: 776–785.

French DJ, France CR, Vigneau F, French JA, Evans RT 2007 Fear of movement/(re)injury in chronic pain: A psychometric assessment of the original English version of the Tampa scale for kinesiophobia (TSK). *Pain* 127: 42–51.

Fukumoto M, Ushida T, Zinchuk VS, Yamamoto H, Yoshida S 1999 Contralateral thalamic perfusion in patients with reflex sympathetic dystrophy syndrome. *Lancet* 354: 1790–1791.

Geurts AC, Visschers BA, van Limbeek J, Ribbers GM 2000 Systematic review of aetiology and treatment of post-stroke hand oedema and shoulder-hand syndrome. *Scandinavian Journal of Rehabilitation Medicine* 32: 4–10.

Goebel A 2011 Complex regional pain syndrome in adults. *Rheumatology* 50: 1739–1750.

González-Iglesias J, Fernández-de-Las-Peñas C, Cleland JA, Hujibregts P, Del Rosario Gutiérrez-Vega M 2009 Short-term effects of cervical kinesio taping on pain and cervical range of motion in patients with acute whiplash injury: A randomized clinical trial. *Journal of Orthopaedic and Sports Physical Therapy* 39: 515–521.

Gopalkrishnan P, Sluka KA 2000 Effect of varying frequency, intensity, and pulse duration of transcutaneous electrical nerve stimulation on primary hyperalgesia in inflamed rats. *Archives of Physical Medicine and Rehabilitation* 81: 984–990.

Groeneweg JG, Huygen FJ, Heijmans-Antonissen C, Niehof S, Zijlstra FJ 2006 Increased endothelin-1 and diminished nitric oxide levels in blister fluids of patients with intermediate cold type complex regional pain syndrome type 1. *BMC Musculoskeletal Disorders* 7: 1–8.

Harden RN, Bruehl S, Perez RS, Birklein F, Marinus J, Maihofner C, Lubenow T, Buvanendran A, Mackey S, Graciosa J, Mogilevski M, Ramsden C, Chont M, Vatine JJ 2010 Validation of proposed diagnostic criteria (the "Budapest Criteria") for Complex Regional Pain Syndrome. *Pain* 150: 268–274.

Heijmans-Antonissen C, Wesseldijk F, Munnikes RJ, Huygen FJ, van der Meijden P, Hop WC, Hooijkaas H, Zijlstra FJ 2006 Multiplex bead array assay for detection of 25 soluble cytokines in blister fluid of patients with complex regional pain syndrome type I. *Mediators of Inflammation* 2006: 28398.

Jackson T, Huang X, Chen H, Phillips H 2009 Effects of threatening information on interpersonal responses to pain. *European Journal of Pain* 13: 431–438.

Juottonen K, Gockel M, Silén T, Hurri H, Hari R, Forss N 2002 Altered central sensorimotor processing in patients with complex regional pain syndrome. *Pain* 98: 315–323.

- Kalichman L, Ratmansky M 2011 Underlying pathology and associated factors of hemiplegic shoulder pain. *American Journal of Physical Medicine and Rehabilitation* 90: 768–780.
- Kalra A, Urban MO, Sluka KA 2001 Blockade of opioid receptors in rostral ventral medulla prevents antihyperalgesia produced by transcutaneous electrical nerve stimulation (TENS). *Journal of Pharmacology and Experimental Therapeutics* 298: 257–263.
- Kase K, Wallis J, Kase T 2003 Clinical therapeutic applications of the kinesio taping method, 2nd edn. Tokyo, Ken Ikai Co Ltd.
- Kaya E, Zinnuroglu M, Tugcu I 2011 Kinesio taping compared to physical therapy modalities for the treatment of shoulder impingement syndrome. *Clinical Rheumatology* 30: 201–207.
- Kelly AM 2001 The minimum clinically significant difference in visual analogue scale pain score does not differ with severity of pain. *Emergency Medicine Journal* 18: 202–205.
- Kingery WS 2010 Role of neuropeptide, cytokine, and growth factor signaling in complex regional pain syndrome. *Pain Medicine* 11: 1239–1250.
- Koban M, Leis S, Schultze-Mosgau S, Birklein F 2003 Tissue hypoxia in complex regional pain syndrome. *Pain* 104: 149–157.
- Kocabas H, Levendoglu F, Ozerbil OM, Yuruten B 2007 Complex regional pain syndrome in stroke patients. *International Journal of Rehabilitation Research* 30: 33–38.
- Koltyn KF, Arbogast RW 1998 Perception of pain after resistance exercise. *British Journal of Sports Medicine* 32: 20–24.
- Lakshminarayan K, Anderson DC, Jacobs Jr DR, Barber CA, Luepker RV 2009 Stroke rates: 1980–2000: The Minnesota stroke survey. *American Journal of Epidemiology* 169: 1070–1078.
- Leard JS, Breglio L, Fraga L, Ellrod N, Nadler L, Yasso M, Fay E, Ryan K, Pellecchia GL 2004 Reliability and concurrent validity of the figure-of-eight method of measuring hand size in patients with hand pathology. *Journal of Orthopaedic and Sports Physical Therapy* 34: 335–340.
- Louw A, Diener I, Butler DS, Puenteadura EJ 2011 The effect of neuroscience education on pain, disability, anxiety, and stress in chronic musculoskeletal pain. *Archives of Physical Medicine and Rehabilitation* 92: 2041–2056.
- Magee DJ 2006 *Orthopedic physical assessment*, 4th edn. St. Louis, MO, Saunders Elsevier.
- Maihöfner C, Handwerker HO, Neundörfer B, Birklein F 2003 Patterns of cortical reorganization in complex regional pain syndrome. *Neurology* 61: 1707–1715.
- Maihöfner C, Handwerker HO, Neundörfer B, Birklein F 2004 Cortical reorganization during recovery from complex regional pain syndrome. *Neurology* 63: 693–701.
- Marinus J, Moseley GL, Birklein F, Baron R, Maihöfner C, Kingery WS, van Hilten JJ 2011 Clinical features and pathophysiology of complex regional pain syndrome. *Lancet Neurology* 10: 637–648.
- McLean DE 2004 Medical complications experienced by a cohort of stroke survivors during inpatient, tertiary-level stroke rehabilitation. *Archives of Physical Medicine and Rehabilitation* 85: 466–469.
- Meeus M, Nijs J, Elsemans KS, De Meirleir K 2010 Development and properties of the Dutch neurophysiology of pain test in patients with chronic fatigue syndrome. *Journal of Musculoskeletal Pain* 18: 58–65.
- Merskey H, Bogduk N 1994 *Classification of chronic pain, descriptions of chronic pain syndromes and definitions of pain terms*. Seattle, IASP Press.
- Millan MJ 2002 Descending control of pain. *Progress in Neurobiology* 66: 355–474.
- Mintken PE, Cleland JA, Whitman JM, George SZ 2010 Psychometric properties of the fear-avoidance beliefs questionnaire and Tampa scale of kinesiophobia in patients with shoulder pain. *Archives of Physical Medicine and Rehabilitation* 91: 1128–1136.
- Moseley GL 2006 Graded motor imagery for pathologic pain: A randomized controlled trial. *Neurology* 67: 2129–2134.
- Murie-Fernández M, Carmona Iragui M, Gnanakumar V, Meyer M, Foley N, Teasell R 2012 Painful hemiplegic shoulder in stroke patients: Causes and management. *Neurologia* 27: 234–244.
- Niehof SP, Huygen FJ, van der Weerd RW, Westra M, Zijlstra FJ 2006 Thermography imaging during static and controlled thermoregulation in complex regional pain syndrome type I: Diagnostic value and involvement of the central sympathetic system. *Biomedical Engineering Online* 5: 1–13.
- Nijs J, Paul van Wilgen C, Van Oosterwijck J, van Ittersum M, Meeus M 2011 How to explain central sensitization to patients with ‘‘unexplained’’ chronic musculoskeletal pain: Practice guidelines. *Manual Therapy* 16: 413–418.
- Nijs J, Van Houdenhove B, Oostendorp RA 2010 Recognition of central sensitization in patients with musculoskeletal pain: Application of pain neurophysiology in manual therapy practice. *Manual Therapy* 15: 135–141.
- Oaklander AL, Rissmiller JG, Gelman LB, Zheng L, Chang Y, Gott R 2006 Evidence of focal small-fiber axonal degeneration in complex regional pain syndrome-I (reflex sympathetic dystrophy). *Pain* 120: 235–243.
- Pleger B, Ragert P, Schwenkreis P, Förster AF, Wilimzig C, Dinse H, Nicolas V, Maier C, Tegenthoff M 2006 Patterns of cortical reorganization parallel impaired tactile discrimination and pain intensity in complex regional pain syndrome. *NeuroImage* 32: 503–510.
- Pleger B, Tegenthoff M, Ragert P, Förster AF, Dinse HR, Schwenkreis P, Nicolas V, Maier C 2005 Sensorimotor retuning in complex regional pain syndrome parallels pain reduction. *Annals of Neurology* 57: 425–429.
- Pleger B, Tegenthoff M, Schwenkreis P, Janssen F, Ragert P, Dinse HR, Völker B, Zenz M, Maier C 2004 Mean sustained pain levels are linked to hemispherical side-to-side differences of primary somatosensory cortex in the complex regional pain syndrome I. *Experimental Brain Research* 155: 115–119.
- Price DD, McGrath PA, Rafii A, Buckingham B 1983 The validation of visual analogue scales as ratio scale measures for chronic and experimental pain. *Pain* 17: 44–56.
- Roy JS, MacDermid JC, Woodhouse LJ 2009 Measuring shoulder function: A systematic review of four questionnaires. *Arthritis and Rheumatism* 61: 623–632.
- Schinkel C, Gaertner A, Zaspel J, Zedler S, Faist E, Schuermann M 2006 Inflammatory mediators are altered in the acute phase of posttraumatic Complex Regional Pain Syndrome. *Clinical Journal of Pain* 22: 235–239.
- Sebastian D 2005 *Principles of manual therapy*. New Delhi, Jaypee Brothers Medical Publishers.
- Thelen MD, Dauber JA, Stoneman PD 2008 The clinical efficacy of kinesio tape for shoulder pain: A randomized, double blinded, clinical trial. *Journal of Orthopaedic and Sports Physical Therapy* 38: 389–395.
- van de Meent H, Oerlemans M, Bruggeman A, Klomp F, van Dongen R, Oostendorp R, Frölke JP 2011 Safety of ‘‘pain exposure’’ physical therapy in patients with complex regional pain syndrome type I. *Pain* 152: 1431–1438.
- Veldman PH, Reynen HM, Arntz IE, Goris RJ 1993 Signs and symptoms of reflex sympathetic dystrophy: Prospective study of 829 patients. *Lancet* 342: 1012–1016.
- Watson HK, Carlson L 1987 Treatment of reflex sympathetic dystrophy of the hand with an active ‘‘stress loading’’ program. *Journal of Hand Surgery* 12: 779–785.
- Woolf CJ 2011 Central sensitization: Implications for the diagnosis and treatment of pain. *Pain* 152: S2–S15.
- Woolf CJ, Salter MW 2000 Neuronal plasticity: Increasing the gain in pain. *Science* 288: 1765–1769.

Appendix 1 – Budapest diagnostic criteria (2010) for CRPS

To make a clinical diagnosis, the following criteria must be met:

- (a) Continuing pain, which is disproportionate to any inciting event
- (b) Must report at least one symptom in three of the four following categories:
 - (i) Sensory – reports of hyperesthesia and/or allodynia
 - (ii) Vasomotor – reports of temperature asymmetry and/or skin color changes and/or skin color asymmetry
 - (iii) Sudomotor/Oedema – reports of edema and/or sweating changes and/or sweating asymmetry
 - (iv) Motor/Trophic – reports of decreased range of motion and/or motor dysfunction (weakness, tremor, dystonia) and/or trophic changes (hair, nail, skin)
- (c) Must display at least one sign at time of evaluation in two or more of the following categories:
 - (i) Sensory – evidence of hyperalgesia (to pinprick) and/or allodynia (to light touch and/or temperature sensation and/or deep somatic pressure and/or joint movement)
 - (ii) Vasomotor – evidence of temperature asymmetry (>1 °C) and/or skin color changes and/or asymmetry

- (iii) Sudomotor/Oedema – evidence of oedema and/or sweating changes and/or sweating asymmetry
 - (iv) Motor/Trophic – evidence of decreased range of motion and/or motor dysfunction (weakness, tremor, dystonia) and/or trophic changes (hair, nail, skin)
 - (d) There is no other diagnosis that better explains the signs and symptoms
- For research purposes, diagnostic decision rule should be at least one symptom in all four symptom categories and at least one sign (observed at evaluation) in two or more sign categories.