

## CASE REPORT

# Transient hemiparesis due to a ruptured cerebral aneurysm in the prehospital setting

Youichi Yanagawa,<sup>1</sup> Kazuoki Hirano,<sup>2</sup> Arisa Hayashida,<sup>2</sup> Tomoko Nakazato<sup>2</sup>

<sup>1</sup>Department of Emergency and Disaster Medicine, Juntendo University Shizuoka Hospital, Izunokuni, Shizuoka, Japan  
<sup>2</sup>Juntendo University, Bunkyo-ku, Tokyo, Japan

**Correspondence to**  
Professor Youichi Yanagawa,  
yyanaga@juntendo.ac.jp

## SUMMARY

A 67-year-old woman developed a sudden onset headache and left hemiparesis. Emergency medical technicians found that she was conscious, but had left hemiparesis. On arrival, she had an isolated headache without any neurological deficits, however, suddenly became comatose during a head CT examination, which demonstrated a subarachnoid haemorrhage. The head CT angiography on the second day revealed a cerebral aneurysm at the right middle cerebral artery, which was clipped on the same day. The patient demonstrated left haemiplegia and total aphasia after the operation, however, the neurological deficit gradually subsided and discharged on foot in 4 months without any deficits. Some patients with a subarachnoid haemorrhage may demonstrate transient neurological deficits, like those occurring during an ischaemic stroke, so emergency medical technicians and physicians should pay attention to treat such patients gently to avoid the re-rupture of a cerebral aneurysm, especially if the patient has headache symptoms.

## BACKGROUND

The main symptoms of a ruptured cerebral aneurysm are a sudden onset headache or unconsciousness after a headache, without any neurological deficit. However, approximately one-third of patients with a ruptured cerebral aneurysm demonstrate a neurological deficit based on complications associated with an intracerebral haematoma or the localisation of the subarachnoid haemorrhage.<sup>1</sup> This deficit usually does not improve in the short time during transportation from the scene to a local hospital, and there have so far been no reports which demonstrated any transient neurological deficit due to a ruptured cerebral aneurysm in the prehospital setting. Hence, we report the first case of a transient hemiparesis due to a ruptured cerebral aneurysm in the prehospital setting and discuss the mechanism underlying this phenomenon.

## CASE PRESENTATION

A 67-year-old woman developed a sudden onset headache and left hemiparesis that prevented her from standing and walking. She had no specific history or family history. Emergency medical technicians found that she was conscious, but had left hemiparesis.

## INVESTIGATIONS

On arrival, she remained conscious. Her vital signs were: blood pressure 170/82 mm Hg; heart rate 84

bpm and percutaneous oxygen saturation on room air 99%. The left hemiparesis subsided, but she had an isolated headache without any neurological deficits. She suddenly became comatose during a head CT examination, which demonstrated a subarachnoid haemorrhage (figure 1). She immediately underwent tracheal intubation to secure her airway after being given a sedative and muscle relaxant. A biochemical blood examination revealed no specific changes. The head CT on the second day of hospitalisation demonstrated a subarachnoid haemorrhage with a sylvian haematoma and CT angiography revealed two cerebral aneurysms at the right middle cerebral and anterior communicating arteries (figure 2).

## DIFFERENTIAL DIAGNOSIS

According to previous reports, the differential diagnosis for a headache with a transient neurological deficit was a migraine with hemiparesis, dissection of the cerebral artery, traumatic extra-axial haematoma, vasculitis or syndrome of transient headache and neurological deficits with cerebrospinal fluid lymphocytosis.<sup>2–8</sup> These diseases could all be ruled out based on the results of CT and CT angiography in this case.

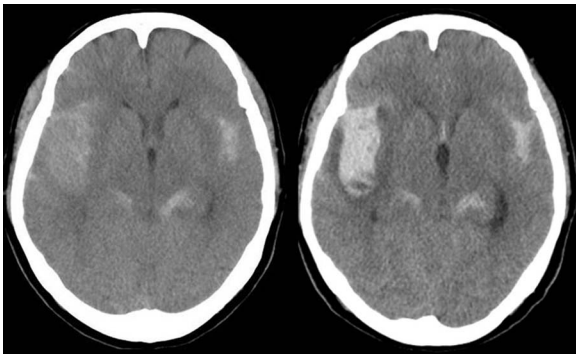
## TREATMENT

After the diagnosis of a ruptured aneurysm, the patient underwent aggressive blood pressure control targeting under 120 mm Hg of systolic blood pressure and was also treated for vasospasm using nicardipine, stress control and the prevention of convulsions using midazolam, respiratory support with mechanical ventilation using vecuronium and the prevention of Cushing ulcer formation using ranitidine. On the second hospital day, we clipped both aneurysms, confirming that the middle cerebral aneurysm was the bleeding source and evacuated the sylvian haematoma. After performing the aneurysmal clipping, cysternal drainage of the subarachnoid haemorrhage, permissive hypertension management and the use of fasudil were applied; the use of nicardipine was continued for the treatment of cerebral vasospasm, and a dehydrator was also used to treat brain oedema.

## OUTCOME AND FOLLOW-UP

The patient demonstrated left haemiplegia and total aphasia after the operation, however, the neurological deficit gradually subsided and the patient was discharged on foot within 4 months without any deficits.

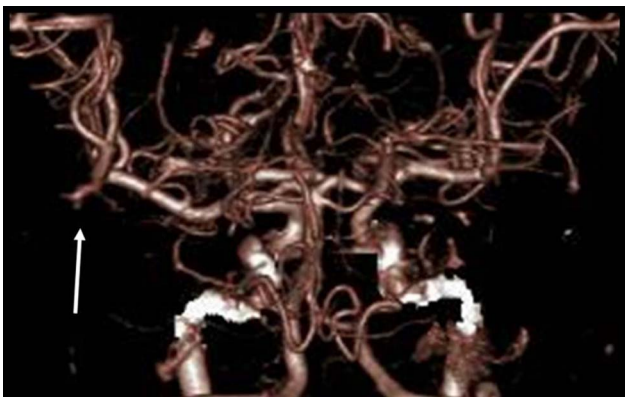
**To cite:** Yanagawa Y, Hirano K, Hayashida A, et al. *BMJ Case Rep* Published online: [please include Day Month Year] doi:10.1136/bcr-2013-010321



**Figure 1** Head CT on arrival (right) and on the second day (left). The head CT on arrival demonstrated a diffuse subarachnoid haemorrhage. The right sylvian fissure had a fresh subarachnoid haemorrhage during CT examination on arrival, which was confirmed the next day.

## DISCUSSION

The present case demonstrated transient left hemiparesis with a sudden onset headache due to a ruptured middle cerebral aneurysm in the prehospital setting, and became comatose after re-rupture of the aneurysm after she was admitted to the hospital. There has been no report which described improvement of such deficit due to a ruptured cerebral aneurysm in the short time during transportation from the scene to a local hospital. The one possible mechanism causing the transient neurological deficit was subsequent distal embolisation or parent vessel occlusion due to local extension from an intrasaccular aneurysmal thrombosis.<sup>9</sup> The factors associated with aneurysmal thrombosis are the size, and particularly, the ratio of the chamber volume to the orifice area, blood stagnation, slow flow and increased blood viscosity.<sup>9</sup> The aneurysmal size of the present case was less than 10 mm and the neck was narrow, so this condition was considered to be unlikely. Another possible mechanism was transient ischaemia based on hemodynamic insufficiency due to vaso-



**Figure 2** A CT angiogram taken on the second day. The CT angiogram demonstrated a cerebral aneurysm at the right middle cerebral artery (arrow).

spasm induced by a subarachnoid haemorrhage.<sup>10</sup> The cerebral artery can exhibit spastic changes induced by subarachnoid haemorrhage immediately after aneurysmal rupture during the subacute phase. Immediate transient vasospastic changes following a hemodynamic insufficient blood supply, which was rapidly resolved by hypertension, may have caused the hemiparesis in the prehospital setting in this case.

## Learning points

- ▶ Some patients with subarachnoid haemorrhage may demonstrate transient neurological deficits, like those occurring during an ischaemic stroke.
- ▶ Re-rupture of a cerebral aneurysm could be lethal.
- ▶ Emergency medical technicians and physicians should treat such patients gently to avoid the re-rupture of a cerebral aneurysm, especially if the patient has headache symptoms; for example, aggressive headache control using pain killers, stress control using sedatives and anticonvulsant medication and blood pressure control after a diagnosis of subarachnoid haemorrhage, are recommended to prevent any fatal re-bleeding of the aneurysm until either aneurysmal neck clipping or coiling can be performed.

**Acknowledgements** The authors would like to thank Dr Katoh who treated the patient.

**Competing interests** None.

**Patient consent** Obtained.

**Provenance and peer review** Not commissioned; externally peer reviewed.

## REFERENCES

- 1 van Gijn J, Rinkel GJ. Subarachnoid haemorrhage: diagnosis, causes and management. *Brain* 2001;124:249–78.
- 2 Pelzer N, Stam AH, Haan J, et al. Familial and sporadic hemiplegic migraine: diagnosis and treatment. *Curr Treat Options Neurol* 2013;15:13–27.
- 3 Hsieh PF, Lee YC, Chang MH. Unilateral carotid and vertebral artery dissections and contralateral subarachnoid hemorrhage in a postpartum patient. *Acta Neurol Taiwan* 2008;17:94–8.
- 4 Chaves C, Estol C, Esnaola MM, et al. Spontaneous intracranial internal carotid artery dissection: report of 10 patients. *Arch Neurol* 2002;59:977–81.
- 5 Rahimi AR, Poorkay M. Subdural hematomas and isolated transient aphasia. *J Am Med Dir Assoc* 2000;1:129–31.
- 6 Lemmens R, Ceuppens J, Wilms G, et al. Transient hemiparesis caused by spontaneous cervical epidural hematoma. *Acta Neurol Belg* 2012;112:291–3.
- 7 Limotai C, Phanthumchinda K. Cerebral venous sinus thrombosis in Behcet's disease: a case report. *J Med Assoc Thai* 2004;87:845–9.
- 8 Krause T, Nolte CH. The syndrome of transient headache and neurological deficits with cerebrospinal fluid lymphocytosis (HaNDL) as an acute ischemic stroke mimic leading to systemic thrombolysis: a case report. *Clin Neurol Neurosurg* 2012;114:689–90.
- 9 Guillon B, Daumas-Duport B, Delaroché O, et al. Cerebral ischemia complicating intracranial aneurysm: a warning sign of imminent rupture? *AJNR Am J Neuroradiol* 2011;32:1862–5.
- 10 Arutiunov AI, Baron MA, Majorova NA. Experimental and clinical study of the development of spasm of the cerebral arteries related to subarachnoid hemorrhage. *J Neurosurg* 1970;32:617–25.

Copyright 2013 BMJ Publishing Group. All rights reserved. For permission to reuse any of this content visit <http://group.bmj.com/group/rights-licensing/permissions>.  
BMJ Case Report Fellows may re-use this article for personal use and teaching without any further permission.

Become a Fellow of BMJ Case Reports today and you can:

- ▶ Submit as many cases as you like
- ▶ Enjoy fast sympathetic peer review and rapid publication of accepted articles
- ▶ Access all the published articles
- ▶ Re-use any of the published material for personal use and teaching without further permission

For information on Institutional Fellowships contact [consortiasales@bmjgroup.com](mailto:consortiasales@bmjgroup.com)

Visit [casereports.bmj.com](http://casereports.bmj.com) for more articles like this and to become a Fellow