

CASE REPORTS

Sudden headache, third nerve palsy and visual deficit: thinking outside the subarachnoid haemorrhage box

DANIELLE NÍ CHRÓINÍN¹, JOHN LAMBERT²

¹Department of Care of the Elderly, Beaumont Hospital, Dublin, Ireland

²Department of Infectious Diseases, Mater Misericordiae University Hospital, Dublin, Ireland

Address correspondence to: D. Ní Chróinín. Tel: +35317164574; Fax: +35317164557. Email: dmmnic@student.ucc.ie

Abstract

A 75-year-old lady presented with sudden severe headache and vomiting. Examination was normal, and CT and lumbar puncture not convincing for subarachnoid haemorrhage. Shortly thereafter, she developed painless diplopia. Examination confirmed right third cranial nerve palsy plus homonymous left inferior quadrantanopia. Urgent cerebral MRI with angiography was requested to assess for a possible posterior communicating artery aneurysm, but revealed an unsuspected pituitary mass. Pituitary adenoma with pituitary apoplexy was diagnosed. Pituitary apoplexy is a syndrome comprising sudden headache, meningism, visual and/or oculomotor deficits, with an intrasellar mass. It is commonly due to haemorrhage or infarction within a pituitary adenoma. Treatment includes prompt steroid administration, and potentially surgical decompression. While subarachnoid haemorrhage is an important, well-recognised cause of sudden severe headache, other aetiologies, including pituitary apoplexy, should be considered and sought.

Keywords: *pituitary apoplexy, pituitary neoplasms, headache, cranial nerve diseases, older people*

Case

A 75-year-old lady presented with sudden severe headache and vomiting. Background history included hypertension and type II diabetes mellitus. Examination, including blood pressure, was normal, and venous glucose mildly elevated. The history was concerning for subarachnoid haemorrhage. CT brain did not show any subarachnoid blood (Figure 1a), and lumbar puncture revealed few red cells, falling sequentially between sample containers. Shortly thereafter, she developed painless diplopia. Examination confirmed right third cranial nerve palsy, with miosis, ptosis and ophthalmoplegia (Figure 1b). Visual field testing revealed a homonymous left-sided inferior quadrant deficit. Cerebral MRI with angiography was expedited to assess for a possible posterior communicating artery aneurysm. This revealed an unsuspected pituitary mass (Figure 1c). On review, the CT brain also showed a subtle hyperdensity in the pituitary fossa. A

diagnosis of pituitary adenoma with pituitary apoplexy was made. The patient was immediately commenced on steroid therapy, and happily improved.

Discussion

Sudden severe headache is a common presenting symptom, both in primary and secondary care settings. The stereotypical presentation of subarachnoid haemorrhage is familiar to most clinicians. Investigations, including CT, lumbar puncture and angiography, are often employed to confirm or outrule this diagnosis. However, other conditions may present with thunderclap-style headache, and should not be overlooked. These include meningitis, cervical arterial dissection, venous sinus thrombosis, spontaneous intracranial hypotension, acute hypertensive crises, colloid cysts of the third ventricle, retroclival haematoma, reversible vaso-

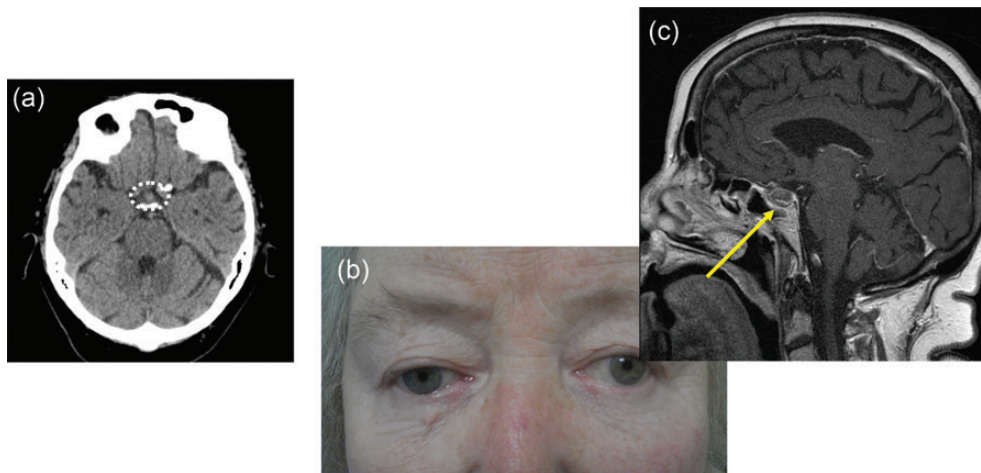


Figure 1. Clinical signs and imaging findings. (a) CT brain: no subarachnoid blood, but closer review revealed a subtle hyperdensity in the pituitary fossa; (b) Third nerve palsy: ptosis, miosis, inferolateral eye deviation; (c) MRI brain: pituitary adenoma.

constriction syndrome, and even ischaemic stroke (most commonly posterior circulation, large artery stroke) [1, 2]. A number of primary headache disorders also exist, e.g. primary thunderclap headache, cough, exertional and coital headaches, but secondary ‘organic’ causes should be excluded first [1]. Clinical features such as precipitants, postural exacerbation, lateralisation, and neurological deficit may aid in differentiating the cause. A recent retrospective autopsy review suggests that older age, collapse and ‘worst-ever’ character may be ‘red flags’ indicating a life-threatening aetiology [3]. Furthermore, the value of CT extends beyond identification of blood. While scan requests for patients with sudden violent headache probably often read ‘query subarachnoid haemorrhage?’, imaging may elucidate alternative diagnoses, and should be examined bearing this in mind.

Pituitary apoplexy is a syndrome comprising sudden headache, meningism, and visual and/or oculomotor deficits, associated with an intrasellar mass [4–6]. The symptomatology closely mirrors that of subarachnoid haemorrhage. Oculomotor deficits most often involve third and sixth cranial nerves [4–9]. Other causes of sudden simultaneous field deficits and oculomotor palsy, e.g. trauma or ischaemic neuropathy, are rare.

Pituitary apoplexy commonly occurs due to haemorrhage or extensive infarction within a pituitary adenoma, although the adenoma is often previously undiagnosed [4–6]. Two in three patients presenting with pituitary apoplexy will have been unaware they had a pituitary tumour [4].

Approximately 10% of intracranial tumours are pituitary [4]. It is thought that these may be more likely to bleed than other neoplasms, e.g. gliomas, with an incidence of haemorrhage within pituitary adenomas in the order of 0.6–10.5% [4, 5]. However, not all pituitary tumour haemorrhages will result in pituitary apoplexy [4]. Endocrine abnormalities may occur as a result of the adenoma itself, or in the context of haemorrhage/infarction therein. Diagnosis is confirmed by imaging, with MRI the modality of choice; CT is diagnostic in only about a quarter of cases [6]. Lumbar puncture, which

often reveals a raised red cell count, cannot reliably distinguish it from subarachnoid haemorrhage [4].

Treatment requires prompt initiation of steroid therapy in the first instance, with monitoring of fluid/electrolyte balance and surveillance for emerging endocrine dysfunction (hypopituitarism, diabetes insipidus or SIADH) [4, 5, 7, 8]. Early surgical decompression should be considered; while there are no stringent criteria for the selection of surgical candidates, those with severe cranial neuropathy, drowsiness or progressive deterioration warrant urgent surgical decompression [4, 5]. The condition can be fatal, even with treatment.

Conclusion

While subarachnoid haemorrhage is an important and well-recognised cause of sudden severe headache, other aetiologies should be considered and sought. Pituitary apoplexy is an important differential diagnosis in patients with acute headache, meningeal irritation and visuo-oculomotor deficits. It necessitates prompt recognition and treatment.

Key points

- Pituitary apoplexy, as in our patient, is characterised by sudden headache, meningism, visual and/or oculomotor deficits, associated with an intrasellar mass.
- It is commonly due to haemorrhage or infarction within a pituitary adenoma.
- Treatment includes prompt steroid administration, and potentially surgical decompression.
- While subarachnoid haemorrhage is an important cause of sudden severe headache, other aetiologies should be considered and sought.
- Pituitary apoplexy should be considered in patients presenting with this symptom complex.

Conflicts of interest

None declared.

References

1. Ferrante E, Tassorelli C, Rossi P, Lisotto C, Nappi G. Focus on the management of thunderclap headache: from nosogargy to treatment. *J Headache Pain* 2011; 12: 251–8.
2. Ferro JM, Melo TP, Oliveira V *et al.* A multivariate study of headache associated with ischemic stroke. *Headache* 1995; 35: 315–9.
3. Lynch KM, Brett F. Headaches that kill: a retrospective study of incidence, etiology and clinical features in cases of sudden death. *Cephalalgia* 2012; 32: 972–8.
4. Cardoso ER, Peterson EW. Pituitary apoplexy: a review. *Neurosurg* 1984; 14: 363–73.
5. Woo HJ, Hwang JH, Hwang SK, Park YM. Clinical outcome of cranial neuropathy in patients with pituitary apoplexy. *J Korean Neurosurg Soc* 2010; 48: 213–8.
6. Rajasekaran S, Vanderpump M, Baldeweg S *et al.* UK Guidelines for the management of pituitary apoplexy. *Clin Endocrinol* 2011; 74: 9–20.
7. Komurcu HF, Ayberk G, Ozveren MF, Anlar O. Pituitary adenoma apoplexy presenting with bilateral third nerve palsy and bilateral proptosis: a case report. *Med Princ Pract* 2012; 21: 285–7.
8. Matti AI, Rudkin AK, Lee AW, Chen CS. Isolated unilateral abducens cranial nerve palsy: a rare presentation of pituitary apoplexy. *Eur J Ophthalmol* 2010; 20: 234–6.
9. Diyora B, Nayak N, Kukreja S, Kamble H. Sudden onset isolated complete third nerve palsy due to pituitary apoplexy. *Oman J Ophthalmol* 2011; 4: 32–4.

Received 22 December 2012; accepted in revised form 1 May 2013

Age and Ageing 2013; 42: 812–814
doi: 10.1093/ageing/afz090
Published electronically 4 August 2013

© The Author 2013. Published by Oxford University Press on behalf of the British Geriatrics Society.
All rights reserved. For Permissions, please email: journals.permissions@oup.com

Inoperable isolated cardiac hydatid cyst controlled with albendazole in an older adult with dementia

MEHMET EMIN KUYUMCU¹, YUSUF YEŞİL¹, SEZGIN ETGÜL², BURÇIN HALAÇLI², HAMZA SUNMAN³, BURCU BALAM YAVUZ¹, TUNCAY HAZIROLAN⁴, MELTEM HALİL¹, MUSTAFA CANKURTARAN¹, SERVET ARIOĞUL¹

¹Division of Geriatric Medicine, Department of Internal Medicine, Faculty of Medicine, Hacettepe University, 06100 Sıhhiye, Ankara, Turkey

²Department of Internal Medicine, Faculty of Medicine, Hacettepe University, Ankara, Turkey

³Department of Cardiology, Faculty of Medicine, Hacettepe University, Ankara, Turkey

⁴Department of Radiology, Faculty of Medicine, Hacettepe University, Ankara, Turkey

Address correspondence to: M. E. Kuyumcu. Tel: (+90) 3123051538; Fax: (+90) 3123097620. Email: mekuyumcu@gmail.com

Abstract

Hydatid cyst, a human parasitic disease, remains a clinical problem in undeveloped and developing countries. Although liver and lungs are regular sites of infection, rarely other organs such as the heart can be involved. Herein, we report an isolated cardiac hydatid cyst in an 87-year-old man. He had a history of dementia for 5 years and no history for cardiac or pulmonary disease. He presented with exertional dyspnoea which continued up to 6 months. The diagnosis was made by echocardiography and computed tomography (CT). The patient was inoperable and was treated with albendazole 10 mg/kg for 6 months. After a 6-month follow-up, echocardiography revealed reduction in the size of the cyst. We believe this is the first documented case of cardiac hydatid cyst which regressed with only medical treatment in an older adult with dementia.

Keywords: elderly, hydatid cyst, cardiac, cardiac hydatid cyst, albendazole, older people, parasitic, geriatric, inoperable, dementia