

# Resolution of Diminished Olfactory Sensation After Treatment of Bilateral Ophthalmic Segment Aneurysms With Flow Diversion: Case Report

Prashant S. Kelkar, DO\*§  
 Mohamad R. Chaaban, MD‡  
 Beverly C. Walters, MD, MSc\*§  
 Bradford A. Woodworth, MD‡  
 John P. Deveikis, MD\*  
 Mark R. Harrigan, MD\*

\*Department of Neurosurgery, ‡Department of Surgery, Division of Otolaryngology, University of Alabama, Birmingham, Alabama; §Department of Surgery, Division of Neurosurgery, St. John Providence Health System, Southfield, Michigan

## Correspondence:

Mark R. Harrigan, MD,  
 Department of Neurosurgery,  
 1530 3rd Avenue South,  
 Birmingham, AL.  
 E-mail: mharrigan@uabmc.edu

Received, February 15, 2013.

Accepted, July 31, 2013.

Published Online, October 30, 2013.

**BACKGROUND AND IMPORTANCE:** Olfactory tract dysfunction due to an unruptured intracranial aneurysm is rare. We present a case in which a patient with impaired olfaction related to bilateral internal carotid artery aneurysms experienced subjective and quantitative objective improvement of olfactory sensation after treatment of ophthalmic segment aneurysms with flow diversion.

**CLINICAL PRESENTATION:** A 44-year-old woman presented with hyposmia and bilateral ophthalmic segment internal carotid artery aneurysms. The symptom of hyposmia, worsening over a period of several months, was suspected to be due to mass effect from bilateral unruptured ophthalmic segment aneurysms pressing on the olfactory tracts. Each aneurysm was treated with a Pipeline embolization device (PED). Follow-up angiography at 5 months showed occlusion of both aneurysms. The patient experienced subjective improvement in olfaction and complete objective resolution of her hyposmia as measured by the validated University of Pennsylvania Smell Identification Test (UPSIT).

**CONCLUSION:** Intracranial aneurysms causing dysfunction of olfactory sensation due to mass effect upon the olfactory tract can be successfully treated with flow diversion. Flow diversion should be considered as one of the treatment options for patients with cranial nerve dysfunction due to unruptured intracranial aneurysms.

**KEY WORDS:** Aneurysm, Anosmia, Olfactory tract, Pipeline embolization device

Neurosurgery 74:E226–E229, 2014

DOI: 10.1227/NEU.0000000000000127

www.neurosurgery-online.com

Copyright © 2013 by the  
 Congress of Neurological Surgeons

Cranial nerve dysfunctions due to unruptured intracranial aneurysms are relatively common; olfactory tract dysfunction due to intracranial aneurysms, however, is rare. We describe a case of a patient with hyposmia due to bilateral ophthalmic segment internal carotid artery aneurysms who was successfully treated with flow diversion.

## Clinical Presentation

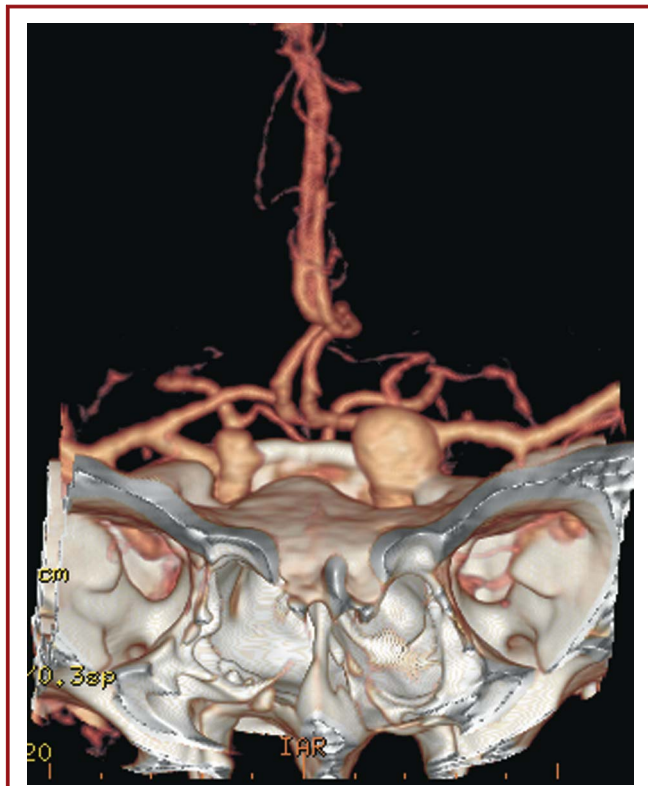
A 44-year-old woman was referred with a diagnosis of bilateral unruptured ophthalmic segment internal carotid artery aneurysms. The patient had experienced subjective symptoms of blurred vision, double vision, and diminished sensations of taste and smell for 8 months prior to being evaluated. Investigation at an outside institution included a computed tomographic angiogram (CTA) of the brain that confirmed bilateral ophthalmic segment aneurysms (Figure 1). Further imaging, including axial (Figure 2A) and coronal

(Figure 2B) T1-weighted magnetic resonance imaging with gadolinium, demonstrated mass effect upon the basal frontal lobes and olfactory tract by the dome of the larger 1-cm, left-sided ophthalmic segment aneurysm OSA with minimal edema seen on the axial (Figure 2C) T2 fluid attenuated inversion recovery image.

After consideration of several treatment options, including surgical clipping, coil embolization, and flow diversion, it was felt that the optimal strategy to obtain thrombosis and involution of the aneurysms would be flow diversion with Pipeline embolization devices (eV3). Prior to treatment, quantitative assessment of olfactory sensation with the University of Pennsylvania Smell Identification Test (UPSIT) was done; the score was 26/40, indicating moderate hyposmia.

## Endovascular Procedure

The patient was given aspirin (325 mg) and clopidogrel (75 mg) for 5 days prior to the



**FIGURE 1.** Three-dimensional computed tomographic angiogram showing mirror ophthalmic segment aneurysms (OSA).

procedure. Platelet aggregation testing demonstrated adequate platelet inhibition by both medications. The procedure was done under general anesthesia. A Neuron 070 guide catheter (eV3) was placed in the proximal petrous segment of the internal carotid artery and an angiogram was done. A Marksman microcatheter (eV3) was advanced under roadmap guidance and positioned in the middle cerebral artery. A 4 mm × 18 mm PED was deployed in the internal carotid artery across the neck of the aneurysm. Final angiograms showed good positioning of the PED with contrast stasis within the aneurysm dome (Figure 3). The patient awakened from general anesthesia at her neurological baseline.

One month following Pipeline embolization of her symptomatic left ophthalmic aneurysm, the patient underwent Pipeline embolization of the smaller (7 mm) right ophthalmic segment ICA aneurysm. The same technique and device size used for the left sided lesion were employed for the right side, and the procedure was uncomplicated.

### Clinical and Angiographic Follow-up

In May 2012, the patient returned for a follow-up appointment and reported that her sense of smell and taste had improved over the months following her treatment. A 5-month follow-up cerebral angiogram showed complete occlusion of both aneurysms

(Figure 4). Incidental treatment-related asymptomatic stenosis was also noted within the proximal parts of both devices (49% on the right and 47% on the left). During this visit the patient underwent repeat quantitative olfaction assessment with the UPSIT and was found to have an improved score (30/40), but was still within the range of moderate hyposmia. Another follow-up angiogram done 6 months later showed no change in the stenosis on the right and improvement on the left to 33%. A final UPSIT done 11 months after the initial endovascular procedure showed an improved score of 35/40, indicating normal olfaction. The patient's subjective improvements in olfactory sensation correlated with the radiographic occlusion of her bilateral ophthalmic segment aneurysms, and her final objective testing showed a greater than 1 standard deviation improvement from moderate hyposmia to normal smell sensation.

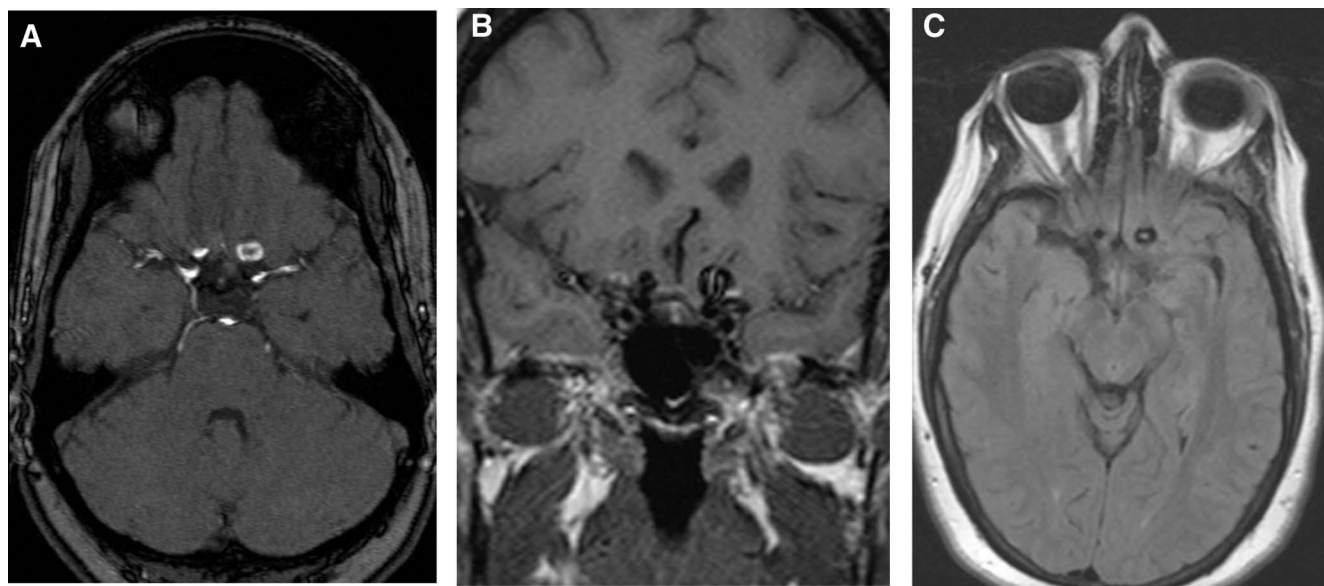
## DISCUSSION

Flow diversion is a relatively new technique for the treatment of intracranial aneurysms, and holds promise as the least invasive method to reduce mass effect of intracranial aneurysms causing cranial nerve dysfunction. Insertion of a flow diverter results in disruption of blood inflow and outflow of the aneurysm and alters the vector of blood flow within the parent vessel lumen.<sup>1</sup> This results in immediate reduction of pulsation upon the affected cranial nerve. Over time, after placement of the device, the aneurysm typically undergoes progressive thrombosis and occlusion. After endothelialization of the device has occurred, the parent vessel has been remodeled and the intra-aneurysmal thrombus resorbs and involutes.<sup>1</sup>

Several case series have shown resolution or improvement of symptomatic cranial nerve dysfunction after treatment with either clipping or coiling.<sup>2-10</sup> While most reports concern third nerve palsy due to posterior communicating artery aneurysms, the same principles have been seen with and applied to aneurysms causing various other cranial nerve palsies.<sup>5,6</sup> Only 1 previous case of anosmia due to aneurysmal mass effect has been reported, and this was from an anterior communicating artery aneurysm.<sup>11</sup>

The University of Pennsylvania Smell Identification Test (UPSIT) consists of 40 different "scratch and sniff" odors and is a quick self-administered test in which the patient is asked to match the odorant with the correct answer in a multiple-choice format. The total number of correct items is added and the sum is compared to subjects matched for age and sex.<sup>12</sup> Test results may be classified as either normal, hyposmic (mild, moderate or severe), anosmic or suggestive of malingering. The test-retest reliability of the UPSIT exceeds 0.9,<sup>12-15</sup> and the test score correlates with other lengthy olfactory tests including the traditional olfaction detection threshold test which uses phenyl-ethyl-alcohol.<sup>15,16</sup>

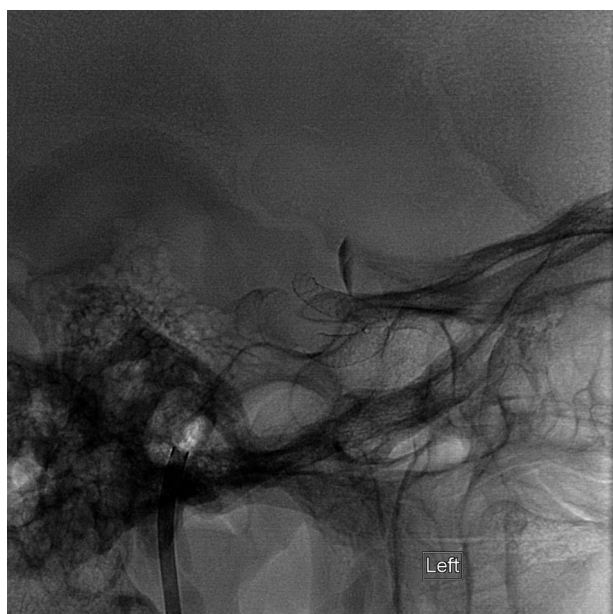
Possible mechanisms of improvement of cranial neuropathy with treatment of aneurysms include reduction of direct mass effect upon the nerve, reduction of the inflammatory process causing neuropathy, and diminution of the pulsations causing a water-hammer effect upon the nerve.<sup>2-4,7,8,17</sup> Advocates of surgical



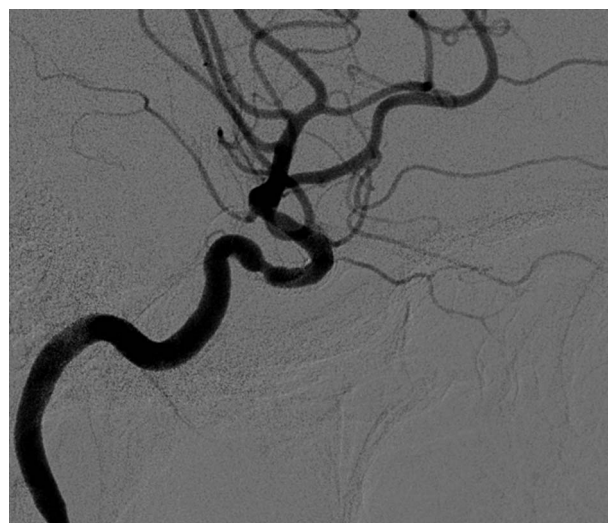**FIGURE 2.** Axial (A) and coronal (B) T1 weighted magnetic resonance imaging with gadolinium demonstrating mass effect upon basal frontal lobe/olfactory tract by the dome of the larger left sided ophthalmic segment aneurysm. Axial fluid attenuated inversion recovery image (C) shows the left and right aneurysms with minimal, if any, signal change to indicate edema.

decompression argue that aneurysm embolization with coils or liquid embolic agents cannot provide mechanical decompression of the injured nerve and is therefore an inferior option.<sup>18</sup> However,

a water-hammer effect of arterial pulsation appears to be a factor in cranial nerve dysfunction in this setting, and can be reduced with embolization of the aneurysm.<sup>2</sup> Endovascular treatment may be advantageous over surgery in that it does not carry a risk of nerve injury from manipulation of the compromised nerve and artery.



**FIGURE 3.** Unsubtracted lateral angiogram, the Pipeline embolization device is seen and contrast stasis is noted within the aneurysm.



**FIGURE 4.** Five-month follow-up left lateral digital subtraction angiography showing occlusion of the ophthalmic segment aneurysm from the normal circulation. Asymptomatic proximal in-stent stenosis is noted.



Endovascular treatment with flow diversion is very promising technology that offers the purported advantages of both open surgery and coil embolization. The immediate effect of flow diversion is an alteration in intra-aneurysmal flow dynamics and a reduction in the intensity of pulsations. As the stent undergoes endothelialization and complete thrombosis of the aneurysm occurs, the subsequent resorption of the organized thrombus and involution of the aneurysm dome produces a direct decompression of the injured nerve.

## CONCLUSION

To our knowledge, this is the second report of hyposmia due to an unruptured intracranial aneurysm, the first case of this finding due to bilateral ophthalmic artery aneurysms, and the first case report of flow diversion with a flow diverter resulting in subjective and objective improvement in olfaction. Flow diversion should be considered a routine part of the treatment algorithm for patients with cranial nerve dysfunction due to unruptured intracranial aneurysms.

## Disclosures

Bradford A. Woodworth, MD, Consultant for ArthroCare ENT, Gyrus, and Cook Medical. The other authors have no personal financial or institutional interest in any of the drugs, materials, or devices described in this article.

## REFERENCES

1. Fiorella D, Lylyk P, Szikora I, et al. Curative cerebrovascular reconstruction with the Pipeline embolization device: the emergence of definitive endovascular therapy for intracranial aneurysms. *J Neurointerv Surg*. 2009;1(1):56-65.
2. Birchall D, Khangure MS, McAuliffe W. Resolution of third nerve paresis after endovascular management of aneurysms of the posterior communicating artery. *AJNR Am J Neuroradiol*. 1999;20(3):411-413.
3. Rodriguez-Catarino M, Frisen L, Wikholm G, Elfverson J, Quiding L, Svendsen P. Internal carotid artery aneurysms, cranial nerve dysfunction and headache: the role of deformation and pulsation. *Neuroradiology*. 2003;45(4):236-240.
4. Santillan A, Zink WE, Knopman J, Riina HA, Gobin YP. Early endovascular management of oculomotor nerve palsy associated with posterior communicating artery aneurysms. *Interv Neuroradiol*. 2010;16(1):17-21.
5. Halbach VV, Higashida RT, Dowd CF, et al. The efficacy of endosaccular aneurysm occlusion in alleviating neurological deficits produced by mass effect. *J Neurosurg*. 1994;80(4):659-666.
6. Malisch TW, Guglielmi G, Vinuela F, et al. Unruptured aneurysms presenting with mass effect symptoms: response to endosaccular treatment with Guglielmi detachable coils. Part I. Symptoms of cranial nerve dysfunction. *J Neurosurg*. 1998;89(6):956-961.
7. Panagiotopoulos V, Ladd SC, Gizewski E, et al. Recovery of ophthalmoplegia after endovascular treatment of intracranial aneurysms. *AJNR Am J Neuroradiol*. 2011;32(2):276-282.
8. Inamasu J, Nakamura Y, Saito R, Kuroshima Y, Ohba S, Ichikizaki K. Early resolution of third nerve palsy following endovascular treatment of a posterior communicating artery aneurysm. *J Neuroophthalmol*. 2002;22(1):12-14.
9. Feely M, Kapoor S. Third nerve palsy due to posterior communicating artery aneurysm: the importance of early surgery. *J Neurol Neurosurg Psychiatry*. 1987;50(8):1051-1052.
10. Ahn JY, Han IB, Yoon PH, et al. Clipping vs coiling of posterior communicating artery aneurysms with third nerve palsy. *Neurology*. 2006;66(1):121-123.
11. Manconi M, Paolino E, Casetta I, Granieri E. Anosmia in a giant anterior communicating artery aneurysm. *Arch Neurol*. 2001;58(9):1474-1475.
12. Doty RL, Frye RE, Agrawal U. Internal consistency reliability of the fractionated and whole University of Pennsylvania Smell Identification Test. *Percept Psychophys*. 1989;45(5):381-384.
13. Doty RL, McKeown DA, Lee WW, Shaman P. A study of the test-retest reliability of ten olfactory tests. *Chem Senses*. 1995;20(6):645-656.
14. Doty RL, Gregor T, Monroe C. Quantitative assessment of olfactory function in an industrial setting. *J Occup Med*. 1986;28(6):457-460.
15. Doty RL, Shaman P, Applebaum SL, Giberson R, Siksorski L, Rosenberg L. Smell identification ability: changes with age. *Science*. 1984;226(4681):1441-1443.
16. Doty RL. Studies of human olfaction from the University of Pennsylvania Smell and Taste Center. *Chem Senses*. 1997;22(5):565-586.
17. Scholtes F, Martin D. Strategical implications of aneurysmal cranial nerve compression. *Neurochirurgie*. 2012;58(2-3):146-150.
18. Yanaka K, Matsumaru Y, Mashiko R, Hyodo A, Sugimoto K, Nose T. Small unruptured cerebral aneurysms presenting with oculomotor nerve palsy. *Neurosurgery*. 2003;52(3):553-557; discussion 556-557.