

Cortical Deafness: A Case Report and Review of the Literature

*Robert M. Brody, *Brian D. Nicholas, †Michael J. Wolf,
*Paula B. Marcinkevich, and *Gregory J. Artz

*Departments of *Otolaryngology and †Radiology, Thomas Jefferson University Hospital, Philadelphia, Pennsylvania, U.S.A.*

Objective: To review the literature regarding cortical hearing loss and document a case of cortical hearing loss including its presentation, diagnosis, and evolution over 32 months of follow-up.

Patient: A 56-year-old woman with profound bilateral sensorineural hearing loss secondary to sequential hemorrhagic, temporal lobe infarctions separated in time by 8 months.

Intervention: Diagnostic.

Results: Sequential infarctions affecting the patient's auditory radiations and primary auditory cortices bilaterally combined to cause cortical hearing loss. At presentation, audiogram revealed a bilateral profound sensorineural hearing loss with no reliable responses to pure-tone or speech audiometry. She has subsequently recovered the ability to distinguish environmental sounds. At her

32-month follow-up, she had a pure-tone average (PTA) of 62 dB on the right and 70 dB on the left but continued to display a poor word recognition score (0%). A literature review was performed from the year 1891 until the present.

Conclusion: Cortical deafness is an exceedingly rare entity. Presentation and recovery of hearing are dependent on the extent of the initial lesions. The majority of patients can expect improvements in pure-tone auditory thresholds over time; however patients should be counseled that recovery of the ability to understand speech is unlikely. **Key Words:** Auditory testing—Cortical deafness—Central deafness—Functional magnetic resonance imaging—Stroke.

Otol Neurotol 34:1226–1229, 2013.

Cortical deafness is a rare complication of stroke. Early reports, published in the late 19th century, describe patients with acute onset of deafness after experiencing symptoms described as apoplexy. The only means of definitive diagnosis in these reports were postmortem dissections (1–8). Subsequent cases throughout the 20th century reflect advancements in diagnoses of both hearing loss and stroke. With the advent of audiometric and electrophysiologic studies, investigators could diagnose cortical deafness with increasing precision. Advances in imaging techniques greatly improved the diagnosis and localization of cerebral infarcts that coincide with primary or secondary auditory centers. Neurologic and cognitive testing help to distinguish between total cortical deafness or an auditory variant of agnosia resulting in the inability to perceive words, music, or specific environmental sounds (9–18).

Sensorineural hearing loss (SNHL) occurs at many different levels, from the inner ear to the cerebral cortex. The overwhelming majority of SNHL results from insults to the cochlea or cochlear nerve. Afferent signals are transmitted from the cochlea to the ipsilateral and contralateral auditory cortices by way of brainstem nuclei and tracts. An incomplete decussation occurs in the brainstem at the trapezoid body, dictating that insults to cortical auditory processing must be bilateral to produce persistent symptomatic hearing loss. These bilateral insults occur most often after embolic stroke or intraparenchymal hemorrhage leading to infarction.

The typical presentation of cortical hearing loss involves a history of unilateral infarction in the region of the temporal lobe that leads to deficits such as hemiparesis, dysphagia, and aphasia without hearing loss (12,16,18). A subsequent contralateral stroke then results in bilateral profound sensorineural hearing loss. An initial insult to the nondominant cortex is likely to remain asymptomatic and subclinical because of contralateral afferent fibers and a functioning contralateral primary auditory cortex. Only 1 case has described simultaneous insults causing immediate deafness (19).

Address correspondence and reprint requests to Gregory J. Artz, M.D., Thomas Jefferson University Hospital, Department of Otolaryngology–Head and Neck Surgery, 925 Chestnut St, 6th Floor Philadelphia, PA 19107; E-mail: Gregory.Artz@jefferson.edu

The authors disclose no conflicts of interest.

Financial Disclosures: none.

When a patient presents with sudden bilateral hearing loss, it is important to perform a comprehensive examination. This includes the physical exam, pure-tone audiograms (PTAs), otoacoustic emissions (OAEs), acoustic reflex testing, and auditory brainstem responses (ABRs). Patients with cortical hearing loss will display normal OAEs, suggesting intact outer hair cell function. They will have normal early latency response waveforms, suggesting that the cochlear nerve and brainstem are functioning. In patients who are found to have poor thresholds on pure-tone audiometry with intact OAEs and early latency response ABR, middle latency responses (MLRs) and late responses or cortical evoked response audiometry (CERA) can provide insight into the site of the cortical pathology. MLR and CERA are rarely performed at our institution. Magnetic resonance imaging (MRI) can identify the specific regions of the brain affected by pathologic processes.

CLINICAL PRESENTATION

The patient is a 56-year-old woman with a history of hypertension, hypercholesterolemia, and multiple cerebrovascular accident (CVA) who presented in March of 2009 with a complaint of complete bilateral hearing loss.

In July 2008, she presented with right-sided hemiparesis and slurred speech. Imaging revealed a posterior putaminal hemorrhage involving the left lateral thalamus, globus pallidus, as well as portions of the internal, external, and extreme capsules. The adjacent temporal and insular cortex seemed spared. The patient was transferred to a rehabilitation facility, and her right-sided hemiparesis subsequently resolved. At that time, there were no complaints of hearing loss or any concerns by family members (Figs. 1A and B).

In March 2009, she experienced an acute right-sided insulotemporal intracerebral hemorrhage. Immediately after this event, the patient complained of hearing loss with the inability to hear all sounds except for severe bilateral tinnitus. Imaging revealed sequelae in the left cerebral cortex from her previous CVA. The new right-sided hemorrhage was centered on the posterior putamen with surrounding edema involving the posterior portion of the posterior limbs of the internal, external, and extreme capsules. Signal abnormalities extended into the right temporal lobe. The patient had no other neurologic deficits and spoke fluently, although with poor internal volume control of her voice. Otoloscopic examination revealed normal-appearing external auditory canals, intact tympanic membranes bilaterally, and normal middle ear anatomy. Audiogram at that time showed bilateral profound hearing loss with no responses to pure-tone or speech testing. Valid and reliable responses were obtained with both transient evoked otoacoustic emissions (TEOAE) and distortion product otoacoustic emissions (DPOAEs) (Figs. 2 and 3).

There were no verbal responses to the consonant-nucleus-consonant (CNC) test at a presentation level of 75 dB or to the hearing in noise test (HINT), even in a quiet environment at a presentation level of 70 dB). Although no speech was detected, she did have the ability to hear faint sounds during the HINT testing. The patient had symmetric responses on caloric testing and normal early latency waveform ABR. She was diagnosed with a cortical hearing loss.

Cochlear implantation and auditory brainstem implantation were discussed. With a diagnosis of cortical deafness and normal brainstem and peripheral auditory

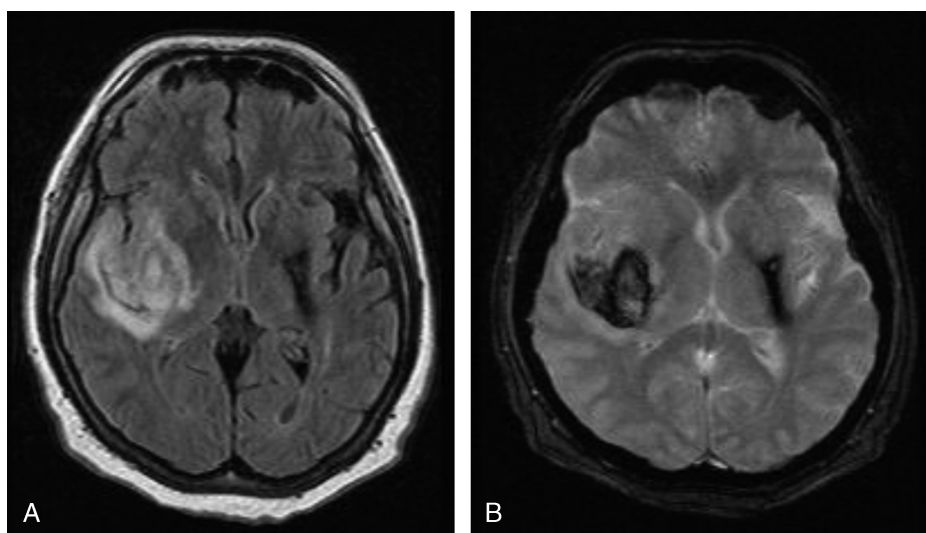


FIG. 1. A, Fluid attenuated inversion recovery (FLAIR) and B, Gradient-echo (GRE) magnetic resonance images obtained in 2009 after second cerebral hemorrhage. Residual hemosiderin and associated encephalomalacia is seen in the medial aspect of the left temporal lobe and associated structures. The new hemorrhage and cerebral edema is seen in the medial aspect of the right temporal lobe, posterior putamen, and posterior limbs of the internal and external capsules carrying ascending and descending axons from the brainstem to the cerebral cortices.

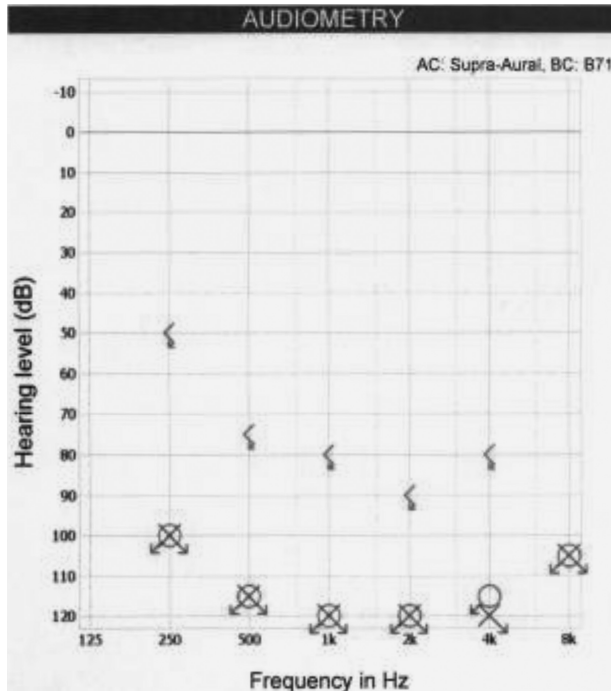


FIG. 2. Pure tone audiometry 1 month after a right cerebrovascular accident, resulting in bilateral, profound sudden cortical hearing loss. Speech discrimination was 0% bilaterally.

function, it was determined that a cochlear implant would not provide her with any benefit.

By January 2010, the patient began to perceive high-pitched loud sounds. Her audiogram showed bilateral profound hearing loss with reliable responses to pure tones—a change from her previous audiograms. Word recognition scores remained poor at 0%. In December 2010, she noted further improvement in distinguishing sounds, particularly music. She failed to display any improvements in speech discrimination; however, she had learned to lip-read and text message proficiently. On the right, her PTA was 75 dB HL, and on the left, her PTA was 88 dB HL. Although thresholds had become lower, her discrimination

with speech audiometry again remained at 0%; 32 months after her the second (right) cortical injury, the patient again noted she could hear noises consistently, on the left better than the right. On PTA, she again displayed marginal improvement, although her word recognition score remained at 0% (Fig. 4).

Almost 3 years after her last cerebrovascular accident, she had adjusted well to her hearing disability and acquired excellent lip-reading skills.

DISCUSSION

Cortical hearing loss is an exceedingly rare diagnosis. Bilateral damage must occur in central auditory processing centers to result in cortical deafness; however, the specific lesions and presentations vary considerably. We speculate that the damage to the left basal ganglion region caused an occult disconnection of the patient’s left temporal lobe from its associated auditory radiations. Afferent auditory signals were intact below the thalamus, and the patient displayed no aphasic symptoms. Therefore, left-sided processing of the bilateral auditory stimuli may have continued unimpeded because of a presumed cross-over of auditory information through the corpus callosum. Subsequent damage to the right insulotemporal region resulted in profound hearing loss, presumably because of a loss of bilateral afferent information reaching both left and right auditory cortices.

In reviewing the literature, the initial presentation and extent of cerebral damage correlates with prognosis. If the insult is reversible, such as with cerebral vasospasm, the patient may expect a complete recovery (20). Patients presenting with cortical hearing loss and no other associated symptoms recover to a variable degree, depending on the size and type of the cerebral lesion (6–9,13–15,17–19,22). Many patients have a persistent word deafness, although they often recover the ability to distinguish environmental sounds and musical tonality, as our patient did. Patients whose symptoms include both motor deficits and aphasia often have larger lesions with an associated poorer prognosis in regard to functional status and recovery (1,3,4,5,10,16).

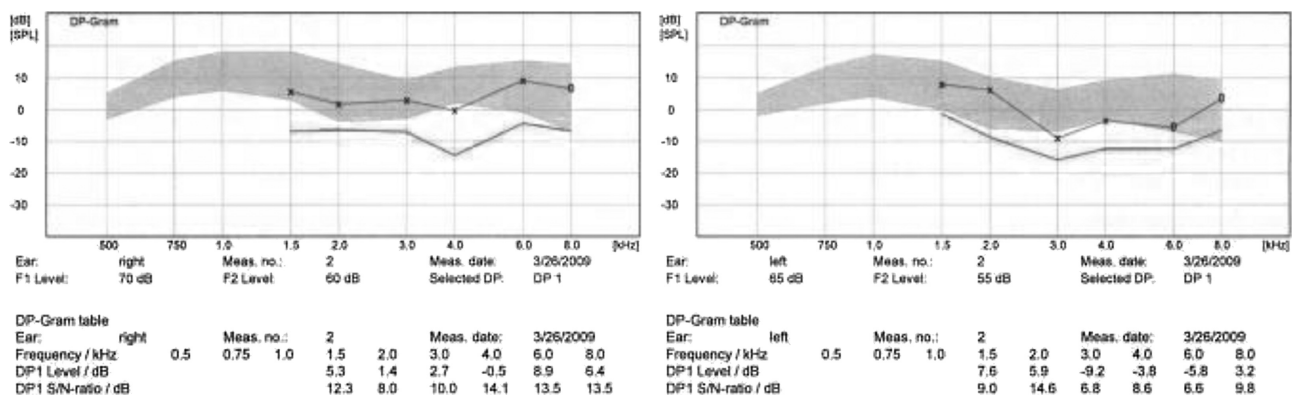


FIG. 3. Normal distortion product otoacoustic emissions (DPOAEs) at 1 month.

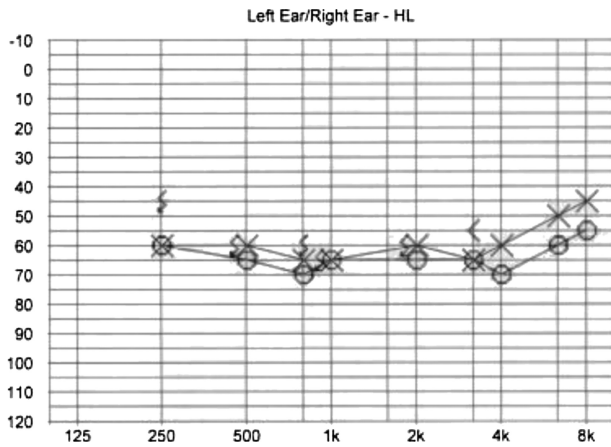


FIG. 4. Pure tone audiometry 32 months shows an improvement in pure tone audiometry bilaterally. Speech discrimination scores remained at 0% bilaterally. On pure tone audiometry, the patient displays marginal improvement, with a PTA on the left of 65 dB HL and a PTA on the right of 62 dB HL. Functional hearing to speech remained poor, as her word recognition score remained at 0%.

Patients with both hearing loss and aphasia but without motor deficits have intermediate prognoses for recovery (2,11,12,21). Certain reports implicate damage to auditory radiations as the cause of cortical deafness (22). Others implicate gray matter damage after measuring metabolic activity in the cortex using positron emission tomography (PET) (16). Combined damage to both auditory radiations and auditory cortices likely creates the varied constellation of symptoms seen in the literature.

Cochlear or auditory brainstem implantation could be a treatment option. Electrical stimulation of the peripheral auditory system may result in improved sound perception or cortical remapping in patients with cortical deafness. We elected not to pursue these surgical options. Patients should be directed toward resources to aid them in lip-reading, learning American Sign Language, as well as speech and occupational therapy. Patients should follow-up regularly to evaluate for any long-term recovery.

This rare case gives further insight into the evolution of cortical deafness. In 32 months, the patient made a considerable recovery from her initial state of profound deafness with severe tinnitus. There seems to be a level of neuroplasticity that allowed the patient to recover the ability to perceive environmental and certain musical sounds. In addition, her recovery has correlated with a decrease in tinnitus—perhaps further supporting the theory of a cortical origin of tinnitus. Despite marginal improvements in sound awareness, even at 32 months after the onset of hearing loss, the patient's word recognition remains poor. The complex architecture of the

brain involved with recognition and perception of speech may be irreversibly damaged. The majority of patients can expect improvements in pure-tone auditory thresholds over time; however, patients should be counseled that recovery of the ability to distinguish speech is unlikely.

REFERENCES

1. Wernicke C, Friedlander C. Ein Fall von Taubheit in Folge von doppelseitiger Läsionen des Schläfenlappens. *Fortschritte der Medizin* 1883;1:177–85.
2. Pick A. Beiträge zur Lehre von den Störungen der Sprache. *Arch Psychiat Nervkrankh* 1898;23:896–918.
3. Mills C. On the localization of the auditory centre. *Brain* 1891;14:465–72.
4. Mott FW. Bilateral lesion of the auditory cortical centre: complete deafness and aphasia. *Br Med J* 1907;2:310–5.
5. Misch W. Über corticale Taubheit. *Z ges Neurol Psychiat* 1928:567–73.
6. Bramwell E. A case of cortical deafness. *Brain* 1927;579–80.
7. Clark WLG, Russel W. Cortical deafness without aphasia. *Brain* 1938;61:375–83.
8. Chavany J. Un cas de surdit  d'origine corticale. *Presse m d* 472.
9. Jerger J, Weikers NJ, Sharbrough FW, Jerger S. Bilateral lesions of the temporal lobe. *Acta Otolaryngol Suppl* 1969;258:1–51.
10. Goldstein MN, Brown M, Hollander J. Auditory agnosia and cortical deafness: analysis of a case with three-year followup. *Brain Lang* 1975;2:324–32.
11. Eamest MP, Monroe PA, Yamell PR. Cortical deafness: demonstration of the pathologic anatomy by CT scan. *Neurology* 1977;27:1172–5.
12. Graham J, Greenwood R, Lecky B. Cortical deafness—a case report and review of the literature. *J Neurol Sci* 1980;48:35–49.
13. Ozdamar O, Kraus N, Curry F. Auditory brain stem and middle latency responses in a patient with cortical deafness. *Electroencephalogr Clin Neurophysiol* 1982;53:224–30.
14. Woods DL, Knight RT, Neville HJ. Bitemporal lesions dissociate auditory evoked potentials and perception. *Electroencephalogr Clin Neurophysiol* 1984;57:208–20.
15. Bahls FH, Chatrian GE, Mesher RA, Sumi SM, Ruff RL. A case of persistent cortical deafness: clinical, neurophysiologic, and neuropathologic observations. *Neurology* 1988;38:1490–3.
16. Engelen A, Silbersweig D, Stern E, et al. The functional anatomy of recovery from auditory agnosia. A PET study of sound categorization in a neurological patient and normal controls. *Brain* 1995;118(Pt 6):1395–1409.
17. Leussink V, Andermann P, Reiners K, et al. Sudden deafness from stroke. *Neurology* 2005;64:1817–8.
18. Zöllner C, Karnahl T, Pedersen P. ERA-Befunde bei ‘‘kortikaler Schwerhörigkeit’’. *Arch Otorhinolaryngol* 1977;217:451–61.
19. Musiek FE, Baran JA, Shinn JB, et al. Central deafness: an audiological case study. *Int J Audiol* 2007;46:433–41.
20. Tabuchi S, Kadowaki M, Watanabe T. Reversible cortical auditory dysfunction caused by cerebral vasospasm after ruptured aneurysmal subarachnoid hemorrhage and evaluated by perfusion magnetic resonance imaging. Case report. *J Neurosurg* 2007;107:161–4.
21. Leicester J. Central deafness and subcortical motor aphasia. *Brain Lang* 1980;10:224–42.
22. Tanaka Y, Kamo T, Yoshida M, Yamadori A. ‘‘So-called’’ cortical deafness. Clinical, neurophysiological and radiological observations. *Brain* 1991;114(Pt 6):2385–2401.