

4. Dayan MR, Elston JS, McDonald B. Bilateral lymphomatous optic neuropathy diagnosed on optic nerve biopsy. *Arch Ophthalmol* 2000;**118**: 1455–7.
5. Behbehani RS, Vacarezza N, Sergott RC, et al. Isolated optic nerve lymphoma diagnosed by optic nerve biopsy. *Am J Ophthalmol* 2005;**139**:1128–30.
6. Mavrikakis I, Heran MK, Rootman J. MR findings in a patient with isolated intrinsic optic nerve lymphoma. *Ophthalm Plast Reconstr Surg* 2006;**22**:482–4.
7. Millar MJ, Tumuluri K, Murali R, et al. Bilateral primary optic nerve lymphoma. *Ophthalm Plast Reconstr Surg* 2008;**24**:71–3.
8. Zelefsky JR, Revercomb CH, Lantos G, et al. Isolated lymphoma of the anterior visual pathway diagnosed by optic nerve biopsy. *J Neuroophthalmol* 2008;**28**:36–40.
9. Murray K, Kun L, Cox J. Primary malignant lymphoma of the central nervous system. Results of treatment of 11 cases and review of the literature. *J Neurosurg* 1986;**65**:600–7.
10. Kodama K, Goto T, Sato A, et al. Standard and limitation of intraoperative monitoring of the visual evoked potential. *Acta Neurochir* 2010;**152**:643–8.

doi:<http://dx.doi.org/10.1016/j.jocn.2012.12.021>

## Complete recovery following intra-arterial tenecteplase administration in a woman with acute ischemic stroke



S. Meenakshi-Sundaram<sup>a,\*</sup>, A. Periakaruppan<sup>b</sup>, S.N.K.P. Karuppiah<sup>c</sup>, S.N. Karthik<sup>a</sup>, L. Roopakumar<sup>b</sup>, I. Thembavani<sup>a</sup>

<sup>a</sup> Department of Neurosciences, Apollo Speciality Hospitals, Lake View Road, KK Nagar, Madurai, Tamil Nadu 625 020, India

<sup>b</sup> Department of Radiology, Apollo Speciality Hospitals, Madurai, Tamil Nadu, India

<sup>c</sup> Department of Cardiology, Apollo Speciality Hospitals, Madurai, Tamil Nadu, India

### ARTICLE INFO

#### Article history:

Received 26 July 2012

Accepted 10 December 2012

#### Keywords:

Acute ischemic stroke

Alteplase

Intra-arterial thrombolysis

Mitral stenosis

Recanalization

Tenecteplase

### ABSTRACT

A 23-year-old woman, who underwent a percutaneous transluminal mitral commissurotomy for a tight mitral stenosis, developed an acute ischemic stroke involving the proximal right middle cerebral artery territory. She had a dense left hemiplegia with a National Institutes of Health Stroke Scale score of 12. She was emergently treated within 1 hour with intra-arterial tenecteplase and made a dramatic recovery. Intra-arterial tenecteplase is an attractive option for treating acute ischemic stroke with proximal or major vessel occlusion.

© 2013 Elsevier Ltd. All rights reserved.

### 1. Introduction

Intravenous recombinant tissue plasminogen activator (rt-PA) is currently the only recommended therapy for acute ischemic stroke. However recent data highlight the beneficial effect of intravenous tenecteplase for this condition. A recent head-to-head trial between alteplase and tenecteplase showed the superiority of tenecteplase, with patients treated with tenecteplase showing better reperfusion and overall outcomes.<sup>1</sup> However data on the role of intra-arterial tenecteplase in acute ischemic stroke are scarce.<sup>2</sup> We report a patient with acute ischemic stroke successfully treated with intra-arterial tenecteplase.

### 2. Case report

A 23-year-old woman was diagnosed with rheumatic mitral stenosis with pulmonary hypertension when evaluated for right sided hemiplegia 6 months prior to the ischemic stroke reported here. She made a complete neurologic recovery (treatment details not available) over 4 weeks and remained neurologically asymptomatic thereafter. She underwent cardiac evaluation when a trans-esophageal echocardiogram revealed severe mitral stenosis with a valve area of 0.8 cm<sup>2</sup> and no intra-cardiac clot. She underwent a percutaneous transluminal mitral commissurotomy. The procedure was uneventful. On postoperative day three she devel-

oped a sudden onset weakness in the left limbs and the left side of her face. There was no history of headache, vomiting or convulsions.

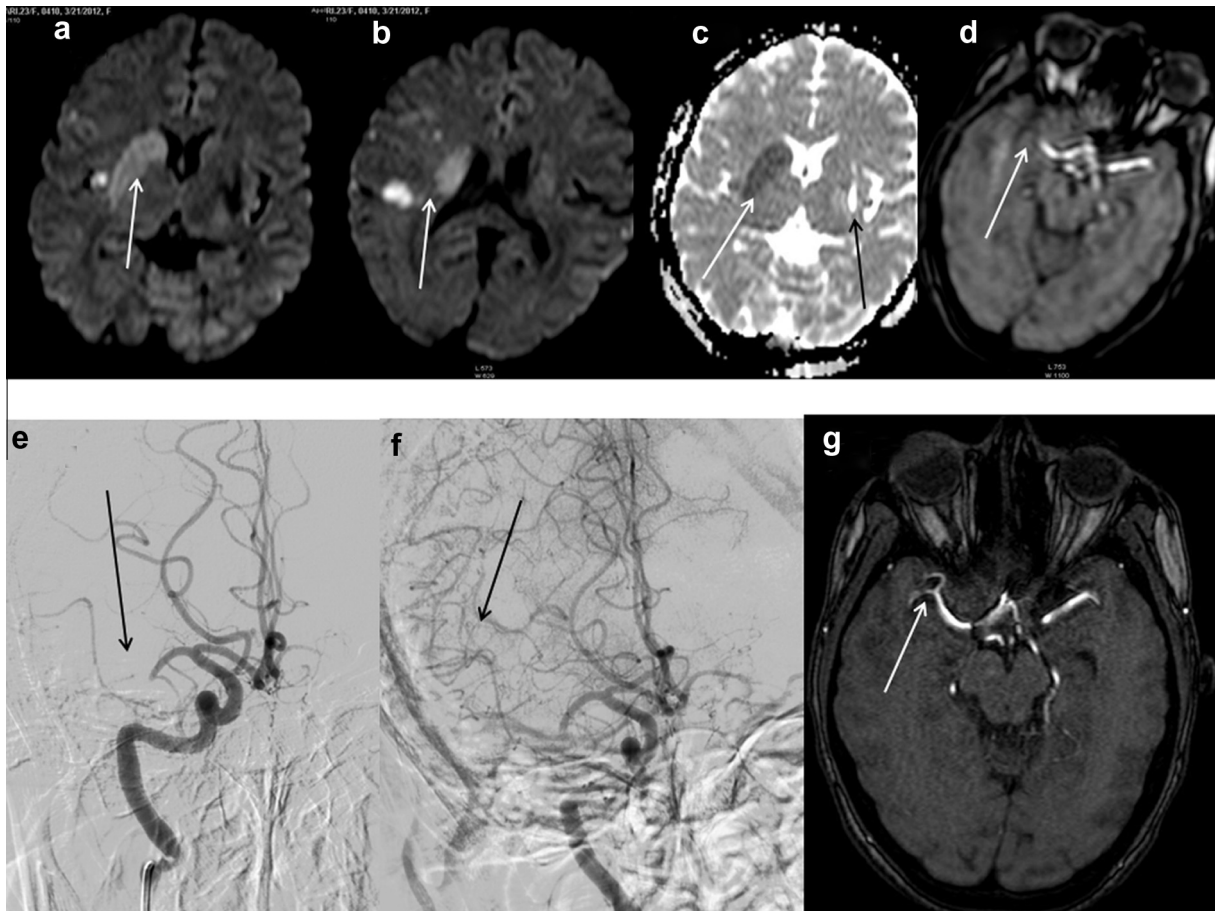
Clinical examination revealed a regular pulse of 68 beats/minute, blood pressure of 160/100 mmHg, a respiratory rate of 22 breaths/minute, and a temperature of 36.9 °C. Cardiovascular examination revealed a mid-diastolic murmur (grade 2/6) and an opening snap at the mitral area. Respiratory and per abdominal examinations were unremarkable.

Neurologically she was alert and oriented. She had a left upper motor neuron facial palsy, partial left gaze palsy, and left hemiplegia (Medical Research Council grade 0) with left hemihypoesthesia. Deep tendon reflexes were absent on the left side and the left plantar reflex was absent. The National Institutes of Health Stroke Scale (NIHSS) score was 12. MRI of the brain revealed an acute infarct involving the right striatocapsular region, head of the caudate nucleus, right centrum semiovale, and inferior frontal cortex. A chronic infarct with gliosis was also seen involving the left posterior putamen and insular cortex (Fig. 1a–c). A magnetic resonance angiogram (MRA) revealed abrupt cut off of the M1 segment of the right middle cerebral artery (MCA) with poor visualization of the right MCA branches (Fig. 1d). There was also total occlusion of the left internal carotid artery (ICA) from its origin.

After obtaining consent from the family the patient was transferred to the catheterization laboratory for intra-arterial thrombolysis through a transfemoral approach. A catheter angiogram confirmed right MCA M1 occlusion (Fig. 1e). She received 15 mg of tenecteplase (0.25 mg/kg) into the supraclinoid ICA and ICA bifurcation. Stroke onset to thrombolysis time was 60 minutes.

\* Corresponding author. Tel.: +91 98 4298 0211; fax: +91 45 2258 1157.

E-mail address: [drsundarsms@yahoo.com](mailto:drsundarsms@yahoo.com) (S. Meenakshi-Sundaram).



**Fig. 1.** (a, b) Axial diffusion weighted imaging showing an acute infarct involving the right ganglio-capsular region and insular cortex (white arrow). (c) Axial apparent diffusion coefficient map showing previous infarction in the lateral putamen and external capsule region (black arrow). (d) Axial time-of-flight source images of the circle of Willis angiogram showing total occlusion of the M1 segment of the right middle cerebral artery (white arrow) with poor visualization of the right middle cerebral artery branches. (e) Pre-thrombolytic digital subtraction angiogram of the right internal carotid artery showing total occlusion of the right M1 segment of the middle cerebral artery (black arrow). (f) Post-thrombolytic digital subtraction angiogram showing flow in the branches of the right middle cerebral artery (black arrow). (g) Axial time-of-flight source images of the circle of Willis angiogram showing recanalization of the M1 segment of the right middle cerebral artery (white arrow) and opening of right middle cerebral artery branches.

Following thrombolysis there was flow in the right M1 segment of the MCA with complete opening of its branches (Fig. 1f).

Limb weakness had recovered completely 30 minutes after the procedure and she had only mild residual left facial weakness which resolved after 2 hours. NIHSS score was 0 at 2 hours. MRI of the brain repeated 24 hours postoperatively revealed a number of new small subcortical infarcts distal to the site of thrombolysis and involving the right corona radiata and periventricular region. MRA showed complete recanalization of the right M1 segment with opening of the MCA branches (Fig. 1g). Anticoagulation was initiated and she was discharged after 3 days.

### 3. Discussion

Tenecteplase is a fibrinolytic drug which has greater fibrin specificity, causing less systemic depletion of fibrin than rt-PA. It has a longer half life compared to rt-PA and is more resistant to plasminogen activator inhibitor-1. A recent phase IIB trial compared standard rt-PA with two doses of tenecteplase (0.1 mg/kg and 0.25 mg/kg) in patients with acute ischemic stroke, selected carefully based on CT scan perfusion and CT angiography findings. Better radiological reperfusion (79% versus 55%) and clinical

improvement (8-point versus 3-point improvement in NIHSS score) was seen in patients treated with tenecteplase compared to rt-PA.<sup>1</sup>

In respect to safety, tenecteplase has been shown to be associated with a lower incidence of systemic hemorrhages than rt-PA in patients with myocardial infarction.<sup>3</sup> In an uncontrolled pilot dose-escalation safety study of tenecteplase in acute ischemic stroke, doses ranging from 0.1 mg/kg to 0.4 mg/kg have been shown to be safe with respect to intracranial hemorrhage.<sup>4</sup> Thus tenecteplase may be a promising agent in the treatment of acute ischemic stroke.

Our patient had undergone a cardiac procedure only 2 days prior and presented with in-hospital acute ischemic stroke. She had a dense motor weakness, moderate NIHSS score and radiological features of M1 occlusion. Recanalization rates are low with intravenous rt-PA in patients with proximal, large-vessel occlusions, as the clot burden is large.<sup>5</sup> Intra-arterial thrombolysis may be theoretically more beneficial than intravenous thrombolysis as there is direct visualization of the efficacy and lower doses of the fibrinolytic agent may be sufficient. A meta-analysis of intra-arterial fibrinolytic therapy has shown better recanalization and outcomes.<sup>6</sup> The dense nature of the weakness, occlusion of the M1 segment, rapid identification of the stroke and availability of the catheterization laboratory without delay were factors that made us proceed with intra-arterial rather than intravenous

thrombolysis. Intra-arterial tenecteplase has been shown to be safe with favorable functional outcomes compared to other thrombolytics.<sup>2</sup> Since there is no clear guideline regarding the dose of intra-arterial tenecteplase we arbitrarily chose the dose reported here. Our patient had a dramatic recovery following this despite a fairly large area of infarction on diffusion weighted imaging, suggesting functional neuronal salvage. The improvement correlated with recanalization of the M1 segment on MRA but there was persistence of the large area of infarct on diffusion weighted imaging done 24 hours post-thrombolysis. We could also not fully explain her complete recovery from the previous stroke 6 months ago when she was not treated with thrombolysis since there was persistent ICA occlusion on this side.

It is well known that the long term prognosis for ischemic stroke is better in the young than the elderly.<sup>7</sup> Lesions of the anterior (plus caudate/putamen) or posterior limb of the internal capsule may lead to an initially severe motor impairment, yet may be followed by excellent recovery.<sup>8</sup> Presumably, chronic hypoperfusion caused by arterial flow restrictions due to previous carotid stenosis could have promoted collateral development. Such collateral circulation could be a critical determinant in acute cerebral ischemia to maintain perfusion of the penumbral regions. Reperfusion of ischemic regions by collaterals is known to minimize the extent of infarction, accounting for such clinical benefits.<sup>9</sup> Thus collaterals may alter the underlying cerebral hemodynamics and have a role in determining the severity of the stroke and/or the extent of recovery.<sup>10</sup> Intra-arterial tenecteplase may be an attractive

option in the management of acute ischemic stroke with large artery involvement and future randomized studies are needed to confirm this benefit.

## References

1. Parsons M, Spratt N, Bivard A, et al. A randomized trial of tenecteplase versus alteplase for acute ischemic stroke. *N Engl J Med* 2012;**366**:1099–107.
2. Georgiadis AL, Memon MZ, Shah QA, et al. Intra-arterial tenecteplase for treatment of acute ischemic stroke: feasibility and comparative outcomes. *J Neuroimaging* 2012;**22**:249–54.
3. Assessment of the Safety and Efficacy of a New Thrombolytic (ASSENT-2) Investigators, Van De Werf F, Adgey J, et al. Single-bolus tenecteplase compared with front-loaded alteplase in acute myocardial infarction: the ASSENT-2 double-blind randomised trial. *Lancet* 1999;**354**:716–22.
4. Haley Jr EC, Lyden PD, Johnston KC, et al. TNK in stroke investigators. A pilot dose-escalation safety study of tenecteplase in acute ischemic stroke. *Stroke* 2005;**36**:607–12.
5. Trouillas P, Nighoghossian N, Getenet JC, et al. Open trial of intravenous tissue plasminogen activator in acute carotid territory stroke: correlations of outcome with clinical and radiological data. *Stroke* 1996;**27**:882–90.
6. Lee M, Hong KS, Saver JL. Efficacy of intra-arterial fibrinolysis for acute ischemic stroke: meta-analysis of randomized controlled trials. *Stroke* 2010;**41**:932–7.
7. Varona JF, Bermejo F, Guerra JM, et al. Long-term prognosis of ischemic stroke in young adults. Study of 272 cases. *J Neurol* 2004;**251**:1507–14.
8. Fries W, Danek A, Scheidtmann K, et al. Motor recovery following capsular stroke. Role of descending pathways from multiple motor areas. Motor recovery following capsular stroke. *Brain* 1993;**116**:369–82.
9. Leibeskind DS. Collateral circulation. *Stroke* 2003;**34**:2279–84.
10. Henderson RD, Eliasziw M, Fox AJ, et al. Angiographically defined collateral circulation and risk of stroke in patients with severe carotid artery stenosis. *Stroke* 2000;**31**:128–32.

doi:<http://dx.doi.org/10.1016/j.jocn.2012.12.027>

# Acute lumbosacral transverse myelitis

Takao Hashimoto\*, Kosuke Naito

Department of Neurology, Aizawa Hospital, 2-5-1 Honjo, Matsumoto 390-8510, Japan



## ARTICLE INFO

### Article history:

Received 9 July 2012

Accepted 29 September 2012

### Keywords:

Acute transverse myelitis  
Lumbosacral spinal cord  
Spinal cord  
Steroid  
Urinary retention

## ABSTRACT

We report two patients with idiopathic acute lumbosacral myelitis, a rare form of acute transverse myelitis. Both patients developed urinary retention, moderate motor and sensory paresis of the lower extremities, severe sensory deficit in the anogenital region and reduced deep tendon reflexes. Steroid pulse therapy was initiated within 2 days after onset, and progress of the symptoms stopped immediately after administration in both of our patients. The sequelae of the sensory deficits in the sacral dermatome distribution and urinary retention impaired daily functioning. Immediate immunosuppressive therapy, including high-dose steroid treatment, is important to improve the prognosis of acute lumbosacral transverse myelitis.

© 2013 Elsevier Ltd. All rights reserved.

## 1. Introduction

Acute lumbosacral myelitis is a rare form of acute transverse myelitis (ATM)<sup>1,2</sup> characterized by urinary retention and sensory loss in the sacral dermatome area.<sup>3</sup> Idiopathic ATM is thought to result from an immune-mediated inflammatory process, but the outcome of immune suppression therapies remains unclear.<sup>4</sup> We present two patients with idiopathic ATM confined to the lumbosacral spinal cord; both of them achieved incomplete, but good, recovery with corticosteroid treatment.

## 2. Case reports

### 2.1. Patient 1

A 59-year-old woman with a 3 year history of diabetes mellitus presented with lower limb dysesthesia. The next day she was admitted because of the development of weakness and sensory loss in the distal lower limbs and urinary retention. Neurological examination on admission revealed moderate paresis in both legs. She could not stand up without support. Deep tendon reflexes were decreased, and plantar responses were flexor on both sides. Fine touch and pinprick sensation were decreased in a sacral dermatome distribution, most severely in the anogenital region. She had no constipation, but required catheterization for urinary reten-

\* Corresponding author. Tel.: +81 263 33 8600; fax: +81 263 33 8609.  
E-mail address: [sinke-dr@ai-hosp.or.jp](mailto:sinke-dr@ai-hosp.or.jp) (T. Hashimoto).