

Long-term cortical reorganization following stroke in a single subject with severe motor impairment

Kenneth C. Chelette^a, Cheryl Carrico^a, Laurie Nichols^{a,b} and Lumy Sawaki^{a,*}

^a*Department of Physical Medicine and Rehabilitation, University of Kentucky, Lexington, KY, USA*

^b*Cardinal Hill Rehabilitation Hospital, Lexington, KY, USA*

Abstract.

BACKGROUND: Stroke continues to be a major public health concern in the United States. Motor recovery in the post-acute stages of stroke is possible due to neuroplasticity, or the capacity of the brain to reorganize.

OBJECTIVE: This case study tracks neuroplastic and motor change in a subject with severe hemiparesis following an extensive middle cerebral artery stroke. He had absence of ipsilesional motor evoked potentials in early evaluations. This report is unique in that the duration of follow-up evaluation extends nearly 2 years, with evaluations being performed at 7, 9, 10, 13, 20, and 21 months post-stroke.

METHODS: At each evaluation we used transcranial magnetic stimulation to track neuroplastic change and the Fugl-Meyer Assessment and the Wolf Motor Function Test to evaluate upper extremity motor performance.

RESULTS: The contralesional hemisphere showed dynamic change throughout the study period. In contrast, the ipsilesional hemisphere demonstrated notable change only between 13 and 21 months post-stroke, with the most dramatic change occurring between 20 and 21 months post-stroke. Motor performance generally improved throughout the study period.

CONCLUSIONS: Our findings demonstrate that substantial neuroplasticity-mediated motor recovery can occur nearly 2 years after stroke in an individual with severe post-stroke motor impairment.

Keywords: Neuroplasticity, rehabilitation, transcranial magnetic stimulation, chronic, upper extremity

1. Introduction

Neuroplastic change plays a major role in post-stroke motor recovery (Sawaki et al., 2008; Traversa, Cicinelli, Bassi, Rossini, & Bernardi, 1997). Research has shown that both ipsilesional and contralesional hemispheres can contribute to motor recovery; moreover, the presence of motor evoked potentials (MEPs) elicited by transcranial magnetic stimulation (TMS) has been generally accepted as a predictor of motor

recovery (Escudero, Sancho, Bautista, Escudero, & Lopez-Trigo, 1998; van Kuijk, Pasman, Hendricks, Zwarts, & Geurts, 2009). Here, we report on long-term post-stroke neuroplastic change and improvement in upper extremity motor function in a subject without ipsilesional MEPs at early (<12 months post-stroke) evaluation.

2. Methods

We evaluated neuroplasticity and upper extremity motor function in a 61-year old man with a large (lesion of 93 cm³) left middle cerebral artery ischemic stroke of thrombotic origin (Fig. 1a). Evaluations occurred

*Address for correspondence: Lumy Sawaki, MD, PhD, Department of Physical Medicine and Rehabilitation, University of Kentucky, 2050 Versailles Road, Lexington, KY 40508, USA. Tel.: +1 859 323 6889; E-mail: Lumy.Sawaki@uky.edu.

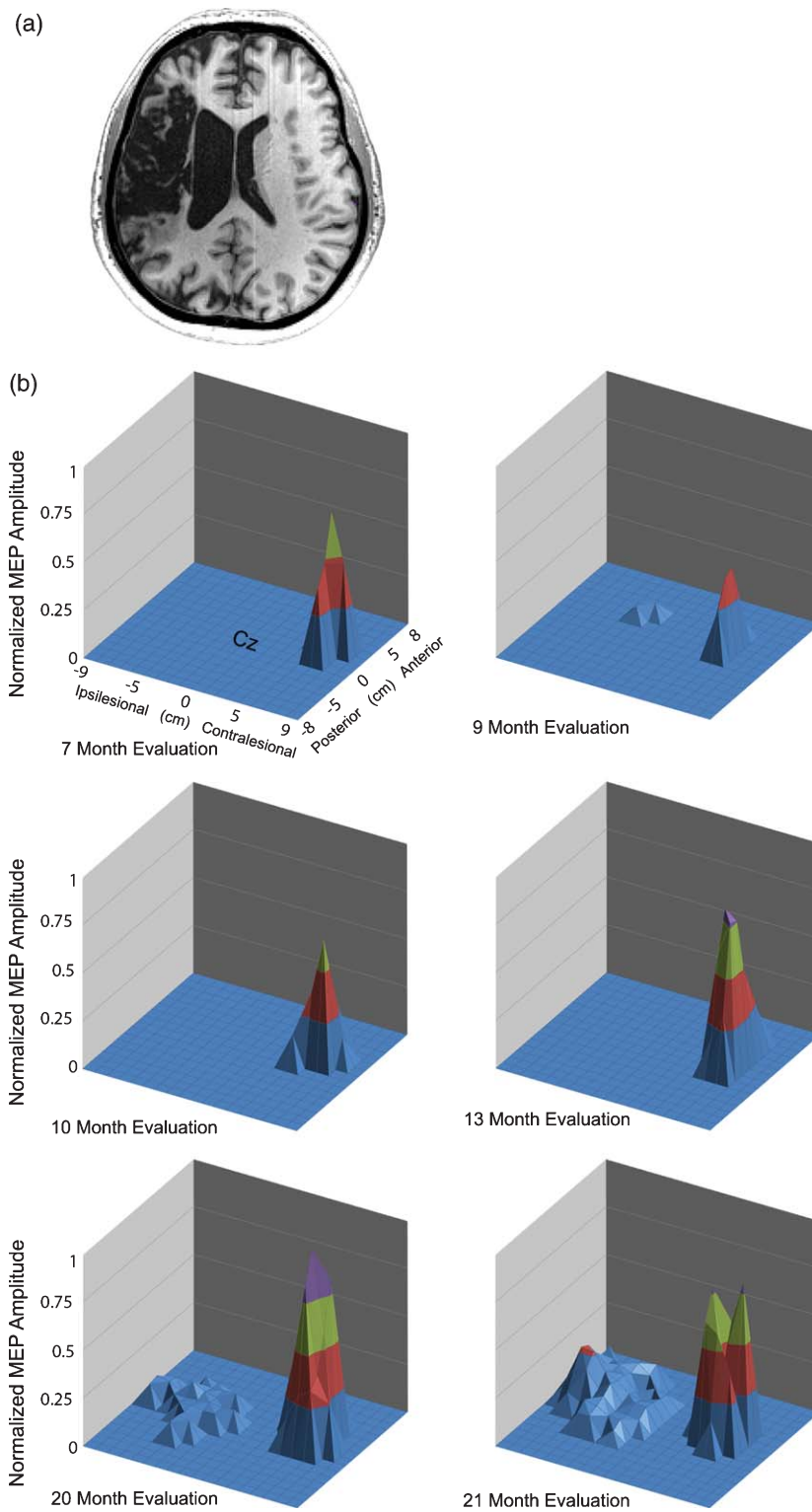


Fig. 1. (a) Axial view of T1 weighted MRI displayed in neurological convention. (b) TMS motor maps: change over time. X- and y-coordinates indicate scalp position; z-axis indicates normalized MEP amplitude.

at 7, 9, 10, 13, 20, and 21 months post-stroke. The subject was left-handed prior to stroke. He presented with significant expressive aphasia, but comprehension was intact. Although he was taking CNS-active medications (levothyroxine and gabapentin), no medication changes occurred during the study period. Proprioception, stereognosis, and graphesthesia, as well as sensory response to light touch, temperature, pin prick, and vibration, were significantly decreased at baseline. During the time period reported in this study, the subject was enrolled in 2 separate research protocols in which interventions to upmodulate neuroplasticity were applied in conjunction with occupational therapy. However, these interventions are not the primary focus of this study. All research activities were approved by the local institutional review board.

To track neuroplastic change, we used a standardized methodology to acquire TMS cortical motor maps (Sawaki et al., 2008). Additionally, we used a neuronavigation system to ensure coil placement reproducibility (Krings et al., 2001), and plastic film templates to ensure electrode placement reproducibility. Because of high ipsilesional resting motor thresholds, we used maximum stimulator output (100%) to acquire all ipsilesional maps. Cortical motor mapping provides information about location and strength of the cortical representation of a given muscle. Change in the volume of the TMS cortical motor map has been associated with neuroplasticity (Hallett, 2001; Sawaki et al., 2008; Wittenberg et al., 2003). To evaluate upper extremity motor performance, we administered the Fugl-Meyer Assessment (FMA) and the Wolf Motor Function Test (WMFT). These tests have high interrater reliability (Duncan, Propst, & Nelson, 1983; Morris, Uswatte, Crago, Cook, & Taub, 2001). All evaluators received standardized training to administer TMS, the FMA, and the WMFT. Evaluations were conducted in a blinded manner. Change scores were computed for each measure at each time point to track motor recovery and cortical reorganization.

3. Results

Change scores revealed that a net increase (4.6 normalized amplitude \times cm²) in contralesional map volume occurred between 7 and 20 months post-stroke, followed by a decrease (−1.7 normalized amplitude \times cm²) evident at 21 months post-stroke. Ipsilesional motor map volume remained relatively stable between 7 and 13 months post-stroke and increased

between 13 and 21 months post-stroke (6.5 normalized amplitude \times cm²), with a marked increase occurring between 20 and 21 months post-stroke (4.1 normalized amplitude \times cm²). From the first evaluation to the last, the change in contralesional volume was 134% (2.9 normalized amplitude \times cm²), while ipsilesional volume changed from 0 to 6.5 normalized amplitude \times cm² (Fig. 1b). No substantial shifts in contralesional resting motor thresholds were noted across sessions.

Both FMA and WMFT showed net improvement at completion of the study (FMA increase: 17 points, 49%; WMFT decrease: 0.38s, 22%). Dramatic improvement in motor performance occurred between 7 and 10 months post-stroke (FMA increase: 9 points; WMFT decrease: 0.18s) and between 20 and 21 months post-stroke (FMA increase: 12 points; WMFT decrease: 0.32s). Figure 2 illustrates how motor gains correlated with neuroplastic change.

4. Discussion

Noteworthy ipsilesional MEPs in this subject did not emerge until the late phase of recovery. This finding suggests that the absence of ipsilesional MEPs in early recovery should not necessitate a poor prognosis and, in turn, that post-stroke recovery is more dynamic than conventional wisdom holds. Our findings also highlight that the restoration of ipsilesional cortical pathways is not the only mechanism of post-stroke neural recovery. Interestingly, contralesional map volume reflected dynamic change throughout the study period. Each decrease in contralesional map volume was accompanied by dramatic improvement in motor performance. The largest motor performance changes in the affected upper extremity were measured between 20 and 21 months post-stroke. During this period, we observed a marked increase in ipsilesional map volume and a decrease in contralesional map volume. These late ipsilesional volume changes clearly exceed normal variability associated with the TMS technique (Butler, Kahn, Wolf, & Weiss, 2005). The remarkable change in ipsilesional volume from no volume to considerable volume during a period of substantial FMA gain leaves little doubt that cortical plasticity played a substantial role in this subject's motor recovery. The findings reported here differ from previously reported analyses of contralesional map volume in mildly affected stroke subjects (Sawaki et al., 2008) and suggest that recovery mechanisms may differ between mildly and severely affected stroke survivors.

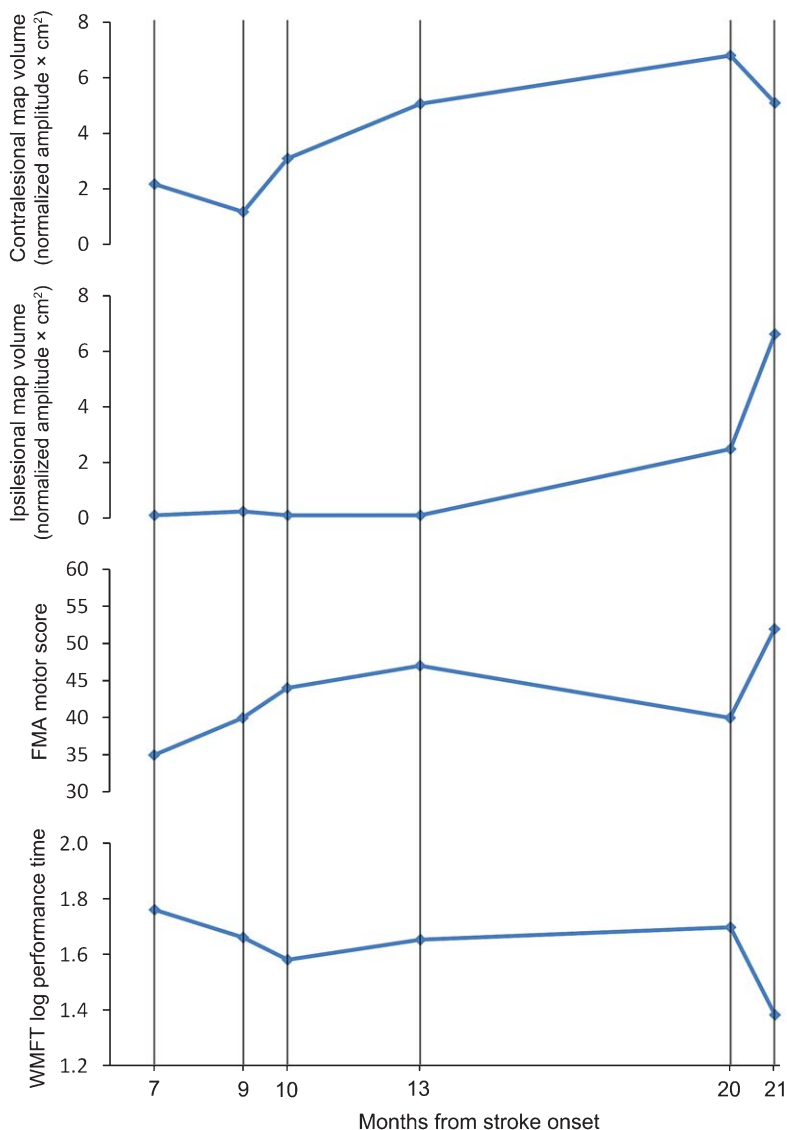


Fig. 2. Behavioral and neurophysiological findings. Net change in motor map volume, as well as improvement in motor performance, is evident (increase in FMA and/or decrease in WMFT indicate improvement).

Clinically meaningful FMA changes occur with improvement of 10%, which indicates progress to the next stage of motor recovery (Feys et al., 1998). This threshold was reached at the 9, 10, and 21 month evaluations.

Although not the focus of this case study, it should be noted that the subject participated in several types of motor therapy during the period coinciding with our evaluation timeframe. Between 7 and 9 months post-stroke, he had 18 sessions of peripheral nerve stimulation paired with 3 hours of occupational therapy in a

research setting. Between 9 and 12 months post-stroke, he did not undergo any therapy. Between 12 and 20 months post-stroke, he had 54 one-hour sessions (two per week) of standard, outpatient occupational therapy. Between 20 and 21 months post-stroke, he had 10 sessions of transcranial direct current stimulation paired with 3 hours of occupational therapy in a research setting. That this subject participated in interventions with multiple rehabilitative approaches does not change the implications of our findings, which suggest that we may not be following subjects with an absence of MEPs long

enough to fully understand the neuroplastic changes that accompany recovery. This is likely to be particularly true in severely affected subjects and in response to interventions designed to upmodulate neuroplasticity.

5. Study limitation

Technical constraints of TMS could be considered as a possible limitation of the study: it may not have been possible to set TMS intensity high enough to activate ipsilesional MEPs at baseline. A different neuroimaging technique (eg, functional magnetic resonance imaging or magnetoencephalography) may have revealed ipsilesional activation at baseline.

6. Conclusions

In sum, neuroplastic change and associated motor recovery can occur well past the early post-stroke phase. The motor maps presented here, particularly the ipsilesional maps, remained in flux nearly 2 years post-stroke. Thus, it appears that both contralesional and ipsilesional neuroplastic change can play a role in long-term motor recovery. More studies are needed to follow subjects continuously for long periods (ie, >2 years post-stroke) in order to establish better understanding of longitudinal neuroplastic change, particularly in stroke survivors with severe motor impairments. Likewise, further studies are needed for better understanding of the contribution of each hemisphere to early and late recovery after severe stroke. This information would have great value for developing neuroplasticity-based therapy protocols tailored to a specific population.

Declaration of interest

The authors have no conflicts of interest to disclose.

Acknowledgments

This work was funded in part by NIH grant # 5R01HD056002 and the Cardinal Hill Stroke and Spinal Cord Injury Endowment #0705129700.

We thank the participant and his family for their time and effort. We also thank Dr. David Jackson for his

assistance with subject selection and his ongoing support as well as Dr. Heather Bush for her assistance with statistical analysis.

References

- Butler, A. J., Kahn, S., Wolf, S. L., & Weiss, P. (2005). Finger extensor variability in TMS parameters among chronic stroke patients. *J Neuroengineering Rehabil*, 2, 10.
- Duncan, P. W., Propst, M., & Nelson, S. G. (1983). Reliability of the Fugl-Meyer assessment of sensorimotor recovery following cerebrovascular accident. *Phys Ther*, 63(10), 1606-1610.
- Escudero, J. V., Sancho, J., Bautista, D., Escudero, M., & Lopez-Trigo, J. (1998). Prognostic value of motor evoked potential obtained by transcranial magnetic brain stimulation in motor function recovery in patients with acute ischemic stroke. *Stroke*, 29(9), 1854-1859.
- Feys, H. M., De Weerd, W. J., Selz, B. E., Cox Steck, G. A., Spichiger, R., Vereeck, L. E., et al. (1998). Effect of a therapeutic intervention for the hemiplegic upper limb in the acute phase after stroke: A single-blind, randomized, controlled multicenter trial. [Clinical Trial Multicenter Study Randomized Controlled Trial Research Support, Non-U.S. Gov't]. *Stroke*, 29(4), 785-792.
- Hallett, M. (2001). Functional reorganization after lesions of the human brain: Studies with transcranial magnetic stimulation. *Rev Neurol (Paris)*, 157(8-9 Pt 1), 822-826.
- Krings, T., Chiappa, K. H., Foltys, H., Reinges, M. H., Cosgrove, G. R., & Thron, A. (2001). Introducing navigated transcranial magnetic stimulation as a refined brain mapping methodology. [Research Support, Non-U.S. Gov't Review]. *Neurosurg Rev*, 24(4), 171-179.
- Morris, D. M., Uswatte, G., Crago, J. E., Cook, E. W., 3rd, & Taub, E. (2001). The reliability of the wolf motor function test for assessing upper extremity function after stroke. [Research Support, Non-U.S. Gov't Research Support, U.S. Gov't, Non-P.H.S.]. *Arch Phys Med Rehabil*, 82(6), 750-755. doi: 10.1053/apmr.2001.23183
- Sawaki, L., Butler, A. J., Leng, X., Wassenaar, P. A., Mohammad, Y. M., Blanton, S., et al. (2008). Constraint-induced movement therapy results in increased motor map area in subjects 3 to 9 months after stroke. *Neurorehabil Neural Repair*, 22(5), 505-513. doi: 22/5/505 [pii] 10.1177/1545968308317531
- Traversa, R., Cicinelli, P., Bassi, A., Rossini, P. M., & Bernardi, G. (1997). Mapping of motor cortical reorganization after stroke. A brain stimulation study with focal magnetic pulses. *Stroke*, 28(1), 110-117.
- van Kuijk, A. A., Pasman, J. W., Hendricks, H. T., Zwarts, M. J., & Geurts, A. C. (2009). Predicting hand motor recovery in severe stroke: The role of motor evoked potentials in relation to early clinical assessment. *Neurorehabil Neural Repair*, 23(1), 45-51. doi: 1545968308317578 [pii] 10.1177/1545968308317578
- Wittenberg, G. F., Chen, R., Ishii, K., Bushara, K. O., Eckloff, S., Croarkin, E., et al. (2003). Constraint-induced therapy in stroke: Magnetic-stimulation motor maps and cerebral activation. *Neurorehabil Neural Repair*, 17(1), 48-57.