

Case Reports

Ipsilateral Leg Weakness Associated With Carotid Stenosis

Marc I. Chimowitz, MD, E. Frank Lafranchise, MD,
Anthony J. Furlan, MD, and Issam A. Awad, MD

Ipsilateral motor or sensory symptoms associated with carotid occlusive disease are rare. We report a 52-year-old man who presented with aphasia, right hemiparesis, mild left leg weakness, and bilateral Babinski's signs. During the previous 10 days, he had experienced three episodes of left leg numbness and incoordination that occurred either alone or in association with right arm and leg weakness. Computed tomography showed infarcts in the right frontoparietal (parasagittal), left frontal, and left parietal lobes. Cerebral angiography revealed 60% stenosis of the right internal carotid artery, 80% stenosis of the left internal carotid artery, absence of the A1 segment of the right anterior cerebral artery, filling of the right anterior cerebral artery from the left carotid circulation only, and a normal vertebrobasilar system. This report illustrates that leg weakness may occur ipsilateral to carotid disease if the contralateral anterior cerebral artery is supplied by the ipsilateral carotid artery. (*Stroke* 1990;21:1362-1364)

It is generally considered that weakness or sensory dysfunction associated with carotid disease occurs contralateral to the involved carotid artery. However, a study by Yanagihara et al,¹ which focused on the mechanism of lower extremity weakness in carotid occlusive disease, described two patients with lower extremity weakness ipsilateral to a highly stenotic carotid artery. We report another patient with leg weakness ipsilateral to carotid stenosis and attempt to clarify the clinical, radiologic, and pathophysiological features of this unusual entity.

Case Report

A 52-year-old hypertensive man was transferred from another hospital on September 15, 1989, because of aphasia, right hemiparesis, and left leg weakness. Six months previously, over 2 weeks he had experienced three episodes of transient monocular blindness in the left eye, each of which resolved after a few minutes. The visual symptoms did not recur. On August 30, he had an episode of right arm weakness and tingling lasting <5 minutes. A similar spell on September 5 prompted admission to an outside hospital, where the neurologic examination, a cranial computed tomogram (CT scan), and an electroencephalogram were reported as normal. Carotid ultra-

sonography suggested >90% stenosis of the left internal carotid artery and 50-70% stenosis of the right internal carotid artery. Dipyridamole was prescribed.

Over the next 10 days, the patient experienced two brief (<5 minutes) episodes of right arm weakness and tingling and three episodes of left leg numbness that involved almost the entire leg from the foot to the buttock and was associated with incoordination of the leg. The left leg symptoms lasted from 30 minutes to a few hours and usually occurred independently of the right arm symptoms, although on one occasion they occurred together. On September 15, the patient awoke confused and agitated with a right hemiparesis. He was transferred to the Cleveland Clinic, where examination revealed a blood pressure of 160/90 mm Hg, a regular pulse of 85/min, bilateral carotid bruits, expressive aphasia, right hemiparesis (arm 2/5, leg 4-/5), mild left leg weakness (proximal 4-/5, distal 4+/5), bilateral hyperreflexia and Babinski's signs, and mild sensory loss (pinprick, touch, proprioception) of the right arm. Heparin was prescribed.

A cranial CT scan on September 15 was normal, but another scan on September 20 showed infarcts involving the right frontoparietal (parasagittal), left frontal, and left parietal lobes (Figure 1). Cerebral angiography on September 20 revealed 60% stenosis of the right internal carotid artery with a large ulcer, 80% stenosis of the left internal carotid artery with an apparent filling defect in the proximal portion of the vessel, filling of the proximal right anterior cerebral artery from the left carotid circulation only, delayed filling of the distal right anterior cerebral

From the Departments of Neurology (M.I.C., E.F.L., A.J.F.) and Neurosurgery (I.A.A.), The Cleveland Clinic Foundation, Cleveland, Ohio.

Address for correspondence: Marc I. Chimowitz, MD, Neurology Service, Veterans Administration Medical Center, Ann Arbor, MI 48105.

Received January 17, 1990; accepted May 24, 1990.

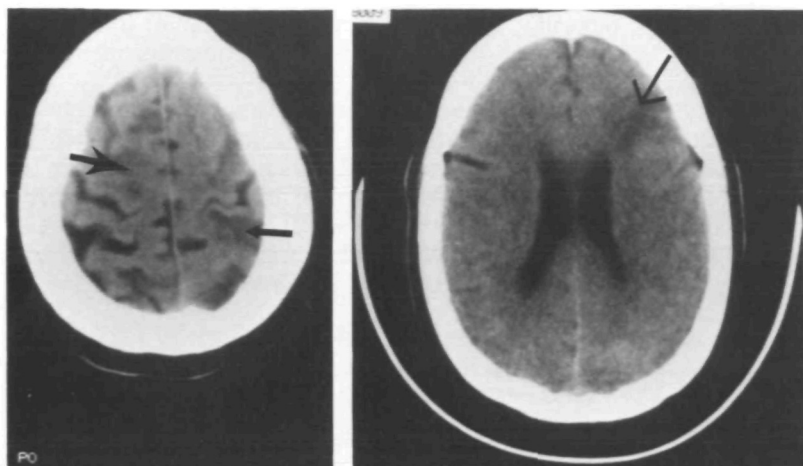


FIGURE 1. Cranial computed tomography showing right parasagittal (large bold arrow), left parietal (small bold arrow), and left frontal (large fine arrow) infarcts in 52-year-old hypertensive man with 80% stenosis of left internal carotid artery.

artery territory compared with the left, no evidence of a filling defect in the right anterior cerebral artery territory, and a normal vertebrobasilar system that did not contribute flow to the right middle cerebral artery (Figure 2). An echocardiogram and an electrocardiogram were normal.

The patient underwent left carotid endarterectomy on September 21, 1989. At surgery a large ulcerative plaque was found that severely compromised the vessel lumen (residual diameter <2 mm). There was no intraluminal clot. All motor deficits resolved within 1 week after surgery, and his expressive aphasia recovered during the subsequent 6 weeks. The patient has not experienced recurrent cerebral ischemic symptoms in 4 months of postoperative follow-up.

Discussion

Although this patient had stenosis of both internal carotid arteries, it is highly likely that the right frontoparietal (parasagittal) infarct was caused by the left carotid stenosis since the right anterior cerebral artery was supplied exclusively by the left carotid circulation. This occurred despite a higher grade stenosis on the left side, which suggests that the A1 segment of the right anterior cerebral artery was atretic.

It is difficult to determine whether embolism or hypoperfusion was the underlying mechanism of our patient's right hemisphere transient ischemic attacks (TIAs) and infarct. The long duration of the right hemisphere TIAs argues against a hemodynamic mechanism,² but the simultaneous occurrence of

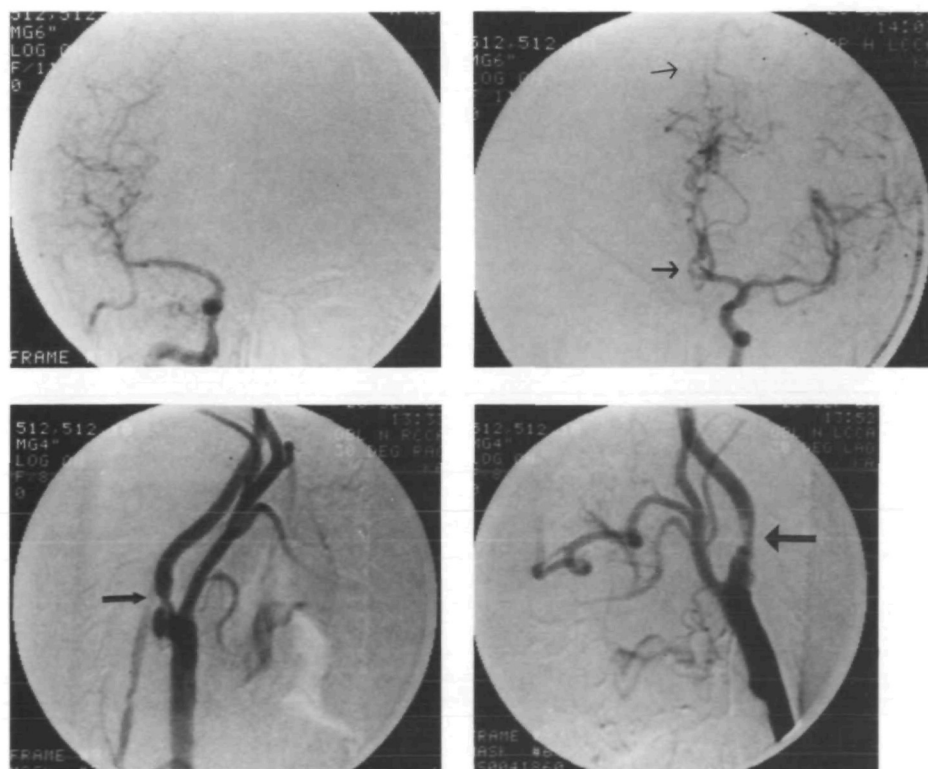


FIGURE 2. Cerebral angiograms showing 60% stenosis of right internal carotid artery (small bold arrow), 80% stenosis of left internal carotid artery (large bold arrow), filling of right anterior cerebral artery from left carotid circulation only (arrow), and delayed filling of distal right anterior cerebral artery territory (fine arrow) compared with left anterior cerebral artery territory.

right and left hemisphere TIAs on one occasion, the location of the right frontoparietal infarct on CT scan,^{3,4} and the angiographic finding of delayed filling of the distal right anterior cerebral artery territory suggest that hypoperfusion was the major factor. Further evidence that hypoperfusion is the likely mechanism of leg weakness ipsilateral to carotid stenosis is provided by the two patients of Yanagihara et al¹ who reported stereotypical episodes of leg weakness prompted by walking, and by cerebral blood flow studies in patients with carotid disease and weakness of the lower extremity that show hypoperfusion in the border zone between the anterior and middle cerebral arteries.^{1,5}

A necessary condition for leg weakness ipsilateral to carotid disease is that the contralateral anterior cerebral artery be supplied by the ipsilateral carotid artery. In the two patients of Yanagihara et al,¹ this occurred in the setting of prior occlusion of the contralateral internal carotid artery; however, in our patient the contralateral internal carotid artery was patent but the A1 segment of the contralateral anterior cerebral artery was atretic. This finding stresses the importance of evaluating the intracranial circulation bilaterally in patients with extracranial carotid occlusive disease since without this data our

patient's left leg symptomatology may have been attributed to the moderate stenosis of the right internal carotid artery.

Although our patient presented with bilateral symptoms, signs, and CT-documented infarcts, the two previously reported patients presented with leg weakness only on the side of the stenotic carotid artery. Therefore, ipsilateral carotid disease should be considered in the differential diagnosis of episodic or persistent weakness of one lower extremity.

References

1. Yanagihara T, Sundt TM Jr, Piepgras DG: Weakness of the lower extremity in carotid occlusive disease. *Arch Neurol* 1988; 45:297-301
2. Pessin MS, Duncan GW, Mohr JP, Poskanzer DC: Clinical and angiographic features of carotid transient ischemic attacks. *N Engl J Med* 1977;296:358-362
3. Bogousslavsky J, Regli F: Unilateral watershed cerebral infarcts. *Neurology* 1986;36:373-377
4. Wodarz R: Watershed infarctions and computed tomography. A topographical study in cases with stenosis or occlusion of the carotid artery. *Neuroradiology* 1980;19:245-248
5. Powers WJ, Grubb RL Jr, Raichle ME: Physiological responses to focal cerebral ischemia in humans. *Ann Neurol* 1984; 16:546-552

KEY WORDS • carotid artery diseases • cerebral infarction

Ipsilateral leg weakness associated with carotid stenosis.
M I Chimowitz, E F Lafranchise, A J Furlan and I A Awad

Stroke. 1990;21:1362-1364

doi: 10.1161/01.STR.21.9.1362

Stroke is published by the American Heart Association, 7272 Greenville Avenue, Dallas, TX 75231

Copyright © 1990 American Heart Association, Inc. All rights reserved.

Print ISSN: 0039-2499. Online ISSN: 1524-4628

The online version of this article, along with updated information and services, is located on the
World Wide Web at:

<http://stroke.ahajournals.org/content/21/9/1362>

Permissions: Requests for permissions to reproduce figures, tables, or portions of articles originally published in *Stroke* can be obtained via RightsLink, a service of the Copyright Clearance Center, not the Editorial Office. Once the online version of the published article for which permission is being requested is located, click Request Permissions in the middle column of the Web page under Services. Further information about this process is available in the [Permissions and Rights Question and Answer](#) document.

Reprints: Information about reprints can be found online at:
<http://www.lww.com/reprints>

Subscriptions: Information about subscribing to *Stroke* is online at:
<http://stroke.ahajournals.org/subscriptions/>