

## HEMISPATIAL NEGLECT IN A PATIENT WITH CALLOSAL INFARCTION

by ASAKO KASHIWAGI,<sup>1</sup> TOSHIHIRO KASHIWAGI,<sup>2</sup> TAKASHI NISHIKAWA,<sup>3</sup> HIROTAKA TANABE<sup>4</sup> and JUN-ICHIRO OKUDA<sup>5</sup>

(From Kyoritsu Rehabilitation Hospital, Kawanishi, Hyogo, Japan)

### SUMMARY

Left hemispatial neglect, confined to right-hand and verbal responses, was exhibited by a 56-yr-old right-handed male patient with callosal lesions due to cerebral infarction. Various disconnection signs were also present. His CT and MRI scans disclosed major lesions situated in the posterior half of the genu and the whole trunk of the corpus callosum, as well as in the left medial frontal and temporo-occipital lobes. Left hemispatial neglect was invariably demonstrated in right-hand performance such as copying drawings, line bisection, matching identical figures and copying multiple digit numbers, and in verbal performance such as confrontation naming and reading aloud multiple digit numbers. In contrast, little or no right hemispatial neglect was demonstrated in tasks performed with the left hand. These findings support the hypothesis that the left hemisphere is only concerned with attending to the contralateral hemispace and that the right hemisphere is specialized for attending to both sides of space although the preponderant tendency is for attending to the contralateral hemispace. The neglect symptoms observed in our patient may be a disconnection sign which was attributable to a combination of lesions in the corpus callosum and in the left medial frontal lobe.

### INTRODUCTION

It is generally accepted that hemispatial neglect is manifested in the contralateral hemispace of a damaged hemisphere, and that right hemisphere lesions cause more frequent and more severe neglect than those in the left hemisphere (Costa *et al.*, 1969; De Renzi *et al.*, 1970; Gainotti *et al.*, 1972; Albert, 1973; for reviews, see Heilman *et al.*, 1985, and Mesulam, 1985). It is plausible to argue that theoretical considerations on hemispatial neglect must be based on such asymmetric manifestations of hemispatial neglect (Friedland and Weinstein, 1977). A few cogent hypotheses have been put forward to explain this asymmetry.

Kinsbourne (1977) argued that each hemisphere explored contralateral hemispace although the exploration of the left hemisphere into right hemispace was more powerful than that of the right hemisphere into left hemispace. He also pointed out that right- and left-orientating tendencies were in a reciprocal system; if one hemisphere was

Correspondence to: A. Kashiwagi, Kyoritsu Rehabilitation Hospital, Hirano-Shioyama 281, Kawanishi 666-01, Japan.

<sup>1</sup> Department of Rehabilitation, Kyoritsu Rehabilitation Hospital, <sup>2</sup> Department of Rehabilitation, Kyowakai Hospital, <sup>3</sup> Department of Neuropsychiatry, Hoshigaoka Kosei-Nenkin Hospital, <sup>4</sup> Department of Neuropsychiatry, Osaka University Medical School, and <sup>5</sup> Faculty of Health and Sport Sciences, Osaka University.

inactivated, the other was disinhibited. Based on these mechanisms, a right hemisphere lesion released the function of the left hemisphere resulting in left hemispatial neglect. He further argued that activation of the left hemisphere by linguistic activities enhanced exploration into right hemispace, resulting in the more frequent occurrence of left hemispatial neglect in patients with right hemisphere lesions.

On the other hand, models based on the asymmetry of attentional direction of the two hemispheres have been proposed. Following the suggestion by Heilman and Valenstein (1979) that the right hemisphere dominated the attentional processes, Heilman and Van Den Abell (1980), on the basis of electroencephalographic data of normal subjects, proposed that the right hemisphere attended to stimuli presented to both the right and left sides while the left hemisphere could not attend to ipsilateral stimuli. Heilman *et al.* (1985), in explaining a mechanism of hemispatial akinesia, argued that the right hemisphere could prepare the limbs physiologically to work in (or towards) either right or left hemispace, but that the left hemisphere could only activate them to work in (or towards) right hemispace. In a review article, Mesulam (1981) expressed a similar view but limited the ipsilateral attentional capacity of the right hemisphere to a lesser extent than the contralateral one. He postulated that (1) the intact right hemisphere may contain the neural apparatus for attending to both sides of space, although the predominant tendency was for attending to the contralateral (left) hemispace; (2) the left hemisphere is almost exclusively concerned with attending to the contralateral right hemispace; and (3) more synaptic space was devoted to attentional functions in the right hemisphere than in the left, so that most attentional tasks involving either hemispace would generate greater activity in the right hemisphere. Weintraub and Mesulam (1987) supported this model with their experimental data, where patients with right-hemisphere damage showed neglect in ipsilateral hemispace, although not as severe as in contralateral hemispace. These asymmetric attention models, including that of Kinsbourne, seem capable of explaining differences in the spatial lateralization and severity of neglect resulting from damage to the right or left hemispheres.

If directed attention is asymmetrically represented in the right and left hemispheres, it would be anticipated that patients with callosal lesions might demonstrate unimanual hemispatial neglect because an inferior hemisphere is obliged to run by itself, as in the case of the linguistically nondominant hemisphere yielding unimanual agraphia, tactile anomia and so forth in callosal disconnection. However, as far as commissurotomy patients are concerned, salient neglect has not been described (Sperry *et al.*, 1969; Gordon *et al.*, 1971; Joynt, 1977; Plourde and Sperry, 1984; Bogen, 1985), although neglect only in the acute period (Wilson *et al.*, 1977), rudimentary neglect in the chronic period (Plourde and Sperry, 1984) and the superiority of the right hemisphere in attentional capacity (Dimond, 1976) have been reported. Thus the absence of salient neglect in commissurotomy patients has been a serious obstacle in the acceptance of the hemisphere asymmetry models of directed attention.

What interpretation has been given to the lack of prominent neglect in commissurotomy patients? Holtzman *et al.* (1981) proposed that each hemisphere is provided with bilateral visual representation for the allocation of attentional resources. Plourde and Sperry (1984)

also suggested that each hemisphere has the capacity for exploration and representation of both sides of space, although the right hemisphere has the lead role in cognitive operations that involve spatial relationships as well as for certain attentional tasks. These authors considered that the left-sided awareness of the left hemisphere was subject to differential suppression in the presence of the cerebral commissures via disruptive influences from a focally damaged right hemisphere. Heilman *et al.* (1984), on the basis of the data from a patient with callosal damage due to infarction, suggested mechanisms which presupposed that each hemisphere attended only to contralateral hemispace independent of the sensory field or extremity used. In conclusion, the observations on commissurotomy patients seem to support symmetric cerebral representations of directed attention whether each hemisphere is postulated to orient unilaterally or bilaterally.

More recently, however, hemispatial neglect has been sporadically described in patients with callosal lesions due to cerebrovascular disease. Sine *et al.* (1984) observed a right-handed patient with a cerebral haemorrhage, who showed a callosal syndrome and left-sided neglect confined to the right hand when drawing a clock. The CT scan demonstrated a haemorrhage in the left parasagittal frontoparietal area and an angiogram on day 4 demonstrated spasm of the A-1 segment of the anterior cerebral artery. Furthermore, a right-handed patient of Goldenberg (1986) with destruction of the anterior two-thirds of the corpus callosum and the adjacent medial frontal lobes as a sequel of bleeding from an anterior cerebral artery aneurysm, displayed neglect of left hemispace limited to her right hand. To date, these case studies have never come to adequate attention in the literature. The present authors had the opportunity to examine a patient with callosal lesions due to cerebral infarction who demonstrated signs of unilateral hemispatial neglect not only confined to the right hand in visuomanual tasks but also in verbal responses for visuo-verbal tasks. Observations supporting the hemisphere asymmetry models of directed attention advanced by Heilman and Van Den Abell (1980) and Mesulam (1981) have been reported. On the basis of these hemisphere asymmetry models, we will further explore the possibility that the asymmetric neglect observed in our patient may be a disconnection sign and that medial frontal lesions may in addition contribute to callosal lesions.

### CASE REPORT

Y.Y. was a 56-yr-old government official with 16 yrs of education, completely right-handed according to our handedness enquiry list consisting of 14 questions about manual dexterity. He had no left-hand genetic relatives. He developed sudden paresis of the right lower limb in December 1983 and was admitted to a local hospital. He was diagnosed as having had a cerebral thrombosis, but no lesion was detected on a CT scan. He began work again in September 1984 but needed assistance both in commuting and in office work. On July 14, 1985, he was found unconscious in bed by a family member and brought to another local hospital. His CT scan disclosed a large low density area extending from the temporal to the occipital lobes in the left hemisphere. He was transferred to Kyoritsu Rehabilitation Hospital for further investigation and rehabilitation on October 31, 1985.

Y.Y. was alert and cooperative in examinations, although his face was somewhat expressionless. He was disorientated in time and space because of amnesia, but his general intelligence was not grossly impaired. A right homonymous hemianopia was demonstrated on confrontation. The other cranial nerves were normal.

Tendon reflexes in both lower limbs were moderately exaggerated but there was no right-left difference. Pathological reflexes and ankle clonus were absent. Muscle tone was normal. He was not ataxic. Although showing neither gross paresis nor definite sensory loss, he demonstrated a small stepped 'arteriosclerotic'

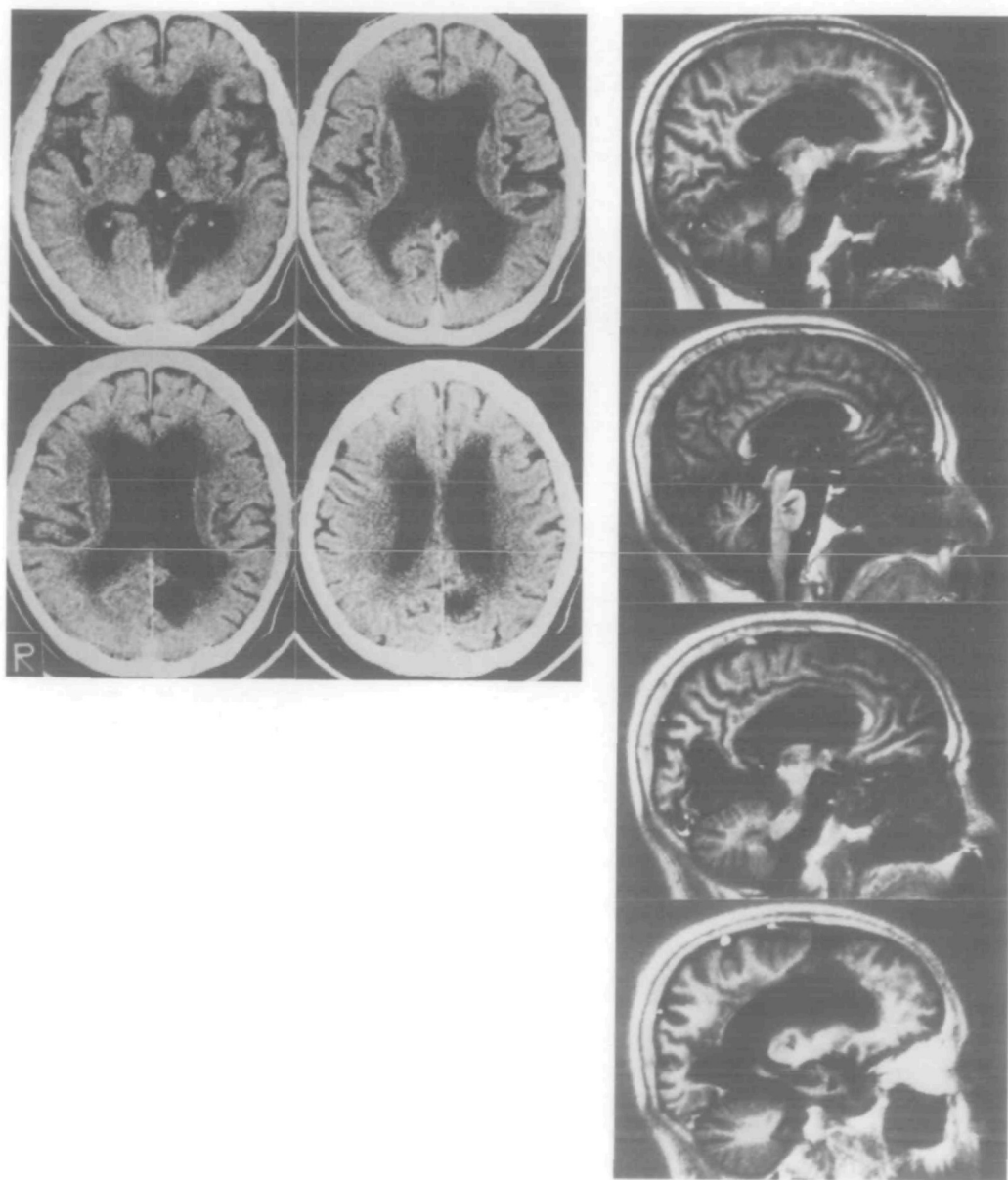


FIG. 1. *Left*: CT scans (December 3, 1985), *Right*: MRI sagittal planes (February 20, 1986). IR method: TR = 2100 ms, TI = 600 ms, from the top, 1.2 cm to the right of the median plane, the median plane, 1.2 cm to the left, and 2.4 cm to the left.

gait (démarche à petit pas) with a freezing phenomenon in the right leg and desynchronization in manual pronation-supination diadochokinesis. No grasping reflexes were demonstrable.

The CT (December 3, 1985) and MRI scans (February 20, 1986) showed lesions situated in the posterior half of the genu, the whole trunk of the corpus callosum, the posterosuperior portion of the left medial frontal lobe, and in the left medial temporo-occipital lobes (fig. 1). Spots of low density were also found in the basal ganglia bilaterally, the thalamus and the pons.

Neuropsychologically, Y.Y. showed marked ideomotor apraxia, agraphia, and tactile anomia confined to the left hand. Apraxia was conspicuous in response to oral commands resulting in perseveration, but improved slightly on imitation. He could manipulate objects without difficulty. His agraphia did not improve with the use of anagram kanji and kana. Diagonistic apraxia was also observed. For example, the left hand tried to grasp a pencil held with the right hand with which he intended to write. He exhibited neither auditory extinction to nonverbal or verbal stimuli, nor tactile extinction when manual responses were required. However, when verbal responses were required, auditory or tactile stimuli to the left ear or hand were almost completely extinguished in bilateral simultaneous stimulation tests. The details of these phenomena, designated as 'apparent extinction', were reported by Nishikawa *et al.* (1988). Visuomotor ataxia (ataxie optique) was present with the right hand in the left visual hemifield. Only the left hand demonstrated marked difficulties in forming rhythmic patterns. Details of this symptom have been reported previously (Kashiwagi *et al.*, 1989). These findings led us believe that he had a callosal disconnection syndrome. He was not aphasic from the beginning of our observation, but we are uncertain whether he had been at an earlier stage. According to the WAIS, his verbal IQ was 63 and his performance IQ was off scale with either hand. His verbal IQ was poorer than expected, but he could cope with an intellectual conversation when he was spoken to.

## INVESTIGATIONS ON HEMISPATIAL NEGLECT

On admission (November 1985), we observed that Y.Y. showed left hemispatial neglect in line cancellation, copying sentences, spontaneous writing when performed with the right hand, and in reading sentences aloud. When asked to copy line drawings, his right hand demonstrated hemispatial neglect on the left side of the drawings, and constructional disturbances and perseveration in the right half of the copied drawings. His left hand seemed to display no neglect although the details were not clearly drawn.

His left hand showed conspicuous agraphia, producing completely unintelligible scrawls in spontaneous writing. His performance in copying characters with the same hand was slightly better. Later (September 1986), his left hand improved for copying characters to such a degree that we could conduct further studies. The following investigations were conducted from September 1986 to December 1987. He had no further attacks or changes in his general condition or neuropsychological state from the time of admission to the end of 1987.

### *Copying line drawings: complete figures (November 1986)*

#### *Methods*

Y.Y. was asked to sit in front of a desk so that the line of his shoulders was parallel to the front edge of the desk. He was then asked to copy black line drawings (5×5 cm). Model drawings had been made on the upper half of a sheet of white paper (18×13 cm) and he was to draw under the model on the same sheet. The drawings employed for models were a crab and a butterfly (*see* fig. 2). The stimulus sheet was placed on the desk in three different spatial positions, i.e., centrally, right hemispace and left hemispace (as suggested by Heilman *et al.*, 1984). In the central space, the stimulus sheet was aligned with the midline of the patient's body. In the right hemispace, it was placed on the desk so that the midline of the sheet was aligned at 45° to his body. In the left hemispace, it was placed in a corresponding position to the left. A total of 6 trials (2 drawings × 3 spatial positions) was performed with each hand.

### Results

As fig. 2 shows, the fundamental characteristics of the copied drawings did not vary with drawing or spatial position. The left hand showed no neglect, whereas the right displayed almost complete neglect on the left side. Constructional disturbances and perseveration were also discernible in the copies made with the right hand. The patient spoke very little while copying and made no reference to the neglected part of his own copies. He once wrote explanatory words alongside what he had drawn (fig. 2). He often

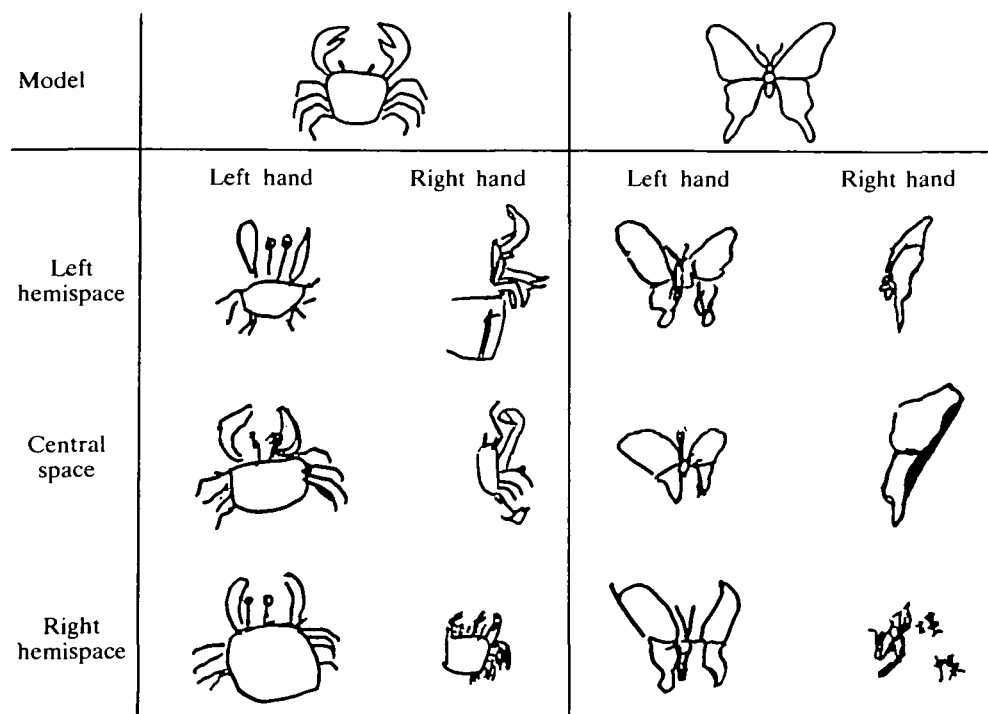


FIG. 2. All the responses in copying complete figures, edited for demonstration. The Chinese characters (kanji) read as 'choucho' (a butterfly) were written by the patient alongside one of his copies (right hemisphere: right hand).

exhibited signs of irritation, saying that he had not been able to copy well as he had been poor at drawing before his illness. When asked how well his copies had been executed, he commented 'They were done badly'. His wife said that he had not been good at drawing.

### *Copying line drawings: half figures (August 1987)*

In order to determine whether the attention of the left hemisphere was restricted to the right half of figures under a different experimental condition, a task that involved copying half figures was administered.

### Methods

Half figures were made by bisecting the same drawings as had been employed for copying complete figures. The patient was asked to copy them with each hand. A test sheet was presented only in the central space. The rest of the test procedure was the same as for the copying of complete figures.



### Results

As displayed in fig. 3, almost the same results as for the copying of complete figures were obtained. It was noted that the right hand tended to copy only the right side of the left half models. No evidence was obtained that a half model was copied as a complete figure (Gazzaniga and Smylie, 1984).




FIG. 3. All responses in copying half figures, arranged for display. The smaller drawing of the left half butterfly was drawn for the second time following an instruction to copy again.

### Line bisection (September 1986)

#### Methods

Seated at a desk, the patient was asked to bisect a visually presented, horizontally orientated line drawn in black ink, with each hand using a pencil. The line was 2 mm wide and was placed in the middle of a 12×36 cm sheet of white paper. Five different line lengths (16, 20, 24, 28 and 32 cm) were used. As in the test of copying complete figures, a stimulus sheet was placed on a desk in 3 different spatial positions: central space, right hemispace, and left hemispace. A session comprised 6 blocks, that is, all combinations of hands and spatial positions. Both the blocks in a session and the 5 lines in each block were randomized. The distance between the estimated and actual midpoints was measured to the nearest millimetre and was expressed as a rate of deviation or a percentage of the half length of a corresponding line. Deviations to the left of the actual midpoint were assigned a negative value. The session was repeated 2 days later.

#### Results and Discussion

In fig. 4, the black triangles indicate the point that the patient considered to be the midpoint of the line. Mean rates of deviation for two sessions are inserted block by block with a vertical dotted line.

An analysis of variance (ANOVA) for repeated measures was performed on these data with hand (right, left), spatial position (central space, right hemispace, left hemispace), and length of lines (5 lengths) as factors. The results of this analysis revealed that hand and spatial position were significant ( $F(1, 30) = 66.85, P < 0.01$ ;  $F(2, 30) = 17.02, P < 0.01$ , respectively). The length of the lines and all the interactions were not significant.

Based on the line bisection task (16 cm, in the central space) conducted for right-handed normals, Imamura *et al.* (1988) determined the normal range of deviation as less than 9.6% rightward and 8.3% leftward,

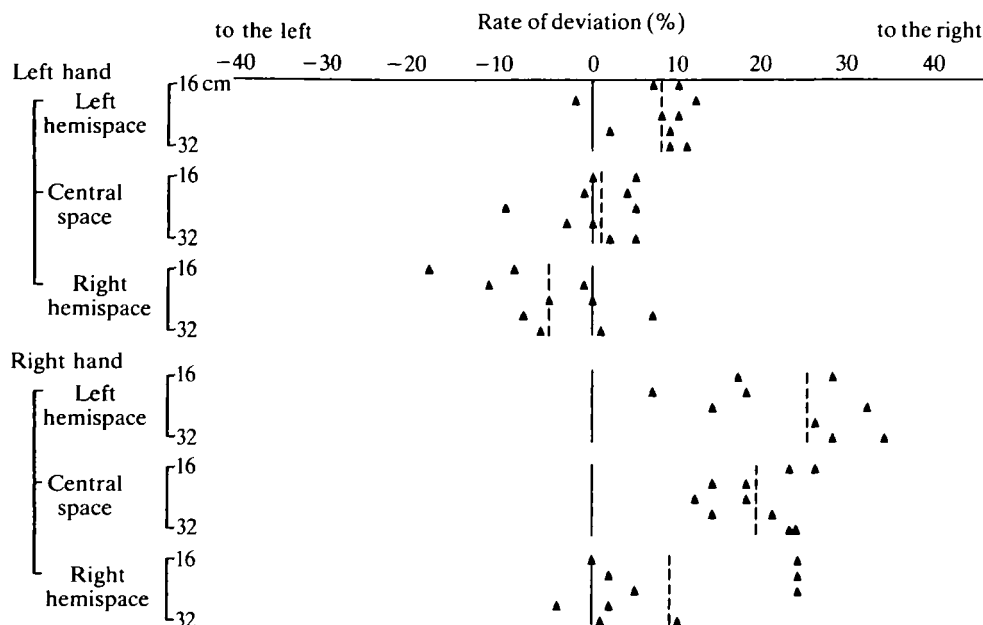


FIG. 4. Deviation rates of line bisection. For each block, deviation rates (%) were calculated in terms of dividing a deviated length by a half length of a line and plotted with black triangles. Dotted lines represent the means, calculated block by block.

regardless of the hand used. Taking these data into consideration, the performance of Y.Y.'s left hand in central space was considered to be normal. Both the rightward deviation in left hemispace and the leftward deviation in right hemispace were slight. On the other hand, performance with the right hand revealed marked deviations towards the right in left hemispace and central space, while deviation was less conspicuous in right hemispace with the right hand. This dissociation between hands could be explained by the weak attentional capacity of the left hemisphere in ipsilateral hemispace.

Heilman *et al.* (1984) summarized the line bisection data of a patient who had a partial callosal disconnection due to cerebral haemorrhage as follows. Each hand appeared to deviate towards its own hemispace and this was most apparent when the hand was required to operate in the contralateral hemispace. The overall tendencies of right-hand performance were similar to the results for Y.Y., whereas those of the left-hand performance differed. It is difficult to determine the relationship between the neglect signs shown by Y.Y. and what Heilman *et al.* designated as 'pseudoneglect'.

#### *Confrontation naming (August 1987)*

Difficulties in naming due to hemispatial neglect were examined with respect to directional attention of the left hemisphere.

#### *Methods*

Twenty familiar drawings, which were symmetric about their vertical midline and easily recognizable, were selected. Some of them were taken from Sasanuma's drawing cards (Sasanuma *et al.*, 1978). Each had four different variants as illustrated in fig. 5. One of the variants was designated as a complete figure, i.e., an original drawing. The second variant was designated as a chimeric figure: 20 right half figures were paired with a left half figure arbitrarily selected. The third variant was a right half figure, which



## Complete figure



Correct	80.0%
Incorrect related	20.0
Total	100.0

## Chimeric figure



		Responses to the right halves			
		Correct	Incorrect		Total
			Related	Don't know	
Responses to the left halves					
Correct		0.0%	0.0	0.0	0.0
Incorrect					
Referred to the left halves					
Unrelated		5.0	2.5	0.0	7.5
Perseverated		5.0	2.5	0.0	7.5
Not referring to the left halves		75.0	5.0	0.0	80.0
Unclassified		0.0	0.0	5.0	5.0
Total		85.0	10.0	5.0	100.0

## Right half figure



Correct	85.0%
Incorrect related	15.0
Total	100.0

## Left half figure



Correct	42.5%
Incorrect	
Related	10.0
Related or perseverated	5.0
Unrelated	5.0
Perseverated	20.0
Don't know	17.5
Total	100.0

FIG. 5. Confrontation naming. Mean percentages correct of each type of response for the total of the two sessions are shown in the tables, and examples of the 4 variations of figure cards are illustrated.

was made by erasing the left half of an original drawing. The final variant was a left half figure, which was made by erasing the right half. All of these figures were drawn in black ink without a line frame, so that the midline of symmetry coincided with the midline of a 9×6 cm card. The cards were presented on the desk one by one so that the midline of the card coincided with the midline of the patient's body. The patient was instructed to name a drawing presented in free vision and to say what he noticed about the drawing. No restriction in response time was imposed. A total of 80 figures were presented randomly. The test was repeated 2 days later, using the same procedure.

Responses for each figure type were classified into the categories listed in fig. 5. Responses which named either a morphological or semantic relationship to a stimulus drawing were classified as 'related'.

### *Results and Discussion*

The results of the 2 tests were almost equal. The mean rates for both were subjected to analysis. The results are listed for each type of response in fig. 5 and summarized as follows. (1) For complete figures, there were 20% incorrect responses, all of which were 'related'. (2) For the chimeric figures, 85% of the right halves were correctly named but, in contrast, none of the left halves was named correctly and 80% were not even referred to. (3) Right half figures tended to be correctly named (85%). (4) The left half figures were named correctly less than half as often as the other types of figures (42.5%). Among incorrect responses, perseveration and 'don't know' responses predominated (20% and 17.5%, respectively).

We interpreted these results as follows. (1) In chimeric figures, Y.Y.'s left hemisphere attended strongly to the right half of a figure but weakly to the left half. High scores were obtained only in response to the information from the right half. (2) In naming right half figures, good scores were obtained. According to the earlier results of copying right half figures with his right hand, Y.Y. attended predominantly to the right half of a right half figure. It can be surmised that when the left hemisphere was ready for confrontation naming, the rightward field of attention for right half figures was narrower than that for chimeric figures. Nevertheless, the scores of right half figures and the right half of chimeric figures were the same. He could presumably command enough information for naming from the right half of right half figures, given the symmetric nature of the object whose distinctive visual features were lateralized to the periphery. (3) In naming left half figures, we presume that Y.Y. attended only to the right side of left half figures. As a result, he was presumably seeing an unfamiliar figure, and this lack of visual information resulted in the poorest scores for all the tasks. Note also that the left half figures were drawn on the left side of the midline of the card in an area to which the left hemisphere was supposed to be poor. Thus the two factors resulting in a paucity of attention to the left side might be responsible for his poor performance in this task. (4) In naming complete figures, Y.Y. produced almost the same number of incorrect responses as in naming chimeric or right half figures. It is supposed that the same amount of decrease in information, or the neglect of the left side, might affect the naming processes. All the incorrect responses were morphologically and semantically related, that is, when enough information for naming was not available from the part to which he attended, he misnamed it. (5) All of these phenomena suggested that Y.Y. had a naming deficit due to left hemispatial neglect. The left hemisphere probably had a reduced attention capacity directed to ipsilateral hemispace.

### *Matching identical figures (December 1987)*

To examine further the characteristics of hemispatial neglect in the visual processes where the influence from kinetic bias was minimized, a task involving the matching of identical figures was performed. Discriminative information was placed in only one half of the figure: left half identification (LHI) and right half identification (RHI).

### *Methods*

Y.Y. was asked to point, with each hand, to the figure identical to a stimulus figure among 4 choices on a multiple-choice board. A multiple-choice board was placed on the desk in front of him and on the

## Left half identification (LHI)      Right half identification (RHI)

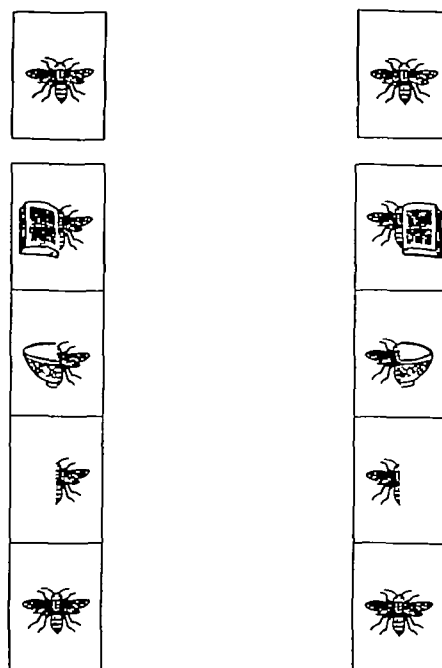


FIG. 6. Examples of a stimulus and multiple-choice board for left half identification (LHI) and right half identification (RHI) in matching identical figures.

top of it was placed a stimulus board. In LHI, as shown in fig. 6, the right halves of the 4 figures on a multiple-choice board were all identical with the right half of a stimulus figure so that distinctive information for the identification was lateralized to the left halves of the figures. Figures for RHI were prepared so as to be symmetrical to LHI figures. The remaining conditions were identical.

Five symmetric and easily recognizable drawings (9×6 cm) of common objects (a bee, a hat, a bell, a tree, and Chinese noodles in a bowl) were prepared. For the LHI task, 3 kinds of stimulus figures and 3 kinds of multiple-choice boards per drawing were prepared. A right half figure, a chimeric figure (a right half figure attached to the left half figure of a different drawing), and a complete figure (an original drawing) were employed for stimulus figures. The multiple-choice board contained 4 choices: the 3 figures as were used for a stimulus, plus 1 additional chimeric figure. These 4 choices were aligned vertically to avoid horizontal bias due to directional neglect and were distributed in each position once through the 3 boards so that distributional bias could be avoided. The 3 multiple-choice boards were paired randomly with 1 of the 3 stimulus boards for matching. Thus 15 sets (3 stimulus boards × 5 drawings) were prepared. Completely identical sets were prepared for the RHI task.

The vertical midlines of the stimulus board and the multiple-choice board were always set on the desk coinciding with Y.Y.'s midline to minimize the influence of lateral movements in visual searching and pointing with hands.

The 30 trials (15 sets each of LHI and RHI) were randomized and performed with randomly ordered right-hand and left-hand pointing. Response time was measured. The test was repeated 3, 6 and 9 days later.

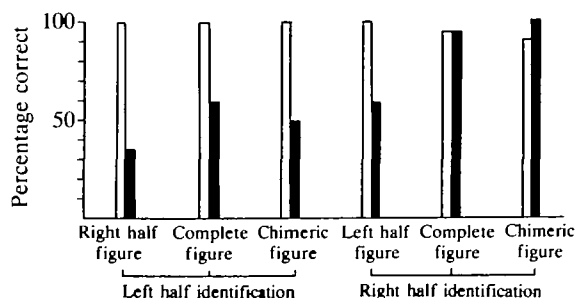


FIG. 7. Matching identical figures. Mean percentages for the total of correct responses in the four sessions. Open column = left hand; closed column = right hand.

### Results and Discussion

Since Y.Y. correctly performed almost all trials within 5 s with his left hand, we gave 1 point for a correct response produced within 5 s. Otherwise, no point was given. The mean scores of the four sessions are charted in fig. 7. ANOVA for repeated measures was performed on these data by hand (right, left), type of identification (LHI, RHI), stimulus figure (half, complete, chimera), and drawing (5 objects) as factors. The results were as follows. (1) Hand, type of identification, and the interaction between these 2 factors were significant ( $F(1, 3) = 21.07, P < 0.05$ ), ( $F(1, 182) = 15.44, P < 0.01$ ) and ( $F(1, 182) = 26.74, P < 0.01$ ), respectively. (2) The stimulus figure was also significant ( $F(2, 182) = 4.41, P < 0.05$ ). (3) An interaction between hand and stimulus figure was significant ( $F(2, 182) = 7.23, P < 0.01$ ). (4) The drawing was not significant. (5) The other interactions were not significant. Tukey's multiple comparisons among the percentages correct for the 6 conditions revealed the following. (6) The left hand responded moderately well under all of the 6 conditions (3 stimulus figures  $\times$  2 identification types) and showed no significant differences among them. (7) The right hand responded well to the complete and chimeric figures in RHI. There was no significant difference between them. However, if compared with the performances under these two conditions, the performances under the other 4 conditions (left half figures in RHI and 3 kinds of figures in LHI), among which there were no significant differences, decreased significantly ( $P < 0.01$  for each of the 8 comparisons).

When pointing to a target, Y.Y. moved his right hand slowly and stopped on figures one by one on a multiple-choice board. This tendency was conspicuous in performing left half figure trials in the RHI task and all trials in the LHI task.

Performance of the LHI task presumably reflected the degree of attention to the left halves of figures, since no differential information was placed in the right halves. Similarly, the performance in the RHI task reflected the degree of attention to the right halves of figures. The left hand scored well under any condition. As for responses with the right hand, the decrease in the scores in the LHI task suggested that Y.Y. oriented poorly to the left side. Of all the responses with the right hand in RHI, complete and chimeric figures had the highest averages of correct responses. These results suggest that he demonstrated good attention to the right side even with the right hand. In contrast, the significantly low score for left half figures with the right hand was considered to be attributable to imperfect visual perception, as suggested by the discussion of line bisection and confrontation naming during which he attended poorly to left half figures in the left hemisphere.

### *Copying and reading aloud multiple digit numbers (August 1987)*

The left hand revealed a behaviour that made us suspect mild neglect in right hemispace in copying multiple digit numbers.




FIG. 8. Examples of responses in copying multiple digit numbers.

### Methods

Y.Y. was asked to read aloud and copy numbers involving multiple digits, using a pencil held in either the left or the right hand. The numbers presented were written horizontally, 3 cm from the top, in the centre of a sheet of white paper (18×13 cm). Each digit was written by hand in black ink (2 mm thick), approximately 1.3 cm high and 1 cm wide including the space between digits. The stimulus numbers employed were from 1 to 6 digits. Three arbitrarily selected numbers were employed for every digit number. A total of 18 trials was performed. The order of the stimulus numbers and the hands used to execute the task was randomized. Copying accuracy was evaluated first.

### Results and Discussion

Y.Y. copied the numbers from left to right with either hand. With 1 or 2 digit numbers, he revealed no abnormality with either hand. With more than 4 digits, his right hand neglected the leftmost 1 or 2 digits but copied the rest flawlessly in normal hand writing. In contrast, he successfully copied the leftmost 2–4 digits with his left hand. For the remainder, however, he repeatedly hesitated in his writing and/or wrote agraphically malformed digits which he strenuously tried to correct (fig. 8). In these circumstances, he was instructed to write again from the beginning or to write under the malformed digits. Sometimes anomalous stroke orders were observed that made us infer that he was copying digits as if he were drawing geometric or pictorial figures. The results of oral reading were almost the same as the ones with the right hand: he neglected the leftmost 1 or 2 digits of numbers with more than 4 digits, and read aloud the remainder without difficulty.

The poor replication of the leftmost digits in the multiple digit numbers, both in copying with the right hand and in reading aloud, can be considered in the same light as was observed in the above investigations. However, how can we interpret the poor replication of the rightmost digits while copying with the left hand? Right homonymous hemianopia can hardly explain this symptom because the right hand copied the rightmost digits flawlessly. Agraphia confined to the left hand cannot explain the fact that the same hand was able to copy some digits on the left side. We infer that the weakness in directional attention to the right side may be the cause of this right side symptom.

## GENERAL DISCUSSION

Hemispatial neglect demonstrated by Y.Y. under nonlateralized testing conditions is summarized as follows. First, left hemispatial neglect was invariably shown not only in tasks performed with the right hand such as copying drawings, line bisection, matching identical figures, and copying multiple digit numbers, but also in tasks involving verbal responses such as confrontation naming and reading aloud multiple digit numbers. Secondly, equivocal right hemispatial neglect became apparent only when the left hand was mobilized for copying multiple digit numbers. Thus it is clear that conspicuous left hemispatial neglect occurred relative to the activities of the left hemisphere and little or no right hemispatial neglect occurred in relation to the activities of the right hemisphere. Since an apparent decrease in his responses to the left side was confirmed in the tasks where horizontal movement in visual searching and in pointing with the hands was minimized, such as in confrontation naming and matching identical figures, Y.Y.'s left-sided neglect was considered to be based on attentional deficits.

How can we interpret this symptom complex? Obviously, right homonymous hemianopia is not the explanation for the manifestation of severe neglect on the left side, because the hemispace in which salient neglect showed up was not on the right side. This suggests that neglect is not a mere sensory disturbance.

Secondly, it may be argued that the hemispatial neglect observed in Y.Y. was caused by unilateral intrahemispheric lesions. Certainly, there were low density spots which were considered to be lesions in the basal ganglia and thalamus of both hemispheres and the left medial frontal and temporo-occipital lobes. In the literature, left hemispatial neglect has been documented in association with damage in the region of the basal ganglia on the right (Damasio *et al.*, 1980), in the subcortical frontal lobe and basal ganglia on the right (Stein and Volpe, 1983), in the posterior limb of the right internal capsule (Ferro and Kertesz, 1984), and in the right thalamus (Watson and Heilman, 1979). Nevertheless, it seems difficult to ascribe left hemispatial neglect in our patient to the spots of low density in the right basal ganglia and thalamus. If these lesions are responsible for the development of left-sided neglect demonstrated conspicuously by left hemisphere activities, provided that the corpus callosum was intact then right hemisphere activities may be associated with left-sided neglect as well. In fact, the left hand did not show any left-sided neglect. Joannette *et al.* (1986) have observed that left-sided neglect was less severe with the left hand than with the right in right brain-damaged individuals with the least hemiparesis. The data for their 3 patients indicated that the left hand still showed prominent although less severe neglect. Weintraub and Mesulam (1987) also reported that manual exploration in patients with right hemisphere lesions, in whom the left hand was completely mobile, was less efficient within contralateral hemispace, regardless of the hand used. Furthermore, the cases of Sine *et al.* (1984) and Goldenberg (1986), who showed neglect signs confined to the right hand responses as well as varieties of callosal disconnection symptoms, had no lesion in the basal ganglia in either hemisphere. In light of these views, we surmise that Y.Y.'s left hemispatial neglect



confined to left hemisphere activities is not attributable to the small hemisphere lesions.

Right hemispatial neglect, on the other hand, shown in left hand performance, if any, might be ascribed to the lesions in the parasagittal areas and/or the basal ganglia of the left hemisphere (Damasio *et al.*, 1980). If the right-sided neglect was a left hemisphere sign, there remains a question why left hemisphere activities did not demonstrate such right-sided neglect. This will be discussed later. In summary, marked dissociated manifestations of neglect between right and left hemisphere activities led us to infer that the neglect signs observed in Y.Y. could not be explained solely by his intrahemispheric lesions.

The remaining possibility is an interhemispheric disconnection. Note that he demonstrated various disconnection signs and had extensive lesions in the corpus callosum and the adjacent parasagittal hemisphere. Moreover, the dissociated manifestations of hemispatial neglect found between right and left hemisphere activities were observed. These findings strongly support an interhemispheric disconnection, which presupposes asymmetric cerebral representations of directed attention.

An adequate model of directed attention should be equipped with an explanation not only for the asymmetric manifestations of hemispatial neglect resulting from damage to the right or left hemispheres but also for such dissociated manifestations of neglect as observed in Y.Y. and the cases of Sine *et al.* (1984) and Goldenberg (1986). The asymmetrically directed attention model postulated by Heilman *et al.* (1980) and Mesulam (1981) explains the above two phenomena. This model may be compatible with the findings of Joannette *et al.* (1986) and Nishikawa *et al.* (1987) that the left hand tends to show milder left hemispatial neglect than the right hand in patients with right hemisphere damage. The contralaterally directed attention model with left hemisphere preponderance advocated by Kinsbourne (1977) fails to explain why, in our patient, right hemisphere activities were accompanied by little or no neglect in the right hemispace. The contralaterally directed symmetric attention model of Heilman *et al.* (1984) also fails to explain the same phenomenon. The bilaterally directed symmetric attention model of Plourde and Sperry (1984) also cannot explain the dissociated hemispatial neglect exhibited by Y.Y.

If such an asymmetry exists in the cerebral representation of directed attention, then it can be surmised that the brain is equipped with mechanisms for transmitting directed attention between the right and left hemispheres and also for modulating the whole. Suppose that the anatomical apparatus for the transmission is disturbed. The subject would have to depend predominantly on the left hemisphere when verbal or right manual performance was required. In this state, only the right-sided attention of the left hemisphere is activated while the bilateral attention of the right hemisphere is inhibited, thus resulting in the exclusion of left-sided attention. By the same logic, the subject has to depend on the right hemisphere when left manual performance is required. In this state, only the bilateral attention of the right hemisphere is activated while the right-sided attention of the left hemisphere is inhibited. As a result, the total amount of the right-sided attention may be decreased to some extent. Y.Y.'s symptomatology is

consistent with these presuppositions and we may well interpret his neglect symptoms as a reflection of disturbances in the reciprocal transmission of attentional competence between the two hemispheres.

We should comment on the observation that the left hand showed mild right-sided neglect in copying multiple digit numbers. As discussed earlier, this may be ascribed to the lesions in the left medial frontal lobe. However, it is more likely that the right-sided neglect shown only by the left hand is also reflected by an interhemispheric disconnection. The capacity of the right hemisphere is preponderant in attending to the contralateral hemispace than to the ipsilateral hemispace where, as Mesulam (1981) anticipated, the left hemisphere is more preponderant. Thus we consider that the disconnection neglect syndrome, if any, has two types of neglect which are independently reflected by the shortage of the attentional capacities in each hemisphere. Further investigation is necessary to determine the capacity of the right hemisphere in ipsilateral hemispace.

How did the lesions in Y.Y. interfere with the transmission and modulation of directed attention? In light of the studies on commissurotomy patients, the lesions confined to the corpus callosum are unlikely to develop disconnection neglect. Y.Y., in common with the patients of Sine *et al.* (1984) and Goldenberg (1986), possessed lesions in the corpus callosum and medial frontal lobes. Y.Y. and the patient of Sine *et al.* (1984) had lesions in the medial part of the left frontal lobe, and the patient of Goldenberg (1986), bilaterally in the frontal lobes. It may be possible that intrahemispheric involvement, together with callosal involvement, is relevant to the occurrence of disconnection neglect. A similar view has been advanced with regard to disconnection apraxia. Yamadori (1985) pointed out that patients with spontaneous lesions in the corpus callosum, apparently accompanied by left hemisphere lesions, seem to develop far more severe apraxia than commissurotomy patients. The importance of medial frontal lobe damage for apraxia of the left limbs was also emphasized by Goldenberg *et al.* (1985).

Two reported cases with callosal lesions due to cerebrovascular disease have come to our attention. The patient of Heilman *et al.* (1984) showed the symptom designated as 'hemialexia' in reading compound words 3 days after the onset, which is presumably interpreted as a sign of left hemispatial neglect. Forty-four days after the ictus, these authors confirmed that the patient had no signs of hemispatial neglect. Meanwhile, improvement was also observed in language disturbance, palpatory naming difficulty with the left hand, difficulty in copying the alphabet with the left hand, and proximal leg weakness, which was presumed to have been caused by severe spasm of both anterior cerebral arteries. As the CT and MRI scans (Watson *et al.*, 1985) disclosed no evidence of cortical involvement, including the supplementary motor and cingulate cortices, the neuropsychological signs that subsided in the acute and subacute periods were attributed to transient dysfunction of the medial frontal lobes. Anatomical intactness of these regions might have contributed to her early improvement in 'hemialexia'. The patient of Nishikawa *et al.* (1988), diagnosed as cerebral infarction, did not show hemispatial neglect with either hand according to observations begun 5 wks postonset, although several disconnection signs were noted. The MRI studies disclosed lesions situated in

the genu and trunk of the corpus callosum as well as minor lesions situated in the splenium and subcortically in front of the anterior horn of the left lateral ventricle. No major lesion was found in the medial cortices of either hemisphere. Our inferential argument is indirectly supported by these 2 cases.

The cerebral networks for attention may be represented widely from the brainstem to the forebrain cortex in the whole brain (*see* the network models of Heilman *et al.*, 1985) more widely than those for language. As a result, commissural fibres other than the forebrain commissure take part in the transmission of attentional information. Damasio *et al.* (1980) have suggested that the supplementary motor area and the anterior cingulate gyrus mediate information to and from the dorsolateral structures of the frontal lobe and subcortical components of the limbic system. Presumably, Y.Y.'s lesions in the left medial frontal lobe prevented transmission through the extracallosal commissures, which are spared in commissurotomy patients. It may be possible that lesions in the right medial frontal lobe play an identical role in producing disconnection neglect. Thus we propose that disconnection neglect would be attributable to a combination of lesions in the corpus callosum and in the medial frontal lobe.

On the basis of the discussion above, the following conclusions are derived. (1) The neglect symptoms observed in right manual and verbal performance provide evidence that the human capacity of directed attention is asymmetrically represented in the hemispheres. The right hemisphere is responsible for bilateral hemispaces although, possibly, less preponderant in the ipsilateral hemispace, while the left hemisphere only for the contralateral hemispace. (2) Hemispatial neglect may manifest as a disconnection sign in patients with callosal lesions resulting from cerebrovascular disease. It is suggested that a combination of lesions in the corpus callosum and in the medial frontal lobe is responsible for its manifestation, so that the capacities of directed attention represented in each hemisphere cannot be transmitted to the contralateral hemisphere.

#### ACKNOWLEDGEMENTS

The authors are greatly indebted to Drs Tsuyoshi Nishimura, Junzo Shiraishi (Osaka University), Atsushi Yamadori, Etsuro Mori (Hyogo Brain and Heart Center at Himeji), Keiich Takeda (Osaka University of Education), Tetsuro Kamino and Kenzo Kiso (Kyoritsu Hospital) for their valuable comments and cooperation and to Mrs Hiroko Ashida for preparing the English manuscript. We also acknowledge the sincere cooperation of Mr and Mrs Y.Y. during the investigation. The observations were presented at the 11th and 12th annual meetings of the Neuropsychology Association of Japan, in Tokyo in September 1987 and in Fukuoka in September 1988, and to the International Neuropsychology Society in Antwerp in July 1989.

#### REFERENCES

- ALBERT ML (1973) A simple test of visual neglect. *Neurology, Minneapolis*, **23**, 658–664.
- BOGEN JE (1985) Split-brain syndromes. In: *Handbook of Clinical Neurology*, Volume 45. Edited by P. J. Vinken, G. W. Bruyn and H. L. Klawans. Amsterdam: Elsevier, pp. 99–106.
- COSTA LD, VAUGHAN HG, HORWITZ M, RITTER W (1969) Patterns of behavioral deficit associated with visual spatial neglect. *Cortex*, **5**, 242–263.
- DAMASIO AR, DAMASIO H, CHUI HC (1980) Neglect following damage to frontal lobe or basal ganglia. *Neuropsychologia*, **18**, 123–132.

- DE RENZI E, FAGLIONI P, SCOTTI G (1970) Hemispheric contribution to exploration of space through the visual and tactile modality. *Cortex*, **6**, 191–203.
- DIMOND SJ (1976) Depletion of attentional capacity after total commissurotomy in man. *Brain*, **99**, 347–356.
- FERRO JM, KERTESZ A (1984) Posterior internal capsule infarction associated with neglect. *Archives of Neurology, Chicago*, **41**, 422–424.
- FRIEDLAND RP, WEINSTEIN EA (1977) Hemi-inattention and hemisphere specialization: introduction and historical review. *Advances in Neurology*, **18**, 1–31.
- GAINOTTI G, MESSERLI P, TISSOT R (1972) Qualitative analysis of unilateral spatial neglect in relation to laterality of cerebral lesions. *Journal of Neurology, Neurosurgery and Psychiatry*, **35**, 545–550.
- GAZZANIGA MS, SMYLLIE CS (1984) What does language do for a right hemisphere? In: *Handbook of Cognitive Neuroscience*. Edited by M. S. Gazzaniga. New York: Plenum Press.
- GOLDENBERG G (1986) Neglect in a patient with partial callosal disconnection. *Neuropsychologia*, **24**, 397–403.
- GOLDENBERG G, WIMMER A, HOLZNER F, WESSELY P (1985) Apraxia of the left limbs in a case of callosal disconnection: the contribution of medial frontal lobe damage. *Cortex*, **21**, 135–148.
- GORDON HW, BOGEN JE, SPERRY RW (1971) Absence of deconnection syndrome in two patients with partial section of the neocommissures. *Brain*, **94**, 327–336.
- HEILMAN KM, VALENSTEIN E (1979) Mechanisms underlying hemispatial neglect. *Annals of Neurology*, **5**, 166–170.
- HEILMAN KM, VAN DEN ABELL T (1980) Right hemisphere dominance for attention: the mechanism underlying hemispheric asymmetries of inattention (neglect). *Neurology, Cleveland*, **30**, 327–330.
- HEILMAN KM, BOWERS D, WATSON RT (1984) Pseudoneglect in a patient with partial callosal disconnection. *Brain*, **107**, 519–532.
- HEILMAN KM, VALENSTEIN E, WATSON RT (1985) The neglect syndrome. In: *Handbook of Clinical Neurology*, Volume 45. Edited by P. J. Vinken, G. W. Bruyn and H. L. Klawans. Amsterdam: Elsevier, pp. 153–183.
- HOLTZMAN JD, SIDTIS JJ, VOLPE BT, WILSON DH, GAZZANIGA MS (1981) Dissociation of spatial information for stimulus localization and the control of attention. *Brain*, **104**, 861–872.
- IMAMURA Y, UEMURA K, RYU H, KOJIMA Y, KANEKO M (1988) A line bisection test—experimental studies (in Japanese). Paper presented to the annual meeting of Neuropsychological Association of Japan, Tokyo. *Shinkei Shinrigaku*, **4**, 158 (abstract).
- JOANETTE Y, BROUCHON M, GAUTHIER L, SAMSON M (1986) Pointing with left vs right hand in left visual field neglect. *Neuropsychologia*, **24**, 391–396.
- JOYNT RJ (1977) Inattention syndromes in split-brain man. *Advances in Neurology*, **18**, 33–39.
- KASHIWAGI A, KASHIWAGI T, NISHIKAWA T, OKUDA J-I (1989) Hemispheric asymmetry of processing temporal aspects of repetitive movement in two patients with infarction involving the corpus callosum. *Neuropsychologia*, **27**, 799–809.
- KINSBOURNE M (1977) Hemi-neglect and hemisphere rivalry. *Advances in Neurology*, **18**, 41–49.
- MESULAM M-M (1981) A cortical network for directed attention and unilateral neglect. *Annals of Neurology*, **10**, 309–325.
- MESULAM M-M (1985) Attention, confusional states, and neglect. In: *Principles of Behavioral Neurology*. Edited by M.-M. Mesulam. Philadelphia: F. A. Davis, pp. 125–168.
- NISHIKAWA T, TABUSHI K, KOIZUMI K, OKUDA J, NISHIMURA T, TANABE H, SHIRAISHI J (1987) Significance of the response modes in unilateral spatial agnosia—difference between hands in line bisection (in Japanese). *Shinkei Shinrigaku*, **3**, 148 (abstract).
- NISHIKAWA T, TANABE H, OKUDA J, KASHIWAGI T, KASHIWAGI A (1988) Extinction in cases of callosal disconnection—‘apparent extinction’ and some additional findings in dichotic listening tests. *Shinkei Shinrigaku*, **4**, 33–46 (in Japanese).
- PLOURDE G, SPERRY RW (1984) Left hemisphere involvement in left spatial neglect from right-sided lesions: a commissurotomy study. *Brain*, **107**, 95–106.

- SASANUMA S, ITOH M, WATAMORI T, FUKUSAKO Y, MONOI H (1978) *Shitsugosho no Gengo-chiryō* (in Japanese. Language Therapy for Aphasia). Tokyo: Igaku Shoin, Appendix.
- SINE RD, SOUFI A, SHAH M (1984) Callosal syndrome: implications for understanding the neuropsychology of stroke. *Archives of Physical Medicine and Rehabilitation*, **65**, 606–610.
- SPERRY RW, GAZZANIGA MS, BOGEN JE (1969) Interhemispheric relationships: the neocortical commissures; syndromes of hemisphere disconnection. In: *Handbook of Clinical Neurology*, Volume 4. Edited by P. J. Vinken and G. W. Bruyn. Amsterdam: North-Holland, pp. 273–290.
- STEIN S, VOLPE BT (1983) Classical 'parietal' neglect syndrome after subcortical right frontal lobe infarction. *Neurology, Cleveland*, **33**, 797–799.
- WATSON RT, HEILMAN KM (1979) Thalamic neglect. *Neurology, New York*, **29**, 690–694.
- WATSON RT, HEILMAN KM, BOWERS D (1985) Magnetic resonance imaging (MRI, NMR) scan in a case of callosal apraxia and pseudoneglect. *Brain*, **108**, 535–536.
- WEINTRAUB S, MESULAM M-M (1987) Right cerebral dominance in spatial attention: further evidence based on ipsilateral neglect. *Archives of Neurology, Chicago*, **44**, 621–625.
- WILSON DH, REEVES A, GAZZANIGA M, CULVER C (1977) Cerebral commissurotomy for control of intractable seizures. *Neurology, Minneapolis*, **27**, 708–715.
- YAMADORI A (1985) *Shinkei Shinrigaku Nyūmon* (in Japanese. Introduction to Neuropsychology). Tokyo: Igaku Shoin, pp. 307–327.

(Received January 25, 1989. Revised August 8, 1989. Accepted August 16, 1989)

#### ADDENDUM

After this paper was accepted, we noticed further evidence for right hemispatial neglect in tasks of copying line-drawn cubes performed in October 1986 and May 1987 (fig. 9). A test sheet was presented only in central space and the rest of the procedures was the same as for testing the copying of line drawings (complete figures) as in the original report. Performances of the left hand were poor for the right side of the cubes. These observations are most likely based on the same mechanism as was inferred from the results in copying multiple digit numbers and thus further support our argument that the right hemisphere is less dominant in the ipsilateral hemispace.

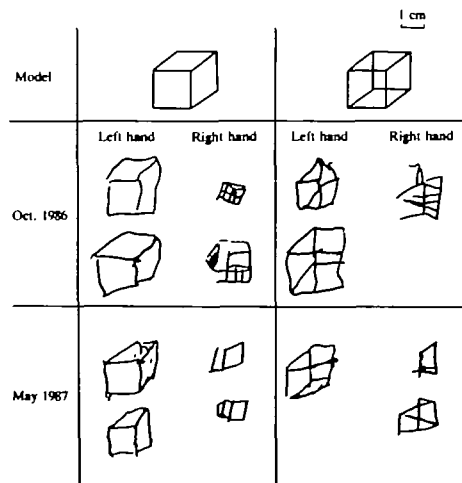


FIG. 9. YY's responses in copying line-drawn cubes, edited for demonstration.