

Neurocase: The Neural Basis of Cognition

Publication details, including instructions for authors and subscription information:

<http://www.tandfonline.com/loi/nncs20>

Impaired reading not due to visual field loss in a patient with a right-hemispheric lesion

Benedetta Basagni^{ab}, Ivan Patané^c, Vera Ferrari^c & Nicola Bruno^c

^a Centro S. Maria ai Servi, Fondazione Don Carlo Gnocchi, Parma, Italy

^b Centro Cardinal Ferrari, S. Stefano Riabilitazione, Fontanellato, Parma, Italy

^c Dipartimento di Neuroscienze, Università degli Studi di Parma, Parma, Italy

Published online: 28 Aug 2013.



[Click for updates](#)

To cite this article: Benedetta Basagni, Ivan Patané, Vera Ferrari & Nicola Bruno (2014) Impaired reading not due to visual field loss in a patient with a right-hemispheric lesion, *Neurocase: The Neural Basis of Cognition*, 20:5, 510-523, DOI: [10.1080/13554794.2013.826684](https://doi.org/10.1080/13554794.2013.826684)

To link to this article: <http://dx.doi.org/10.1080/13554794.2013.826684>

PLEASE SCROLL DOWN FOR ARTICLE

Taylor & Francis makes every effort to ensure the accuracy of all the information (the "Content") contained in the publications on our platform. However, Taylor & Francis, our agents, and our licensors make no representations or warranties whatsoever as to the accuracy, completeness, or suitability for any purpose of the Content. Any opinions and views expressed in this publication are the opinions and views of the authors, and are not the views of or endorsed by Taylor & Francis. The accuracy of the Content should not be relied upon and should be independently verified with primary sources of information. Taylor and Francis shall not be liable for any losses, actions, claims, proceedings, demands, costs, expenses, damages, and other liabilities whatsoever or howsoever caused arising directly or indirectly in connection with, in relation to or arising out of the use of the Content.

This article may be used for research, teaching, and private study purposes. Any substantial or systematic reproduction, redistribution, reselling, loan, sub-licensing, systematic supply, or distribution in any form to anyone is expressly forbidden. Terms & Conditions of access and use can be found at <http://www.tandfonline.com/page/terms-and-conditions>

Impaired reading not due to visual field loss in a patient with a right-hemispheric lesion

Benedetta Basagni^{1,2}, Ivan Patané³, Vera Ferrari³, and Nicola Bruno³

¹Centro S. Maria ai Servi, Fondazione Don Carlo Gnocchi, Parma, Italy

²Centro Cardinal Ferrari, S. Stefano Riabilitazione, Fontanellato, Parma, Italy

³Dipartimento di Neuroscienze, Università degli Studi di Parma, Parma, Italy

We describe a right-handed patient (M.B.), who developed left hemianopsia and a severe reading impairment after right occipital–parietal hemorrhage. The pattern of his reading deficit was very similar to that of pure alexia (alexia-without-agraphia): extremely slow reading times with frequent grapheme substitutions and omissions. A test of letter reading while controlling for saccadic eye movements and hemifield of presentation ruled out hemianoptic alexia. Although there have already been reports of reading impairments in right handers following right-hemispheric lesions, ours is, to the best of our knowledge, the first where visual field loss can be definitely excluded as the main cause. Based on a standard neuropsychological assessment and on additional behavioral tests, we argue that M.B.'s difficulties are unlikely to be due to right-hemisphere dominance for language. After considering several candidate explanations, we suggest that M.B.'s symptoms may be related to an impairment in attentional processes related to reading.

Keywords: Pure alexia; Alexia-without-agraphia; Hemianoptic alexia; Right lesion.

Pure alexia (alexia-without-agraphia) is a severe reading disorder seen in patients that maintain relatively intact writing abilities (see Damasio, 1983; Déjerine, 1914; Montant & Behrmann, 2000). Observed deficits range from the inability to name even single letters (Déjerine, 1892) to slow, laborious reading based on the sequential integration of the letter names (see Cohen et al., 2004). Neuroimaging studies and patient data converge in suggesting that pure alexia is associated to lesions to the visual word form area (VWFA) within the left occipito-temporal sulcus (for reviews, see Damasio, 1983; McCandliss, Cohen, & Dehaene, 2003; Montant & Behrmann, 2000).

Despite ample evidence that the left VWFA is the critical lesion site for alexia, there have been occasional reports of alexic patients after right-hemispheric lesions. We have been able to locate nine such reports involving non-right-handed (Erkylvrawatr, 1978; Pillon, Bakchine, & Lhermitte, 1987; Yamaguchi, Murata, Kobayashi, Katsube, & Tsunematsu, 1984), but also right-handed patients (Estanol et al., 1999; Hirose, Kin, & Murakami, 1977; Mochizuki, Sugishita, Tohgi, & Satoh, 1980; Ogden, 1984; Shipkin, Gray, Daroff, & Glaser, 1981), plus one study where we were unable to determine the patient's handedness (Thomas & Sanford, 2007). Although

Address correspondence to Nicola Bruno, Dipartimento di Neuroscienze, Università di Parma, Borgo Carissimi 10, 43100 Parma, Italy. (E-mail: nicola.bruno@unipr.it).

Based in part on Ivan Patané's undergraduate thesis at the University of Parma. Supported by PRIN 2008RBFNLH and by a start-up grant from the University of Parma, both to the last author. We thank Roberto Cubelli, Carlo Semenza, Eduardo Navarrete, and Eraldo Paulesu for suggestions at various stages of this work, Chiara Ciraci for access to control patients, and M.B. for his patience throughout our testing sessions.

it is possible that all these patients were right-dominant for language, the evidence that this was indeed the case remains ambiguous. Hirose et al. (1977) reported that in their patient the right hemisphere was dominant for verbal sounds. Two other papers included explicit tests ruling out right-hemispheric dominance (Erkylvrawatr, 1978; Estanol et al., 1999). In addition, seven of these cases had occipital or parietal lesions, or both, with no involvement of right temporal areas. Thus, these reports remain a potential challenge for our current understanding of brain networks involved in reading.

Alternatively, reading impairments in these patients may be due to visual field loss. Occipital damage in one hemisphere typically causes homonymous hemianopsia, which is associated to reading difficulties (see e.g., Rowe, et al., 2011). However, lesions affecting the retrochiasmatic visual tract and the primary visual cortex spare half of the visual field and at least half of the fovea. Resulting reading impairments are usually mild. Impairments associated to right hemianopsia can produce reading difficulties (hemianoptic alexia), as the location of the scotoma interferes with rightward scanning eye movements (see e.g., Leff et al., 2000). Patients with left hemianopsia, however, are disturbed only in the return eye movements to the beginning of a new line, and usually learn to compensate (see Pambakian & Kennard, 1997). Still, because previous reports of pure alexia in right-hemispheric patients did not include controlled tests of reading in the spared hemifield, a causal role of hemianopsia cannot be ruled out, possibly in association with oculomotor impairments.

We report a novel case of reading impairment following a right-hemispheric lesion. This case is interesting, as the associated clinical picture is quite rare. Tests of reading while controlling visual field loss and eye movements provided evidence of frequent errors in the spared hemifield. Thus, we could definitely rule out hemianoptic alexia as the cause of the deficit. After several additional tests, we also ruled out damage at early perceptual processes. The site of the lesion as well as the neuropsychological assessment argued against right-hemispheric dominance for language. Thus, we suggest that this case provides novel evidence that symptoms similar to those of pure alexia can be observed following lesions outside the areas classically implied in visual word recognition. We speculate that such impairments may be due

to the damage to right-lateralized centers responsible for attentional processing of text chunks while reading.

CASE REPORT

M.B. is a 67-year-old right-handed male with 8-year schooling (he holds a 5-year elementary degree, compulsory at the time of his youth, plus a 3-year intermediate degree). Formerly employed as a television cameraman, he worked as manager of a children's merry-go-round in a city park, and is currently retired. On 7 July 2010, he suffered a brain hemorrhage. M.B. came to our attention 7 months after the stroke, when he began rehabilitation at the Parma Center of the *Don Gnocchi* Foundation. On December 2011, he declined to continue the program due to additional health problems.

M.B.'s motivation for entering the program was a marked difficulty in reading. Informal observations confirmed that M.B. was slow and made frequent errors even when reading single words. When presented with a sentence, he generally became too frustrated to even attempt a guess. However, he had normal ability to copy words, wrote normally both spontaneously and under dictation, had good comprehension of spoken language, and could reconstruct a word from its verbally spelled letters.

BACKGROUND ASSESSMENTS

Anatomical evidence

A morphological MR scan performed 3 weeks after the stroke (see Appendix) exhibited an extended lesion encompassing all the right occipital lobe from the interhemispheric fissure to the temporo-occipital junction, a temporo-occipital intraparenchymal hematoma, and more focal lesions at the level of the right posterior parietal cortex. The right fusiform gyrus did not appear to be affected. There was no sign of left lesion. The parietal lesions may be due at least in part to craniotomy in relation to surgery underwent by M.B. in 1967 to remove a benign meningioma. However, given that the patient did not experience any impairment (in reading or otherwise) for several decades afterwards, it is plausible that these lesions were also due to the recent hemorrhage.

Visual field deficit

This revealed left homonymous hemianopsia (Figure 1).

Handedness

Handedness was assessed by the Edinburgh Handedness Inventory (Oldfield, 1971). M.B.'s score was 0.875, reflecting exclusive or preferred use of the right hand in all activities mentioned in the test.

Early visual processing

We assessed perceptual competency by two subtests of the Benton Visual Retention test (Benton, 1983), by tests of copying from drawings or actual objects, and by the City University of London dynamic color vision test (Barbur, Harlow, & Plant, 1994) and Farnsworth Color Arrangement Test (Farnsworth, 1943). Scores in the Benton subtests were 20/30 for line orientation and 23/32 (corrected for age and sex) for visual discrimination. The first corresponds to the 40th centile of the normative sample, which is below average but within the normal range. The second corresponds to the fifth lower centile and can be classified as moderately defective (see Benton, 1983). Copying (e.g., Figure 2) and color vision were normal. Thus, these tests showed signs of impairment only in visual

discrimination. This is not surprising as poor performance in this subtest is known to be associated with right posterior lesions (Benton, 1983) and with alexia (Varney, 1981).

Overall cognitive functions

We performed an assessment of cognitive functions using the WAIS-R battery (Wechsler, 1981).

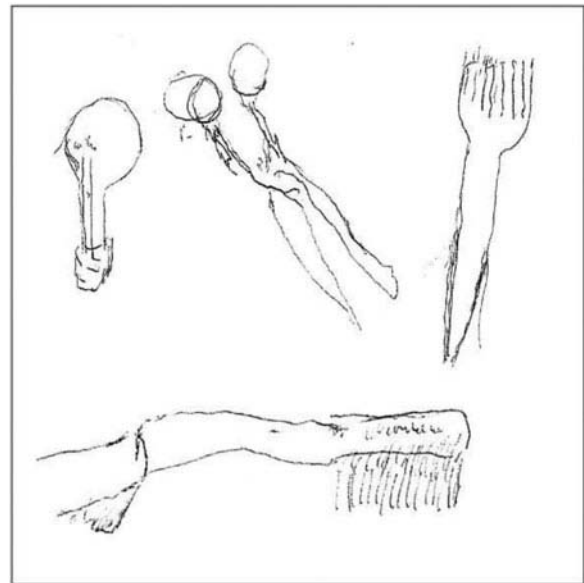


Figure 2. M.B.'s rendition of a light bulb, scissors, a fork, and a toothbrush. The first two were copied from black-and-white drawings. The other two were copied from actual objects.




Figure 1. Visual field testing results, documenting M.B.'s almost complete loss of the left hemifield (L = left eye, R = right eye). Dark areas on the uppermost part of the right hemifields are artifacts due to blepharoptosis. The dark area in the center of the right hemifield of the right eye corresponds to the blind spot. The visual field assessment was performed using Humphrey's automated perimetry and the SITA threshold testing program.

Specific quotients were 91 (verbal) and 79 (performance), yielding an 85 total score that is below average but within the normal range. The poorest subtests were arithmetic (age-corrected scaled score 3), letter–number sequencing (5), block design (6), and picture arrangement (6). These results are quite typical of normally lateralized patients with right-hemispheric lesions (see Ryan et al., 2009).

Spatial attention

We performed tests of visual (line bisection; Schenkenberg, Bradford, & Ajax, 1980; bells test; Gauthier, Dehaut, & Joanne, 1989, drawing from copy), representational (drawing from memory), and somatosensory (reporting the felt location of unseen contact on body parts) spatial attention over several different sessions. These failed to reveal hints of left neglect in any of these domains.

Language production

We assessed impairments related to language production by the naming subtest of the Aachen Aphasia Test (AAT), Italian version (Luzzati, Wilmes, & Bleser, 1996). M.B.'s performance was reasonably good, except for some minor difficulties with compound names (e.g., *aspirapolvere*, Italian for vacuum cleaner but literally dust-inhaler, which he dubbed *aspiratore*, literally, inhaler). Overall, his normalized *t*-score was 60 ± 9 , which is consistent with a minimal impairment.

Color naming

M.B. was able to name all the colors in the PowerPoint palette (red, yellow, blue, green, orange, purple, black, and white) and to provide correct verbal labels for colored pencils. Only in one case, he was unable to name the color (this happened with a purple pencil), and in a second case committed what looked like an outright error (used purple for pink). Given that naming errors involving the color purple are frequent even in normal individuals (De Renzi & Spinnler, 1967), these results do not suggest impairments in color naming.

Object recognition

We asked M.B. to name 20 common objects placed one at a time in front of him (see Table 1 for details).

TABLE 1

Recognition performance by M.B. and a matched control group (average and range) with a set of 20 common objects (a fork, comb, clip, pen, saucer, cup, pencil-sharpener, cork, meter stick, spoon, necklace, battery, lighter, cherry, toothbrush, candy, scissors, watch, tape, key, and calculator). The control group consisted of 8 cardiac patients, all males, average age 67 years (73–60), and average schooling 9 years (5–13)

	<i>M.B.</i>	<i>Controls</i>
Correct (%)	70	93 (90–100%)
Circumlocution (%)	10	6 (0–10%)
Error/not known (%)	20	1 (0–5%)

For 14 of these, he provided correct labels, and for two objects, he provided an appropriate functional description (clip = to hold papers together; toothbrush = to clean one's teeth). For the remaining four objects, the responses did not provide a comparable proof of implicit recognition. Even in these cases, however, responses were compatible with the three-dimensional structure of the object and its parts (e.g., "lighter" when shown a battery), although in one of them they were also compatible with a semantic error ("grape" for cherry). When compared to the performance of a control group matched for age, sex, and schooling (see again Table 1), these results indicate that M.B.'s circumlocutions were within the normal range, whereas his error rate was higher than normal. This confirms a slight impairment in retrieving object names in accord with the previously reported results of the AAT naming test.

Face recognition

We selected 34 photographs from books and magazines portraying well-known contemporary (e.g., Silvio Berlusconi) or historical figures (e.g., Adolf Hitler). These were presented in random order and for each we asked to (1) name the person (e.g., "Sylvester Stallone"); (2) if unable to name, to provide evidence of recognition by mentioning what the person did and in what contexts (circumlocutions, e.g., "famous American actor, was a boxer"). He was able to provide the name only in six cases but he provided convincing evidence of recognition in the additional 27 cases. In comparison to a control group (see Table 2), his overall recognition rate (naming or circumlocution) was within the normal range, although he had difficulty in retrieving the actual names for many faces he recognized.

TABLE 2

Recognition performance by M.B. and a matched control group when viewing 34 photographs of famous individuals (Hollywood actors, widely known international historical figures, widely known Italian politicians, actors, singers, and footballers). For control group details, see the caption of Table 1

	<i>M.B.</i>	<i>Controls</i>
Correct (%)	18	79 (50–91%)
Circumlocation (%)	79	15 (6–35%)
Error/not known (%)	3	6 (0–15%)

Letter recognition

We randomly selected 40 four-letter words with high (top 33%) written frequency from the LEXVAR database (see Barca, Burani, & Arduino, 2002). For each of these, we created a comparable nonword by inverting the first and last letters (e.g., *nido* becomes *oidn*). Finally, we created a set of 80 single-letter stimuli by extracting the two central letters of each selected word. This yielded a set of 160 stimuli that were each presented twice in separate sessions (40 words, 40 nonwords, and 80 single letters). In each session, half of the words were presented in uppercase and the other half in lowercase (see Arditi & Cho, 2007), in counter-balanced order across sessions. The corresponding nonwords and single letters were presented in the same case as the words. For each presented stimulus, we asked M.B. to read aloud the letter or letters. All letters were written using the Verdana-44 font and presented at the screen center using PowerPoint running on an Acer-Aspire laptop (screen resolution 1280 × 800 pixels). Stimulus presentation was controlled manually by the experimenter. To facilitate M.B. in the task, stimuli remained on the screen until response. Sessions were videotaped for off-line analysis using QuickTime Player on a Macintosh computer. To compare reading across the same materials, we analyzed errors only for isolated letters and corresponding central letters in the word and nonword strings. The three conditions did not differ (isolation: 14 errors; words: 16; nonwords: 12). Errors were also similar across cases (uppercase: 19 errors; and lowercase: 23 errors). These results suggest that the recognition of single letters was partly preserved, although there was an evidence of some impairment. Crucially, however, we found no evidence of a single-letter advantage in comparison to letters embedded in letter strings.

We will return to the implications of this finding in the “Discussion” section.

Word reading

We randomly selected 50 words from testing materials and from LEXVAR. The words had 4–11 letters (median = 6 letters) and their written frequency ranged from 1 to 951 occurrences out of 1,500,000 (median = 26). Most had two (18 words), three (18), or four (12) syllables. Two words had 5 syllables, and 85% of all syllables had the most common CV (consonant–vowel) structure. Words were presented and sessions were recorded as described in the previous section. Video and audio tracks were automatically synchronized in the recorded .mov files. Reading times were measured from the start of the presentation of the word to the onset of the vocal response using the time stamps associated with individual video frames in the QuickTime Player software (resolution = 1 s). The median reading time was 8 s, with the faster-read word requiring as much as 2 s and the slowest 31 s. Inspection of reading times as a function of word length revealed a significant correlation (rate = 1.8 s/letter), $t(48) = 5.36$, $p < .0001$. In addition, we observed a significant decrease of time as a function of frequency in logarithmic units, $t(43) = -2.2$, $p < .03$. However, the effect of word length on reading time remained significant, and quite large, after we removed the frequency effect by testing the residuals of the time vs. frequency regression (rate = 1.4 s/letter), $t(43) = 3.4$, $p < .002$. The overall accuracy in reading the 50 words was 58%. Errors consisted almost entirely of substitutions. The only observed omission was the last syllable of the word *cadavere* (corpse), which he read as *casale* (cottage). Overall, this preliminary assessment confirmed a substantial reading impairment, with frequent errors and an abnormally large word length effect (see Figure 3). In particular, the reading time increase for each additional letter (1.4 s/letter after correcting for the frequency effect) was much larger than the typical increase in healthy individuals (about 10 ms/letter, see Behrmann, Plaut, & Nelson, 1998). This is quite similar to what is observed in pure alexics.

Number reading

We created four sets of numbers with 1, 2, 3, or 4 digits (30 numbers per set). Sets were created

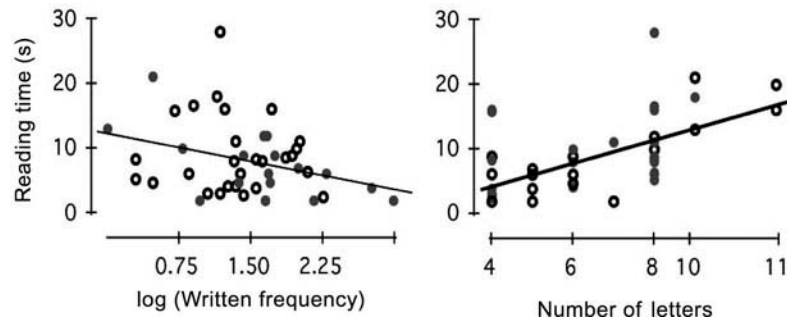


Figure 3. Effect of written frequency (left) and word length (right) on M.B.'s reading times. Gray-filled circles: correctly read word. Open-filled circles: incorrect. Frequency (occurrences/1,500,000) is plotted in logarithmic units to linearize the relationship. The effect of word length remained significant after accounting for the effect of frequency (see text). Reading performance with 50 words of different lengths and written frequency was recorded by video for off-line analysis. Performance was evaluated using reading accuracy and reading times. Reading accuracy was defined in relation to M.B.'s first response. Thus, words were recorded as correct if the first response produced by M.B. corresponded to the word, but not if M.B. corrected himself after an initial wrong response. Reading time, conversely, was defined as the time between the presentation of the word and the end of the initial reading response, be it correct or incorrect. We used reading time, instead of word-naming latency (see Montant & Behrmann, 2000), because M.B. often could not name a word unless he first tried to read it aloud (for a similar approach, see Bartolomeo, Bachoud-Levi, Chokron, & Degos, 2002).

by drawing at random with replacement from 0 to 9 and presented in two sessions of the same length. Methods of presentation and data recording were the same as for letters and words. M.B. read the numbers slowly and laboriously. His median reading time for 4-digit numbers (3.8 s) was similar to the median reading time for the comparable 4-letter words (4 s), and the rate of increase of reading time per each additional number (about 1 s/number) was comparable to the corresponding rate for words. M.B.'s accuracy was also affected by the length of the number. He did reasonably well with 1 and 2 digits (93% and 83% accuracy, respectively), but much worse with 3 and 4 digits (43% with both). A detailed analysis revealed that 39 errors (out of a total of 41) involved omissions of the first digit (e.g., "835" for "2835"). In about half of these cases (21/39), this was the only mistake. In the other half, M.B. skipped the first digit *and* misread one of the remaining digits (e.g., "74" for "354") or, in two instances, two of the remaining digits (e.g., "957" for "3567"). These results suggest that M.B. has an impairment in reading numbers. His impairment is similar to those affecting words in that his reading times are abnormally long. His pattern of errors, however, presents a puzzling feature that involves a systematic tendency to omit the first digit in the conditions of these measurements. Omissions of the initial item are typical of neglect dyslexia (see "Discussion" section). However, because these omissions occurred with numbers, but not with words, this interpretation is problematic. We note, in addition, that all our background assessments

of reading (letters, words, and numbers) did not control fixation and may therefore be affected by M.B.'s visual field loss.

RULING OUT VISUAL FIELD LOSS

Background assessments revealed a complex reading disorder, with components not unlike those typical of pure alexia, possibly accompanied by other, milder concurring deficits. In particular, we observed slow, cumbersome reading and frequent errors both with letters and with numbers, with no evidence of significant impairments in color, object, and face recognition, but with some evidence of impaired naming, especially of faces. The background assessments, however, were conducted under the standard conditions for neuropsychological evaluations and did not control for hemifield of presentation. For this reason, we wondered to what extent his errors in reading words might be due to the visual field deficit. In addition, his tendency to miss the first digit when reading a number also calls for an explanation.

At first blush, this tendency would seem consistent with left neglect. However, standard tests, such as line bisection, ruled this out, and a blind left visual field might explain this tendency in a simpler way. Possibly, M.B. failed to report the first digit of numbers because this digit fell in his blind hemifield and he simply did not see it. He therefore reported the number that he had seen. This would be less likely with words, as 46 of our 50 tested

words become meaningless without the first letter, and this might have encouraged him to read again.

To assess reading errors in conditions that rule out visual field loss as a factor, we presented uppercase words, lowercase words, and numbers either to the right of a central dot or centered around this dot (see caption of Figure 5). We trained M.B. to fixate the dot at a go signal. One second after the go signal, the dot disappeared and the word or number appeared for 100 ms. M.B. attempted to read the string or to report as many letters or digits as he could. In presentations to the right of fixation, the first letter of the word was positioned immediately to the right of the dot, whereas in presentations centered around the dot, we determined the center of the word or number by measuring the distance between the leftmost and rightmost visual element and aligned this center to the dot. Because the 100 ms presentation is shorter than the average saccadic latency for reflexive tasks (about 200 ms; see Fischer, Biscaldi, & Gezeck, 1997; Munoz, Broughton, Goldring, & Armstrong, 1998), these conditions insured that in the right presentation, the stimulus was presented in the spared hemifield, whereas in the centered presentation half of the stimulus was presented in the blind hemifield and

the other half in the spared hemifield. Pilot observations confirmed that stimuli presented to the left of fixation remained completely invisible in these conditions, as expected given the visual field perimetry results. Therefore, we concentrated on the two conditions that were most informative to the role of visual field loss in reading. If visual field loss were the only cause for the reading deficit, his performance should be near ceiling for all letter or digits that fall to the right of fixation. Conversely, if additional factors impair his reading ability, we should continue to observe errors even in this condition.

The methods of stimulus presentation and data recording were similar to those of the background assessments, with the only exception that in this case we used the KeyNote presentation software on a MacBook Pro portable computer. Proportions of words and numbers that were read correctly are presented in Figure 4, as a function of the number of items in the string. With centered presentations, M.B. was hardly ever capable of reading anything. With presentations to the right of fixation, his performance was good, although far from perfect, with two items in the string. However, it declined rapidly with three and four items especially when attempting to read numbers. Although

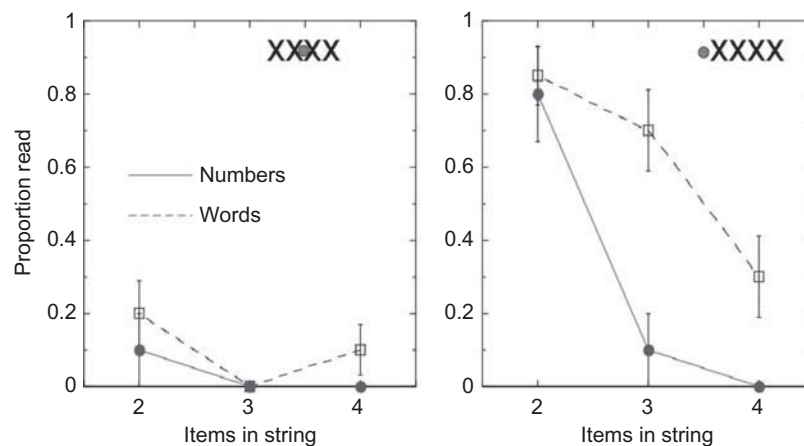


Figure 4. Proportions of 2-, 3-, or 4-item words (open squares) and numbers (filled circles) correctly read by M.B. with 100 ms presentations, either centered around a fixation dot (left) or immediately to the right of the dot (right). Error bars are standard errors. We tested 2-, 3-, or 4-letter or digits, in equal proportions for lowercase words, uppercase words, and numbers. Number sets were created by drawing digits at random without replacement from 0 to 9, whereas words consisted of 2-letter definite articles (e.g., “la,” the), 3-letter indefinite articles (e.g., “una,” a) or words (e.g., “bar,” bar), or 4-letter high-frequency words (e.g., “mare,” sea). Ten stimuli were created for each pairing of fixation condition and length level (yielding a total of 60 numbers) or of fixation, length, and case (120 words). All stimuli were low-contrast (medium gray on white) Gill sans-42 font, generated and timed using a custom-made program running on a MacBook pro laptop, and presented on a Mitsubishi Diamond Scan 70M CRT screen (model no. SD7704CM). As in previous tests, reading was coded as correct based on M.B.’s initial response and successive self-corrections were disregarded. In addition, for each reported letter, we classified errors as omissions (e.g., “a” when shown “la”), or substitutions (e.g., “1761” instead of “9761”). In one case, the response could not be meaningfully classified (“92” when shown “6534,” such that it was impossible to determine which numbers were substituted) and was dropped from analysis.

the advantage of words over numbers in these specific conditions might be ascribed to guessing or to residual automatic recognition of familiar words, the *lack* of an advantage of numbers over words is interesting in another respect. It is often claimed that pure alexics read numbers better than words (see e.g., Ingles & Eskes, 2008). However, a recent meta-analysis suggested that the evidence supporting this dissociation may simply reflect intrinsic differences between the two types of symbols (Starrfelt & Behrmann, 2011). Our results are consistent with this conclusion.

An error analysis is presented in Figure 5. The data clearly demonstrate that M.B. was strongly impaired at reading items that appeared in his blind hemifield. For both words and numbers, he failed to report about 80% of these (top-left panel, first position in the string). Even when he reported them, he often misread them, substituting another

item (bottom-left panel, first position). Conversely, he generally reported items that appeared in the spared hemifield (top-left panel, third and fourth positions; as well as top-right panel). Although he reported these items, however, his substitution rates were abnormal (bottom-left panel, third and fourth positions). Although we did not run an age-matched control group, this was a very easy-reading task. The strings were only 2–4 items long and appeared right at fixation. It would be very surprising for a healthy individual to make any mistake in this task. M.B. substitution rates, conversely, ranged from around 10% (central fixation, considering only positions 3–4 because M.B. could hardly ever see letters on positions 1–2 in this condition) to around 4% (left fixation). An interesting feature of the pattern of substitutions is the difference between positions 3–4 in the central fixation condition and positions 1–2 in the left fixation condition.

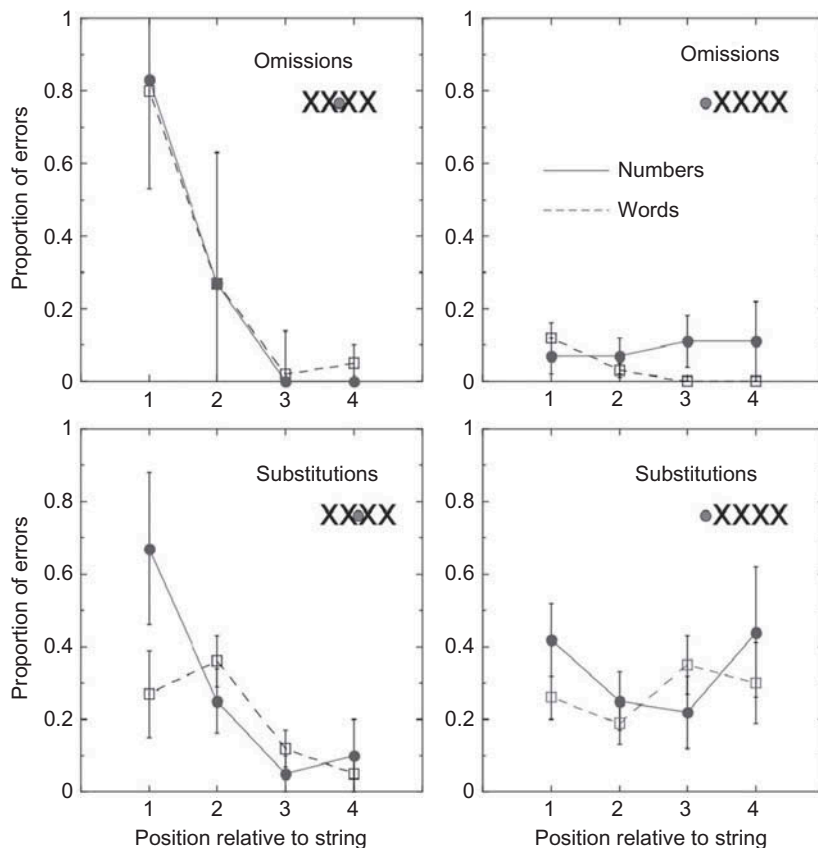


Figure 5. Proportion of errors (omissions and substitutions) as a function of the position of the letter within the string (abscissa) and of fixation. First column: fixation at the center of the string. Second column: fixation at the left of the first item in the string. Open squares: words. Filled circles: numbers. Error bars represent one standard error. When fixation was at the center of the string (left column), the first item always fell in the blind hemifield, the second item fell in the blind hemifield within four-item strings but not within two- and three-item strings, and the third and fourth items never fell in the blind hemifield. When fixation was to the left of the string, conversely, no item ever fell in the blind hemifield.

This difference is statistically significant, $t(3) = 2.8$, $p < .02$, and surprising. Although we have no evidence for this, we speculate that it could be caused again by the hemianopsia. In the central fixation condition, M.B. often did not see the items to the left of fixation. Hence, he had to process 1 or 2 items at most. In the left fixation condition, conversely, he could see all the letters and therefore had to process up to 4 items. This may well have increased the chance of a misread. Overall, these data suggest that M.B.'s reading is affected by his hemianopsia, but visual field loss cannot be the sole cause of the impairment, as many errors are observed even in the spared hemifield.

DISCUSSION

We have described the case of M.B., a right-handed patient with a right-hemispheric lesion. M.B. presents symptoms not unlike what is typically observed in patients with lesions located at the level of the left VWFA. Although part of his reading difficulties stems from left visual field loss, we have documented substantial impairments even when words or numbers fell entirely in his spared visual field and the presentation ruled out eye movements. Although there have already been reports of reading impairments in right handers following right lesions, ours is, to the best of our knowledge, the first to conclusively demonstrate that these impairments cannot be ascribed to hemianopsia. Given the available data, and given that the patient is no longer testable, we cannot provide a definite explanation for these difficulties. In what follows we will however consider candidate accounts. For clarity of exposition, we have grouped them into three main categories: right VWFA, early visual processing, and attentional processes.

Right VWFA

It is possible that M.B. has right-hemisphere dominance for language and that the hemorrhage lesioned his right VWFA. However, several results argue against such an anomalous lateralization account. First, M.B.'s conversation was relatively normal and did not provide an evidence of aphasia, which is often associated to classical alexia. Second, M.B.'s is unambiguously right-handed. Third, the outcome of the neurological assessment was typical of right-hemispheric patients. Fourth, tests of

color-naming failed to provide an evidence for color anomia, which is also associated to classical alexia, as lesions often extend from the VWFA to the mesial-occipital cortex (Damasio & Damasio, 1983). Finally, the site of M.B.'s lesion did not seem to directly include the right fusiform cortex (see Case Report, Anatomical Evidence), although we cannot definitely rule out right fusiform damage due to pressure from the parenchymal hematoma caused by the stroke.

Early visual processing

M.B.'s reading impairment may be related to a dysfunction of early visual processes. In a trivial sense, we know that he has a dysfunction of this type, as the lesion in the right visual area deprived him of the entire left hemifield. However, left hemianopsia cannot underlie the impairments that we have observed in his right field. As an alternative, M.B. could have a form of apperceptive agnosia, an impairment at identifying shapes and objects, which is often associated to bilateral lesions at intermediate visual areas such as V2 and V4 (Humphreys & Riddoch, 1993; Lissauer, 1890). There is evidence that apperceptive agnosics can be impaired at reading words (Heider, 2000; Rizzo, Nawrot, Blake, & Damasio, 1992). However, we deem this possibility also unlikely for at least three reasons. First, although the primary site of M.B.'s lesion may include right intermediate visual areas, his left hemisphere is spared and thus one would not expect impairments in the right hemifield. Second, M.B.'s neurological assessment provided evidence of suboptimal visual discrimination but apart from this his performance in recognizing objects was good. Third, M.B. lives alone and neither he nor his relatives reported difficulties in his daily dealings with objects. Such difficulties would be expected if he was impaired at identifying shapes and objects.

Attentional processes

A third possibility is an impairment in attentional processes that impact on reading. We consider three of these: neglect dyslexia, attentional dyslexia, and sluggish attentional shifting.

In neglect dyslexia, a disorder typically associated with right-hemisphere lesions, patients omit or misread text on the left side of words (see Vallar, Burani, & Arduino, 2010). Although neglect

dyslexia is usually associated with classical unilateral neglect, which M.B. does not have, it has also been observed in patients who do not have unilateral neglect (Haywood & Coltheart, 2001). The key symptom of neglect dyslexia are approximately constant reading errors on the left side of words across horizontal positions (Ptak, Di Pietro, & Schnider, 2012). Because this pattern implies a stimulus-centered spatial framework, independent of retinal position, neglect dyslexia could—in principle—impact on reading in M.B.'s spared hemifield.

In our assessments, we did observe a striking tendency to omit digits on the left side of numbers in free-viewing conditions. However, when double-checking reading responses to words in the same conditions, we failed to note a comparable tendency to omit or misread on the left side of words. For instance, when presented the word *formidabile* (formidable), he uttered *formidalile* (a nonword), and when presented *cadavere* (corpse), he uttered *casale* (cottage). This suggests that, in conditions that did not control for eye movements, M.B. omitted digits that remained unseen because they fell in the blind hemifield. Because numbers remain meaningful even after omitting the first digits, he did not have reason to search for the beginning of the string in this task. Words, on the other hand, become meaningless if the beginning of the string is omitted, and this presumably stimulated him to bring the whole word in the spared hemifield before attempting to read. In support of this interpretation, when we assessed errors for letters presented in the spared hemifield (see Figure 4), we did not observe an increase of omissions or substitutions on the left side of words in the right hemifield.

The term “attentional dyslexia” is instead used to refer to a rare impairment in reading words when these are surrounded by other words (Warrington, Cipolotti, & McNeil, 1993). Patients with the condition perform better with single letters and isolated words than with whole sentences, and make several substitutions, omissions, or additions of letters. Attentional dyslexia has been attributed to impaired attentional selection of visual elements, producing generally inadequate processing of target words as well as confusions between different textual elements (Shallice, 1988). M.B. is hardly able to read whole sentences, but he manages to read some words although laboriously and with many errors. Thus, his impairment appears not unlike what is observed in attentional dyslexia. However, he did not read single letters better than letters

within words or nonwords. If he had an impairment in attentional selection, one would expect flanking letters to disturb letter recognition. In addition, lesions observed in cases of attentional dyslexia suggest an involvement of left parietal cortex (e.g., Friedmann & Gvion, 2001). Given that M.B. has a right lesion, our observations seem at odd with attentional dyslexia also in this respect. Given the scarcity of relevant data, however, the possibility that M.B. has an impairment in attentional selection cannot be completely ruled out. Moreover, a related role of attentional selection involves shifts of attention across successive fixations. Fluid reading requires rapid and precise engagement and disengagement of attention across successive chunks of text. If these shifts were impaired, one would expect to observe frequent substitution errors and strong difficulties when reading sentences that require several such shifts. In accord with this expectation, M.B. was essentially unable to read complete sentences. While reading single letters or short words, which require fewer shifts, one would instead expect a comparably less severe difficulty unless the manner of presentation of the short word requires a rapid shift of attention. Also in accord with this expectation, M.B. did manage to read some short words in unconstrained conditions, but performed much more poorly when four-letter strings were presented briefly at an unpredictable location relative to fixation.

Based on the above considerations, we suggest that M.B.'s alexia might be due to the damage to right-lateralized centers responsible for attentional selection or shifting, or both, during reading. Word recognition requires accurate selection of text elements for processing of associated orthographic and phonological information. Although reading impairments are not ordinarily observed after parietal lesions, there is evidence supporting the idea that attentional selection plays a key role in the neural network for reading. Several studies have suggested that an impairment in rapidly engaging and disengaging attention, usually referred to as “sluggish attentional shifting,” is a critical factor in developmental dyslexia (Facoetti et al., 2003, 2008; Lum, Conti-Ramsden, & Lindell, 2007; Ruffino et al., 2010). These findings have been related to neuroimaging (Pammer, Hansen, Holliday, & Cornelissen, 2006) as well as ERP (Wimmer, Hutzler, & Wiener, 2002) data suggesting that the right-posterior parietal cortex may be involved in spatial and temporal selection during word recognition. In addition, there is evidence

TABLE 3

A synopsis of nine published cases of alexic symptoms following right-hemispheric lesions. Interestingly, only two reported evidence of temporal involvement, potentially implicating the right homolog of the VWFA, whereas four included lesions at the level of the right-posterior parietal cortex

<i>Reference</i>	<i>Main lesion</i>	<i>Hemianopsia</i>	<i>Handedness</i>	<i>Right-dominant</i>
Erkylvrawatr (1978)	Occipital	Unknown	Left	No
Estanol et al. (1999)	Temporo-parietal	Yes	Right	Not tested
Hirose et al. (1977)	Uncertain	Yes	Right	Yes
Mochizuki et al. (1980)	Occipital	Unknown	Right	Not tested
Ogden (1984)	Temporo-parietal	Unknown	Right	No
Pillon et al. (1987)	Occipital	Unknown	Left	Not tested
Shipkin et al. (1981)	Parietal	Yes	Right	Not tested
Thomas and Sanford (2007)	Parietal	No	Unknown	Not tested
Yamaguchi et al. (1984)	Occipital	Occipital	Ambidextrous	Not tested

from TMS studies that the right-posterior parietal cortex plays a key role in the recognition of words (Braet & Humphreys, 2006, 2007; Laycock, Crewther, Fitzgerald, & Crewther, 2009). Finally, a closer consideration of the reports of alexias following right-hemisphere lesions that we found in the literature (see Table 3) reveals that in four of these cases, the main lesion site was indeed at the level of the right parietal cortex (Estanol et al., 1999; Ogden, 1984; Shipkin et al., 1981; Thomas & Sanford, 2007).

CONCLUSIONS

We have studied reading deficits in a right-handed patient presenting with alexic symptoms after a right-hemisphere lesion. We believe that this case has significant interest in the context of the literature on acquired reading disorders. First, this case adds to the existing evidence that reading impairments similar to pure alexia can be observed in right-hemispheric patients. Second, after a detailed assessment of impairments with single letters, words, and numbers, we have been able to conclusively show that the impairment is not due to visual field loss. Although there have already been occasional reports of alexic symptoms after right-hemispheric damage, to the best of our knowledge, this is the first where an hemianopsia explanation can be definitely ruled out. Third, after considering several candidate explanations, we have suggested that the causal factor that best fits the behavioral deficit and the lesion pattern may be related to attentional selection or shifting. While this conclusion remains speculative at present, it may prove

useful to stimulate research or to interpret further patient data in the future.

Original manuscript received 14 September 2012

Revised manuscript received 29 May 2013

Revised manuscript accepted 7 June 2013

First published online 28 August 2013

REFERENCES

- Arditi, A., & Cho, J. (2007). Letter case and text legibility in normal and low vision. *Vision Research*, 47(19), 2499–2505.
- Barbur, J. L., Harlow, A. J., & Plant, G. T. (1994). Insights into the different exploits of colour in the visual cortex. *Proceedings of the Royal Society of London B*, 258(1353), 327–334.
- Barca, L., Burani, C., & Arduino, L. S. (2002). Word naming times and psycholinguistic norms for Italian nouns. *Behavior Research Methods, Instruments, and Computers*, 34, 424–434.
- Bartolomeo, P., Bachoud-Levi, A. C., Chokron, S., & Degos, J. D. (2002). Visually- and motor-based knowledge of letters: Evidence from a pure alexic patient. *Neuropsychologia*, 40(8), 1363–1371.
- Behrmann, M., Plaut, D. C., & Nelson, J. (1998). A literature review and new data supporting an interactive account of letter-by-letter reading. *Cognitive Neuropsychology*, 15, 7–51.
- Benton, A. L. (1983). *Manuale del test di ritenzione visiva, forma riveduta* (it. ed.). Firenze: Organizzazioni Speciali.
- Braet, W., & Humphreys, G. W. (2006). Case mixing and the right parietal cortex: Evidence from rTMS. *Experimental Brain Research*, 168(1–2), 265–271.
- Braet, W., & Humphreys, G. W. (2007). A selective effect of parietal damage on letter identification in mixed case words. *Neuropsychologia*, 45(10), 2226–2233.
- Cohen, L., Henry, C., Dehaene, S., Martinaud, O., Lehericy, S., Lemer, C., & Ferrieux, S. (2004). The pathophysiology of letter-by-letter reading. *Neuropsychologia*, 42(13), 1768–1780.

- Damasio, A. R. (1983). Pure alexia. *Trends in Neurosciences*, 6, 93–96.
- Damasio, A. R., & Damasio, H. (1983). The anatomic basis of pure alexia. *Neurology*, 33, 1573–1583.
- Déjerine, J. (1892). Contribution à l'étude anatomopathologique et clinique des différentes variétés de cécité verbale. *Mémoires de la société de biologie*, 4, 61–90.
- Déjerine, J. (1914). *Sémiologie des affections du système nerveux*, Deuxième ed. (pp. 68–149). Paris: Masson.
- De Renzi, E., & Spinnler, H. (1967). Impaired performance on color tasks in patients with hemispheric damage. *Cortex*, 3, 194–216.
- Erkylvratr, S. (1978). Alexia and left homonymous hemianopsia in a non-right-hander. *Annals of Neurology*, 3, 549–552.
- Estanol, B., Vega-Boada, F., Corte-Franco, G., Juarez, S., Hernandez, R., & Garcia-Ramos, G. (1999). Alexia without agraphia due to the lesion in the right occipital lobe in a right-handed man: Detection of hemispheric lateralization of handedness and language in a right-handed patient. *Revista de Neurologia*, 28(3), 243–245.
- Facoetti, A., Lorusso, M. L., Paganoni, P., Cattaneo, C., Galli, R., & Mascetti, G. G. (2003). The time course of attentional focusing in dyslexic and normally reading children. *Brain and Cognition*, 53(2), 181–184.
- Facoetti, A., Ruffino, M., Peru, A., Paganoni, P., & Chelazzi, L. (2008). Sluggish engagement and disengagement of non-spatial attention in dyslexic children. *Cortex*, 44(9), 1221–1233.
- Farnsworth, D. (1943). The Farnsworth-Munsell 100-hue and dichotomous tests for color vision. *Journal of the Optical Society of America*, 33, 568–578.
- Fischer, B., Biscaldi, M., & Gezeck, S. (1997). On the development of voluntary and reflexive components in human saccade generation. *Brain Research*, 754, 285–297.
- Friedmann, N., & Gvion, A. (2001). Letter position dyslexia. *Cognitive Neuropsychology*, 18, 673–696.
- Gauthier, L., Dehaut, F., & Joanette, Y. (1989). The bells test: A quantitative and qualitative test for visual neglect. *International Journal of Clinical Neuropsychology*, 11, 49–54.
- Haywood, M., & Coltheart, M. (2001). Neglect dyslexia with a stimulus-centred deficit and without visuospatial neglect. *Cognitive Neuropsychology*, 18(7), 577–615.
- Heider, B. (2000). Visual form agnosia: Neural mechanisms and anatomical foundations. *Neurocase*, 6, 1–12.
- Hirose, G., Kin, T., & Murakami, E. (1977). Alexia without agraphia associated with right occipital lesion. *Journal of Neurology, Neurosurgery, and Psychiatry*, 40(3), 225–227.
- Humphreys, G. W., & Riddoch, M. J. (1993). Object agnosias. In C. Kennard (Ed.), *Visual perceptual defects*. London: Baillière Tindall.
- Ingles, J. L., & Eskes, G. A. (2008). A comparison of letter and digit processing in letter-by-letter reading. *Journal of the International Neuropsychological Society*, 14(1), 164–173.
- Laycock, R., Crewther, D. P., Fitzgerald, P. B., & Crewther, S. G. (2009). Tms disruption of V5/Mt+ indicates a role for the dorsal stream in word recognition. *Experimental Brain Research*, 197(1), 69–79.
- Leff, A. P., Scott, S. K., Crewes, H., Hodgson, T. L., Cowey, A., Howard, D., & Wise, R. J., (2000). Impaired reading in patients with right hemianopsia. *Annals of Neurology*, 47(2), 171–178.
- Lissauer, H. (1890). Ein fall von Seelenblindheit nebst einen Beitrage zur Theorie derselben. *Archiv für Psychiatrie und Nervenkrankheiten*, 21, 222–270.
- Lum, J. A., Conti-Ramsden, G., & Lindell, A. K. (2007). The attentional blink reveals sluggish attentional shifting in adolescents with specific language impairment. *Brain and Cognition*, 63(3), 287–295.
- Luzzati, C., Wilmes, K., & Bleser, De. (1996). *AAT Aachner Aphasie Test* (Edizione italiana). Firenze: Giunti O.S.
- McCandliss, B. D., Cohen, L., & Dehaene, S. (2003). The visual word form area: Expertise for reading in the fusiform gyrus. *Trends in Cognitive Sciences*, 7(7), 293–299.
- Mochizuki, H., Sugishita, M., Tohgi, H., & Satoh, Y. (1980). Alexia without agraphia associated with right occipital lobe lesion in a right-hander (author's transl). *Rinsho Shinkeigaku*, 20(9), 750–756.
- Montant, M., & Behrmann, M. (2000). Pure alexia. *Neurocase*, 6, 265–294.
- Munoz, D. P., Broughton, J. R., Goldring, J. E., & Armstrong, I. T. (1998). Age-related performance of human subjects on saccadic eye movement tasks. *Experimental Brain Research*, 121(4), 391–400.
- Ogden, J. A. (1984). Dyslexia in a right-handed patient with a posterior lesion of the right cerebral hemisphere. *Neuropsychologia*, 22(3), 265–280.
- Oldfield, R. C. (1971). The assessment and analysis of handedness: The Edinburgh inventory. *Neuropsychologia*, 9(1), 97–113.
- Pambakian, A.L., & Kennard, C. (1997). Can visual function be restored in patients with homonymous hemianopsia? *British Journal of Ophthalmology*, 81, 324–328.
- Pammer, K., Hansen, P., Holliday, I., & Cornelissen, P. (2006). Attentional shifting and the role of the dorsal pathway in visual word recognition. *Neuropsychologia*, 44(14), 2926–2936.
- Pillon, B., Bakchine, S., & Lhermitte, F. (1987). Alexia without agraphia in a left-handed patient with a right occipital lesion. *Archives of Neurology*, 44(12), 1257–1262.
- Ptak, R., Di Pietro, M., & Schnider, A. (2012). The neural correlates of object-centered processing in reading: A lesion study of neglect dyslexia. *Neuropsychologia*, 50(6), 1142–1150.
- Rizzo, M., Nawrot, M., Blake, R., & Damasio, A. (1992). A human visual disorder resembling area V4 dysfunction in the monkey. *Neurology*, 42, 1175–1180.
- Rowe, F., Wrigth, D., Brand, D., Jackson, C., Price, A., Walker, L., . . . Freeman, C. (2011). Reading difficulty after stroke: Ocular and non ocular causes. *International Journal of Stroke*, 6(5), 404–411.

- Ruffino, M., Trussardi, A. N., Gori, S., Finzi, A., Giovagnoli, S., Menghini, D., . . . Facoetti, A. (2010). Attentional engagement deficits in dyslexic children. *Neuropsychologia*, 48(13), 3793–3801.
- Ryan, J. J., Bartels, J. M., Morris, J., Cluff, R. B., Gontkovsky, S. T., & Wais-II, I. (2009). Viq-Piq and Vci-Poi discrepancies in lateralized cerebral damage. *International Journal of Neuroscience*, 119(8), 1198–1209.
- Schenkenberg, T., Bradford, D. C., & Ajax, E. T. (1980). Line bisection and unilateral visual neglect in patients with neurological impairment. *Neurology*, 30(5), 509–517.
- Shallice, T. (1988). *From neuropsychology to mental structure*. Cambridge: Cambridge University Press.
- Shipkin, P. M., Gray, B. S., Daroff, R. B., & Glaser, J. S. (1981). Alexia without agraphia in a right-handed patient with a left field defect and diffuse cerebral atrophy. *Neuro-Ophthalmology*, 2(2), 123–128.
- Starrfelt, R., & Behrmann, M. (2011). Number reading in pure alexia: A review. *Neuropsychologia*, 49(9), 2283–2298.
- Thomas, J. J., & Sanford, J. M. (2007). Large acute cerebral hemorrhage presenting with pure alexia. *Annals of Emergency Medicine*, 49(4), 428–430.
- Vallar, G., Burani, C., & Arduino, L. S. (2010). Neglect dyslexia: A review of the neuropsychological literature. *Experimental Brain Research*, 206(2), 219–235.
- Varney, N. R. (1981). Letter recognition and visual form discrimination in aphasic alexia. *Neuropsychologia*, 19(6), 795–800.
- Warrington, E. K., Cipolotti, L., & McNeil, J. (1993). Attentional dyslexia: A single case study. *Neuropsychologia*, 31(9), 871–885.
- Wechsler, D. (1981). *Wechsler adult intelligence scale revised*. New York, NY: Psychological Corporation.
- Wimmer, H., Hutzler, F., & Wiener, C. (2002). Children with dyslexia and right parietal lobe dysfunction: Event-related potentials in response to words and pseudowords. *Neuroscience Letters*, 331(3), 211–213.
- Yamaguchi, S., Murata, A., Kobayashi, S., Katsube, T., & Tsunematsu, T. (1984). Alexia without agraphia in an ambidexterous patient due to the right occipital lobe lesion). *Rinsho Shinkeigaku*, 24(7), 711–715.

APPENDIX

Morphological MR (T1-T2 FLAIR) imaging documenting a right temporo-occipital intraparenchymal hematoma with an extended lesion at the level of the right occipital cortex (rows 1–2), and signs of additional right-parietal lesions (row 3). Imaging performed on 23 July 2010 (Figure A1).

