

Magnetic resonance imaging in MELAS syndrome

L. Rosen, S. Phillips, and D. Enzmann

Department of Diagnostic Radiology and Neurology, Stanford University School of Medicine, Stanford, California, USA

Received: 24 August 1989

Summary. MELAS syndrome is a distinct clinical entity belonging to a group of mitochondrial encephalomyopathies characterized by the tetrad of myopathy, encephalopathy, lactic acidosis, and stroke-like episodes. Computed tomography (CT) and magnetic resonance (MR) findings are reviewed in a patient with MELAS. Serial CT studies demonstrated multiple “migrating” infarcts in various stages of evolution involving primarily the posterior temporal and occipital regions. MR was more sensitive than CT in demonstrating the number and extent of cortical lesions in this disease entity.

Key words: MRT – MELAS syndrome

In 1984, Pavlakis et al. [1] described eleven patients with a syndrome consisting of mitochondrial myopathy, encephalopathy, lactic acidosis, and stroke-like episodes which he termed the MELAS syndrome. Additionally, a large proportion of these patients exhibited short stature, hemiparesis, hemianopsia, and the presence of ragged red fibers in skeletal muscle when stained with Gomori trichrome stain. MELAS is a distinct clinical entity belonging to a group of disorders known as mitochondrial encephalopathies. These disorders, presumably stemming from a disorder in mitochondrial function, affect both muscle and the central nervous system. Two closely related but separate entities, the Kearns-Sayre syndrome (KSS) and myoclonus epilepsy associated with ragged-red fibers (MERFF syndrome) have also been described [2, 3].

Only scattered descriptions of neuroradiological findings including computed tomography (CT) and cerebral angiography have been described in MELAS syndrome [5, 6, 11]. To our knowledge, to date there have been no published reports of magnetic resonance imaging in these patients. We report a patient with MELAS syndrome and correlate the CT and MR findings.

Case report

A 27-year-old Hispanic right handed female was admitted in November, 1984 with an acute onset of bitemporal headache, left homonymous hemianopsia, and left sided seizures. She had a previous history of recurrent headaches with visual symptoms. Her past medical history was unremarkable except for small stature noted since early childhood. Family history was negative except for a mother with short stature. A CT scan at that time reportedly demonstrated a right parietal-occipital cortical low density area consistent with infarct. Electroencephalogram (EEG) at that time revealed diffuse slowing without epileptiform potentials. Cerebrospinal fluid (CSF) and serum chemistry analysis were normal. A diagnosis of complicated migraine was made, and the patient was treated with phenytoin and propranolol with subsequent resolution of her visual field deficit.

The patient was well until February, 1985 at which time multiple grand mal seizures recurred which responded to restarting phenytoin. In May, 1985 she was admitted with an acute left hemiparesis and bilateral hearing loss. CT reportedly demonstrated the previously noted right parieto-occipital cortical lesion as well as a new left superior temporal lucency. Echocardiogram, sedimentation rate, antinuclear antibody titers, treponemal antibody screen, and CSF analysis were normal. The patient refused a cerebral angiogram. Her hemiparesis cleared over several weeks, and she subsequently discontinued anticonvulsant therapy.

In September, 1987, the patient presented with focal right sided seizures which became generalized and the patient required endotracheal intubation. The seizures were resistant to anticonvulsant therapy. Sequential arterial blood gas monitoring at that time revealed a persistent metabolic acidosis and serum lactic acid levels were noted to be elevated. CT at that time (Fig. 1) revealed a new region of well-defined cortical low density in the left calcarine cortex with subtle adjacent cortical contrast en-

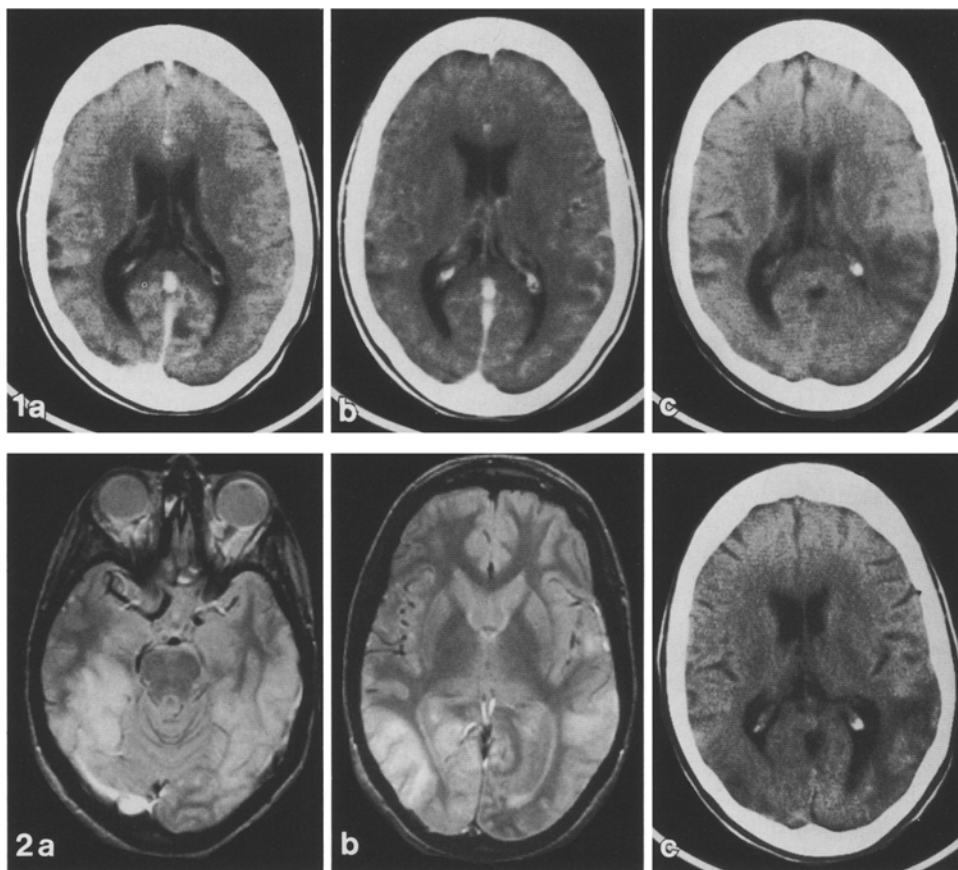


Fig. 1 a–c. Serial brain CT scans in MELAS patient; **a** and **b** are with intravenous contrast. **a** Scan obtained during acute period of seizure activity and metabolic acidosis. A well-defined area of lucency with minimal adjacent cortical enhancement is seen in the left calcarine cortex consistent with a sub-acute infarct. Local right parietal sulcal enlargement is present. **b** Scan obtained 2 months after **a** demonstrates resolution of the previously noted left calcarine lesion. A subtle ill-defined cortical low density lesion is present in the left posterior temporal lobe. Minimal abnormal enhancement is noted. **c** Scan obtained 1 month after **b** demonstrated further definition of left posterior temporal cortical/sub-cortical low density with mild associated mass effect consistent with an evolving infarct

Fig. 2. Axial first echo (**a, b**) images from a T2 weighted sequence (gated and flow compensation, TR = 2600 ms, TE = 30, 80 ms). Bilateral temporal and occipital high signal lesions consistent with infarcts are visualized. The abnormality involving the right calcarine cortex is better visualized by MR (**b, c**). The left calcarine cortex lesion has apparently resolved by MR and CT criteria (compare to **1a** and **1c**). Unenhanced CT (**c**) shows cortical and subcortical low density in the left posterior temporal and left occipital regions as well as ill-defined cortical low density in the corresponding location on the right. Lesions do not adhere to vascular territories

hancement but without significant mass effect. Subtle sulcal enlargement was all that remained of the previously noted right parietal low density lesion. The focus of low density in the left temporal cortex had completely resolved with no residua. A skeletal muscle biopsy demonstrated the presence of ragged red fibers and other changes consistent with a mitochondriopathy.

The patient was next admitted in November, 1987 with headaches, receptive aphasia, and a right visual field deficit. CT at that time showed a new ill-defined cortical and sub-cortical left posterior temporal lucency with local sulcal effacement suggesting an acute infarct (Fig. 1). The left calcarine cortex, in which a low density enhancing lesion had been seen a month earlier, now appeared normal. An ill-defined subtle area of cortical low density with local sulcal effacement was now present in the left posterior temporal region (Fig. 1). The patient was treated with Coenzyme Q and subsequently recovered except for a

mild residual receptive aphasia. Since that time, she has been admitted multiple times for severe headaches, vomiting, visual impairment, and fluctuating aphasia. CT examination in January, 1988 showed the left temporo-occipital infarct to be much more well defined (Fig. 1). Local atrophic changes in that region were now evident. A new ill-defined right occipital lucency with local sulcal effacement was seen.

An MR scan was performed in January, 1988 (General Electric Signa at 1.5T), with T1 weighted and T2 weighted pulse sequences. Multiple areas of cortical and subcortical high signal on T2W images were seen in the right occipital, left occipital, left posterior temporal, and right parietal regions which correlated with the areas of low density seen on CT (Fig. 2). Additionally, high signal was noted in the right medial temporal lobe which could not be appreciated on CT (Fig. 2). No posterior fossa, basal ganglia, or brainstem abnormalities were seen.

Discussion

The patient described in this report meets the general criteria for the diagnosis of MELAS syndrome; that is, there is evidence of myopathy, encephalopathy, lactic acidosis, and stroke-like episodes. Short stature, seizures, normal early development, as well as fluctuating motor and visual symptoms are additional diagnostic criteria outlined by Pavlakis [1] which also pertain to our patient. It is, therefore, a diagnosis to be entertained in young

adult patients presenting with unexplained cerebral infarction, especially when the temporo-occipital regions are involved.

The mitochondrial encephalomyopathies, to which MELAS belongs, encompass a group of loosely related disorders characterized by neuromuscular clinical manifestations as well as proven or proposed defects in the aerobic oxidative metabolic pathway presumably secondary to a structural or functional mitochondrial defect [4]. Kearns-Shy syndrome, Menke's syndrome, Alper's disease, Leigh's disease, myoclonus epilepsy with ragged red fibers syndrome (MERFF), as well as MELAS belong to this group.

Angiographic findings have been described in several MELAS patients [1, 5, 6]. We are aware of seven patients having undergone angiography described in the literature to date [1, 5-9], of whom four had normal studies [7-9], 2 demonstrated findings of local infarction, i. e. focal areas of capillary blush and early venous filling in the regions of lucency seen on CT [6], and one was found to have extracranial carotid occlusion felt to be an angiographic complication. In no cases were findings of vasculitis or emboli noted in these patients.

CT findings have included ventricular dilatation, basal ganglia calcification, focal low-density cortical lesions, and regions of cortical atrophy. Hasuo et al. [6] reported foci of cortical enhancement on CT which did not correspond to vascular territories, but did correspond to areas of capillary blush on angiography. Our patient is typical in that CT demonstrated cortical infarcts of varying ages but which did not correspond to vascular territories. The areas of infarction typically involve the posterior temporal, parietal and occipital lobes. Our patient did not have ventriculomegaly or basal ganglia calcification seen in some MELAS patients. MR demonstrated all areas of CNS involvement more clearly than CT. It showed abnormality in areas that were previously abnormal on CT but had reverted to a normal CT appearance. MR confirmed the predominantly cortical location of the infarcts with less white matter involvement. The posterior temporal and occipital predominance of the infarcts observed in this patient is typical of MELAS patients described previously [6, 11]. This correlates well with the visual symptoms these patients frequently express.

Our patient demonstrated multiple infarcts of varying ages which were seen to evolve on serial CT scanning. New areas of acute infarction were seen on every followup scan, with older lesions either progressing to focal areas of cortical atrophy or, in some instances, normalizing. This "migratory" nature of the lesions in MELAS is an observation which has been seen previously [6, 9, 11]. MR very dramatically demonstrated the multiple cortical lesions in our patient, and MR was more sensitive than CT in visualizing the full extent of the lesions present.

The mechanism for the cerebral infarcts seen in MELAS patients remains unclear. The lesions frequently tend to be in the parietal and occipital lobes, but often they do not correspond to a defined vascular territory [1, 6, 10, 11]. The non-vascular nature of the infarcts suggests the ischemia may be cellular in origin, perhaps relating to the inability of the defective mitochondria to re-

spond adequately to periods of high metabolic demand. Narrowing of the capillary lumen secondary to marked swelling of capillary endothelial cells has been noted in skeletal and smooth muscle biopsies in MELAS patients [9]. It is unclear whether this degree of narrowing is sufficient to cause local tissue ischemia. Neuropathologically, spongy degeneration with microcystic change focal cortical encephalomalacia are seen not only in MELAS syndrome but in Kearns-Shy syndrome (KSS) and MERFF as well [1].

The precise biochemical defect underlying the encephalomyopathies is not yet understood. In the original patients described by Pavlakis [1], two of four demonstrated moderate reduction in cytochrome C oxidase activity. A defect in NADHCoQ reductase has also been described in patients with MELAS [7, 12]. Interestingly, Pavlakis [1] also found increased activity of citrate synthetase and carnitine palmitoyl transferase, two enzymes located in the mitochondrial matrix. This may be a reflection of the increased number of mitochondria seen in these patients. In a more general sense, the presence of ragged red fibers seen in MELAS, KSS, and MERFF has been associated with several other biochemical abnormalities as well, including abnormal function of cytochrome b, succinate-cytochrome c reductase, and ATPase [1, 13, 14].

KSS and MERFF, although similar neuropathologically, have distinct clinical manifestations which would be unlikely to be confused with MELAS. KSS is characterized by onset before age 20, ophthalmoplegia, atypical pigmentary degeneration of the retina, and one of the following: heart block, CSF protein greater than 100 mg/dl, or a cerebellar syndrome [1, 6]. MERFF, described by Fukuhara et al. [2], is characterized by normal early development, myoclonus, and a cerebellar syndrome. KSS and MERFF patients do not demonstrate hemiparesis and hemianopia which are commonly seen in MELAS patients.

There is evidence for familial transmission of MELAS, although the exact mode of inheritance still remains unclear. The syndrome has been described in siblings [8] as well as mother/child pairs [5, 11]. Maternal mitochondrial inheritance, autosomal dominant, and X-linked dominant patterns have all been proposed as possible modes of inheritance [5], all of which could account for the transmission in families described to date.

Driscoll [5] reported a family in which the syndrome spanned three generations, being present in three of 13 family members. He noted that several supposedly unaffected female family members had sensorineural hearing loss and short stature without stroke-like events, perhaps reflecting incomplete penetrance of a carrier state. Additionally, he noted, as have others [1, 5, 6, 11], that affected individuals have a markedly variable clinical course. Some of those affected have an episodic course, often with periods of nearly complete recovery of function, while others have a gradual, progressively worsening clinical course.

MELAS should be considered in the differential diagnosis of cerebral infarction in young adults, especially if they are fluctuating in nature, of varying ages, and do not

clearly correspond to vascular territories. If clinical and radiological findings are suggestive, serum pyruvate and lactate levels should be obtained as well as skeletal muscle biopsy.

Acknowledgement. We gratefully thank Dr. Howard Slyter, Jr. for providing valuable clinical information used in the preparation of this manuscript.

References

1. Pavlakis SG, Philips PC, DiMauro S, et al. (1984) Mitochondrial myopathy, encephalopathy, lactic acidosis, and stroke-like episodes: a distinctive clinical syndrome. *Ann Neurol* 16: 481–488
2. Fukuhara N, Tokuguchi S, Shirakawa K, et al. (1980) Myoclonus epilepsy associated with ragged red fibers: disease entity or a syndrome? Light and electronmicrographic studies of two cases and review of the literature. *J Neurol Sci* 47: 117–133
3. Kearns TP, Sayre GP (1958) Retinitis pigmentosa, external ophthalmoplegia, and complete heart block: unusual syndrome with histologic study in one of two cases. *Arch Ophthalmol* 60: 280–289
4. Shapira Y, Harel S, Russell A (1977) Mitochondrial encephalomyopathies: a group of neuromuscular disorders with defects in oxidative metabolism. *Isr J Med Sci* 13: 161–163
5. Driscoll PF, Larsen PD, Gruber AB (1987) MELAS syndrome involving a mother and two children. *Arch Neurol* 44: 971–973
6. Hasuo K, Tamura S, Yasumori K, et al. (1987) Computed tomography and angiography in MELAS (mitochondrial myopathy, encephalopathy, lactic acidosis, and stroke-like episodes); report of 3 cases. *Neuroradiology* 29: 393–397
7. Morgan-Hughes JA, Hayes DJ, Clark JB, et al. (1982) Mitochondrial encephalomyopathies: biochemical studies in two cases revealing defects in the respiratory chain. *Brain* 105: 553–582
8. Hart Z, Change C, Perrin E, et al. (1977) Familial poliodystrophy, mitochondrial myopathy, and lactic acidemia. *Arch Neurol* 34: 180–185
9. Kobayashi Y, Miyabiyashi S, Takada G, et al. (1982) Ultrastructural study of the childhood mitochondrial myopathic syndrome associated with lactic acidosis. *Eur J Pediatr* 139: 25–30
10. Kuriyama M, Igata A (1985) Mitochondrial encephalopathy, lactic acidosis, and stroke-like syndrome (MELAS) *Ann Neurol* 18: 625–626
11. Yamamoto T, Beppu H, Tsubaki T (1984) Mitochondrial encephalomyopathy: fluctuating symptoms and CT. *Neurology* 34: 1456–1460
12. Land JM, Morgan-Hughes JA, Clark JB (1981) Mitochondrial myopathy: biochemical studies revealing a deficiency of NADH-cytochrome b reductase activity. *J Neurol Sci* 50: 1–13
13. Riggs JE, Shochet SS, Fakadej AV, et al. (1984) Mitochondrial encephalomyopathy with decreased succinate-cytochrome c reductase activity. *Neurology (Cleveland)* 34: 48–53
14. Schotland DL, DiMauro S, Bonilla E, et al. (1976) Neuromuscular disorder associated with a defect in mitochondrial energy supply. *Arch Neurol* 33: 475–479

D. Enzmann, M. D.
 Department of Diagnostic Radiology
 and Nuclear Medicine
 Stanford University School of Medicine
 Stanford, CA 94305
 USA